



Ophthalmology

A Short Textbook

Gerhard K. Lang, M. D.

Professor and Chairman
Department of Ophthalmology and
University Eye Hospital Ulm
Germany

With contributions by

J. Amann, M. D.

O. Gareis, M. D.

Gabriele E. Lang, M. D.

Doris Recker, M. D.

C. W. Spraul, M. D.

P. Wagner, M. D.

305 Illustrations



Thieme
Stuttgart · New York 2000

Library of Congress Cataloging-in-Publication Data

Lang, Gerhard K.

[Augenheilkunde. English]

Ophthalmology : a short textbook /

Gerhard K. Lang ; with contributions by J. Amann... [et al.]. p. ; cm. Includes bibliographical references and index.

ISBN 3131261617

1. Eye-Diseases. 2. Ophthalmology.

I. Amann, J. (Josef) II. Title.

[DNLM: 1. Eye Diseases.

WW 40 L269a 2000a]

RE46.L3413 2000

617.7-dc21

00-032597

Student contributors:

Christopher Dedner, Tübingen

Uta Eichler, Karlsruhe

Heidi Janeczek, Göttingen

Beate Jentzen, Husberg

Mathis Kayser, Freiburg

Kerstin Lipka, Kiel

Maren Molkewehrum, Kiel

Alexandra Ogilvie, Munich

Patricia Ogilvie, Würzburg

Stefan Rose, Oldenburg

Translated by John Grossman, Berlin, Germany

This book is an authorized translation of the German edition published and copyrighted 1998 by Georg Thieme Verlag, Stuttgart, Germany.

Drawings by Markus Voll, Fürstenfeldbruck

© 2000 Georg Thieme Verlag

Rüdigerstraße 14

D-70469 Stuttgart, Germany

Thieme New York, 333 Seventh Avenue

New York, N. Y. 10001 U.S.A.

Typesetting by Druckhaus Götz GmbH, Ludwigsburg

Printed in Germany by Appl, Wemding

ISBN 3-13-126161-7 (GTV)

ISBN 0-86577-936-8 (TNY) 1 2 3 4 5

Important Note: Medicine is an ever-changing science undergoing continual development. Research and clinical experience are continually expanding our knowledge, in particular our knowledge of proper treatment and drug therapy. Insofar as this book mentions any dosage or application, readers may rest assured that the authors, editors, and publishers have made every effort to ensure that such references are in accordance **with the state of knowledge at the time of production of the book.**

Nevertheless this does not involve, imply, or express any guarantee or responsibility on the part of the publishers in respect of any dosage instructions and forms of application stated in the book. **Every user is requested to examine carefully** the manufacturers' leaflets accompanying each drug and to check, if necessary in consultation with a physician or specialist, whether the dosage schedules mentioned therein or the contraindications stated by the manufacturers differ from the statements made in the present book. Such examination is particularly important with drugs that are either rarely used or have been newly released on the market. Every dosage schedule or every form of application used is entirely at the user's own risk and responsibility. The authors and publishers request every user to report to the publishers any discrepancies or inaccuracies noticed.

Some of the product names, patents, and registered designs referred to in this book are in fact registered trademarks or proprietary names even though specific reference to this fact is not always made in the text. Therefore, the appearance of a name without designation as proprietary is not to be construed as a representation by the publisher that it is in the public domain.

This book, including all parts thereof, is legally protected by copyright. Any use, exploitation, or commercialization outside the narrow limits set by copyright legislation, without the publisher's consent, is illegal and liable to prosecution. This applies in particular to photostat reproduction, copying, mimeographing or duplication of any kind, translating, preparation of microfilms, and electronic data processing and storage.

The Concept of the Book in Brief . . .

Definition: The concept behind this book was to organize content and layout according to a uniform structure. This enhances the clarity of the presentation and allows the reader to access information quickly. Each chapter has its own header icon, which is shown on every page of the chapter.

Figure headings summarize the key information presented in the respective figure, eliminating the need for the reader to read through the entire legend.

Epidemiology: In the absence of precise epidemiologic data, the authors state whether the disorder is common or rare wherever possible.

Etiology: This section usually combines information about the etiology and pathogenesis of a disorder and in so doing helps to illuminate important relationships.

Symptoms and diagnostic considerations: These items are usually discussed separately. The section on symptoms includes only the phenomena with which the patient presents. How and by which methods the examiner proceeds from these symptoms to a diagnosis is only discussed under diagnostic considerations.



Sections highlighted with an exclamation mark contain important facts. These may be facts that one is often required to know for examinations, or they may be practical tips that are helpful in diagnosing and treating the disorder.

Differential diagnosis: Wherever possible, this section discusses not only other possible diagnoses but also important criteria for differentiating the disorder from others.

Treatment: This section goes beyond merely documenting all possible therapeutic options. It also explains which therapeutic measures are advisable and offer a prospect of success. The discussion of medical treatment occasionally includes dosage information and examples of preparations used. This is done where such information is relevant to cases students will encounter in practice. The trade names specified do not represent a comprehensive listing.

Prognosis and clinical course: The further development of the book depends in no small measure on your criticism. We are happy to receive any suggestions for improvements as this will help us tailor the next edition to better suit your needs. Please use the enclosed postcard.

Authors

Gerhard K. Lang, M. D.
Professor and Chairman, University Eye Hospital, Ulm,
Germany

J. Amann, M. D.
Research assistant, University Eye Hospital, Ulm

O. Gareis, M. D.
Senior physician, University Eye Hospital, Ulm

Gabriele E. Lang, M. D.
Director, Department of Medical Retina and Laser Surgery,
University Eye Hospital, Ulm

Doris Recker
Orthoptist, University Eye Hospital, Ulm

C. W. Spraul, M. D.
Senior physician, University Eye Hospital, Ulm

P. Wagner, M. D.
Chief of medical staff, University Eye Hospital, Ulm

Preface

When my coworkers and I first took up the task of writing a textbook of ophthalmology that was aimed at medical students but would also be suitable for interns and ophthalmology residents, we did not know exactly what we were getting ourselves into. The next four years were devoted to intensive study of this subject. We did not merely intend to design a book according to the maxims “understand it in medical school,” “learn it for the examination,” and “use it during your internship.” Our broader goal was to give students a textbook that would kindle their interest and indeed their enthusiasm for a “small” specialty like ophthalmology and that would sustain this enthusiasm all the way through a successful examination. In an age in which teaching is undergoing evaluation, we felt this was particularly important. In pursuing this admittedly ambitious goal, we were able to draw upon many years of teaching experience. This experience has shaped the educational concept behind this book and manifests itself in details such as the layout, which is characterized by numerous photographs and illustrative drawings. We have placed special emphasis on the figures in particular. These illustrations make ophthalmology come alive and hopefully will be able to imbue the reader with some of the enthusiasm that the authors themselves have for their specialty.

I would like to take this opportunity to offer my heartfelt thanks to my teacher, Prof. Dr. Dr. hc G. O. H. Naumann, Erlangen, Germany, for his suggestions and for the slides from the collection of the Department of Ophthalmology and University Eye Hospital, Erlangen. I would also like to offer special thanks to my coauthors, Dr. Josef Amann, Dr. Oskar Gareis, Prof. Dr. Gabriele E. Lang, Doris Recker, Dr. Christoph Spraul, and Dr. Peter Wagner for their harmonious cooperation and exceptional initiative in writing this book. I also thank Dr. Eckhard Weingärtner for his assistance in compiling the Appendix.

I would also like to extend special thanks to Dr. Jürgen Lühje and Sabine Bartl of Georg Thieme Verlag, whose professionalism and active and tireless support were a constant source of inspiration to us all. I would again like to thank Markus Voll, Fürstfeldbruck, Germany, for his splendid illustrations.

Ulm, Germany, Summer 2000

Gerhard K. Lang

Table of Contents

1 The Ophthalmic Examination ... 1

(Gabriele E. Lang, Gerhard K. Lang)

- 1.1 Equipment ... 1
- 1.2 History ... 3
- 1.3 Visual Acuity ... 4
- 1.4 Ocular Motility ... 5
- 1.5 Binocular Alignment ... 6
- 1.6 Examination of the Eyelids and Nasolacrimal Duct ... 7
- 1.7 Examination of the Conjunctiva ... 7
- 1.8 Examination of the Cornea ... 10
- 1.9 Examination of the Anterior Chamber ... 11
- 1.10 Examination of the Lens ... 12
- 1.11 Ophthalmoscopy ... 13
- 1.12 Confrontation Field Testing ... 14
- 1.13 Measurement of Intraocular Pressure ... 15
- 1.14 Eyedrops, Ointment, and Bandages ... 15

2 The Eyelids ... 17

(Peter Wagner, Gerhard K. Lang)

- 2.1 Basic Knowledge ... 17
- 2.2 Examination Methods ... 19
- 2.3 Developmental Anomalies ... 20
 - 2.3.1 Coloboma ... 20
 - 2.3.2 Epicanthal Folds ... 21
 - 2.3.3 Blepharophimosis ... 21
 - 2.3.4 Ankyloblepharon ... 22
- 2.4 Deformities ... 22
 - 2.4.1 Ptosis ... 22
 - 2.4.2 Entropion ... 24
 - 2.4.3 Ectropion ... 28
 - 2.4.4 Trichiasis ... 30

- 2.4.5 Blepharospasm ... 30
- 2.5 Disorders of the Skin and Margin of the Eyelid ... 30
 - 2.5.1 Contact Eczema ... 30
 - 2.5.2 Edema ... 31
 - 2.5.3 Seborrhic Blepharitis ... 33
 - 2.5.4 Herpes Simplex of the Eyelids ... 34
 - 2.5.5 Herpes Zoster Ophthalmicus ... 35
 - 2.5.6 Eyelid Abscess ... 36
 - 2.5.7 Tick Infestation of the Eyelids ... 37
 - 2.5.8 Louse Infestation of the Eyelids ... 37
- 2.6 Disorders of the Eyelid Glands ... 38
 - 2.6.1 Hordeolum ... 38
 - 2.6.2 Chalazion ... 39
- 2.7 Tumors ... 40
 - 2.7.1 Benign Tumors ... 40
 - 2.7.1.1 Ductal Cysts ... 40
 - 2.7.1.2 Xanthelasma ... 40
 - 2.7.1.3 Molluscum Contagiosum ... 42
 - 2.7.1.4 Cutaneous Horn ... 42
 - 2.7.1.5 Keratoacanthoma ... 42
 - 2.7.1.6 Hemangioma ... 43
 - 2.7.1.7 Neurofibromatosis (Recklinghausen's Disease) ... 44
 - 2.7.2 Malignant Tumors ... 45
 - 2.7.2.1 Basal Cell Carcinoma ... 45
 - 2.7.2.2 Squamous Cell Carcinoma ... 47
 - 2.7.2.3 Adenocarcinoma ... 47

3 Lacrimal System ... 49 (Peter Wagner, Gerhard K. Lang)

- 3.1 Basic Knowledge ... 49
- 3.2 Examination Methods ... 52
 - 3.2.1 Evaluation of Tear Formation ... 52
 - 3.2.2 Evaluation of Tear Drainage ... 53
- 3.3 Disorders of the Lower Lacrimal System ... 57
 - 3.3.1 Dacryocystitis ... 57
 - 3.3.1.1 Acute Dacryocystitis ... 57
 - 3.3.1.2 Chronic Dacryocystitis ... 60
 - 3.3.1.3 Neonatal Dacryocystitis ... 60
 - 3.3.2 Canaliculitis ... 61
 - 3.3.3 Tumors of the Lacrimal Sac ... 61
- 3.4 Lacrimal System Dysfunction ... 62
 - 3.4.1 Keratoconjunctivitis Sicca ... 62

VIII Table of Contents

- 3.4.2 Illacrimation ... 64
- 3.5 Disorders of the Lacrimal Gland ... 64
 - 3.5.1 Acute Dacryoadenitis ... 64
 - 3.5.2 Chronic Dacryoadenitis ... 65
 - 3.5.3 Tumors of the Lacrimal Gland ... 66

4 **Conjunctiva** ... 67

(Gerhard K. Lang, Gabriele E. Lang)

- 4.1 Basic Knowledge ... 67
- 4.2 Examination Methods ... 68
- 4.3 Conjunctival Degeneration and Aging Changes ... 69
 - 4.3.1 Pinguecula ... 69
 - 4.3.2 Pterygium ... 69
 - 4.3.3 Pseudopterygium ... 71
 - 4.3.4 Subconjunctival Hemorrhage ... 72
 - 4.3.5 Calcareous Infiltration ... 72
 - 4.3.6 Conjunctival Xerosis ... 72
- 4.4 Conjunctivitis ... 74
 - 4.4.1 General Notes on the Causes, Symptoms, and Diagnosis of Conjunctivitis ... 74
 - 4.4.2 Infectious Conjunctivitis ... 82
 - 4.4.2.1 Bacterial Conjunctivitis ... 82
 - 4.4.2.2 Chlamydial Conjunctivitis ... 83
 - 4.4.2.3 Viral Conjunctivitis ... 93
 - 4.4.2.4 Neonatal Conjunctivitis ... 95
 - 4.4.2.5 Parasitic and Mycotic Conjunctivitis ... 98
 - 4.4.3 Noninfectious Conjunctivitis ... 98
- 4.5 Tumors ... 104
 - 4.5.1 Epibulbar Dermoid ... 104
 - 4.5.2 Conjunctival Hemangioma ... 104
 - 4.5.3 Epithelial Conjunctival Tumors ... 105
 - 4.5.3.1 Conjunctival Cysts ... 105
 - 4.5.3.2 Conjunctival Papilloma ... 106
 - 4.5.3.3 Conjunctival Carcinoma ... 107
 - 4.5.4 Melanocytic Conjunctival Tumors ... 108
 - 4.5.4.1 Conjunctival Nevus ... 108
 - 4.5.4.2 Conjunctival Melanosis ... 108
 - 4.5.4.3 Congenital Ocular Melanosis ... 112
 - 4.5.5 Conjunctival Lymphoma ... 113
 - 4.5.6 Kaposi's Sarcoma ... 113
- 4.6 Conjunctival Deposits ... 114

5 Cornea ... 117 (Gerhard K. Lang)

- 5.1 Basic Knowledge ... 117
- 5.2 Examination Methods ... 120
 - 5.2.1 Slit Lamp Examination ... 120
 - 5.2.2 Dye Examination of the Cornea ... 120
 - 5.2.3 Corneal Topography ... 121
 - 5.2.4 Determining Corneal Sensitivity ... 121
 - 5.2.5 Measuring the Density of the Corneal Epithelium ... 121
 - 5.2.6 Measuring the Diameter of the Cornea ... 124
 - 5.2.7 Corneal Pachymetry ... 125
 - 5.2.8 Confocal Corneal Microscopy ... 125
- 5.3 Developmental Anomalies ... 125
 - 5.3.1 Protrusion Anomalies ... 125
 - 5.3.1.1 Keratoconus ... 125
 - 5.3.1.2 Keratoglobus ... 127
 - 5.3.2 Corneal Size Anomalies (Microcornea and Megalocornea) ... 127
- 5.4 Infectious Keratitis ... 127
 - 5.4.1 Protective Mechanisms of the Cornea ... 127
 - 5.4.2 Corneal Infections: Predisposing Factors, Pathogens, and Pathogenesis ... 128
 - 5.4.3 General Notes on Diagnosing Infectious Forms of Keratitis ... 130
 - 5.4.4 Bacterial Keratitis ... 130
 - 5.4.5 Viral Keratitis ... 132
 - 5.4.5.1 Herpes Simplex Keratitis ... 132
 - 5.4.5.2 Herpes Zoster Keratitis ... 134
 - 5.4.6 Mycotic Keratitis ... 134
 - 5.4.7 Acanthamoeba Keratitis ... 136
- 5.5 Noninfectious Keratitis and Keratopathy ... 137
 - 5.5.1 Superficial Punctate Keratitis ... 138
 - 5.5.2 Exposure Keratitis ... 140
 - 5.5.3 Neuroparalytic Keratitis ... 141
 - 5.5.4 Problems with Contact Lenses ... 141
 - 5.5.5 Bullous Keratopathy ... 143
- 5.6 Corneal Deposits, Degenerations, and Dystrophies ... 145
 - 5.6.1 Corneal Deposits ... 145
 - 5.6.1.1 Arcus Senilis ... 145
 - 5.6.1.2 Corneal Verticillata ... 145
 - 5.6.1.3 Argyrosis and Chrysiasis ... 146
 - 5.6.1.4 Iron Lines ... 146
 - 5.6.1.5 Kayser-Fleischer Ring ... 146

X Table of Contents

- 5.6.2 Corneal Degeneration ... 146
 - 5.6.2.1 Calcific Band Keratopathy ... 146
 - 5.6.2.2 Peripheral Furrow Keratitis ... 147
- 5.6.3 Corneal Dystrophies ... 148
- 5.7 Corneal Surgery ... 150
 - 5.7.1 Curative Corneal Procedures ... 152
 - 5.7.1.1 Penetrating Keratoplasty (Fig. 5.18 a) ... 152
 - 5.7.1.2 Lamellar Keratoplasty (Fig. 5.18 b) ... 153
 - 5.7.1.3 Phototherapeutic Keratectomy (Fig. 5.18 c) ... 154
 - 5.7.2 Refractive Corneal Procedures ... 155
 - 5.7.2.1 Photorefractive Keratectomy (Fig. 5.18 d) ... 155
 - 5.7.2.2 Radial Keratotomy (Fig. 5.18 e) ... 155
 - 5.7.2.3 Photorefractive Keratectomy Correction of Astigmatism ... 156
 - 5.7.2.4 Holmium Laser Correction of Hyperopia ... 156
 - 5.7.2.5 Epikeratophakic Keratoplasty (Epikeratophakia) ... 156
 - 5.7.2.6 Excimer Laser In Situ Keratomileusis (LASIK) ... 156

6 Sclera ... 157 (Gerhard K. Lang)

- 6.1 Basic Knowledge ... 157
- 6.2 Examination Methods ... 157
- 6.3 Color Changes ... 157
- 6.4 Staphyloma and Ectasia ... 158
- 6.5 Trauma ... 158
- 6.6 Inflammations ... 158
 - 6.6.1 Episcleritis ... 159
 - 6.6.2 Scleritis ... 161

7 Lens ... 165 (Gerhard K. Lang)

- 7.1 Basic Knowledge ... 165
- 7.2 Examination Methods ... 168
- 7.3 Developmental Anomalies of the Lens ... 169
- 7.4 Cataract ... 170
 - 7.4.1 Acquired Cataract ... 173
 - 7.4.1.1 Senile Cataract ... 173
 - 7.4.2 Cataract in Systemic Disease ... 179
 - 7.4.3 Complicated Cataracts ... 180
 - 7.4.4 Cataract after Intraocular Surgery ... 180

7.4.5	Traumatic Cataract ...	180
7.4.6	Toxic Cataract ...	182
7.4.7	Congenital Cataract ...	182
7.4.7.1	Hereditary Congenital Cataracts ...	183
7.4.7.2	Cataract from Transplacental Infection in the First Trimester of Pregnancy ...	185
7.4.8	Treatment of Cataracts ...	185
7.4.8.1	Medical Treatment ...	185
7.4.8.2	Surgical Treatment ...	185
7.4.8.3	Secondary Cataract ...	192
7.4.8.4	Special Considerations in Cataract Surgery in Children ...	192
7.5	Lens Dislocation ...	195

8 Uveal Tract (Vascular Pigmented Layer) ... 199

(Gabriele E. Lang, Gerhard K. Lang)

8.1	Basic Knowledge ...	199
8.1.1	Iris ...	199
8.1.2	Ciliary Body ...	201
8.1.3	Choroid ...	201
8.2	Examination Methods ...	201
8.3	Developmental Anomalies ...	202
8.3.1	Aniridia ...	202
8.3.2	Coloboma ...	203
8.4	Pigmentation Anomalies ...	206
8.4.1	Heterochromia ...	206
8.4.2	Albinism ...	206
8.5	Inflammation ...	208
8.5.1	Acute Iritis and Iridocyclitis ...	208
8.5.2	Chronic Iritis and Iridocyclitis ...	212
8.5.3	Choroiditis ...	213
8.5.4	Sympathetic Ophthalmia ...	214
8.6	Neovascularization in the Iris: Rubeosis Iridis ...	215
8.7	Tumors ...	216
8.7.1	Malignant Tumors (Uveal Melanoma) ...	216
8.7.2	Benign Choroidal Tumors ...	217

XII Table of Contents

9 Pupil ... 219

(Oskar Gareis, Gerhard K. Lang)

- 9.1 Basic Knowledge ... 219
- 9.2 Examination Methods ... 221
- 9.2.1 Testing the Light Reflex (Table 9.1) ... 221
- 9.2.2 Evaluating the Near Reflex ... 223
- 9.3 Influence of Pharmacologic Agents on the Pupil (Table 9.2) ... 224
- 9.4 Pupillary Motor Dysfunction ... 226
- 9.4.1 Isocoria with Normal Pupil Size ... 227
- 9.4.2 Anisocoria with Dilated Pupil in the Affected Eye ... 228
- 9.4.3 Anisocoria with a Constricted Pupil in the Affected Eye ... 229
- 9.4.4 Isocoria with Constricted Pupils ... 230
- 9.3.5 Isocoria with Dilated Pupils ... 231

10 Glaucoma ... 233

(Gerhard K. Lang)

- 10.1 Basic Knowledge ... 233
- 10.2 Examination Methods ... 238
- 10.2.1 Oblique Illumination of the Anterior Chamber ... 238
- 10.2.2 Slit-Lamp Examination ... 238
- 10.2.3 Gonioscopy ... 238
- 10.2.4 Measuring Intraocular Pressure ... 240
- 10.2.5 Optic Disk Ophthalmoscopy ... 244
- 10.2.6 Visual Field Testing ... 246
- 10.2.7 Examination of the Retinal Nerve Fiber Layer ... 250
- 10.3 Primary Glaucoma ... 251
- 10.3.1 Primary Open Angle Glaucoma ... 251
- 10.3.2 Primary Angle Closure Glaucoma ... 265
- 10.4 Secondary Glaucomas ... 270
- 10.4.1 Secondary Open Angle Glaucoma ... 271
- 10.4.2 Secondary Angle Closure Glaucoma ... 271
- 10.5 Childhood Glaucomas ... 273

11 Vitreous Body ... 279

(Christoph W. Spraul, Gerhard K. Lang)

- 11.1 Basic Knowledge ... 279
- 11.2 Examination Methods ... 281
- 11.3 Aging Changes ... 282

- 11.3.1 Synchysis ... 282
- 11.3.2 Vitreous Detachment ... 282
- 11.4 Abnormal Changes in the Vitreous Body ... 284
- 11.4.1 Persistent Fetal Vasculature (Developmental Anomalies) ... 284
- 11.4.1.1 Mittendorf's Dot ... 284
- 11.4.1.2 Bergmeister's Papilla ... 285
- 11.4.1.3 Persistent Hyaloid Artery ... 285
- 11.4.1.4 Persistent Hyperplastic Primary Vitreous (PHPV) ... 285
- 11.4.2 Abnormal Opacities of the Vitreous Body ... 287
- 11.4.2.1 Asteroid Hyalosis ... 287
- 11.4.2.2 Synchysis Scintillans ... 287
- 11.4.2.3 Vitreous Amyloidosis ... 287
- 11.4.3 Vitreous Hemorrhage ... 287
- 11.4.4 Vitritis and Endophthalmitis ... 290
- 11.4.5 Vitreoretinal Dystrophies ... 293
- 11.4.5.1 Juvenile Retinoschisis ... 293
- 11.4.5.2 Wagner's Disease ... 293
- 11.5 The Role of the Vitreous Body in Various Ocular Changes and Following Cataract Surgery ... 293
- 11.5.1 Retinal Detachment ... 293
- 11.5.2 Retinal Vascular Proliferation ... 293
- 11.5.3 Cataract Surgery ... 294
- 11.6 Surgical Treatment: Vitrectomy ... 294

12 Retina ... 299 (Gabriele E. Lang, Gerhard K. Lang)

- 12.1 Basic Knowledge ... 299
- 12.2 Examination Methods ... 304
- 12.2.1 Examination of the Fundus ... 304
- 12.2.2 Normal and Abnormal Fundus Findings in General ... 308
- 12.2.3 Color Vision ... 311
- 12.2.4 Electrophysiologic Examination Methods (electroretinogram, electrooculogram, and visual evoked potentials; see Fig. 12.2a) ... 312
- 12.3 Vascular Disorders ... 314
- 12.3.1 Diabetic Retinopathy ... 314
- 12.3.2 Retinal Vein Occlusion ... 318
- 12.3.3 Retinal Arterial Occlusion ... 320
- 12.3.4 Hypertensive Retinopathy and Sclerotic Changes ... 323
- 12.3.5 Coats' Disease ... 325
- 12.3.6 Retinopathy of Prematurity ... 326

XIV Table of Contents

- 12.4 Degenerative Retinal Disorders ... 328
 - 12.4.1 Retinal Detachment ... 328
 - 12.4.2 Degenerative Retinoschisis ... 333
 - 12.4.3 Peripheral Retinal Degenerations ... 334
 - 12.4.4 Central Serous Chorioretinopathy ... 335
 - 12.4.5 Age-Related Macular Degeneration ... 337
 - 12.4.6 Degenerative Myopia ... 339
- 12.5 Retinal Dystrophies ... 340
 - 12.5.1 Macular Dystrophies ... 340
 - 12.5.1.1 Stargardt's Disease ... 340
 - 12.5.1.2 Best's Vitelliform Dystrophy ... 341
 - 12.5.2 Retinitis Pigmentosa ... 343
- 12.6 Toxic Retinopathy ... 345
- 12.7 Retinal Inflammatory Disease ... 346
 - 12.7.1 Retinal Vasculitis ... 346
 - 12.7.2 Posterior Uveitis Due to Toxoplasmosis ... 348
 - 12.7.3 AIDS-Related Retinal Disorders ... 349
 - 12.7.4 Viral Retinitis ... 351
 - 12.7.5 Retinitis in Lyme Disease ... 351
 - 12.7.6 Parasitic Retinal Disorders ... 352
- 12.8 Retinal Tumors and Hamartomas ... 353
 - 12.8.1 Retinoblastoma ... 353
 - 12.8.2 Astrocytoma ... 355
 - 12.8.3 Hemangiomas ... 356

13 **Optic Nerve** ... 359

(Oskar Gareis, Gerhard K. Lang)

- 13.1 Basic Knowledge ... 359
 - 13.1.1 Intraocular Portion of the Optic Nerve ... 360
 - 13.1.2 The Intraorbital and Intracranial Portion of the Optic Nerve ... 361
- 13.2 Examination Methods ... 362
- 13.3 Disorders that Obscure the Margin of the Optic Disc ... 363
 - 13.3.1 Congenital Disorders that Obscure the Margin of the Optic Disc ... 363
 - 13.3.1.1 Oblique Entry of the Optic Nerve ... 363
 - 13.3.1.2 Tilted Disc ... 364
 - 13.3.1.3 Pseudopapilledema ... 364
 - 13.3.1.4 Myelinated Nerve Fibers ... 365
 - 13.3.1.5 Bergmeister's Papilla ... 366
 - 13.3.1.6 Optic Disc Drusen ... 366
 - 13.3.2 Acquired Disorders that Obscure the Margin of the Optic Disc ... 367

- 13.3.2.1 Papilledema ... 368
- 13.3.2.2 Optic Neuritis ... 370
- 13.3.2.3 Anterior Ischemic Optic Neuropathy (AION) ... 374
- 13.3.2.4 Infiltrative Optic Disc Edema ... 379
- 13.4 Disorders in which the Margin of the Optic Disc is Well Defined ... 380
- 13.4.1 Atrophy of the Optic Nerve ... 380
- 13.4.2 Optic Nerve Pits ... 383
- 13.4.3 Optic Disc Coloboma (Morning Glory Disc) ... 385
- 13.5 Tumors ... 385
- 13.5.1 Intraocular Optic Nerve Tumors ... 385
- 13.5.2 Retrobulbar Optic Nerve Tumors ... 387

14 Visual Pathway ... 389 (Oskar Gareis, Gerhard K. Lang)

- 14.1 Basic Knowledge ... 389
- 14.2 Examination Methods ... 391
- 14.3 Disorders of the Visual Pathway ... 394
- 14.3.1 Prechiasmal Lesions ... 394
- 14.3.2 Chiasmal Lesions ... 396
- 14.3.3 Retrochiasmal Lesions ... 400

15 Orbital Cavity ... 403 (Christoph W. Spraul, Gerhard K. Lang)

- 15.1 Basic Knowledge ... 403
- 15.2 Examination Methods ... 405
- 15.3 Developmental Anomalies ... 409
- 15.3.1 Craniofacial Dysplasia ... 409
- 15.3.1.1 Craniostenosis ... 409
- 15.3.2 Mandibulofacial Dysplasia ... 410
- 15.3.2.1 Oculoauriculovertebral Dysplasia ... 410
- 15.3.2.2 Mandibulofacial Dysostosis ... 410
- 15.3.2.3 Oculomandibular Dysostosis ... 410
- 15.3.2.4 Rubinstein–Taybi Syndrome ... 410
- 15.3.3 Meningoencephalocele ... 410
- 15.3.4 Osteopathies ... 411
- 15.4 Orbital Involvement in Autoimmune Disorders: Graves' Disease ... 411
- 15.5 Orbital Inflammation ... 413
- 15.5.1 Orbital Cellulitis ... 414

XVI Table of Contents

- 15.5.2 Cavernous Sinus Thrombosis ... 415
- 15.5.3 Orbital Pseudotumor ... 416
- 15.5.4 Myositis ... 416
- 15.5.5 Orbital Periostitis ... 417
- 15.5.6 Mucocele ... 417
- 15.5.7 Mycoses (Mucormycosis and Aspergillomycosis) ... 417
- 15.6 Vascular Disorders ... 418
- 15.6.1 Pulsating Exophthalmos ... 418
- 15.6.2 Intermittent Exophthalmos ... 419
- 15.6.3 Orbital Hematoma ... 419
- 15.7 Tumors ... 420
- 15.7.1 Orbital Tumors ... 420
- 15.7.1.1 Hemangioma ... 420
- 15.7.1.2 Dermoid and Epidermoid Cyst ... 420
- 15.7.1.3 Neurinoma and Neurofibroma ... 420
- 15.7.1.4 Meningioma ... 420
- 15.7.1.5 Histiocytosis X ... 421
- 15.7.1.6 Leukemic Infiltrations ... 421
- 15.7.1.7 Lymphoma ... 421
- 15.7.1.8 Rhabdomyosarcoma ... 421
- 15.7.2 Metastases ... 421
- 15.7.3 Optic Nerve Glioma ... 422
- 15.8 Orbital Surgery ... 422

16 Optics and Refractive Errors ... 423

(Christoph W. Spraul, Gerhard K. Lang)

- 16.1 Basic Knowledge ... 423
- 16.1.1 Uncorrected and Corrected Visual Acuity ... 423
- 16.1.2 Refraction: Emmetropia and Ametropia ... 423
- 16.1.3 Accommodation ... 425
- 16.1.4 Adaptation to Differences in Light Intensity ... 428
- 16.2 Examination Methods ... 429
- 16.2.1 Refraction Testing ... 429
- 16.2.2. Testing the Potential Resolving Power of the Retina in the Presence of Opacified Optic Media ... 431
- 16.3 Refractive Anomalies (Table 16.2) ... 432
- 16.3.1 Myopia (Shortsightedness) ... 432
- 16.3.2 Hyperopia (Farsightedness) ... 436
- 16.3.3 Astigmatism ... 440
- 16.3.4 Anisometropia ... 444
- 16.4 Impaired Accommodation ... 445
- 16.4.1 Accommodation Spasm ... 445

- 16.4.2 Accommodation Palsy ... 446
- 16.5 Correction of Refractive Errors ... 447
 - 16.5.1 Eyeglass Lenses ... 447
 - 16.5.2 Contact Lenses ... 451
 - 16.5.2.1 Advantages and Characteristics of Contact Lenses ... 451
 - 16.5.3 Prisms ... 455
 - 16.5.4 Magnifying Vision Aids ... 455
 - 16.5.5 Aberrations of Lenses and Eyeglasses ... 456

17 Ocular Motility and Strabismus ... 459 (Doris Recker, Josef Amann, Gerhard K. Lang)

- 17.1 Basic Knowledge ... 459
- 17.2 Concomitant Strabismus ... 465
 - 17.2.1 Forms of Concomitant Strabismus ... 467
 - 17.2.1.1 Esotropia ... 467
 - 17.2.1.2 Abnormal Accommodative Convergence/Accommodation Ratio ... 470
 - 17.2.1.3 Exotropia ... 471
 - 17.2.1.4 Vertical Deviations (Hypertropia and Hypotropia) ... 471
 - 17.2.2 Diagnosis of Concomitant Strabismus ... 471
 - 17.2.2.1 Evaluating Ocular Alignment with a Focused Light ... 471
 - 17.2.2.2 Diagnosis of Infantile Strabismic Amblyopia (Preferential Looking Test) ... 472
 - 17.2.2.3 Diagnosis of Unilateral and Alternating Strabismus (Unilateral Cover Test) ... 473
 - 17.2.2.4 Measuring the Angle of Deviation ... 474
 - 17.2.2.5 Determining the Type of Fixation ... 476
 - 17.2.2.6 Testing Binocular Vision ... 476
 - 17.2.3 Therapy of Concomitant Strabismus ... 477
 - 17.2.3.1 Eyeglass Prescription ... 477
 - 17.2.3.2 Treatment and Avoidance of Strabismic Amblyopia ... 477
 - 17.2.3.3 Surgery ... 479
- 17.3 Heterophoria ... 480
- 17.4 Pseudostrabismus ... 481
- 17.5 Ophthalmoplegia and Paralytic Strabismus ... 481
- 17.6 Nystagmus ... 494

XVIII Table of Contents

18 **Ocular Trauma** ... 497

(Gerhard K. Lang)

- 18.1 Examination Methods ... 497
- 18.2 Classification of Ocular Injuries by Mechanism of Injury ... 498
- 18.3 Mechanical Injuries ... 498
 - 18.3.1 Eyelid Injury ... 498
 - 18.3.2 Injuries to the Lacrimal System ... 499
 - 18.3.3 Conjunctival Laceration ... 499
 - 18.3.4 Corneal and Conjunctival Foreign Bodies ... 503
 - 18.3.5 Corneal Erosion ... 505
 - 18.3.6 Blunt Ocular Trauma (Ocular Contusion) ... 506
 - 18.3.7 Blowout Fracture ... 507
 - 18.3.8 Open-Globe Injuries ... 514
 - 18.3.9 Impalement Injuries of the Orbit ... 515
- 18.4 Chemical Injuries ... 517
- 18.5 Injuries Due to Physical Agents ... 523
 - 18.5.1 Ultraviolet Keratoconjunctivitis ... 523
 - 18.5.2 Burns ... 523
 - 18.5.3 Radiation Injuries (Ionizing Radiation) ... 524
- 18.6 Indirect Ocular Trauma: Purtscher's Retinopathy ... 525

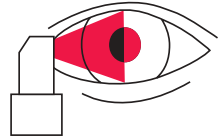
19 **Cardinal Symptoms** ... 527

(Gerhard K. Lang)

Index ... 563

1 The Ophthalmic Examination

Gabriele E. Lang and Gerhard K. Lang



1.1 Equipment

The **basic equipment** for the ophthalmic examination includes the following instruments:

- ❖ *Direct ophthalmoscope* for examining the fundus (Fig. 1.1).
- ❖ *Focused light* (Fig. 1.1) for examining the reaction of the pupil and the anterior chamber.
- ❖ *Aspheric lens* (Fig. 1.1) for examining the anterior chamber.
- ❖ *Eye chart* for testing visual acuity at a distance of 5 meters (20 feet) (Fig. 1.2).

Basic diagnostic instruments for the fundus, pupil, and anterior chamber.



Fig. 1.1 From left to right: direct ophthalmoscope, aspheric lens, and focused light.



Eye charts for testing visual acuity at a distance of 5 meters.

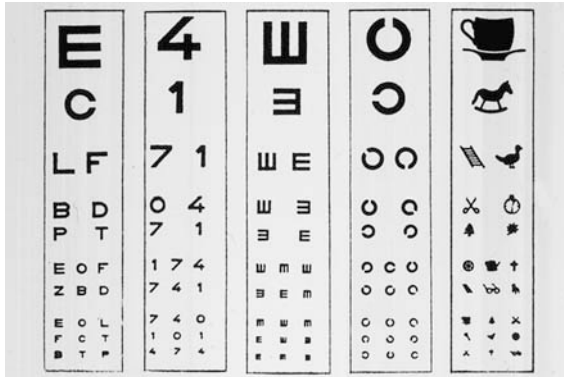


Fig. 1.2 From left to right: Snellen letter chart, Arabic number chart, E game, Landolt broken rings, children's pictograph.

- ❖ *Binocular loupes* for removing corneal and conjunctival foreign bodies.
- ❖ *Desmarres eyelid retractor* and *glass rod* or *sterile cotton swab* for eyelid eversion (Fig. 1.3).

Foreign-body needle for removing superficial corneal foreign bodies (Fig. 1.3).

Recommended medications:

- ❖ *Topical anesthetic* (such as oxybuprocaine 0.4% eyedrops) to provide local anesthesia during removal of conjunctival and corneal foreign bodies and superficial anesthesia prior to flushing the conjunctival sac in chemical injuries.
- ❖ *Sterile buffer solution* for primary treatment of chemical injuries.
- ❖ *Antibiotic eyedrops* for first aid treatment of injuries, *sterile eye compresses*, and a 1 cm *adhesive bandage* for protective bandaging.

! An ophthalmologist should be consulted following any emergency treatment of eye injuries.



Basic diagnostic equipment for removing corneal foreign bodies and eyelid eversion.



Fig. 1.3 From left to right: Foreign body needle, glass spatula, and Desmarres eyelid retractor.

1.2 History

A complete history includes four aspects:

- 1. Family history.** Many eye disorders are hereditary or of higher incidence in members of the same family. Examples include refractive errors, strabismus, cataract, glaucoma, retinal detachment, and retinal dystrophy.
- 2. Medical history.** As ocular changes may be related to systemic disorders, this possibility must be explored. Conditions affecting the eyes include diabetes mellitus, hypertension, infectious diseases, rheumatic disorders, skin diseases, and surgery. Eye disorders such as corticosteroid-induced glaucoma, corticosteroid-induced cataract, and chloroquine-induced maculopathy can occur as a result of treatment with medications such as steroids, chloroquine, Amiodarone, Myambutol, or chlorpromazine (see table in Appendix).
- 3. Ophthalmic history.** The examiner should inquire about corrective lenses, strabismus or amblyopia, posttraumatic conditions, and surgery or eye inflammation.



4. **Current history.** What symptoms does the patient present with? Does the patient have impaired vision, pain, redness of the eye, or double vision? When did these symptoms occur? Are injuries or associated generalized symptoms present?

1.3 Visual Acuity

Visual acuity, the sharpness of near and distance vision, is tested separately for each eye. One eye is covered with a piece of paper or the palm of the hand placed lightly over the eye. The fingers should not be used to cover the eye because the patient will be able to see between them (Fig. 1.4).

The **general practitioner** or **student** can perform an **approximate test of visual acuity**. The patient is first asked to identify certain visual symbols referred to as optotypes (see Fig. 1.2) at a distance of 5 meters or 20 feet (*test of distance vision*). These visual symbols are designed so that optotypes of a certain size can barely be resolved by the normal eye at a specified distance (this standard distance is specified in meters next to the respective symbol). The eye charts must be clean and well illuminated for the examination. The sharpness of vision measured is expressed as a fraction:

Examining visual acuity.



Fig. 1.4 The palm of the hand is placed lightly over the eye to cover it to allow testing of the distance and near vision in the opposite eye.



$$\frac{\text{actual distance}}{\text{standard distance}} = \text{visual acuity.}$$

Normal visual acuity is 5/5 (20/20), or 1.0 as a decimal number, where the actual distance equals the standard distance.

An example of **diminished visual acuity** (see Fig. 1.2): The patient sees only the “4” and none of the smaller symbols on the left eye chart at a distance of 5 meters (20 feet) (actual distance). A normal-sighted person would be able to discern the “4” at a distance of 50 meters or 200 feet (standard distance). Accordingly, the patient has a visual acuity of 5/50 (20/200) or 0.1.

The **ophthalmologist** tests visual acuity after determining objective refraction using the integral lens system of a Phoropter, or a box of individual lenses and an image projector that projects the visual symbols at a defined distance in front of the eye. Visual acuity is automatically calculated from the fixed actual distance and is displayed as a decimal value. *Plus lenses* (convex lenses) are used for *farsightedness* (hyperopia or hypermetropia), *minus lenses* (concave lenses) for *nearsightedness* (myopia), and *cylindrical lenses* for *astigmatism*.

If the patient cannot discern the symbols on the eye chart at a distance of 5 meters (20 feet), the examiner shows the patient the chart at a distance of 1 meter or 3 feet (both the ophthalmologist and the general practitioner use eye charts for this examination). If the patient is still unable to discern any symbols, the examiner has the patient count fingers, discern the direction of hand motion, and discern the direction of a point light source.

1.4 Ocular Motility

With the patient's head immobilized, the examiner asks the patient to look in each of the **nine diagnostic positions of gaze**: 1, straight ahead; 2, right; 3, upper right; 4, up; 5, upper left; 6, left; 7, lower left; 8, down; and 9, lower right (Fig. 1.5). This allows the examiner to diagnose strabismus, paralysis of ocular muscles, and gaze paresis.

Evaluating the **six cardinal directions of gaze** (right, left, upper right, lower right, upper left, lower left) is sufficient when examining paralysis of the one of the six extraocular muscles. The motion impairment of the eye resulting from paralysis of an ocular muscle will be most evident in these positions. Only one of the rectus muscles is involved in each of the left and right positions of gaze (lateral or medial rectus muscle). All other directions of gaze involve several muscles.



Evaluating the nine diagnostic positions of gaze.

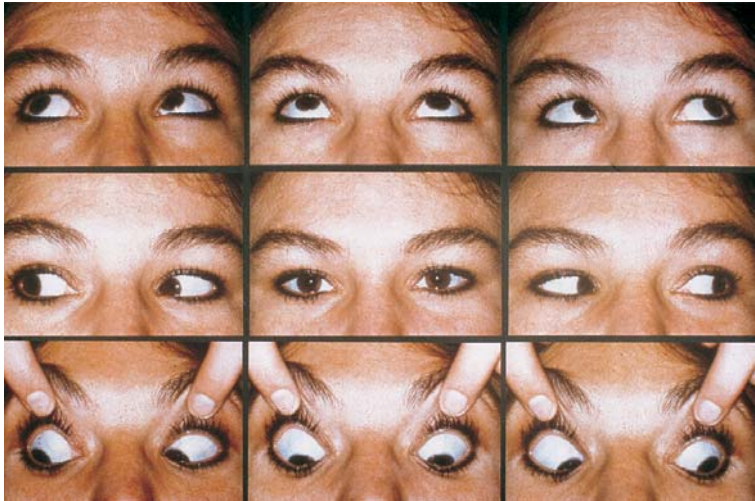

Fig. 1.5 This examination allows the examiner to diagnose strabismus, paralysis of ocular muscles, and gaze paresis.

1.5 Binocular Alignment

Binocular alignment is evaluated with a **cover test**. The examiner holds a point light source beneath his or her own eyes and observes the *light reflections in the patient's corneas* in the near field (40 cm) and at a distance (5 m). The *reflections are normally in the center of each pupil*. If the corneal reflection is not in the center of the pupil in one eye, then a tropia is present in that eye. Then the examiner covers one eye with a hand or an occluder (Fig. 1.6) and tests whether the *uncovered eye* makes a compensatory movement. Compensatory movement of the eye indicates the presence of tropia. However, there will also be a lack of compensatory movement if the eye is blind. The cover test is then repeated with the other eye.

If tropia is present in a newborn with extremely poor vision, the baby will not tolerate the good eye being covered.



Evaluation of binocular alignment.

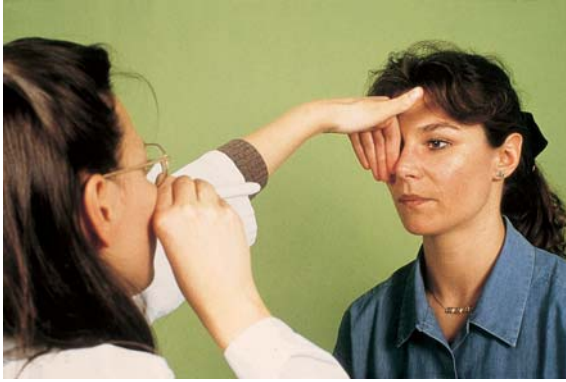

Fig. 1.6 The examiner covers one eye of the patient with the hand to test if the uncovered eye makes a compensatory movement indicating presence of tropia.

1.6 Examination of the Eyelids and Nasolacrimal Duct

The *upper eyelid* covers the superior margin of the cornea. A few millimeters of the sclera will be visible above the *lower eyelid*. The *eyelids* are in direct contact with the eyeball.

Stenosis of the nasolacrimal duct produces a *pool of tears in the medial angle* of the eye with *lacrimation* (epiphora). In inflammation of the lacrimal sac, pressure on the nasolacrimal sac frequently causes a reflux of *mucus or pus from the inferior punctum*. **Patency of the nasolacrimal duct** is tested by instilling a 10% fluorescein solution in the conjunctival sac of the eye. If the dye is present in nasal mucus expelled into paper tissue after two minutes, the lacrimal duct is open (see also p. 53).



Due to the danger of infection, any probing or irrigation of the nasolacrimal duct should be performed only by an ophthalmologist.

1.7 Examination of the Conjunctiva

The conjunctiva is examined by direct inspection. The bulbar conjunctiva is directly visible between the eyelids; the palpebral conjunctiva can only be examined by everting the upper or lower eyelid. The normal conjunctiva is smooth, shiny, and moist. The examiner should be alert to any reddening, secretion, thickening, scars, or foreign bodies.

Eversion of the lower eyelid. The patient looks up while the examiner pulls the eyelid downward close to the anterior margin (Fig. 1.7). This exposes the conjunctiva and the posterior surface of the lower eyelid.



Examination of the lower eyelid and inferior fornix.

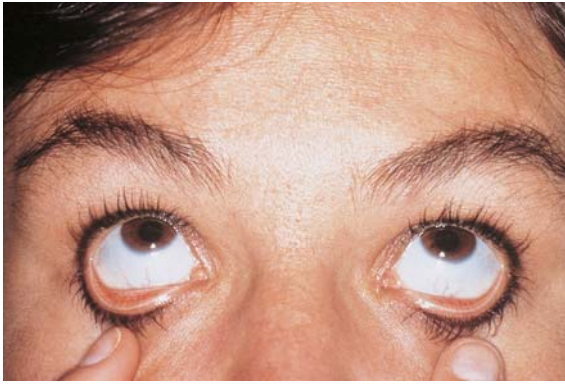

Fig. 1.7 The lower eyelid must be everted for this examination. The patient looks up while the examiner pulls the eyelid downward close to the anterior margin.

Eversion of the upper eyelid. *Simple eversion* (Fig. 1.8). The patient is asked to look down. The patient should repeatedly be told to relax and to avoid tightly shutting the opposite eye. This relaxes the levator palpebrae superioris and orbicularis oculi muscles. The examiner grasps the eyelashes of the upper eyelid between the thumb and forefinger and everts the eyelid against a glass rod or swab used as a fulcrum. Eversion should be performed with a quick levering motion while applying slight traction. The palpebral conjunctiva can then be inspected and cleaned if necessary.

Examination of the upper eyelid (simple eversion).

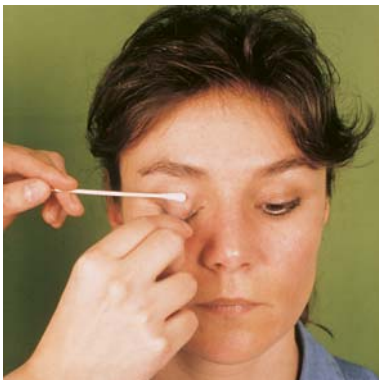
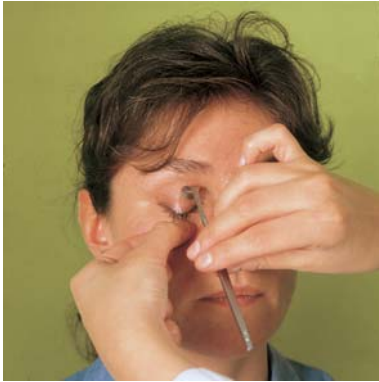
Fig. 1.8 The patient relaxes and looks down. The examiner places a swab superior to the tarsal region of the upper eyelid, grasps the eyelashes of the upper eyelid between the thumb and forefinger, and everts the eyelid using the swab as a fulcrum.

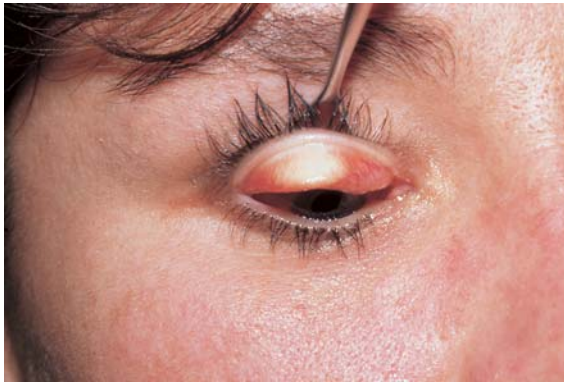

Full eversion with retractor. To expose the superior fornix, the upper eyelid is fully everted around a Desmarres eyelid retractor (Figs. 1.9a and b). This method is used solely by the ophthalmologist and is only discussed here for the sake of completeness. This eversion technique is required to remove foreign bodies or “lost” contact lenses from the superior fornix or to clean the conjunctiva of lime particles in a chemical injury with lime.

Examination of the upper eyelid and superior fornix (full eversion with retractor).



Figs. 1.9a and b In this case, the examiner everts the eyelid around a Desmarres eyelid retractor. In contrast to simple eversion, this procedure allows examination of the superior fornix in addition to the palpebral conjunctiva.





10 1 The Ophthalmic Examination



Blepharospasm can render simple and full eversion very difficult especially in the presence of chemical injury. In these cases, the spasm should first be eliminated by instilling a topical anesthetic such as oxy-buprocaine hydrochloride eyedrops.

1.8 Examination of the Cornea

The cornea is examined with a *point light source* and a *loupe* (Fig. 1.10). The cornea is *smooth, clear, and reflective*. The reflection is distorted in the presence of corneal disorders. Epithelial defects, which are also very painful, will take on an intense green color after application of fluorescein dye; corneal infiltrates and scars are grayish white. Evaluating corneal sensitivity is also important. Sensitivity is evaluated bilaterally to detect possible differences in the reaction of both eyes. The patient looks straight ahead during the examination. The examiner holds the upper eyelid to prevent reflexive closing and touches the cornea anteriorly (Fig. 1.11). Decreased sensitivity can provide information about trigeminal or facial neuropathy, or may be a sign of a viral infection of the cornea.

Examination of the anterior portion of the eye.

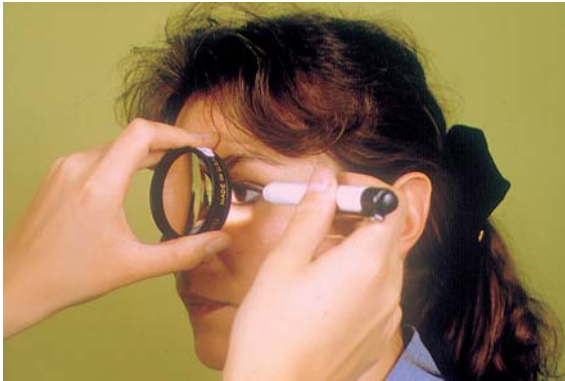

Fig. 1.10 The examiner evaluates the eye using a focal light source and loupe magnification.

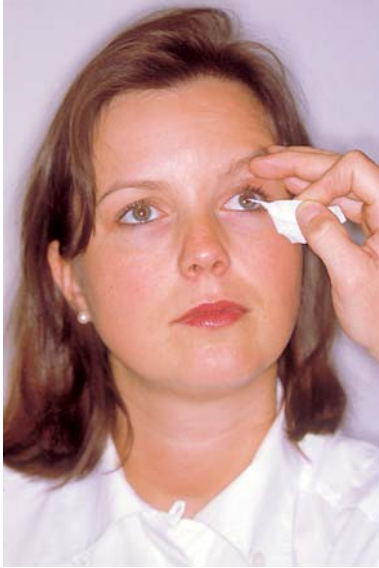**Evaluation of corneal sensitivity.**

Fig. 1.11 Corneal sensitivity can be evaluated with a distended cotton swab. The patient looks straight ahead while the examiner holds the upper eyelid and touches the cornea anteriorly.

1.9 Examination of the Anterior Chamber

The anterior chamber is filled with clear aqueous humor. Cellular infiltration and collection of pus may occur (hypopyon). Bleeding in the anterior chamber is referred to as hyphema.

It is important to **evaluate the depth of the anterior chamber**. In a chamber of *normal depth*, the iris can be well illuminated by a lateral light source (Fig. 1.12). In a *shallow anterior chamber* there will be a medial shadow on the iris. The pupillary dilation should be avoided in patients with shallow anterior chambers because of the risk of precipitating a glaucoma attack. Older patients with “small” hyperopic eyes are a particular risk group.



Dilation of the pupil with a mydriatic is *contraindicated* in patients with a shallow anterior chamber due to the risk of precipitating angle closure glaucoma.



Evaluation of the depth of the anterior chamber.

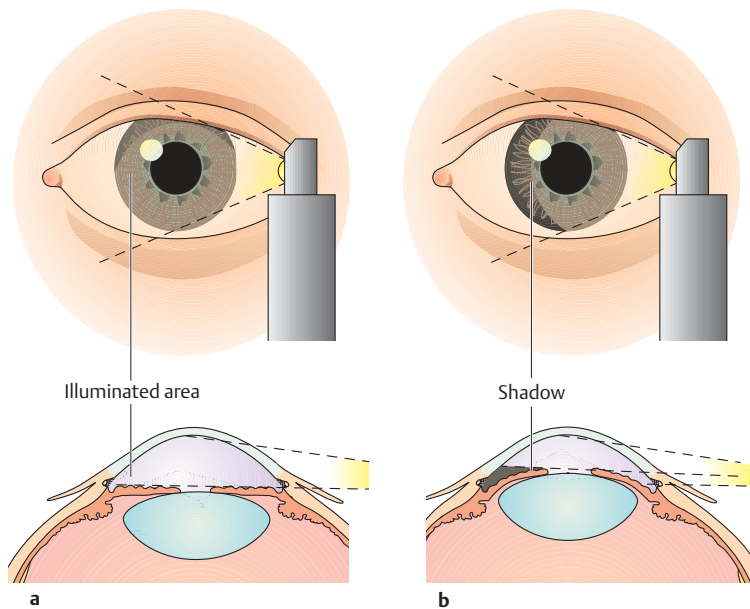


Fig. 1.12 **a** Normal anterior chamber depth: the iris can be well illuminated by a lateral light source. **b** Shallow anterior chamber: a medial shadow is visible on the iris.

1.10 Examination of the Lens

The ophthalmologist uses a **slit lamp** to examine the lens. The eye can also be examined with a **focused light** if necessary.

Direct illumination will produce a *red reflex of the fundus* if the lens is *clear* and *gray shadows* if lens opacities are present. The examiner then illuminates the eye *laterally* with a focused light held as close to the eye as possible and inspects the eye through a +14 diopter loupe (see Fig. 1.10). This examination permits better evaluation of changes in the conjunctiva, cornea, and anterior chamber. With severe opacification of the lens, a gray coloration will be visible in the pupillary plane. Any such light-scattering opacity is referred to as a cataract.



1.11 Ophthalmoscopy

Indirect ophthalmoscopy is usually performed by the ophthalmologist (see p.306) and produces a laterally reversed image of the fundus. Less experienced examiners will prefer **direct ophthalmoscopy**. Here, the ophthalmoscope is held as close to the patient as possible (Fig. 1.13; see also Figs. 12.4b and c). Refractive errors in the patient's eye and the examiner's eye are corrected by selecting the ophthalmoscope lens required to bring the retina into focus. The examiner sees an *erect*, 16 power magnified image of the retina. The examination should be performed in a slightly darkened room with the patient's pupils dilated. Students should be able to identify the *optic* disk. In a normal eye, it is sharply defined structure with vital coloration (i.e., yellowish orange) at the level of the retina and may have a central excavation. The central vein lies lateral to the artery; venous diameter is normally 1.5 times greater than arterial diameter. Each vascular structure should be of uniform diameter, and there should be no vascular constriction where vessels overlap. A spontaneous *venous pulse* is normal; an *arterial pulse* is abnormal. Younger patients will have a foveal and macular light reflex, and the retina will have a reddish color (see Fig. 12.8). An ophthalmologist should be consulted if there are any abnormal findings.

Ophthalmoscopy.

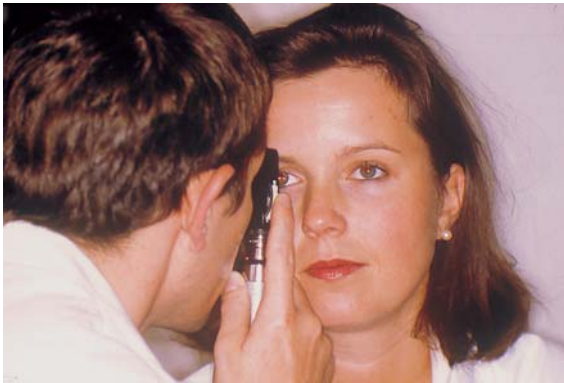

Fig. 1.13 A direct ophthalmoscope produces an erect image of the fundus. The examiner views the patient's right eye with his or her own right eye so that their noses do not interfere with the examination. The examiner's right hand rests on the dial of the ophthalmoscope to bring the retina into focus.



1.12 Confrontation Field Testing

Confrontation testing provides gross screening of the field of vision where perimetry tests are not available (see p. 391).

The patient faces the examiner at a standard distance of 1 m with his or her eyes at the same level as the examiner's (Fig. 1.14). Both focus on the other's opposite eye (i.e., the patient's left eye focuses on the examiner's right eye) while covering their contralateral eye with the palm of the hand. The examiner moves an object such as a pen, cotton swab, or finger from the periphery toward the midline in all four quadrants (in the superior and inferior nasal fields and superior and inferior temporal fields). A patient with a *normal field of vision* will see the object at the same time as the examiner; a patient with an *abnormal or restricted field of vision* will see the object later than the examiner.



Confrontation testing is a gross method of assessing the field of vision. It can be used to diagnose a severely restricted field of vision such as homonymous hemianopsia or quadrant anopsia.

Confrontation field testing.



Fig. 1.14 Confrontation test: the patient faces the examiner at a distance of 1 m with his or her eyes at the same level as the examiner's. Each focuses on the other's opposite eye while covering their contralateral eye with the palm of the hand. The examiner moves a pen from the periphery toward the midline in all four quadrants in the nasal and temporal fields and in the superior and inferior fields.



Measurement of intraocular pressure.

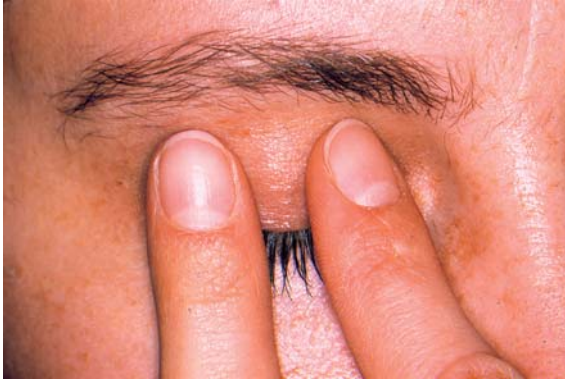

Fig. 1.15 The examiner uses both index fingers to palpate the eye through the upper eyelid.

1.13 Measurement of Intraocular Pressure

With the patient's eyes closed, the examiner places his or her hands on the patient's head and palpates the eye through the upper eyelid with both index fingers (Fig. 1.15). The test is repeated on the contralateral eye for comparison.



A “rock hard” eyeball only occurs in acute angle closure glaucoma. Slight increases in intraocular pressure such as occur in chronic glaucoma will not be palpable.

1.14 Eyedrops, Ointment, and Bandages

Eyedrops and ointment should be administered posterior to the *everted lower eyelid*. One drop or strip of ointment approximately 1 cm long should be administered *laterally to the inferior conjunctival sac*. To avoid injury to the eye, drops should be administered with the patient *supine* (Fig. 1.16) or seated with the *head tilted back and supported*. The person administering the medication places his or her hand on the patient's face for support. Bottles and tubes must not come in contact with the patient's eyelashes as they might otherwise become contaminated. Allow the drops or strip of ointment to drop into the conjunctival sac.



Eye ointment should not be administered following ocular trauma as this may complicate subsequent examination or surgery. Dilation of the pupils with a mydriatic in unconscious patients should be avoided as this complicates neurologic examination.



Administration of eyedrops with the patient supine.

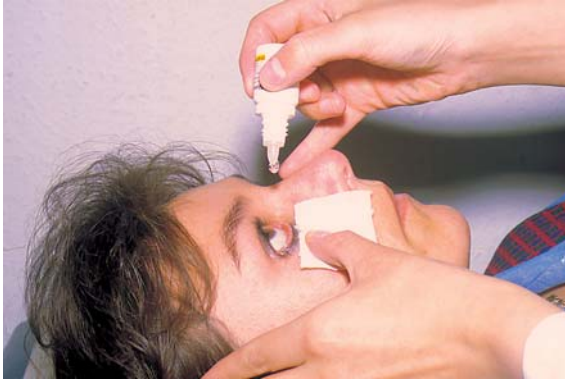

Fig. 1.16 Eye-drops should be administered posterior to the everted lower eyelid.

Eye bandage. A sterile swab or commercially available bandage (two oval layers of bandage material with a layer cotton between them) may be used. Care should be taken to avoid touching the side in contact with the eye. The bandage is fixed to the forehead and cheek with strips of adhesive tape.

2 The Eyelids

Peter Wagner and Gerhard K. Lang



2.1 Basic Knowledge

Protective function of the eyelids: The eyelids are folds of muscular soft tissue that lie anterior to the eyeball and protect it from injury. Their **shape** is such that the eyeball is completely covered when they are closed. Strong mechanical, optical, and acoustic stimuli (such as a foreign body, blinding light, or sudden loud noise) “automatically” elicit an **eye closing reflex**. The cornea is also protected by an additional upward movement of the eyeball (**Bell’s phenomenon**). **Regular blinking** (20–30 times a minute) helps to uniformly distribute glandular secretions and tears over the conjunctiva and cornea, keeping them from drying out.

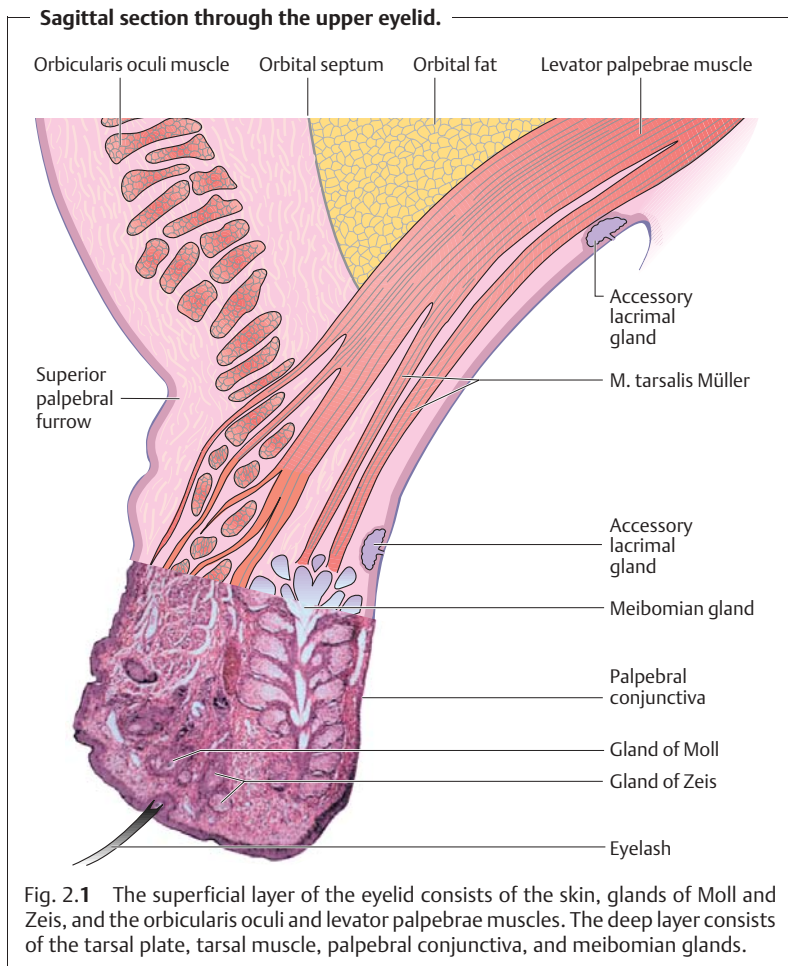
Structure of the eyelids: The eyelids consist of superficial and deep layers (Fig. 2.1).

❖ **Superficial layer:**

- Thin, well vascularized layer of **skin**.
- Sweat glands.
- Modified **sweat gland** and **sebaceous glands** (ciliary glands or **glands of Moll**) and **sebaceous glands** (**glands of Zeis**) in the vicinity of the eyelashes.
- Striated muscle fibers of the **orbicularis oculi muscle** that actively closes the eye (supplied by the facial nerve).

❖ **Deep layer:**

- The **tarsal plate** gives the eyelid firmness and shape.
- Smooth musculature of the levator palpebrae that inserts into the tarsal plate (**tarsal muscle**). The tarsal muscle is supplied by the sympathetic nervous system and regulates the width of the palpebral fissure. High sympathetic tone contracts the tarsal muscle and widens the palpebral fissure; low sympathetic tone relaxes the tarsal muscle and narrows the palpebral fissure.
- The **palpebral conjunctiva** is firmly attached to the tarsal plate. It forms an articular layer for the eyeball. Every time the eye blinks, it acts like a windshield wiper and uniformly distributes glandular secretions and tears over the conjunctiva and cornea.



- **Sebaceous glands (tarsal or meibomian glands)**, tubular structures in the cartilage of the eyelid, which lubricate the margin of the eyelid. Their function is to prevent the escape of tear fluid past the margins of the eyelids. The fibers of Riolan's muscle at the inferior aspect of these sebaceous glands squeeze out the ducts of the tarsal glands every time the eye blinks.



The **eyelashes** project from the anterior aspect of the margin of the eyelid. On the upper eyelid, approximately 150 eyelashes are arranged in three or four rows; on the lower eyelid there are about 75 in two rows. Like the **eyebrows**, the eyelashes help prevent dust and sweat from entering the eye. The orbital septum is located between the tarsal plate and the margin of the orbit. It is a membranous sheet of connective tissue attached to the margin of the orbit that retains the orbital fat.

2.2 Examination Methods

The eyelids are examined by direct inspection under a bright light. A slit lamp may be used for this purpose. **Bilateral inspection of the eyelids** includes the following aspects:

- ❖ *Eyelid position*: Normally the margins of the eyelids are in contact with the eyeball and the puncta are submerged in the lacus lacrimalis.
- ❖ *Width of the palpebral fissure*: When the eye is open and looking straight ahead, the upper lid should cover the superior margin of the cornea by about 2 mm. Occasionally a thin strip of sclera will be visible between the cornea and the margin of the lower lid. The width of the palpebral fissure is normally 6–10 mm, and the distance between the lateral and medial angles of the eye is 28–30 mm (Fig. 2.2). Varying widths of the gaps between the eyelids may be a sign of protrusion of the eyeball, enophthalmos, or eyeballs of varying size (Table 2.1).
- ❖ *Skin of the eyelid*: The skin of the eyelid is thin with only a slight amount of subcutaneous fatty tissue. Allergic reaction and inflammation can rapidly cause extensive edema and swelling. In older patients, the skin of the upper eyelid may become increasingly flaccid (cutis laxa senilis). Occasionally it can even hang down over the eyelashes and restrict the field of vision (dermatochalasis or blepharochalasis).

Dimensions of the normal palpebral fissure.

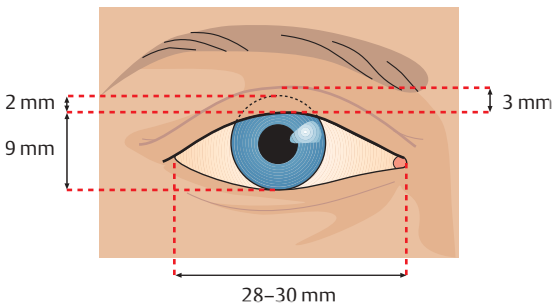


Fig. 2.2 The width of the palpebral fissure is an important indicator for a number of pathologic changes in the eye (see Table 2.1).



Table 2.1 Possible causes of abnormal width of the palpebral fissure

Increased palpebral fissure	Decreased palpebral fissure
<ul style="list-style-type: none">❖ Peripheral facial paresis (lagophthalmos)❖ Grave's disease❖ Perinaud's syndrome❖ Buphthalmos❖ High-grade myopia❖ Retrobulbar tumor	<ul style="list-style-type: none">❖ Congenital ptosis❖ Ptosis in oculomotor nerve palsy❖ Ptosis in myasthenia gravis❖ Sympathetic ptosis (with Horner's syndrome, see pp. 23–24)❖ Progressive ophthalmoplegia (Graefe's sign)❖ Microphthalmos❖ Enophthalmos❖ Shrinkage of the orbital fat (as in senile enophthalmos)

The **palpebral conjunctiva** is examined by **simple eversion** of the upper eyelid (see Figs. 1.7 and 1.8). The normal palpebral conjunctiva is smooth and shiny without any scar strictures or papilliform projections.

Full eversion of the upper eyelid with a Desmarres eyelid retractor (see Fig. 1.9, p.9) allows examination of the **superior fornix** (for normal appearance, see palpebral conjunctiva).

2.3 Developmental Anomalies

2.3.1 Coloboma

Definition

A normally unilateral triangular eyelid defect with its base at the margin of the eyelid occurring most often in the upper eyelid (Fig. 2.3).

Epidemiology and etiology. Colobomas are *rare* defects resulting from a reduction malformation (defective closure of the optic cup). They are only rarely the result of an injury.

Diagnostic considerations: The disorder is often accompanied by additional deformities such as dermoid cysts or a microphthalmos. Congenital defects of the first embryonic branchial arch that can result in coloboma include Franceschetti's syndrome (mandibulofacial dysostosis) or Goldenhar's syndrome (oculoauriculovertebral dysplasia). Depending on the extent of the coloboma, desiccation symptoms on the conjunctiva and cornea with incipient ulceration may arise from the lack of regular and uniform moistening of the conjunctiva and cornea.



Congenital coloboma.

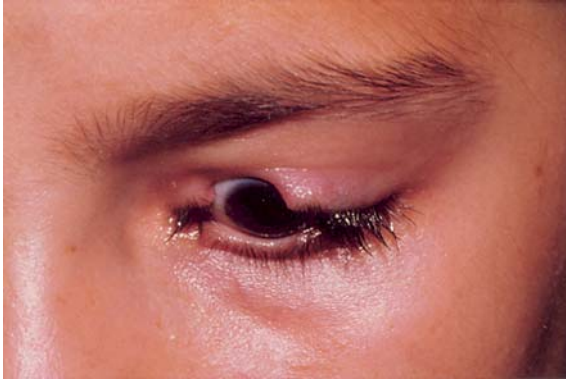

Fig. 2.3 The triangular eyelid defect with its base at the margin of the eyelid results from a reduction malformation during closure of the optic cup in the embryonic stage.

Treatment: Defects are closed by direct approximation or plastic surgery with a skin flap.

2.3.2 Epicanthal Folds

A crescentic fold of skin usually extending bilaterally between the upper and lower eyelids and covering the medial angle of the eye. This *rare congenital anomaly* is *harmless* and typical in eastern Asians. However, it also occurs with Down's syndrome (trisomy 21 syndrome). Thirty per cent of newborns have epicanthal folds until the age of six months. Where one fold is more pronounced, it can simulate esotropia. The nasal bridge becomes more pronounced as the child grows, and most epicanthal folds disappear by the age of four.

2.3.3 Blepharophimosis

This refers to **shortening of the horizontal palpebral fissure without pathologic changes in the eyelids**. The palpebral fissure, normally 28–30 mm wide, may be reduced to half that width. Blepharophimosis is a *rare* disorder that is either *congenital* or *acquired* (for example, from scar contracture or aging). As long as the center of the pupil remains unobstructed despite the decreased size of the palpebral fissure, *surgical enlargement* of the palpebral fissure (by canthotomy or plastic surgery) has a purely cosmetic purpose.



2.3.4 Ankyloblepharon

This refers to **horizontal shortening of the palpebral fissure with fusion of the eyelids at the lateral and medial angles of the eye**. Usually, the partial or total fusion between the upper and lower eyelids will be bilateral, and the palpebral fissure will be partially or completely occluded as a result. Posterior to the eyelids, the eyeball itself will be deformed or totally absent. Ankyloblepharon is frequently associated with other skull deformities.

2.4 Deformities

2.4.1 Ptosis

Definition

Paralysis of the levator palpebrae muscle with resulting drooping of one or both upper eyelids (from the Greek *ptosis*, a falling). The following forms are differentiated according to their origin (see also Etiology):

- ❖ **Congenital ptosis** (Fig. 2.4).
- ❖ **Acquired ptosis:**
 - Paralytic ptosis.
 - Sympathetic ptosis.
 - Myotonic ptosis.
 - Traumatic ptosis.

Epidemiology. On the whole ptosis is a rare disorder.

Etiology: Ptosis may be congenital or acquired.

Congenital ptosis.

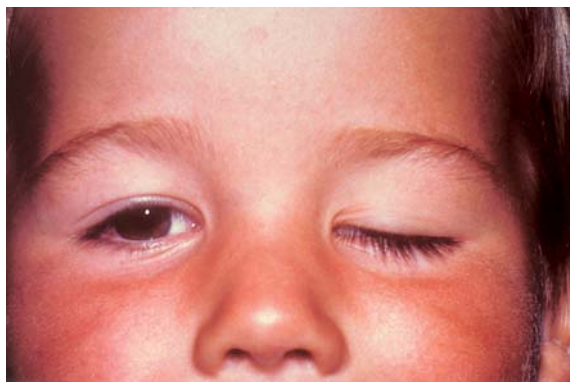

Fig. 2.4 Congenital ptosis of the levator palpebrae muscle causes the upper eyelid to droop; usually the deformity is unilateral. Amblyopia will result if the center of the pupil is covered.



Congenital ptosis. The disorder is usually hereditary and is primarily autosomal dominant as opposed to recessive. The cause is frequently *aplasia* in the *core of the oculomotor nerve* (neurogenic) that supplies the levator palpebrae muscle; less frequently it is attributable to an *underdeveloped levator palpebrae muscle* (myogenic).

Acquired ptosis:

- ❖ Neurogenic causes:
 - Oculomotor palsy (*paralytic ptosis*).
 - Lesions in the sympathetic nerve (*sympathetic ptosis*) is Horner's palsy (ptosis, miosis, and enophthalmos).
- ❖ Myogenic ptosis: *myasthenia gravis* and *myotonic dystrophy*.
- ❖ *Traumatic ptosis* can occur after injuries.

Symptoms. The drooping of the upper eyelid may be *unilateral* (usually a sign of a *neurogenic* cause) or *bilateral* (usually a sign of a *myogenic* cause). A characteristic feature of the *unilateral form* is that the patient attempts to increase the palpebral fissure by frowning (contracting the frontalis muscle).

Congenital ptosis (Fig. 2.4) generally affects one eye only; bilateral symptoms are observed far less frequently (7%).

Diagnostic considerations: Congenital ptosis. The affected eyelid in general is underdeveloped. The skin of the upper eyelid is smooth and thin; the superior palpebral furrow is absent or ill-defined. A typical symptom is “*lid lag*” in which the upper eyelid does not move when the patient glances down. *This important distinguishing symptom excludes acquired ptosis in differential diagnosis.* In about 3% of all cases, congenital ptosis is associated with epicanthal folds and blepharophimosis (Waardenburg syndrome).

Congenital ptosis can occur in varying degrees of severity and may be complicated by the presence of additional eyelid and ocular muscle disorders such as strabismus.



Congenital ptosis in which the upper eyelid droops over the center of the pupil always involves an increased risk of amblyopia.

Acquired ptosis:

- ❖ *Paralytic ptosis* in oculomotor palsy (see also Chap. 17) is usually unilateral with the drooping eyelid covering the whole eye. Often there will be other signs of palsy in the area supplied by the oculomotor nerve. In *external oculomotor palsy*, only the extraocular muscles are affected (mydriasis will not be present), whereas in *complete oculomotor palsy*, the inner ciliary muscle and the sphincter pupillae muscle are also affected (internal ophthalmoplegia with loss of accommodation, mydriasis, and complete loss of pupillary light reflexes).
- ❖ *Myasthenia gravis* (myogenic ptosis that is often bilateral and may be asymmetrical) is associated with abnormal fatigue of the striated



extraocular muscles. Ptosis typically becomes more severe as the day goes on.

- ❖ *Sympathetic ptosis* occurs in Horner's palsy (ptosis, miosis, and enophthalmos).



Rapidly opening and closing the eyelids provokes ptosis in myasthenia gravis and simplifies the diagnosis.

Treatment:

- ❖ **Congenital ptosis:** This involves surgical retraction of the upper eyelid (Fig. 2.5a–c), which should be undertaken as quickly as possible when there is a risk of the affected eye developing a visual impairment as a result of the ptosis.
- ❖ **Acquired ptosis:** Treatment depends on the cause. As palsies often *resolve spontaneously*, the patient should be observed before resorting to surgical intervention. Conservative treatment with special eyeglasses may be sufficient even in irreversible cases.

Because of the risk of overcorrecting or undercorrecting the disorder, several operations may be necessary.

Prognosis and complications: Prompt surgical intervention in congenital ptosis can prevent *amblyopia*. Surgical overcorrection of the ptosis can lead to desiccation of the conjunctiva and cornea with *ulceration* as a result of incomplete closure of the eyelids.

2.4.2 Entropion

Definition

Entropion is characterized by inward rotation of the eyelid margin. The margin of the eyelid and eyelashes or even the outer skin of the eyelid are in contact with the globe instead of only the conjunctiva. The following forms are differentiated according to their origin (see Etiology):

- ❖ **Congenital entropion** (Fig. 2.6).
- ❖ **Spastic entropion** (Fig. 2.7).
- ❖ **Cicatricial entropion**.

Epidemiology: Congenital entropion occurs frequently among Asians but is rare among people of European descent, in whom the spastic and cicatricial forms are more commonly encountered (see also Chap. 18).

Etiology:

- ❖ **Congenital entropion:** This results from fleshy thickening of the skin and orbicularis oculi muscle near the margin of the eyelid. *Usually the lower eyelid is affected.* This condition may persist into adulthood.



Methods of surgical retraction of the upper eyelid.

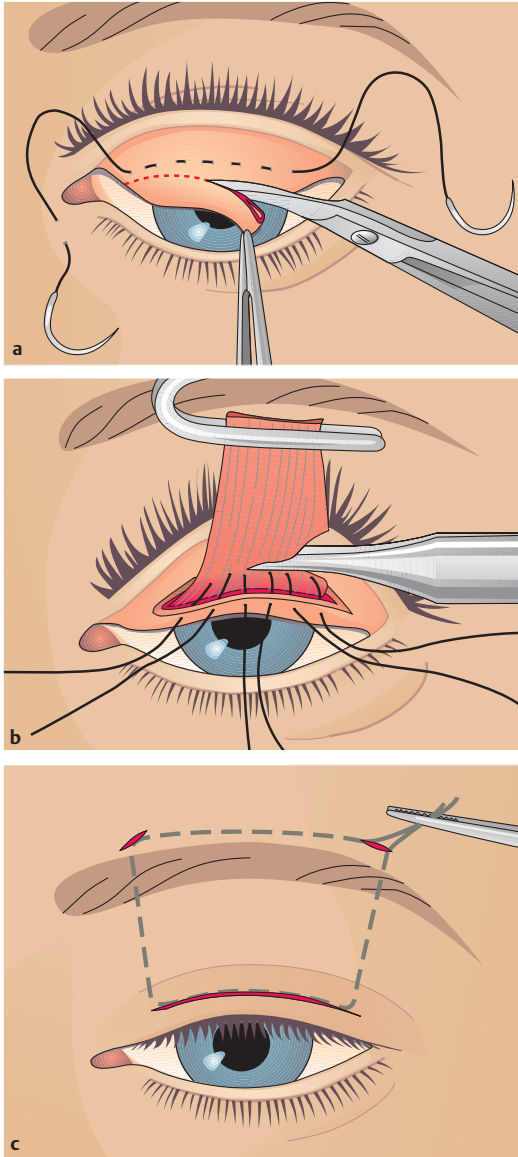


Fig. 2.5 **a** The Fasanella-Servat procedure, indicated for correction of minimal ptosis, involves resection of a portion of the tarsus (2 mm or less) to vertically shorten the eyelid. **b** The amount of muscle removed in a levator resection depends on levator function (ranging from approximately 10 mm with slight ptosis, up to 22 mm with moderate ptosis). **c** Where levator function is poor (less than 5 mm), the upper eyelid can be connected to tissue in the eyebrow region. The frontalis suspension technique may employ autogenous fascia lata or plastic suture.



Congenital entropion.

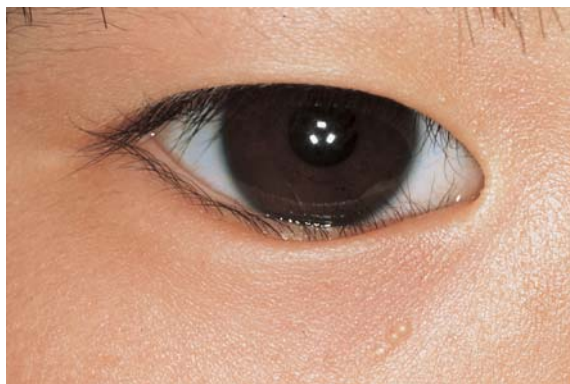

Fig. 2.6 Congenital inward rotation of the margins of the upper and lower eyelids is a frequent finding in Asian populations and is usually asymptomatic.

Spastic entropion.

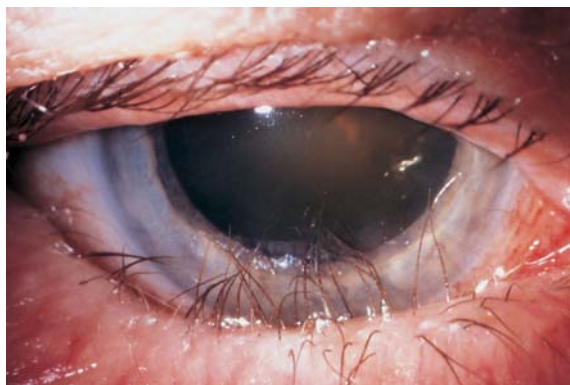

Fig. 2.7 Displaced fibers of the orbicularis oculi muscle cause the eyelashes of the lower eyelid to turn inward. Surgical intervention is indicated to correct the laxity of the lower eyelid.

- ❖ **Spastic entropion:** This affects only the lower eyelid. A combination of several pathogenetic factors of varying severity is usually involved:
- The structures supporting the lower eyelid (palpebral ligaments, tarsus, and eyelid retractor) may become lax with age, causing the tarsus to tilt inward.
 - This causes the fibers of the orbicularis oculi muscle to override the normally superior margin of the eyelid, intensifying the blepharospasm resulting from the permanent contact between the eyelashes and the eyeball.



- Senile enophthalmos, usually occurring in old age as a result of atrophy of the orbit fatty tissue, further contributes to instability of the lower eyelid.

❖ **Cicatricial entropion:** This form of entropion is frequently the result of postinfectious or post-traumatic tarsal contracture (such as trachoma; burns and chemical injuries). Causes can also include allergic and toxic reactions (pemphigus, Stevens-Johnson syndrome, and Lyell's syndrome).

Symptoms and diagnostic considerations (see also etiology): Constant rubbing of the eyelashes against the eyeball (trichiasis) represents a permanent foreign-body irritation of the conjunctiva which causes a blepharospasm (p. 93) that in turn exacerbates the entropion. The chronically irritated conjunctiva is reddened, and the eye fills with tears. Only congenital entropion is usually asymptomatic.

Treatment:

- ❖ **Congenital entropion:** To the extent that any treatment is required, it consists of measured, semicircular resection of skin and orbicularis oculi muscle tissue that can be supplemented by everting sutures where indicated.
- ❖ **Spastic entropion:** Surgical management must be tailored to the specific situation. Usually treatment combines several techniques such as shortening the eyelid horizontally combined with weakening or diverting the pre-tarsal fibers of the orbicularis oculi muscle and shortening the skin vertically.
- ❖ **Cicatricial entropion:** The surgical management of this form is identical to that of spastic entropion.



An adhesive bandage may be applied to increase tension on the eyelid for temporary relief of symptoms prior to surgery.

Prognosis and complications:



Congenital entropion is usually asymptomatic and often resolves within the first few months of life.

- ❖ **Spastic entropion:** The prognosis is favorable with prompt surgical intervention, although the disorder may recur. Left untreated, spastic entropion entails a risk of damage to the corneal epithelium with superinfection which may progress to the complete clinical syndrome of a serpiginous corneal ulcer (see p. 29).
- ❖ **Cicatricial entropion:** The prognosis is favorable with prompt surgical intervention (i.e., before any corneal changes occur).



2.4.3 Ectropion

Definition

Ectropion refers to the condition in which the margin of the eyelid is turned away from the eyeball. This condition almost exclusively affects the lower eyelid. The following forms are differentiated according to their origin (see also Etiology):

- ❖ **Congenital ectropion.**
- ❖ **Senile ectropion.**
- ❖ **Paralytic ectropion.**
- ❖ **Cicatricial ectropion.**

Epidemiology: Senile ectropion is the most prevalent form; the paralytic and cicatricial forms occur less frequently. Congenital ectropion is very rare and is usually associated with other developmental anomalies of the eyelid and face such as Franceschetti's syndrome.

Etiology:

- ❖ **Congenital ectropion:** See Epidemiology.
- ❖ **Senile ectropion:** The palpebral ligaments and tarsus may become lax with age, causing the tarsus to sag outward (Fig. 2.8).
- ❖ **Paralytic ectropion:** This is caused by facial paralysis with resulting loss of function of the orbicularis oculi muscle that closes the eyelid.
- ❖ **Cicatricial ectropion:** Like cicatricial entropion, this form is usually a sequela of infection or injury.

Senile ectropion.

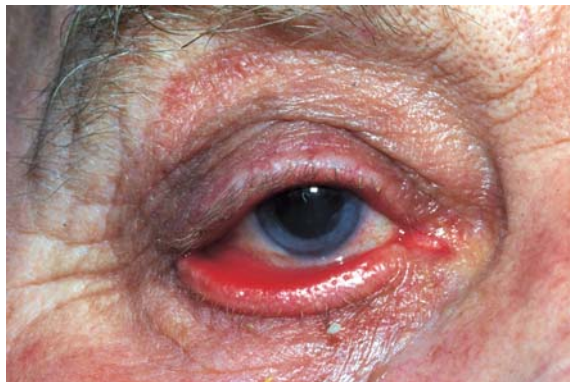


Fig. 2.8 The structures supporting the eyelid are lax, causing the lower eyelid sag outward.



Symptoms and diagnostic considerations: Left untreated, incomplete closure of the eyelids can lead to symptoms associated with desiccation of the cornea including ulceration from lagophthalmos. At the same time, the eversion of the punctum causes tears to flow down across the cheek instead of draining into the nose. Wiping away the tears increases the ectropion. This results in chronic conjunctivitis and blepharitis.

Treatment:

- ❖ **Congenital ectropion:** Surgery.
- ❖ **Senile ectropion:** Surgery is indicated. A proven procedure is to tighten the lower eyelid via a tarsal wedge resection followed by horizontal tightening of the skin.
- ❖ **Paralytic ectropion:** Depending on the severity of the disorder, artificial tear solutions, eyeglasses with an anatomic lateral protective feature, or a “watch glass” bandage (Fig. 2.9) may be sufficient to prevent desiccation of the cornea. In severe or irreversible cases, the lagophthalmos is treated surgically via a lateral tarsorrhaphy.
- ❖ **Cicatricial ectropion:** Plastic surgery is often required to correct the eyelid deformity.

Prognosis: The prognosis is favorable when the disorder is treated promptly. Sometimes several operations will be required. Surgery is more difficult where scarring is present.

Watch glass bandage for paralytic ectropion.

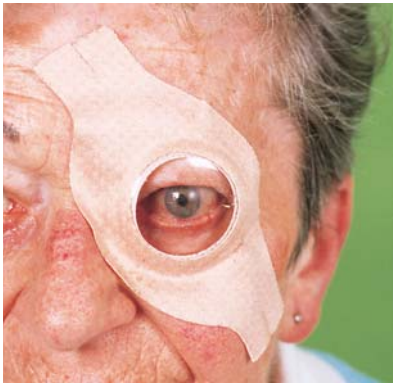

Fig. 2.9 In patients with lagophthalmos resulting from facial paralysis, a watch glass bandage creates a moist chamber that protects the cornea against desiccation.



2.4.4 Trichiasis

Trichiasis refers to the rare **postinfectious or post-traumatic inward turning of the eyelashes**. The deformity causes the eyelashes to run against the conjunctiva and cornea, causing a permanent foreign-body sensation, increased tear secretion, and chronic conjunctivitis. The eyelash follicles can be obliterated by electrolysis. The disorder may also be successfully treated by cryo-cautery epilation or surgical removal of the follicle bed.

2.4.5 Blepharospasm

Definition

This refers to an involuntary spasmodic contraction of the orbicularis oculi muscle supplied by the facial nerve.

Etiology: In addition to photosensitivity and increased tear production, blepharospasm will also accompany *inflammation or irritation of the anterior chamber*. (Photosensitivity, epiphora, and blepharospasm form a triad of reactive clinical symptoms.) Causes of the disorder include *extrapyramidal disease* such as encephalitis or multiple sclerosis. *Trigeminal neuralgia* or *psychogenic causes* may also be present.

Symptoms: Clinical symptoms include spasmodically narrowed or closed palpebral fissures and lowered eyebrows.

Treatment: This depends on the cause of the disorder. *Mild cases* can be controlled well with muscle relaxants. *Severe cases* may require transection of the fibers of the facial nerve supplying the orbicularis oculi muscle. The disorder may also be successfully treated with repeated local injections of botulinum toxin.

Prognosis: The prognosis is *good* where a *cause-related* treatment is possible. *Essential* blepharospasm *does not respond well* to treatment.

2.5 Disorders of the Skin and Margin of the Eyelid

2.5.1 Contact Eczema

Epidemiology: Light-skinned patients and patients susceptible to allergy are frequently affected.

Etiology: Contact eczema is caused by an antigen – antibody reaction in patients with intolerance to certain noxious substances. *Cosmetics, adhesive bandages, or eyedrops and eye ointments* are often responsible, particularly the *preservatives* used in them such as benzalkonium chloride.

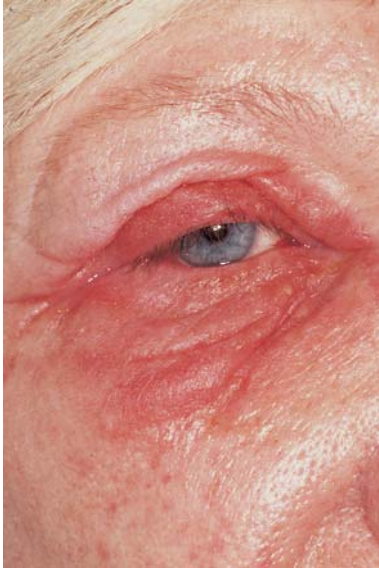
**Contact eczema.**

Fig. 2.10 This disorder is frequently caused by preservatives such as those used in eyedrops. They cause typical reddening, swelling, and lichenification of the skin of the eyelid.

Symptoms: Reddening, swelling, lichenification, and severe itching of the skin of the eyelid occur initially, followed by scaling of the indurated skin with a sensation of tension (Fig. 2.10).

Treatment: This consists of eliminating the causative agent. (Allergy testing may be necessary.) Limited use of corticosteroids usually brings quick relief of symptoms.

Prognosis: The prognosis is good if the cause can be identified.

2.5.2 Edema

Definition

This refers to swelling of the eyelid due to abnormal collection of fluid in the subcutaneous tissue.

Epidemiology: Edema is a frequently encountered clinical symptom.

Etiology: The skin of the eyelid is affected intensively by infectious and allergic processes. With the upper eyelid's relatively thin skin and the loose struc-



ture of its subcutaneous tissue, water can easily accumulate and cause edema.

Symptoms: Depending on the cause (Table 2.2), the intensity of swelling in the eyelid will vary. The location of swelling is also influenced by gravity and can vary in intensity. For example, it may be more intense in the early morning after the patient rises than in the evening (Fig. 2.11).

Fig. 2.2 Differential diagnosis of edema

Criteria	Inflammatory edema	Noninflammatory edema
Symptoms	<ul style="list-style-type: none"> ❖ Swelling ❖ Reddening ❖ Sensation of heat ❖ Painful ❖ Usually unilateral 	<ul style="list-style-type: none"> ❖ Swelling ❖ Pale skin ❖ Cool skin ❖ Painless ❖ Usually bilateral
Possible causes	<ul style="list-style-type: none"> ❖ Hordeolum (p. 38) ❖ Abscess (p. 36) ❖ Erysipelas ❖ Eczema (p. 104) ❖ Associated with: <ul style="list-style-type: none"> – paranasal sinus disorders – orbital cellulitis – dacryoadenitis – dacryocystitis 	<ul style="list-style-type: none"> ❖ Systemic disorder: <ul style="list-style-type: none"> – heart – kidneys – thyroid gland ❖ Allergy such as Quincke's edema

Edema.

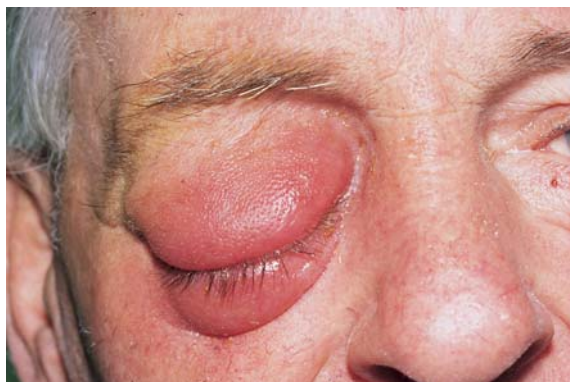

Fig. 2.11 With its relatively thin skin and its subcutaneous tissue that contains little fat, the upper eyelid is particularly susceptible to rapid fluid accumulations from pathologic processes.



Table 2.2 shows the causes and **differential diagnosis** for inflammatory and noninflammatory edemas.

Treatment: This depends on the cause of the disorder.

Clinical course and prognosis: This depends on the underlying disorder.

2.5.3 Seborrheic Blepharitis

Definition

This relatively frequent disorder is characterized by scaly inflammation of the margins of the eyelids. Usually both eyes are affected.

Etiology: There are often *several contributing causes*. The constitution of the skin, seborrhea, refractive anomalies, hypersecretion of the eyelid glands, and external stimuli such as dust, smoke, and dry air in air-conditioned rooms often contribute to persistent chronic inflammation.

Symptoms and diagnostic considerations: The margins of the eyelids usually exhibit *slight inflammatory changes* such as thickening. The eyelashes adhere due to the increased secretion from the glands of the eyelids, and *scaly deposits* form (Fig. 2.12). The disorder will often be accompanied by chronic conjunctivitis.

Treatment: This depends on the cause of the disorder (see Etiology). The scales and crusts can usually be softened with *warm olive oil* and then easily removed with a cotton-tipped applicator. In more severe cases, recom-

Seborrheic blepharitis.

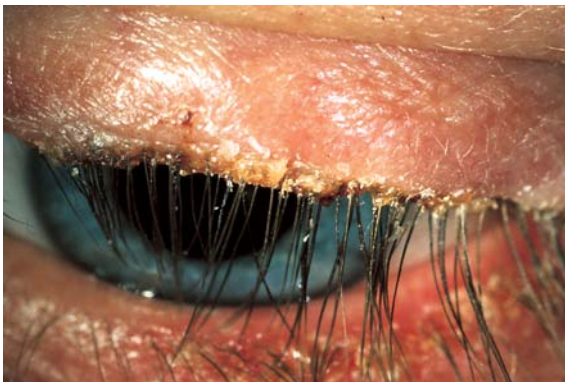

Fig. 2.12 The margins of the eyelids are slightly reddened with adhesion of the eyelashes. Scaly deposits form along the margins of the eyelids.



mended treatment includes expressing the glands of the eyelid and local application of *antibiotic ointment*. Treatment with *topical steroids* may be indicated under certain conditions.

Prognosis: The prognosis is good although the clinical course of the disorder is often quite protracted.

2.5.4 Herpes Simplex of the Eyelids

Definition

Acute, usually unilateral eyelid disorder accompanied by skin and mucous membrane vesicles.

Etiology: Infection of the skin of the eyelids results when latent herpes simplex viruses present in the tissue are activated by *ultraviolet radiation*. The virus spreads along sensory nerve fibers from the trigeminal ganglion to the surface of the skin.

Symptoms: Typical *clustered eruptions* of painful *vesicles* filled with serous fluid frequently occur at the junction of mucous membranes and skin (Fig. 2.13). Later the vesicles dry and crusts form. Lesions heal without scarring. The disorder is usually unilateral.

Treatment: Topical use of virostatic agents is indicated. The patient should avoid intense ultraviolet radiation as a prophylactic measure against recurrence.

Prognosis: The prognosis is good, although the disorder frequently recurs.

Herpes simplex of the eyelids.

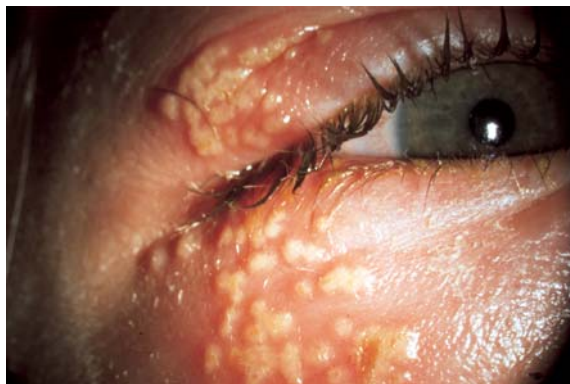

Fig. 2.13 Painful vesicles filled with serous fluid erupt in clusters at the angle of the eye.



2.5.5 Herpes Zoster Ophthalmicus

Definition

Facial rash caused by the varicella-zoster virus.

Epidemiology: The disorder usually affects immunocompromised persons between the ages of 40 and 60 who have underlying disorders.

Etiology: The disorder is caused by the varicella-zoster virus, which initially manifests itself as chickenpox. If activation or reinfection occurs, the latent neurotropic viruses present in the body can lead to the clinical syndrome of herpes zoster ophthalmicus (Fig. 2.14).

Symptoms: The incubation period is 7–18 days, after which *severe pain* occurs in the area supplied by the first branch of the trigeminal nerve (the ophthalmic nerve with its frontal, lacrimal, and nasociliary branches). *Prodromal symptoms* of erythema, swelling, photosensitivity, and lacrimation may occur before the characteristic *clear watery vesicles* appear. The vesicles burst and brownish scabs form, which are later shed. *Blepharitis* (see p. 33) is also present in 50–70% of all cases. As herpes zoster usually affects immunocom-

Herpes zoster ophthalmicus.

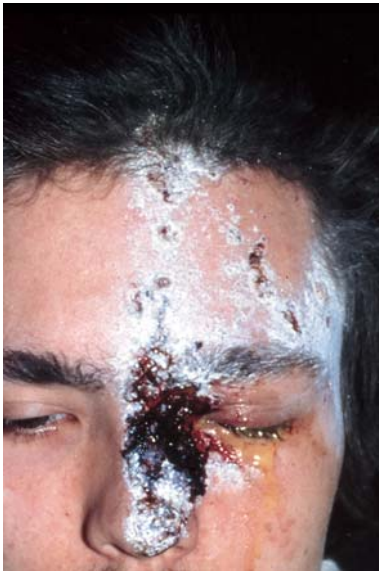

Fig. 2.14 The facial rash of herpes zoster is caused by the neurotropic varicella-zoster virus. After the clear watery vesicles burst, brownish scabs form, which are later shed.



promised persons, the patient should be examined for a possible underlying disorder.

! The skin sensitivity at the tip of the nose should be evaluated on both sides in the initial stage of the disorder. Decreased sensitivity to touch suggests involvement of the nasociliary branch of the ophthalmic nerve, which can lead to severe intraocular inflammation.

Treatment: This includes topical virostatic agents and systemic acyclovir.

Complications: Involvement of the nasociliary branch of the ophthalmic nerve can lead to severe intraocular inflammation.

Prognosis: The skin lesions heal within three to four weeks; scars may remain. Often neuralgiform pain and hypesthesia may persist.

2.5.6 Eyelid Abscess

Definition

Circumscribed collection of pus with severe inflammation, swelling, and subsequent fluctuation.

Etiology: An abscess of the upper or lower eyelid can form as a sequela of minor trauma, insect sting, or spread of inflammation from the paranasal sinuses.

Symptoms: The severe inflammation and swelling often make it impossible actively to open the eye (Fig. 2.15). The contents of the abscess can fluctuate

Eyelid abscess.

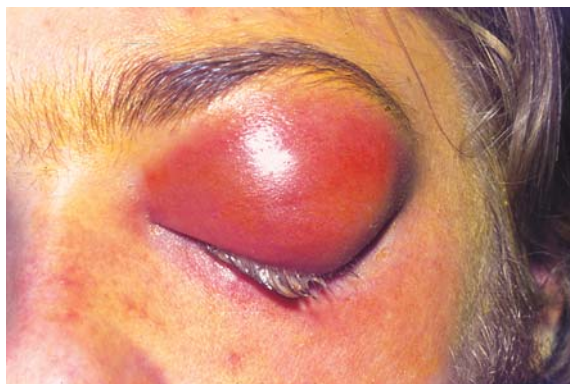

Fig. 2.15 Severe inflammation and swelling make it impossible actively to open the eye.



during the clinical course of the disorder. Spontaneous perforation with pus drainage can occur.

Treatment: Oral or intravenous antibiotics and dry heat are indicated. A stab incision can relieve tension at the onset of fluctuation.

Prognosis: The prognosis is generally good.



Orbital cellulitis or cavernous sinus thrombosis can occasionally occur as a sequela of eyelid abscess, especially when located at the medial angle of the eye. This represents a life-threatening complication.

2.5.7 Tick Infestation of the Eyelids

Ticks have been known to infest the eyelids. They are thought to be vectors of borreliosis and can cause encephalitis. Treatment consists of mechanical removal of the parasites.

2.5.8 Louse Infestation of the Eyelids

This refers to **infestation of the margin of the eyelid with crab lice** as a result of poor hygienic conditions. The small oval nits frequently hang from the eyelashes (Fig. 2.16), causing inflammation of the margin of the eyelid with severe itching. *Mechanical removal with forceps* is a time consuming but effective treatment. *Application of a 2% mercury precipitate ointment* over an extended period of time is also effective.

Louse infestation of the eyelids.

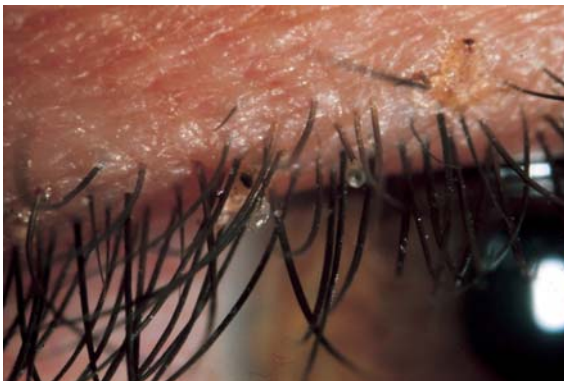

Fig. 2.16 Under poor hygienic conditions, crab lice can infest the bases of the eyelashes.



2.6 Disorders of the Eyelid Glands

2.6.1 Hordeolum

Definition

A **hordeolum** is the result of an acute bacterial infection of one or more *eyelid glands*.

Epidemiology and etiology: *Staphylococcus aureus* is a common cause of hordeolum. **External hordeolum** involves infection of the glands of Zeis or Moll. **Internal hordeolum** arises from infection of the meibomian glands. Hordeolum is often associated with diabetes, gastrointestinal disorders, or acne.

Symptoms and diagnostic considerations: Hordeolum presents as *painful nodules with a central core of pus*. **External hordeolum** appears on the *margin of the eyelid* where the sweat glands are located (Fig. 2.17). **Internal hordeolum** of a sebaceous gland is usually *only revealed by everting the eyelid* and usually accompanied by a more severe reaction such as conjunctivitis or chemosis of the bulbar conjunctiva. Pseudoptosis and swelling of the preauricular lymph nodes may also occur.

Differential diagnosis: Chalazion (tender to palpation) and inflammation of the lacrimal glands (rarer and more painful).

Treatment: Antibiotic ointments and application of dry heat (red heat lamp) will rapidly heal the lesion.

External hordeolum.

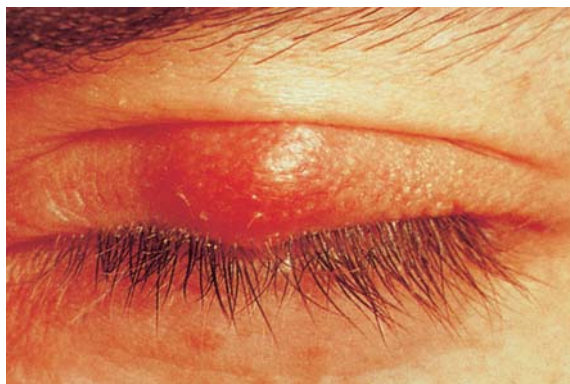

Fig. 2.17 The painful inflamed hordeolum is usually caused by *Staphylococcus aureus* infection of an eyelid gland.



Clinical course and prognosis: After eruption and drainage of the pus, the symptoms will rapidly disappear. The prognosis is good. An underlying internal disorder should be excluded in cases in which the disorder frequently recurs.

2.6.2 Chalazion

Definition

Firm nodular bulb within the tarsus.

Epidemiology and etiology: Chalazia occur relatively frequently and are caused by a chronic granulomatous inflammation due to buildup of secretion from the meibomian gland.

Symptoms: The firm painless nodule develops very slowly. Aside from the cosmetic flaw, it is usually asymptomatic (Fig. 2.18).

Differential diagnosis: Hordeolum (tender to palpation) and adenocarcinoma.

Treatment: Surgical incision is usually unavoidable (Fig. 2.19).



After introducing the chalazion clamp, the lesion is incised either medially, perpendicular to the margin of the eyelid, or laterally, perpendicular to the margin of the eyelid (this is important to avoid cicatricial ectropion). The fatty contents are then removed with a curet.

Prognosis: Good except for the chance of local recurrence.

Chalazion.

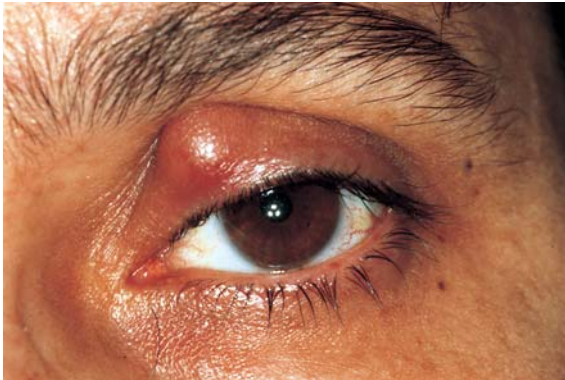

Fig. 2.18 Painful to palpation, the chalazion is caused by a chronic buildup of secretion from the meibomian glands.



Surgical removal of a chalazion.

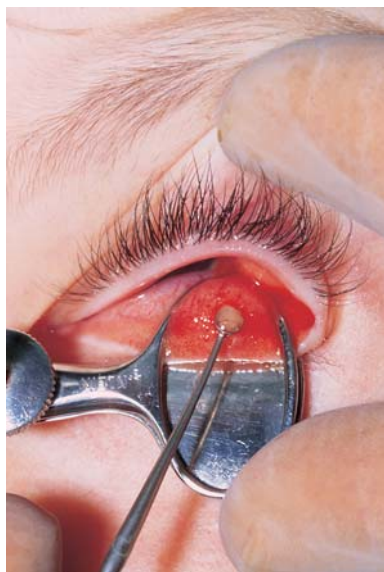

Fig. 2.19 After the chalazion clamp has been introduced and the lesion incised with a scalpel, the fatty contents are removed with a curet.

2.7 Tumors

2.7.1 Benign Tumors

2.7.1.1 Ductal Cysts

The **round cysts** of the glands or Moll are **usually located in the angle of the eye**. Their contents are clear and watery and can be transilluminated. Gravity can result in ectropion (Fig. 2.20). *Therapy* consists of marsupialization. The *prognosis* is good.

2.7.1.2 Xanthelasma

Definition

Local fat metabolism disorder that produces lipoprotein deposits. These are usually bilateral in the medial canthus.

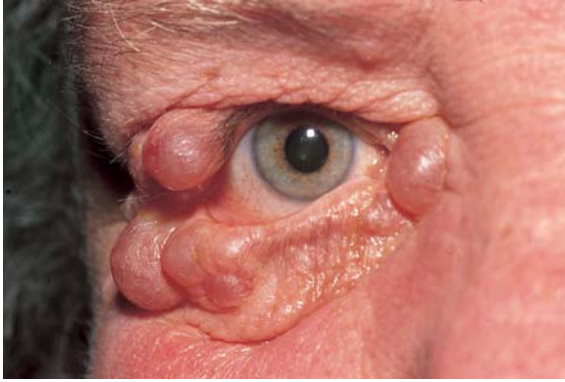**Ductal cyst.**

Fig. 2.20 The round cysts of the glands of Moll are usually located in the angle of the eye. The weight causes temporary ectropion.

Epidemiology: Postmenopausal women are most frequently affected. A higher incidence has also been observed in patients with diabetes, increased levels of plasma lipoprotein, or bile duct disorders.

Symptoms: The soft yellow white plaques are sharply demarcated. They are usually bilateral and distributed symmetrically (Fig. 2.21). Aside from the cosmetic flaw, the patients are asymptomatic.

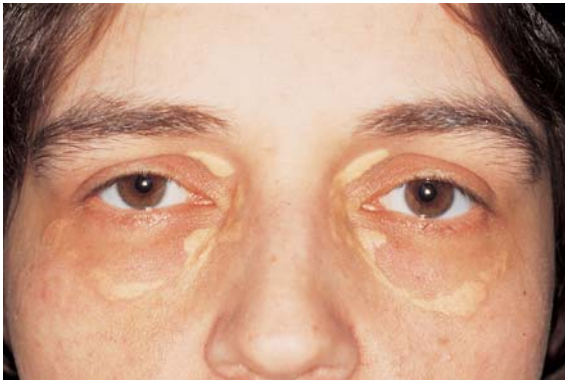Xanthelasma.

Fig. 2.21 The fatty deposits are often symmetrically distributed in the medial canthus.



Treatment and prognosis: The plaques can only be removed surgically. The incidence of recurrence is high.

2.7.1.3 Molluscum Contagiosum

The **noninflammatory contagious infection** is caused by DNA viruses. The disease usually affects *children and teenagers* and is transmitted by direct contact. The *pinhead-sized lesions have typical central depressions* and are scattered near the upper and lower eyelids (Fig. 2.22). These lesions are removed with a curet. (In children this is done under short-acting anesthesia.)

2.7.1.4 Cutaneous Horn

The **yellowish brown cutaneous protrusions** consist of keratin (Fig. 2.23). Older patients are more frequently affected. The cutaneous horn should be surgically removed as 25% of keratosis cases can develop into *malignant squamous cell carcinomas* years later.

2.7.1.5 Keratoacanthoma

A rapidly growing **tumor with a central keratin mass that opens on the skin surface**, which can sometimes be expressed (Fig. 2.24). The tumor may resolve spontaneously, forming a small sunken scar.

Differential diagnosis should exclude a *basal cell carcinoma* (see that section); the margin of a keratoacanthoma is characteristically avascular. Likewise, a *squamous cell carcinoma* can only be excluded by a biopsy.

Molluscum contagiosum.

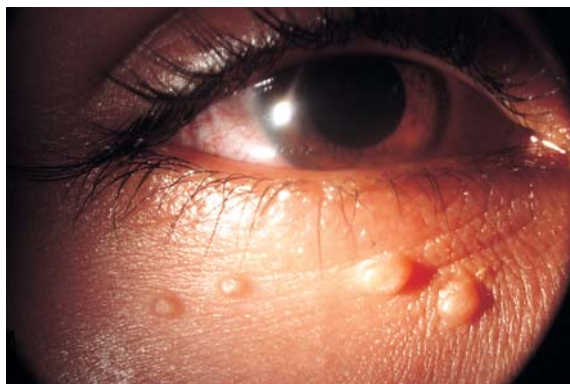

Fig. 2.22 The pinhead-sized molluscum lesions have typical central depressions.



Cutaneous Horn.

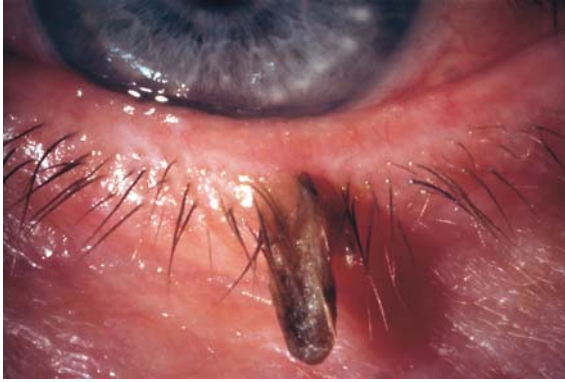

Fig. 2.23 The yellowish brown cutaneous protrusions consist of keratin. They frequently (25% of all cases) develop into a malignant squamous cell carcinoma in later years if they are not surgically removed.

Keratoacanthoma.

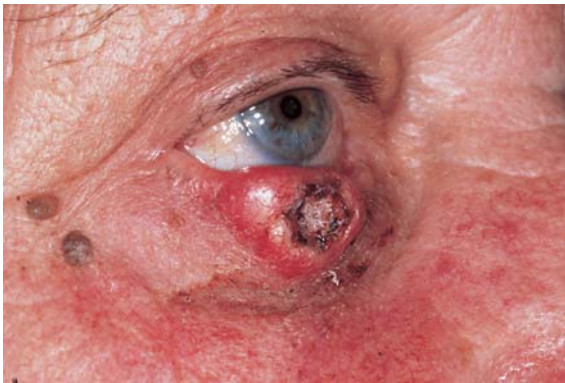


Fig. 2.24 The rapidly growing benign tumor has a central keratin mass that opens on the skin surface.

2.7.1.6 Hemangioma

Definition

Congenital benign vascular anomaly resembling a neoplasm that is most frequently noticed in the skin and subcutaneous tissues.

Epidemiology: Girls are most often affected (approximately 70% of all cases). Facial lesions most commonly occur in the eyelids (Fig. 2.25).



Cavernous hemangioma.

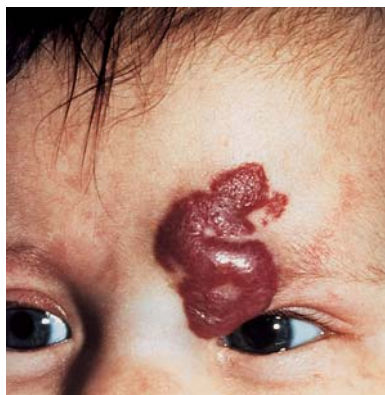

Fig. 2.25 The congenital vascular anomaly occurs as a facial lesion most commonly occur in the eyelids. The lesion regresses spontaneously in approximately 70% of all cases.

Symptoms: Hemangiomas include capillary or superficial, cavernous, and deep forms.

Diagnostic considerations: Hemangiomas can be compressed, and the skin will then appear white.

Differential diagnosis: *Nevus flammeus:* This is characterized by a sharply demarcated bluish red mark (“port-wine” stain) resulting from vascular expansion under the epidermis (not a growth or tumor).

Treatment: A watch-and-wait approach is justified in light of the high rate of *spontaneous remission* (approximately 70%). Where there is increased *risk of amblyopia* due to the size of the lesion, cryotherapy, intralesional steroid injections, or radiation therapy can accelerate regression of the hemangioma.

Prognosis: Generally good.

2.7.1.7 Neurofibromatosis (Recklinghausen’s Disease)

Definition

A congenital developmental defect of the neuroectoderm gives rise to neural tumors and pigment spots (*café au lait spots*).

Neurofibromatosis is regarded as a *phacomatosis* (a developmental disorder involving the simultaneous presence of changes in the skin, central nervous system, and ectodermal portions of the eye).



Neurofibroma.

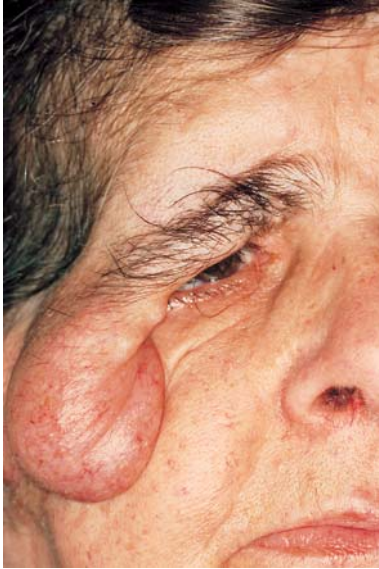

Fig. 2.26 Larger fibromas can lead to elephantiasis of the eyelids.

Symptoms and diagnostic considerations: The numerous tumors are soft, broad-based, or pediculate, and occur either in the skin or in subcutaneous tissue, usually in the vicinity of the upper eyelid.

They can reach monstrous proportions and present as *elephantiasis of the eyelids* (Fig. 2.26).

Treatment: Smaller fibromas can be easily removed by surgery. Larger tumors always entail a risk of postoperative bleeding and recurrence. On the whole, treatment is *difficult*.

2.7.2 Malignant Tumors

2.7.2.1 Basal Cell Carcinoma

Definition

Basal cell carcinoma is a frequent, moderately malignant, fibroepithelial tumor that can cause severe local tissue destruction but very rarely metastasizes.



Epidemiology: Approximately 90% of all malignant eyelid tumors are basal cell carcinomas. Their incidence increases with age. In approximately 60% of all cases they are localized on the *lower eyelid*. Morbidity in sunny countries is 110 cases per 100 000 persons (in central Europe approximately 20 per 100 000 persons). *Dark-skinned people are affected significantly less often*. Gender is not a predisposing factor.

Etiology: Causes of basal cell carcinoma may include a genetic disposition. *Increased exposure to the sun's ultraviolet radiation, carcinogenic substances (such as arsenic), and chronic skin damage* can also lead to an increased incidence. Basal cell carcinomas arise from the basal cell layers of the epidermis and the sebaceous gland hair follicles, where their growth locally destroys tissue.

Symptoms: Typical characteristics include a firm, slightly raised margin (*a halo resembling a string of beads*) with a *central crater* and *superficial vascularization* with an increased tendency to bleed (Fig. 2.27).

Ulceration with “gnawing” peripheral proliferation is occasionally referred to as an *ulcus rodens*; an *ulcus terebans* refers to deep infiltration with invasion of cartilage and bone.

Diagnostic considerations: The diagnosis can very often be made on the basis of clinical evidence. A biopsy is indicated if there is any doubt.



Loss of the eyelashes in the vicinity of the tumor always suggests malignancy.

Treatment: The lesion is treated by surgical excision within a margin of healthy tissue. This is the safest method. If a radical procedure is not feasible,

Basal cell carcinoma.

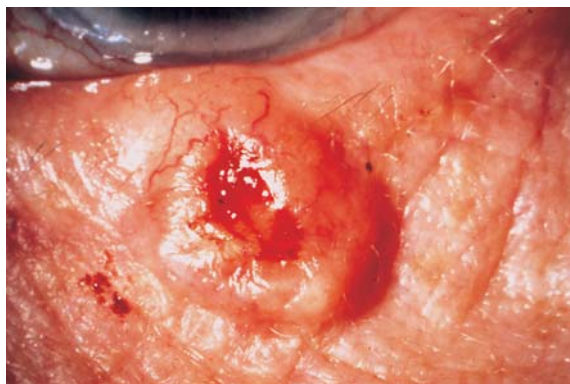


Fig. 2.27 A halo resembling a string of beads, superficial vascularization, and a central crater with a tendency to bleed are characteristic signs of this moderately malignant tumor.



the only remaining options are radiation therapy or cryotherapy with liquid nitrogen.

Prognosis: The changes of successful treatment by surgical excision are very good. Frequent follow-up examinations are indicated.



The earlier a basal cell carcinoma is detected, the easier it is to remove.

2.7.2.2 Squamous Cell Carcinoma

This is the *second most frequently encountered* malignant eyelid tumor. The carcinoma arises from the epidermis, grows rapidly and destroys tissue. It can metastasize into the regional lymph nodes. Remote metastases are rarer. The *treatment of choice* is complete surgical removal.

2.7.2.3 Adenocarcinoma

The *rare* adenocarcinoma arises from the meibomian glands or the glands of Zeis. The **firm, painless swelling** is usually located in the **upper eyelid** and is mobile with respect to the skin but not with respect to the underlying tissue. In its early stages it can be *mistaken easily for a chalazion* (see p. 39). The lesion can metastasize into local lymph nodes.

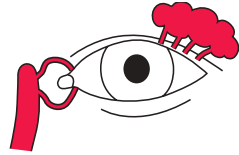


An apparent chalazion that cannot be removed by the usual surgical procedure always suggests a suspected adenocarcinoma.

The *treatment of choice* is complete surgical removal.

3 Lacrimal System

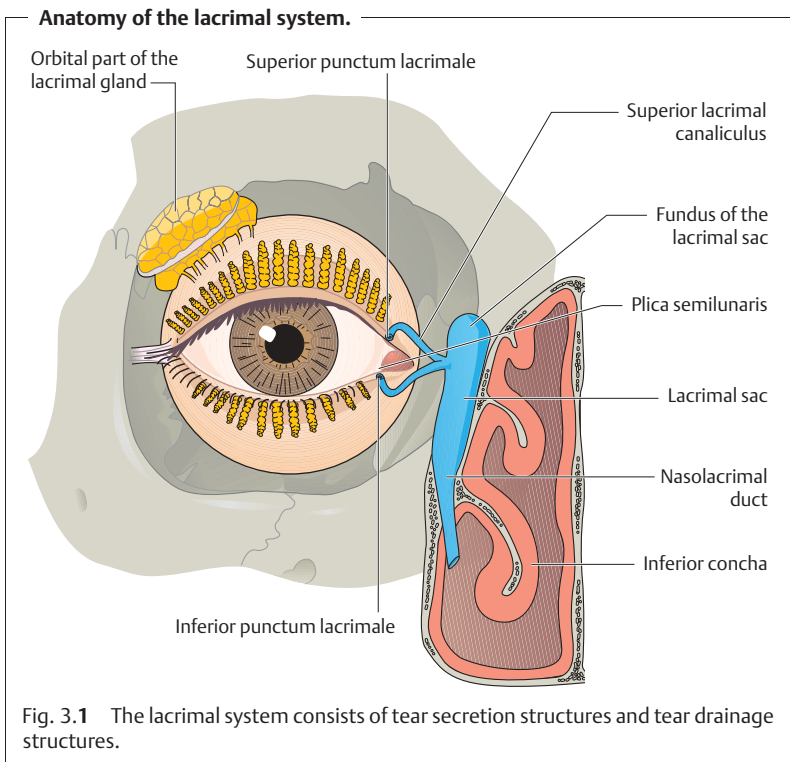
Peter Wagner and Gerhard K. Lang



3.1 Basic Knowledge

The lacrimal system (Fig. 3.1) consists of two sections:

- ❖ Structures that secrete tear fluid.
- ❖ Structures that facilitate tear drainage.



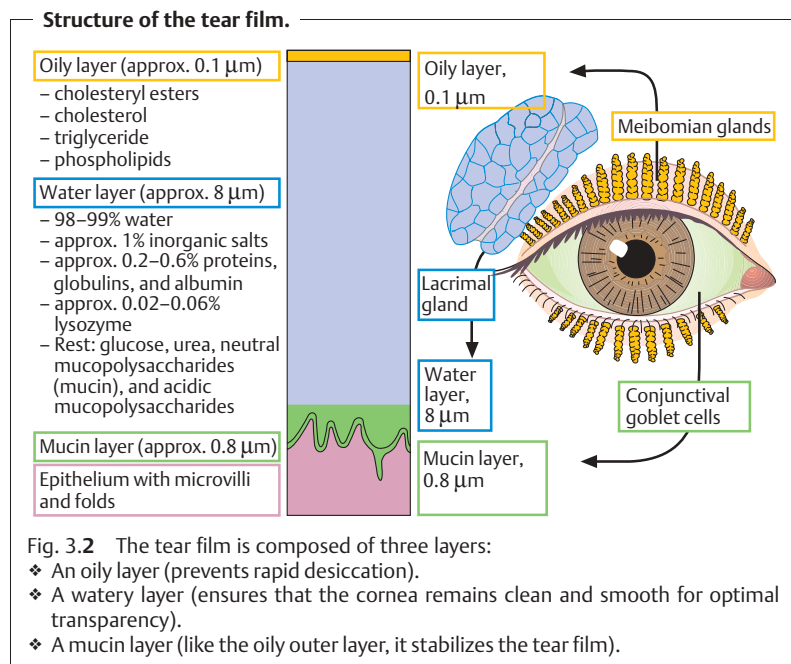


Position, structure, and nerve supply of the lacrimal gland: The **lacrimal gland** is about the **size of a walnut**; it lies beneath the superior temporal margin of the orbital bone in the lacrimal fossa of the frontal bone and is *neither visible nor palpable*. A palpable lacrimal gland is usually a sign of a pathologic change such as dacryoadenitis. The tendon of the levator palpebrae muscle divides the lacrimal gland into a *larger orbital part* (two-thirds) and a *smaller palpebral part* (one-third). Several tiny **accessory lacrimal glands (glands of Krause and Wolfring)** located in the superior fornix secrete additional serous tear fluid.

The lacrimal gland receives its **sensory supply** from the *lacrimal nerve*. Its parasympathetic secretomotor nerve supply comes from the *nervus intermedius*. The sympathetic fibers arise from the superior cervical sympathetic ganglion and follow the course of the blood vessels to the gland.

Tear film: The tear film (Fig. 3.2) that moistens the conjunctiva and cornea is composed of **three layers**:

1. The **outer oily layer** (approximately $0.1\ \mu\text{m}$ thick) is a product of the *meibomian glands* and the *sebaceous glands and sweat glands of the margin of*





the eyelid. The primary function of this layer is to stabilize the tear film. With its hydrophobic properties, it prevents rapid evaporation like a layer of wax.

2. The **middle watery layer** (approximately $8\ \mu\text{m}$ thick) is produced by the *lacrimal gland* and the *accessory lacrimal glands* (glands of Krause and Wolfring). Its task is to clean the surface of the cornea and ensure mobility of the palpebral conjunctiva over the cornea and a smooth corneal surface for high-quality optical images.
3. The **inner mucin layer** (approximately $0.8\ \mu\text{m}$ thick) is secreted by the *goblet cells of the conjunctiva* and the *lacrimal gland*. It is hydrophilic with respect to the microvilli of the corneal epithelium, which also helps to stabilize the tear film. This layer prevents the watery layer from forming beads on the cornea and ensures that the *watery layer moistens the entire surface of the cornea and conjunctiva*.

Lysozyme, beta-lysin, lactoferrin, and gamma globulin (IgA) are **tear-specific proteins** that give the tear fluid *antimicrobial characteristics*.

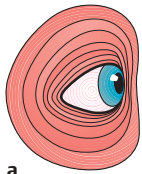
Tear drainage: The shingle-like arrangement of the **fibers of the orbicularis oculi muscle** (supplied by the facial nerve) causes the eye to close progressively from lateral to medial instead of the eyelids simultaneously closing along their entire length. This *windshield wiper motion* moves the tear fluid medially across the eye toward the medial canthus (Figs. 3.3 a–c).

The **superior and inferior puncta lacrimales** collect the tears, which then drain through the superior and inferior **lacrimal canaliculi** into the **lacrimal sac**. From there they pass through the **nasolacrimal duct** into the **inferior concha** (see Fig. 3.1).

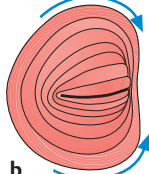
Combined function of the orbicularis oculi muscle and the lower lacrimal system.

Opening the eye
Levator palpebrae
superioris muscle
(oculomotor nerve)

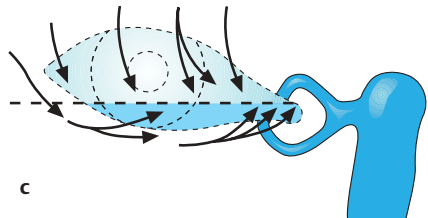
Closing the eye
Orbicularis oculi
muscle (facial
nerve)



a



b



c

Figs. 3.3 a–c As the eyelids close, they act like a windshield wiper to move the tear fluid medially across the eye toward the puncta and lacrimal canaliculi.



3.2 Examination Methods

3.2.1 Evaluation of Tear Formation

Schirmer tear testing: This test (Fig. 3.4) provides information on the **quantity of watery component in tear secretion.**

- ❖ *Test:* A strip of litmus paper is inserted into the conjunctival sac of the temporal third of the lower eyelid.
- ❖ *Normal:* After about five minutes, at least 15 mm of the paper should turn blue due to the alkaline tear fluid.
- ❖ *Abnormal:* Values less than 5 mm are abnormal (although they will not necessarily be associated with clinical symptoms).

The same method is used after application of a topical anesthetic to **evaluate normal secretion without irritating the conjunctiva.**

Tear break-up time (TBUT): This test evaluates the **stability of the tear film.**

- ❖ *Test:* Fluorescein dye (10 μ l of a 0.125% fluorescein solution) is added to the precorneal tear film. The examiner observes the eye under 10–20 power magnification with slit lamp and cobalt blue filter and notes when the first signs of drying occur (i) *without the patient closing the eye* and (ii) *with the patient keeping the eye open as he or she would normally.*
- ❖ *Normal:* TBUT of *at least 10 seconds* is normal.

Rose bengal test: Rose bengal **dyes dead epithelial cells and mucin.** This test has proven particularly useful in evaluating *dry eyes* (keratoconjunctivitis sicca) as it reveals conjunctival and corneal symptoms of desiccation.

Measuring tear secretion with Schirmer tear testing.

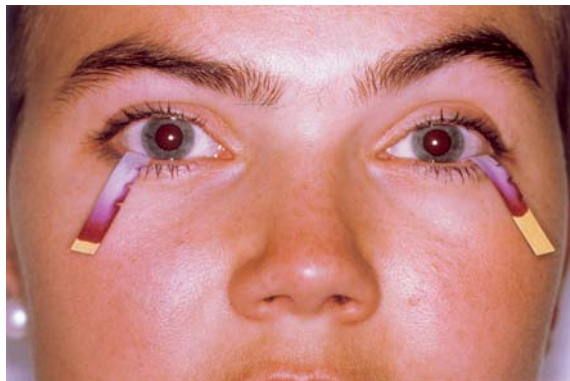

Fig. 3.4 A strip of litmus paper is folded over and inserted into the conjunctival sac of the temporal third of the lower eyelid. Normally, at least 15 mm of the paper should turn blue within five minutes.



Impression cytology: A Millipore filter is fastened to a tonometer and pressed against the superior conjunctiva with 20–30 mm Hg of pressure for two seconds. The **density of goblet cells** is estimated under a microscope (*normal density* is 20–45 goblet cells per square millimeter of epithelial surface). The number of mucus-producing goblet cells is reduced in various disorders such as keratoconjunctivitis sicca, ocular pemphigoid, and xerophthalmia.

3.2.2 Evaluation of Tear Drainage

Conjunctival fluorescein dye test: Normal **tear drainage** can be demonstrated by having the patient blow his or her nose into a facial tissue following application of a 2% fluorescein sodium solution to the inferior fornix.

Probing and irrigation: These examination methods are used to **locate stenoses**. After application of a topical anesthetic, a conical probe is used to dilate the punctum. Then the lower lacrimal system is flushed with a physiologic saline solution introduced through a blunt cannula (Figs. 3.5 a and b). If the passage is *unobstructed*, the solution will drain freely into the nose.



Canalicular stenosis will result in reflux through the irrigated punctum. If the stenosis is deeper, reflux will occur through the opposite punctum (Fig. 3.6).

A probe can be used to determine the site of the stricture, and possibly to eliminate obstructions (Fig. 3.7).

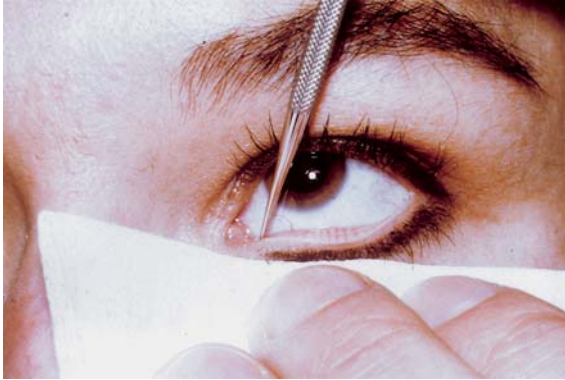
Radiographic contrast studies: Radiographic contrast medium is instilled in the same manner as the saline solution. These studies demonstrate the **shape, position, and size** of the passage and possible **obstructions to drainage**.

Digital subtraction dacrycystography: These studies demonstrate only the contrast medium and image the lower lacrimal system without superimposed bony structures. They are particularly useful as **preoperative diagnostic studies** (Fig. 3.8).

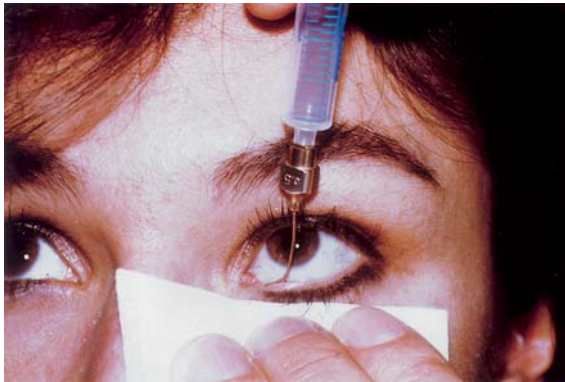Lacrimal endoscopy: Fine endoscopes now permit **direct visualization of the mucous membrane of the lower lacrimal system**. Until recently, endoscopic examination of the lower lacrimal system was not a routine procedure.



Irrigation of the lower lacrimal system under topical anesthesia.



a

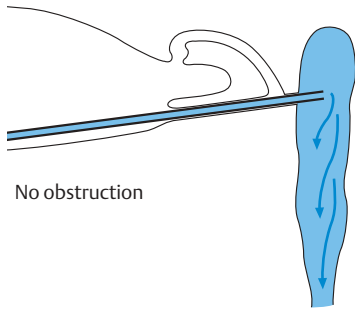


b

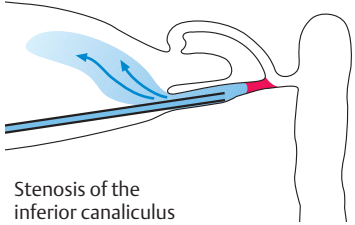
Figs. 3.5 a and b
First the punctum is dilated by rotating a conical probe. Then the lacrimal passage is flushed with a physiologic saline solution. The examiner should be particularly alert to good drainage or possible reflux.



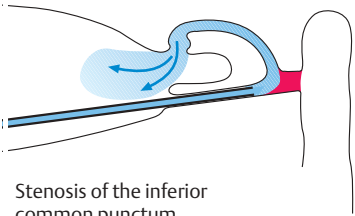
Localizing an obstruction by irrigating the lower lacrimal system.



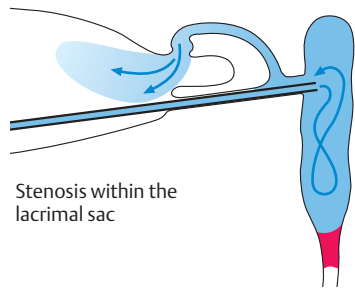
No obstruction



Stenosis of the inferior canaliculus



Stenosis of the inferior common punctum

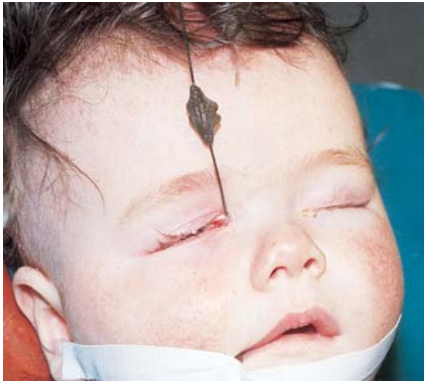

Stenosis within the lacrimal sac

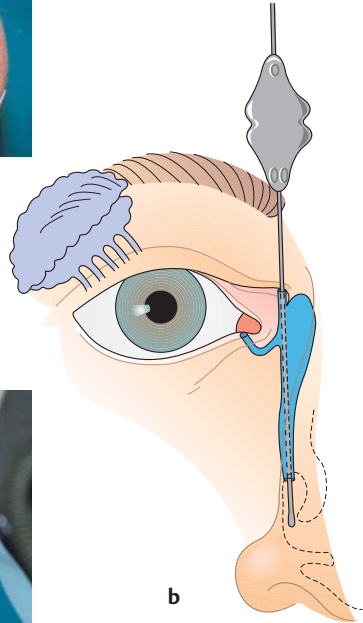
Fig. 3.6 The lower lacrimal system should be irrigated with care by an experienced ophthalmologist. Failure to locate the passage will inflate the eyelid and provide no diagnostic information.



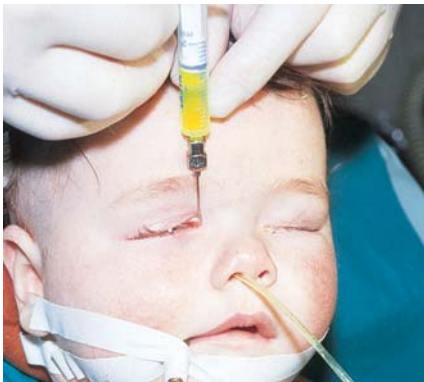Opening a stenosis of the lower lacrimal system with a probe.



a



b



c

Figs. 3.7a–c After application of a topical anesthetic, the probe is carefully introduced into the lower lacrimal system. The puncta are dilated and then the valve of Hasner is opened (a and b). A dye solution can then be introduced to verify patency of the lower lacrimal system (c). In infants six months or older, the procedure is best performed under short-acting general anesthesia.



Radiographic image of the lower lacrimal system.

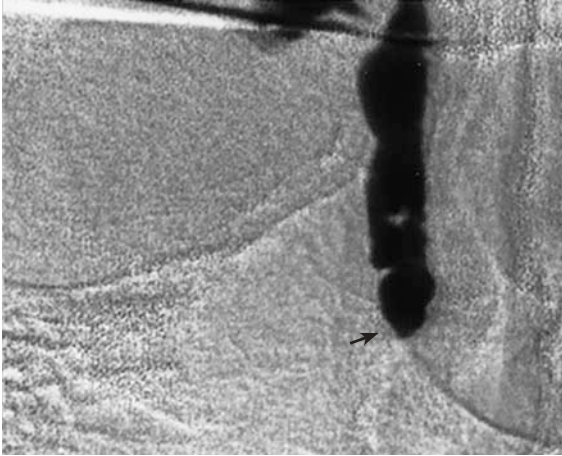


Fig. 3.8 Digital subtraction dacryocystography images the lower lacrimal system and can demonstrate a possible stenosis (arrow) without superimposed bony structures.

3.3 Disorders of the Lower Lacrimal System

3.3.1 Dacryocystitis

Inflammation of the lacrimal sac is the *most frequent* disorder of the lower lacrimal system. It is usually the result of obstruction of the nasolacrimal duct and is *unilateral in most cases*.

3.3.1.1 Acute Dacryocystitis

Epidemiology: The disorder most frequently affects adults between the ages of 50 and 60.

Etiology: The cause is usually a *stenosis within the lacrimal sac*. The retention of tear fluid leads to infection from staphylococci, pneumococci, *Pseudomonas*, or other pathogens.

Symptoms: Clinical symptoms include highly inflamed, painful *swelling in the vicinity of the lacrimal sac* (Fig. 3.9) that may be accompanied by *malaise, fever, and involvement of the regional lymph nodes*. The pain may be referred as far as the forehead and teeth. An *abscess in the lacrimal sac* may form in advanced disorders; it can spontaneously rupture the skin and form a *draining fistula*.



Acute dacryocystitis.

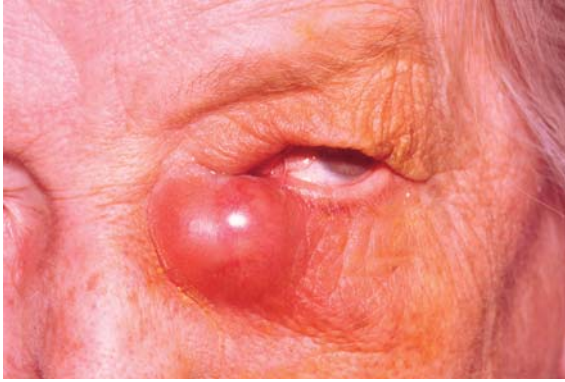

Fig. 3.9 Typical symptoms include highly inflamed, painful swelling in the vicinity of the lacrimal sac.



Acute inflammation that has spread to the surrounding tissue of the eyelids and cheek entails a risk of sepsis and cavernous sinus thrombosis, which is a life-threatening complication.

Diagnostic considerations: Radiographic contrast studies or digital subtraction dacryocystography can visualize the obstruction for preoperative planning. These studies should be avoided during the acute phase of the disorder because of the risk of pathogen dissemination.

Differential diagnosis:

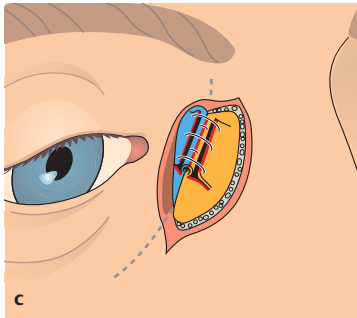
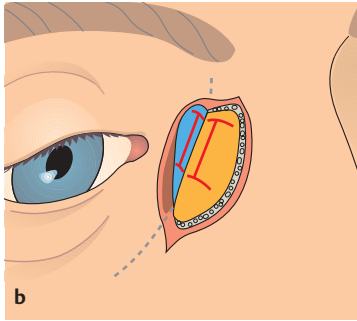
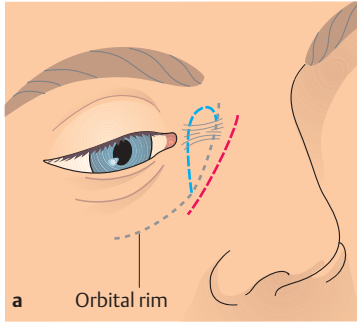
- ❖ Hordeolum (small, circumscribed, nonmobile inflamed swelling).
- ❖ Orbital cellulitis (usually associated with reduced motility of the eyeball).

Treatment: **Acute cases** are treated with *local and systemic antibiotics* according to the specific pathogens detected. *Disinfectant compresses* (such as a 1 : 1000 Rivanol solution) can also positively influence the clinical course of the disorder. Pus from a *fluctuating abscess* is best drained through a *stab incision* following cryoanesthesia with a refrigerant spray.

Treatment after **acute symptoms have subsided** often requires surgery (dacryocystorhinostomy; Figs. 3.10a–c) to achieve persistent relief. Also known as a lower system bypass, this operation involves opening the lateral wall of the nose and bypassing the nasolacrimal duct to create a direct connection between the lacrimal sac and the nasal mucosa.



Dacryocystorhinostomy.



Figs. 3.10a–c A skin incision is made, and the orbital rim is exposed. Then a window is opened to expose the nasal mucosa. The nasal mucosa and the lacrimal sac are both incised in an H-shape and door-like flaps are raised. The anterior and posterior mucosal flaps are then sutured together. This creates a new drainage route for the tear fluid that bypasses the nasolacrimal duct.



3.3.1.2 Chronic Dacryocystitis

Etiology: Obstruction of the nasolacrimal duct is often secondary to chronic inflammation of the connective tissue or nasal mucosa.

Symptoms and diagnostic considerations: The *initial characteristic* of chronic dacryocystitis is *increased lacrimation*. Signs of inflammation are not usually present. Applying pressure to the inflamed lacrimal sac causes *large quantities of transparent mucoid pus* to regurgitate through the punctum.



Chronic inflammation of the lacrimal sac can lead to a serpiginous corneal ulcer.

Treatment: Surgical intervention is the only effective treatment in the vast majority of cases. This involves either a dacryocystorhinostomy (creation of a direct connection between the lacrimal sac and the nasal mucosa; see Figs. 3.10a–c) or removal of the lacrimal sac.

3.3.1.3 Neonatal Dacryocystitis

Etiology: Approximately 6% of newborns have a stenosis of the mouth of the nasolacrimal duct due to a *persistent mucosal fold* (lacrimal fold or valve of Hasner). The resulting retention of tear fluid provides ideal growth conditions for bacteria, particularly staphylococci, streptococci, and pneumococci.

Symptoms and diagnostic considerations: Shortly after birth (usually within two to four weeks), *pus is secreted from the puncta*. The disease continues subcutaneously and pus collects in the palpebral fissure. The *conjunctiva is not usually involved*.

Differential diagnosis:

- ❖ Gonococcal conjunctivitis and inclusion conjunctivitis (see Fig. 4.3).
- ❖ Silver catarrh (harmless conjunctivitis with slimy mucosal secretion following Credé's method of prophylaxis with silver nitrate).

Treatment: **During the first few weeks**, the infant should be monitored for *spontaneous opening of the stenosis*. During this period, *antibiotic and anti-inflammatory eyedrops and nose drops* (such as erythromycin and xylometazoline 0.5% for infants) are administered.

If symptoms persist, *irrigation* or *probing* under short-acting general anesthesia may be indicated (see Figs. 3.7a–c).



Often massaging the region several times daily while carefully applying pressure to the lacrimal sac will be sufficient to open the valve of Hasner and eliminate the obstruction.



3.3.2 Canaliculitis

Definition

This usually involves *inflammation of the canaliculus*.

Epidemiology and etiology: *Genuine canaliculitis is rare. Usually a stricture will be present and the actual inflammation proceeds from the conjunctiva. Actinomycetes (fungoid bacteria) often cause persistent purulent granular concretions that are difficult to express.*

Symptoms and diagnostic considerations: The canaliculus region is swollen, reddened, and often tender to palpation. Pus or granular concretions can be expressed.

Treatment: The disorder is treated with antibiotic eyedrops and ointments according to the specific pathogens detected in cytologic smears. Successful treatment occasionally requires surgical incision of the canaliculus.

3.3.3 Tumors of the Lacrimal Sac

Epidemiology: Tumors of the lacrimal sac are *rare* but are *primarily malignant* when they do occur. They include papillomas, carcinomas, and sarcomas.

Symptoms and diagnostic considerations: Usually the tumors cause unilateral painless swelling followed by dacryostenosis.

Diagnostic considerations: The irregular and occasionally bizarre form of the structure in radiographic contrast studies is typical. Ultrasound, CT, MRI, and biopsy all contribute to confirming the diagnosis.

Differential diagnosis: Chronic dacryocystitis (see above), mucocele of the ethmoid cells.

Treatment: The entire tumor should be removed.



3.4 Lacrimal System Dysfunction

3.4.1 Keratoconjunctivitis Sicca

Definition

Noninfectious keratopathy characterized by reduced moistening of the conjunctiva and cornea (dry eyes).

Epidemiology: Keratoconjunctivitis sicca as a result of dry eyes is one of the most common eye problems between the ages of 40 and 50. As a result of hormonal changes in menopause, *women are far more frequently affected* (86%) than *men*. There are also indications that keratoconjunctivitis sicca is more prevalent in regions with higher levels of environmental pollution.

Etiology: Keratoconjunctivitis sicca results from dry eyes, which may be due to one of two causes:

- ❖ **Reduced tear production** associated with certain systemic disorders (such as Sjögren's syndrome and rheumatoid arthritis) or as a result of atrophy or destruction of the lacrimal gland.
- ❖ **Altered composition of the tear film.** The composition of the tear film can alter due to vitamin A deficiency, medications (such as oral contraceptives and retinoids), or certain environmental influences (such as nicotine, smog, or air conditioning). The tear film breaks up too quickly and causes corneal drying.

Dry eyes can represent a **disorder in and of itself**.

Symptoms: Patients complain of burning, reddened eyes, and excessive lacrimation (reflex lacrimation) from only slight environmental causes such as wind, cold, low humidity, or reading for an extended period of time. A foreign body sensation is also present. These symptoms may be accompanied by intense pain. Eyesight is usually minimally compromised if at all.

Diagnostic considerations: Often there is a discrepancy between the *minimal clinical findings* that the ophthalmologist can establish and the *intense symptoms reported by the patient*. Results from **Schirmer tear testing** usually show reductions of the watery component of tears, and the **tear break-up time** (which provides information about the mucin content of the tear film which is important for its stability) is reduced. Values of at least 10 seconds are normal; the tear break-up time in keratoconjunctivitis sicca is less than 5 seconds.

Slit lamp examination will reveal dilated conjunctival vessels and minimal pericorneal injection. A tear film meniscus cannot be demonstrated on the lower eyelid margin, and the lower eyelid will push the conjunctiva along in folds in front of it.



In *severe cases* the eye will be reddened, and the tear film will contain thick mucus and small filaments that proceed from a superficial epithelial lesion (filamentary keratitis; see Fig. 5.11). The corneal lesion can be demonstrated with **fluorescein dye**. In less severe cases the eye will only be reddened, although application of fluorescein dye will reveal corneal lesions (superficial punctate keratitis; see p. 138). The **rose bengal test** (see p. 52) and **impression cytology** (see p. 53) are additional diagnostic tests that are useful in evaluating persistent cases.

Treatment: Depending on the severity of findings, **artificial tear solutions** in varying viscosities are prescribed. These range from eyedrops to high-viscosity long-acting gels that may be applied every hour or every half hour, depending on the severity of the disorder. In persistent cases, the puncta can be temporarily closed with silicone **punctal plugs** (Fig. 3.11) to at least retain the few tears that are still produced. **Surgical obliteration of the puncta** may be indicated in severe cases.

Patients should also be informed about the possibility of installing an **air humidifier** in the home and redirecting blowers in automobiles to avoid further drying of the eyes. Dry eyes in women may also be due to hormonal changes, and a **gynecologist should be consulted** regarding the patient's hormonal status.

Prognosis: The prognosis is good for those treatments discussed here. However, the disorder cannot be completely healed.

Treatment of dry eyes.

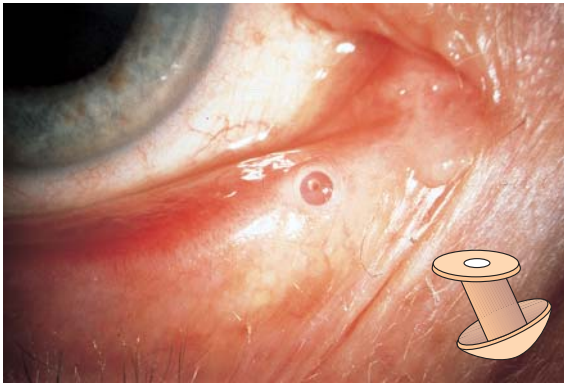


Fig. 3.11 Treatment can be augmented by temporarily closing the puncta with silicone punctal plugs.



3.4.2 Illacrimation

Illacrimation or epiphora may be due to *hypersecretion from the lacrimal gland*. However, it is more often caused by *obstructed drainage through the lower lacrimal system*.

Causes of hypersecretion:

- ❖ *Emotional distress* (crying).
- ❖ *Increased irritation of the eyes* (by smoke, dust, foreign bodies, injury, or intraocular inflammation) leads to excessive lacrimation in the context of the defensive triad of blepharospasm, photosensitivity, and epiphora.

Causes of obstructed drainage:

- ❖ Stricture or stenosis in the lower lacrimal system.
- ❖ Eyelid deformity (eversion of the punctum lacrimale, ectropion, or entropion).

3.5 Disorders of the Lacrimal Gland

3.5.1 Acute Dacryoadenitis

Definition

Acute inflammation of the lacrimal gland is a *rare* disorder characterized by intense inflammation and extreme tenderness to palpation.

Etiology: The disorder is often attributable to pneumococci and staphylococci, and less frequently to streptococci. There may be a relationship between the disorder and infectious diseases such as mumps, measles, scarlet fever, diphtheria, and influenza.

Symptoms and diagnostic considerations: Acute dacryoadenitis usually occurs *unilaterally*. The inflamed *swollen gland* is especially *tender to palpation*.



The upper eyelid exhibits a characteristic S-curve (Fig. 3.12).

Differential diagnosis:

- ❖ Internal hordeolum (smaller and circumscribed).
- ❖ Eyelid abscess (fluctuation).
- ❖ Orbital cellulitis (usually associated with reduced motility of the eyeball).

Treatment: This will depend on the *underlying disorder*. *Moist heat, disinfectant compresses* (Rivanol), and local *antibiotics* are helpful.

Clinical course and prognosis: Acute inflammation of the lacrimal gland is characterized by a rapid clinical course and *spontaneous healing within eight*



Acute dacryoadenitis.

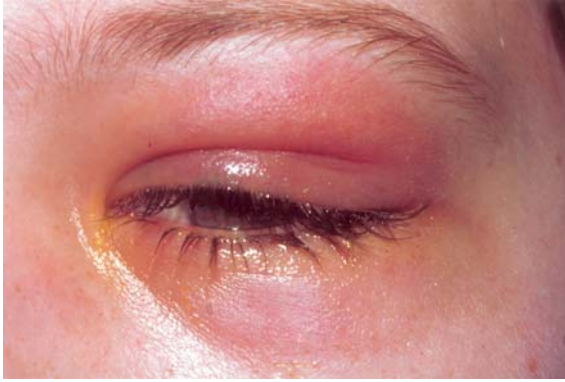

Fig. 3.12
Characteristic S-curve of the upper eyelid.

to ten days. The prognosis is good, and complications are not usually to be expected.

3.5.2 Chronic Dacryoadenitis

Etiology: The chronic form of inflammation of the lacrimal gland may be the result of an incompletely healed *acute* dacryoadenitis. Diseases such as tuberculosis, sarcoidosis, leukemia, or lymphogranulomatosis can be causes of chronic dacryoadenitis.



Bilateral chronic inflammation of the lacrimal and salivary glands is referred to as Mikulicz's syndrome.

Symptoms and diagnostic considerations: Usually there is no pain. The symptoms are less pronounced than in the acute form. However, the S-curve deformity of the palpebral fissure resulting from swelling of the lacrimal gland is readily apparent (see Fig. 3.12).

Differential diagnosis:

- ❖ Periostitis of the upper orbital rim (rare).
- ❖ Lipodermoid (no signs of inflammation).

Treatment: This will depend on the *underlying disorder*. *Systemic corticosteroids* may be effective in treating unspecific forms.

Prognosis: The prognosis for chronic dacryoadenitis is good when the underlying disorder can be identified.



3.5.3 Tumors of the Lacrimal Gland

Epidemiology: Tumors of the lacrimal gland account for 5–7% of orbital neoplasms. Lacrimal gland tumors are *much rarer in children* (approximately 2% of orbital tumors). The relation of benign to malignant tumors of the lacrimal gland specified in the literature is 10 : 1. The **most frequent benign epithelial lacrimal gland tumor** is the *pleomorphic adenoma*. **Malignant tumors** include the *adenoid cystic carcinoma* and *pleomorphic adenocarcinoma*.

Etiology: The WHO classification of 1980 divides lacrimal gland tumors into the following categories:

- I. Epithelial tumors.
- II. Tumors of the hematopoietic or lymphatic tissue.
- III. Secondary tumors.
- IV. Inflamed tumors.
- V. Other and unclassified tumors.

Symptoms: Tumors usually *grow very slowly*. After a while, they displace the eyeball inferiorly and medially, which can cause double vision.

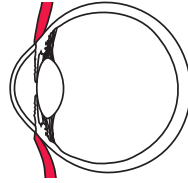
Diagnostic considerations: Testing **motility** provides information about the infiltration of the tumor into the extraocular muscles or mechanical changes in the eyeball resulting from tumor growth. The echogenicity of the tumor in **ultrasound studies** is an indication of its consistency. **CT** and **MRI** studies show the exact location and extent of the tumor. A biopsy will confirm whether it is malignant and what type of tumor it is.

Treatment: To the extent that this is possible, the entire tumor should be removed; orbital exenteration (removal of the entire contents of the orbit) may be required. Systemic administration of corticosteroids is indicated for unspecific tumors.

Prognosis: This depends on the degree of malignancy of the tumor. Adenoid cystic carcinomas have the most unfavorable prognosis.

4 Conjunctiva

Gerhard K. Lang and Gabriele E. Lang



4.1 Basic Knowledge

Structure of the conjunctiva (Fig. 4.1): The conjunctiva is a thin vascular mucous membrane that normally of shiny appearance. It forms the conjunctival sac together with the surface of the cornea. The **bulbar conjunctiva** is loosely attached to the sclera and is more closely attached to the limbus of the cornea. There the conjunctival epithelium fuses with the corneal epithelium. The **palpebral conjunctiva** lines the inner surface of the eyelid and is firmly attached to the tarsus. The loose palpebral conjunctiva forms a fold in the **conjunctival fornix**, where it joins the bulbar conjunctiva. A half-moon-shaped fold of mucous membrane, the *plica semilunaris*, is located in the medial corner of the palpebral fissure. This borders on the lacrimal caruncle, which contains hairs and sebaceous glands.

Function of the conjunctival sac: The conjunctival sac has three main tasks:

- 1. Motility of the eyeball.** The loose connection between the bulbar conjunctiva and the sclera and the “spare” conjunctival tissue in the fornices allow the eyeball to move freely in every direction of gaze.
- 2. Articulating layer.** The surface of the conjunctiva is smooth and moist to allow the mucous membranes to glide easily and painlessly across each other. The tear film acts as a lubricant.
- 3. Protective function.** The conjunctiva must be able to protect against pathogens. Follicle-like aggregations of lymphocytes and plasma cells (the lymph nodes of the eye) are located beneath the palpebral conjunctiva and in the fornices. Antibacterial substances, immunoglobulins, interferon, and prostaglandins help protect the eye.



Anatomy of the conjunctiva.

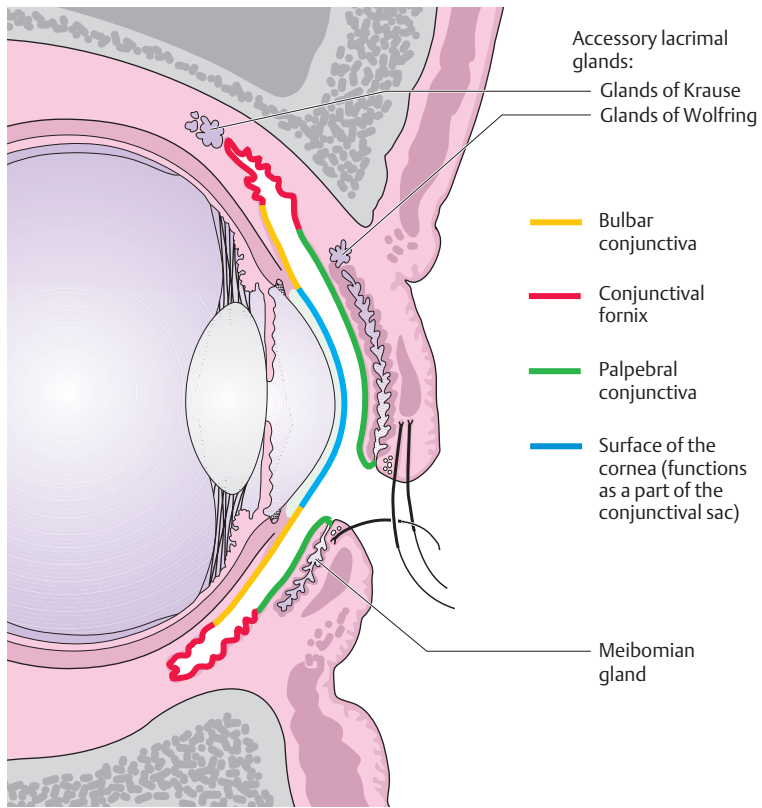


Fig. 4.1 The conjunctiva consists of the bulbar conjunctiva, the conjunctival fornices, and the palpebral conjunctiva. The surface of the cornea functions as the floor of the conjunctival sac.

4.2 Examination Methods

Inspection: The **bulbar conjunctiva** can be evaluated by direct inspection under a focused light. Normally it is shiny and transparent. The **other parts of the conjunctiva** will not normally be visible. They can be inspected by evert-ing the upper or lower eyelid (see eyelid eversion below).



Dye staining: Defects and tears in the conjunctiva or cornea can be visualized by applying a drop of fluorescein dye or rose bengal and inspecting the eye under illumination with a cobalt blue filter (see Fig. 5.11, p. 139).

Eyelid eversion: Even the non-ophthalmologist must be familiar with the technique of everting the upper or lower eyelid. This is an important examination method in cases in which the conjunctival sac requires cleaning or irrigation, such as removing a foreign body or rendering first aid after a chemical injury. See Chapter 1 for a detailed description of the examination method.

4.3 Conjunctival Degeneration and Aging Changes

4.3.1 Pingueculum

Definition

Harmless grayish yellow thickening of the conjunctival epithelium in the palpebral fissure.

Epidemiology: Pinguecula are the most frequently observed conjunctival changes.

Etiology: The harmless thickening of the conjunctiva is due to *hyaline degeneration* of the subepithelial collagen tissue. Advanced age and exposure to sun, wind, and dust foster the occurrence of the disorder.

Symptoms: Pingueculum does not cause any symptoms.

Diagnostic considerations: Inspection will reveal grayish yellow thickening at 3 o'clock and 9 o'clock on the limbus. The base of the triangular thickening (often located medially) will be parallel to the limbus of the cornea; the tip will be directed toward the angle of the eye (Fig. 4.2).

Differential diagnosis: A pingueculum is an unequivocal finding.

Treatment: No treatment is necessary.

4.3.2 Pterygium

Definition

Triangular fold of conjunctiva that usually grows from the medial portion of the palpebral fissure toward the cornea.

Epidemiology: Pterygium is especially prevalent in southern countries due to increased exposure to intense sunlight.



Pinguecula.

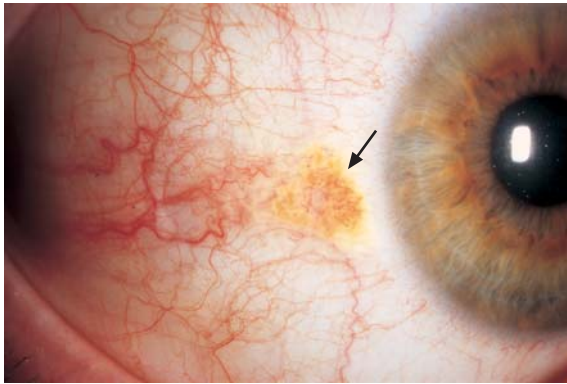

Fig. 4.2 Harmless triangular pingueculum whose base is parallel to the cornea (arrow).

Etiology: Histologically, a pterygium is identical to a pinguecula. However, it differs in that it can grow on to the cornea; the gray head of the pterygium will grow gradually toward the center of the cornea (Fig. 4.3a). This progression is presumably the result of a *disorder of Bowman's layer of the cornea*, which provides the necessary growth substrate for the pterygium.

Symptoms and diagnostic considerations: A pterygium only produces symptoms when its head threatens the center of the cornea and with it the visual axis (Fig. 4.3b). Tensile forces acting on the cornea can cause severe corneal astigmatism. A steadily advancing pterygium that includes scarred conjunctival tissue can also gradually impair ocular motility; the patient will then experience double vision in abduction.

Differential diagnosis: A pterygium is an unequivocal finding.

Treatment: Treatment is only necessary when the pterygium produces the symptoms discussed above. Surgical removal is indicated in such cases. The head and body of the pterygium are largely removed, and the sclera is left open at the site. The cornea is then smoothed with a diamond reamer or an excimer laser (a special laser that operates in the ultraviolet range at a wavelength of 193 nm).

Clinical course and prognosis: Pterygia tend to recur. Keratoplasty is indicated in such cases to replace the diseased Bowman's layer with normal tissue. Otherwise the diseased Bowman's layer will continue to provide a growth substrate for a recurrent pterygium.

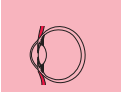
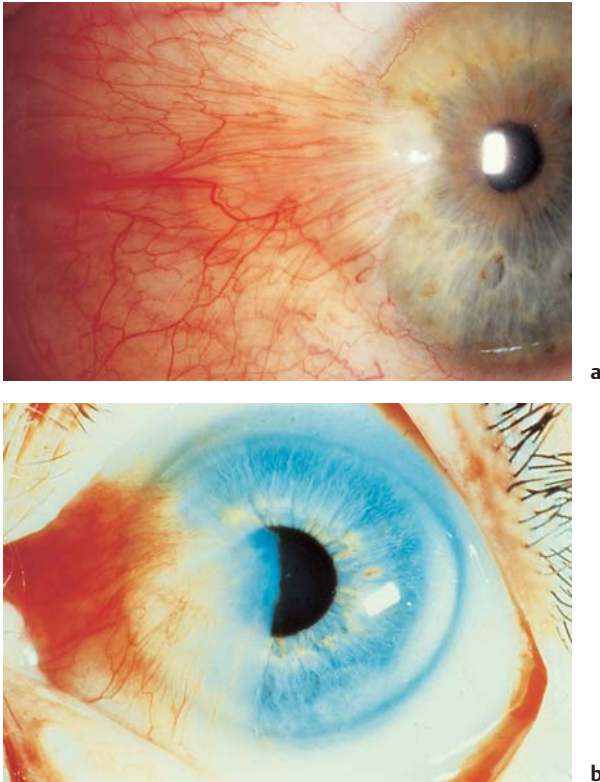
**Pterygium.**

Fig. 4.3 **a** Triangular fold of conjunctiva growing from the medial portion of the palpebral fissure toward the cornea. **b** Pterygium that has grown on to the cornea and threatens the optical axis.

4.3.3 Pseudopterygium

A pseudopterygium due to conjunctival scarring differs from a pterygium in that there are *adhesions* between the scarred conjunctiva and the cornea and sclera. Causes include corneal injuries and/or chemical injuries and burns. Pseudopterygia cause pain and double vision. Treatment consists of lysis of the adhesions, excision of the scarred conjunctival tissue, and coverage of the defect (this may be achieved with a free conjunctival graft harvested from the temporal aspect).

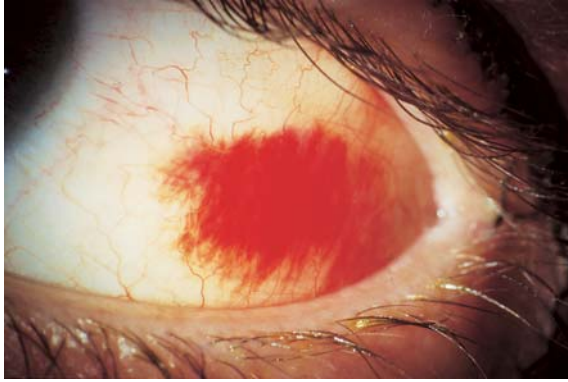**Subconjunctival hemorrhage.**

Fig. 4.4 Extensive bleeding under the conjunctiva.

4.3.4 Subconjunctival Hemorrhage

Extensive bleeding under the conjunctiva (Fig. 4.4) frequently occurs with conjunctival injuries (for obtaining a history in trauma cases, see Chapter 18, conjunctival laceration). Subconjunctival hemorrhaging will also often occur spontaneously in elderly patients (as a result of compromised vascular structures in arteriosclerosis), or it may occur after coughing, sneezing, pressing, bending over, or lifting heavy objects. Although these findings are often very unsettling for the patient, they are usually *harmless* and resolve spontaneously within two weeks. The patient's blood pressure and coagulation status need only be checked to exclude hypertension or coagulation disorders when subconjunctival hemorrhaging occurs repeatedly.

4.3.5 Calcareous Infiltration

A foreign-body sensation in the eye is often caused by white punctate concretions on the palpebral conjunctiva. These concretions are the *calcified contents* of goblet cells, accessory conjunctival and lacrimal glands, or meibomian glands where there is insufficient drainage of secretion. These calcareous infiltrates can be removed with a scalpel under topical anesthesia.

4.3.6 Conjunctival Xerosis

Definition

Desiccation of the conjunctiva due to a vitamin A deficiency.

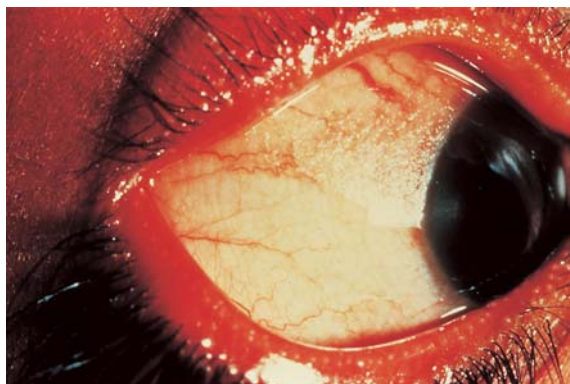
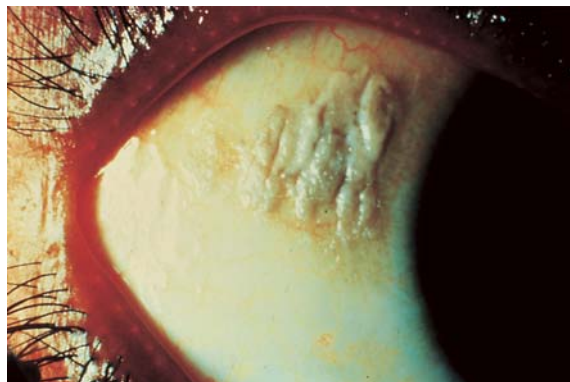
**Conjunctival xerosis due to vitamin a deficiency.**

Fig. 4.5 a Keratinization of the superficial epithelial cells causes the surface of the conjunctiva to lose its luster.



b The keratinized epithelial cells die and create characteristic Bitot's spots in the palpebral fissure.

Epidemiology: Due to the high general standard of nutrition, this disorder is very rare in the developed world. However, it is one of the most frequent causes of blindness in developing countries.

Etiology: Vitamin A deficiency results in keratinization of the superficial epithelial cells of the eye. Degeneration of the goblet cells causes the surface of the conjunctiva to lose its luster (Fig. 4.5a). The keratinized epithelial cells die and are swept into the palpebral fissure by blinking, where they accumulate and create characteristic white Bitot's spots (Fig. 4.5b). Xerosis bacteria frequently proliferate.



Treatment and prognosis: The changes disappear after local and systemic vitamin A substitution. Without vitamin A substitution, the disorder will lead to blindness within a few years.

4.4 Conjunctivitis

4.4.1 General Notes on the Causes, Symptoms, and Diagnosis of Conjunctivitis

Definition

Conjunctivitis is an inflammatory process involving the surface of the eye and characterized by vascular dilation, cellular infiltration, and exudation. Two forms of the disorder are distinguished:

- ❖ **Acute conjunctivitis.** Onset is abrupt and initially unilateral with inflammation of the second eye within one week. Duration is less than four weeks.
- ❖ **Chronic conjunctivitis.** Duration is longer than three to four weeks.

Epidemiology: Conjunctivitis is one of the most frequent eye disorders.

Etiology: Causes of conjunctivitis may be fall into two broad categories:

- ❖ **Infectious** (see Fig. 4.2)
 - bacterial
 - viral
 - parasitic
 - mycotic
- ❖ **Noninfectious** (see Fig. 4.4)
 - from a persistent irritation (such as lack of tear fluid or uncorrected refractive error; see Fig. 4.4)
 - allergic
 - toxic (due to irritants such as smoke, dust, etc.)
 - as a result of another disorder (such as Stevens–Johnson syndrome).

Symptoms: Typical symptoms exhibited by all patients include **reddened eyes** and **sticky eyelids** in the morning due to *increased secretion*. Any conjunctivitis also causes **swelling of the eyelid**, which will appear partially closed (*pseudoptosis*). **Foreign-body sensation**, a **sensation of pressure**, and a **burning sensation** are usually present, although these symptoms may vary between individual patients. Intense itching always suggests an allergic reaction. **Photophobia** and **lacrimation** (epiphora) may also be present but can vary considerably. Simultaneous presence of **blepharospasm** suggests corneal involvement (keratoconjunctivitis).



Diagnostic considerations: There are many causes of conjunctivitis, and the clinical picture and symptoms can vary considerably between individual patients. This makes it all the more important to note certain characteristic findings that permit an accurate diagnosis, such as the type of exudation, conjunctival findings, or swollen preauricular lymph nodes (Table 4.1).

Hyperemia. Reddened eyes are a typical sign of conjunctivitis. The conjunctival injection is due to increased filling of the conjunctival blood vessels, which occurs most prominently in the conjunctival fornices. Hyperemia is present in all forms of conjunctivitis. However, the visibility of the hyperemic vessels and their location and size are important criteria for differential diagnosis. One can also distinguish conjunctivitis from other disorders such as scleritis or keratitis according to the injection (Fig. 4.6). The following types of injection are distinguished.

- ❖ *Conjunctival injection* (bright red, clearly visible distended vessels that move with the conjunctiva, decreasing toward the limbus; Fig. 4.7).
- ❖ *Pericorneal injection* (superficial vessels, circular or circumscribed in the vicinity of the limbus).

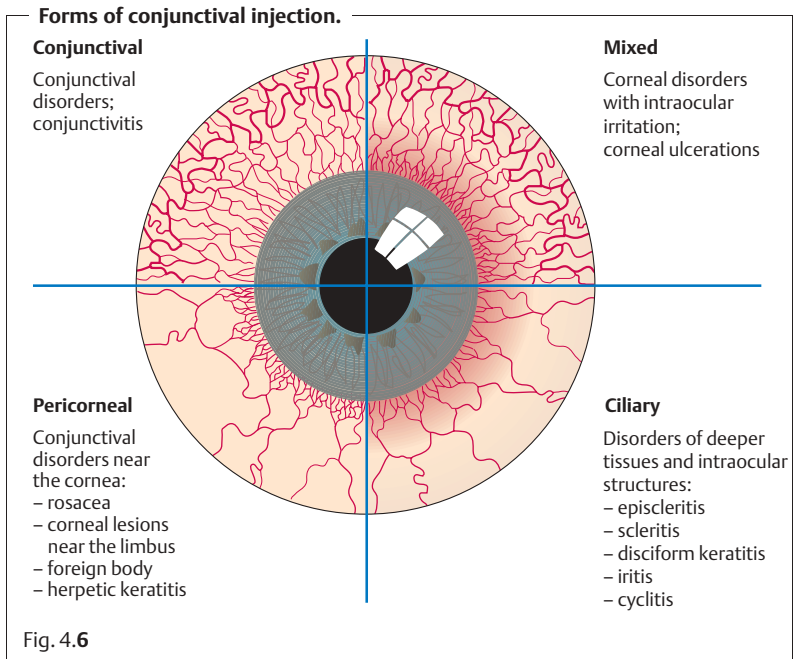




Table 4.1 Symptoms and findings in conjunctivitis as they relate to various forms of the disorder

Symptom or finding	Bacterial conjunctivitis	Chlamydial conjunctivitis	Viral conjunctivitis	Allergic conjunctivitis	Toxic conjunctivitis
Itching	-	-	-	++	-
Hyperemia (reddened eye)	++	+	+	+	+
Bleeding	+	-	+	-	-
Discharge	Purulent; yellow crusts	Mucopurulent	Watery	Ropy white, viscous	-
Chemosis	++	-	±	++	±
Lacrimation (epiphora)	+	+	++	+	+
Follicles	-	++	+	+	+
Papillae	+	±	-	+	-
Pseudomembranes, membranes	±	-	±	-	-
Swollen lymph nodes	+	+	++	-	-
Pannus formation	-	+	-	-	±



Concurrent keratitis	±	+	±	-	±
Fever or angina	±	-	±	-	-
Results of cytologic smear	Granulocytes, bacteria	Intracytoplasmic inclusions in epi- thelial cells, leuko- cytes, plasma cells, lymphocytes	Lymphocytes, monocytes	Eosinophilic granulocytes, lymphocytes	Epithelial cells, granulocytes, lymphocytes

- ++ = Severe
- + = Moderate
- ± = Occasional
- = Rare or absent



Conjunctival injection.

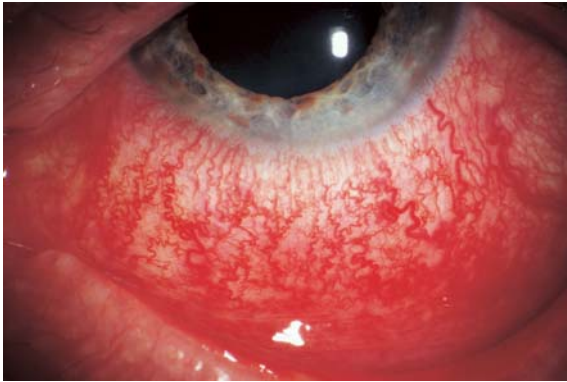

Fig. 4.7 Clearly visible, bright red, distended conjunctival vessels, decreasing toward the limbus of the cornea.

- ❖ *Ciliary injection* (not clearly discernible, brightly colored nonmobile vessels in the episclera near the limbus).
- ❖ *Composite injection* (frequent).

Discharge. The quantity and nature of the exudate (mucoid, purulent, watery,ropy, or bloody) depend on the etiology (see Table 4.1).

Chemosis (Fig. 4.8). This may range from the absence of any conjunctival thickening to a white glassy edema and swelling of the conjunctiva projecting from the palpebral fissure (chemosis this severe occurs with bacterial and allergic conjunctivitis).

Epiphora (excessive tearing). Illacrimation should be distinguished from exudation. Illacrimation is usually reflex lacrimation in reaction to a conjunctival or corneal foreign body or toxic irritation.

Follicle. Lymphocytes in the palpebral and bulbar conjunctiva accumulate in punctate masses of lymph tissue cells that have a granular appearance. Follicles occur typically in viral and chlamydial infections (Fig. 4.9).

Papillae. Papillae appear as polygonal “cobblestone” conjunctival projections with a central network of finely branching vessels. They are a typical sign of allergic conjunctivitis (Fig. 4.10).

Membranes and pseudomembranes. These are conjunctival reactions to severe infectious or toxic conjunctivitis. They form from necrotic epithelial tissue and either can be easily removed without bleeding (pseudomembranes) or leave behind a bleeding surface when they are removed (membranes; Figs. 4.11 a, b).



Conjunctival chemosis.

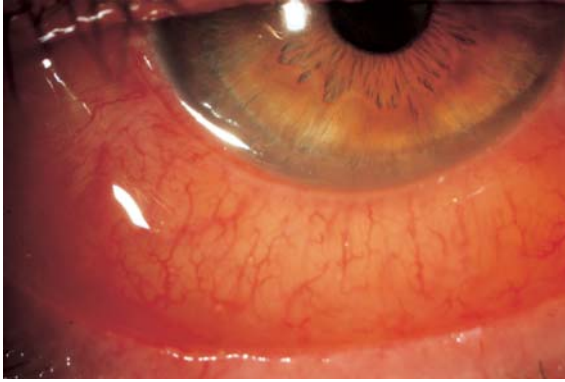


Fig. 4.8 White glassy edema and swelling of the conjunctiva.

Follicular conjunctivitis.

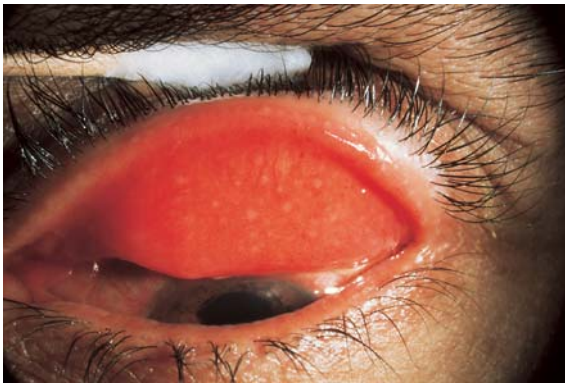

Fig. 4.9 Punctate masses of lymph tissue cells of a granular appearance.

Swollen lymph nodes. Lymph from the eye region drains through the preauricular and submandibular lymph nodes. Swollen lymph nodes are an important and frequently encountered diagnostic sign of viral conjunctivitis.

Pannus formation. Conjunctival or vascular ingrowth between Bowman's layer and the corneal epithelium in the upper circumference.



The combination and severity of individual symptoms usually provide essential information that helps to identify the respective presenting form of conjunctivitis.



Papillary conjunctivitis.

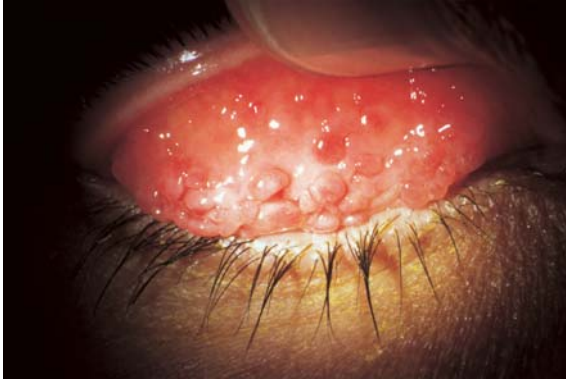

Fig. 4.10 Eversion of the upper eyelid reveals “cobblestone” conjunctival projections.

Granulomas. These are inflamed nodes of conjunctival stroma with circumscribed areas of reddening and vascular injection. They can occur with systemic disorders such as tuberculosis or sarcoidosis or may be exogenous, such as postoperative suture granulomas or other foreign-body granulomas. Granulomas occur in conjunction with swollen preauricular and submandibular lymph nodes in disorders such as Parinaud’s oculoglandular syndrome. Granulomas are not a sign of conjunctivitis in the strict sense and for that reason have not been included as symptoms or findings in Table 4.1.

Examination methods: Slit lamp examination.

The nature and extent of vascular injections, discharge, conjunctival swelling, etc. are evaluated using a slit lamp.

Eyelid eversion. This is performed to examine the upper and lower eyelids for the presence of follicles, papillae, membranes, and foreign bodies.

If the diagnosis is uncertain or what appears to be bacterial conjunctivitis does not respond to antibiotics, a *conjunctival smear* (Fig. 4.12) should be obtained for microbiological examination to identify the pathogen. Cotton swabs with sterile shipping tubes are commercially available; special test kits with specific cultures are available for detecting chlamydiae.

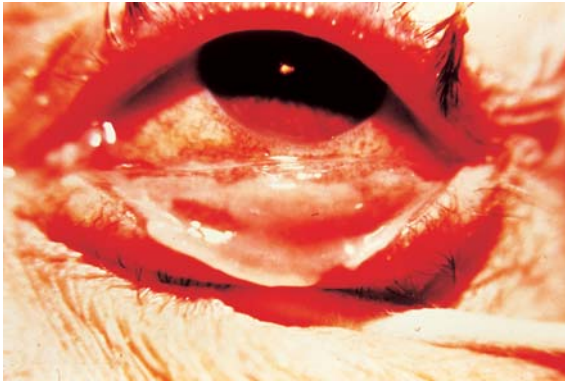

An antibiotic that is not effective in treating what appears to be bacterial conjunctivitis should be discontinued. A conjunctival smear should then be obtained 24 hours later. Microbiological examination to identify the pathogen is indicated for any conjunctivitis in children.

Epithelial smear. This is used to detect chlamydiae in particular and to more clearly identify the pathogen in general. A scraping of conjunctival

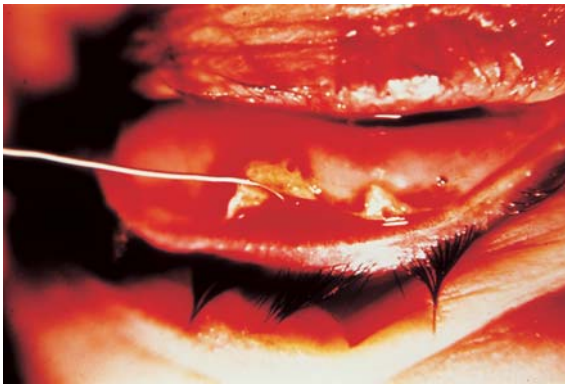


Membranous conjunctivitis.



a

Figs. 4.11 a, b
Genuine membranes (a) leave behind a bleeding surface when they are removed (b).



b

epithelium is smeared on a slide and dyed with Giemsa and Gram stain. Cytologic findings provide important information about the etiology of the conjunctivitis.

- ❖ bacterial conjunctivitis: granulocytes with polymorphous nuclei and bacteria;
- ❖ viral conjunctivitis: lymphocytes and monocytes;
- ❖ chlamydial conjunctivitis (special form of bacterial conjunctivitis): composite findings of lymphocytes, plasma cells, and leukocytes; characteristic intracytoplasmic inclusion bodies in epithelial cells may also be present (see Fig. 4.13);



Conjunctival smear for microbiological examination.

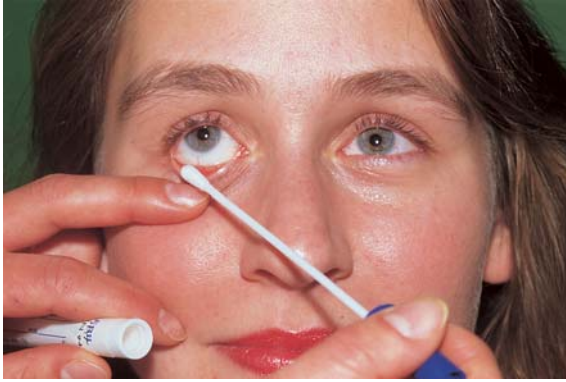

Fig. 4.12 The lower eyelid is slightly everted and a smear of the conjunctival secretion is obtained with a cotton swab.

- ❖ allergic conjunctivitis: findings primarily include eosinophilic granulocytes and lymphocytes;
- ❖ mycotic conjunctivitis (very rare): the Giemsa or Gram stain will reveal the hyphae.

Irrigation. Conjunctivitis will occur occasionally in asymptomatic dacryocystitis (see p. 60) or canaliculitis (see p. 61) as a result of continuous scattered spread of bacteria. The lower lacrimal system should always be irrigated in the presence of inflammation that recurs or resists treatment to verify or exclude that it is the source of the inflammation.

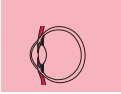
4.4.2 Infectious Conjunctivitis

The normal conjunctiva contains microorganisms. Inflammation usually occurs as a result of infection from *direct contact with pathogens* (such as from a finger, towel, or swimming pool) but also from *complicating factors* (such as a compromised immune system or injury). There are significant regional differences in the spectrum of pathogens. Table 4.2 provides an overview of pathogens, symptoms, and treatments.

4.4.2.1 Bacterial Conjunctivitis

Epidemiology: Bacterial conjunctivitis is very frequently encountered.

Etiology: Staphylococcus, streptococcus, and pneumococcus infections are most common in temperate countries.



Symptoms: Typical symptoms include severe reddening, swelling of the conjunctiva, and purulent discharge that leads to formation of yellowish crusts.

Diagnostic considerations: Bacterial conjunctivitis can usually be reliably diagnosed from the presence of typical symptoms. Laboratory tests (conjunctival smear) are usually only necessary when the conjunctivitis fails to respond to antibiotic treatment.



Bacterial conjunctivitis is diagnosed on the basis of clinical symptoms. Smears are obtained only in severe, uncertain, or persistent cases.

Treatment: Bacterial conjunctivitis usually responds very well to antibiotic treatment. A wide range of well tolerated, highly effective **antibiotic agents** is available today. Most of these are supplied as ointments (which are longer acting and suitable for overnight therapy) and as eyedrops for *topical therapy*. Substances include gentamicin, tobramycin, Aureomycin, chloramphenicol,¹ neomycin, polymyxin B in combination with bacitracin and neomycin, Terramycin, kanamycin, fusidic acid, ofloxacin, and acidamphenicol.¹

Preparations that combine an antibiotic and cortisone can more rapidly alleviate subjective symptoms when findings are closely monitored. These include medications such as gentamicin and dexamethasone; neomycin, polymyxin B, and dexamethasone; or tetracycline, polymyxin B, and hydrocortisone.

In severe, uncertain, or persistent cases requiring microbiological examination to identify the pathogen, treatment with broad-spectrum antibiotics or topical antibiotic combination preparations that cover the full range of Gram-positive and Gram-negative pathogens should begin immediately. This method is necessary because microbiological identification of the pathogen and resistance testing of the antibiotic are not always successful and may require several days. It is not advisable to leave the conjunctivitis untreated for this period.



In the presence of severe, uncertain, or persistent conjunctivitis, treatment with broad-spectrum antibiotics or topical antibiotic combination preparations should be initiated immediately, even before the laboratory results are available.

Clinical course and prognosis: Bacterial conjunctivitis usually responds well to antibiotic treatment and remits within a few days.

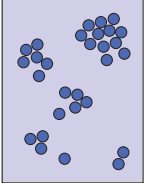
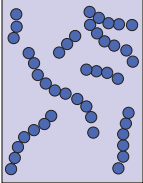

4.4.2.2 Chlamydial Conjunctivitis

Chlamydia are Gram-negative bacteria.

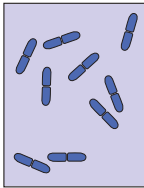
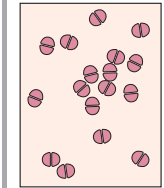
¹ See Appendix for side effects of medications



Table 4.2 Overview of infectious conjunctivitis

Cause	Clinical course	Symptoms and findings	Pathogen	Treatment
Bacteria				
Staphylococcal conjunctivitis	Subacute	Purulent discharge, blepharitis, superficial punctate keratitis, thickening of the conjunctiva at the limbus	 <p>Staphylococci: Gram-positive cluster form</p>	<p>Topical: broad-spectrum antibiotic (such as neomycin, kanamycin, tetracycline, gentamicin, or chloramphenicol)*</p>
Streptococcal conjunctivitis	Subacute	Watery mucoid discharge, conjunctival swelling, pseudomembranes	 <p>Streptococci: Gram-positive chain form</p>	
Pneumococcal conjunctivitis	Acute	Moderately purulent discharge, chemosis, multiple subconjunctival hemorrhages, corneal ulceration	 <p>Pneumococci: Brightly encapsulated Gram-positive lancet-shaped diplococci</p>	

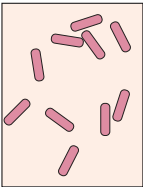
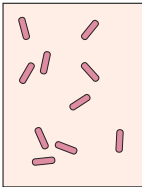


Bacteria	<p>Diphtheric conjunctivitis (must be reported)</p> <p>Acute</p> <p>Moderately purulent discharge, adhesive coverings (membranes) dominate, conjunctival necrosis, eyelid edema</p>	 <p>Gram-positive diplobacilli</p> <ul style="list-style-type: none"> ❖ Topical: broad-spectrum antibiotic (see above) ❖ Systemic: 300–500 units per kg of diphtheria antitoxin IV; antibiotics: penicillin, tetracycline
Gonococcal conjunctivitis	<p>Hyperacute</p> <p>Creamy purulent discharge, bright red conjunctiva, swollen eyelids and conjunctiva</p>	 <p>Gonococci (<i>Neisseria gonorrhoeae</i>): intracellular Gram-negative diplococci</p> <ul style="list-style-type: none"> ❖ Topical: broad-spectrum antibiotic (gentamicin, kanamycin, tetracycline, chloramphenicol)* ❖ Systemic: penicillin for 4–5 days: <ul style="list-style-type: none"> – Newborn: 1 mega-unit per day – Children: 2 mega-units per day – Adults: 4–5 mega-units per day

Continued →



Table 4.2 (Continued)

Cause	Clinical course	Symptoms and findings	Pathogen	Treatment
Bacteria	Pseudomonas conjunctivitis Hyperacute	Purulent discharge, often with corneal involvement. Fulminant course: infection may be spread by unsterile eyedrop bottles and contact lens holders. The bacterium emits an enzyme (proteoglycan) that can penetrate the cornea within 24 hours.	 Gram-negative <i>Pseudomonas aeruginosa</i> (<i>Bacillus pyocyaneus</i>)	Topical: broad-spectrum antibiotic (gentamicin, polymyxin B, chloramphenicol)*
	<i>Haemophilus influenzae</i> conjunctivitis	Serous, mucopurulent discharge; especially common in children. Corneal involvement is rare.	 <i>Haemophilus influenzae</i>: Gram-negative rods	Topical: broad-spectrum antibiotic (see above)

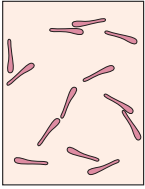


Bacteria

Haemophilus aegyptius (Koch-Weeks) conjunctivitis

Acute

Highly infectious conjunctivitis prevalent in warm countries, rare in temperate countries; eyelid swelling, chemosis, subconjunctival hemorrhaging, pseudomembranes, corneal ulceration



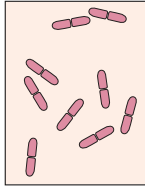
Haemophilus aegyptius
(Koch-Weeks): fine Gram-negative rods

Topical: broad-spectrum antibiotic (tetracycline, kanamycin, gentamicin)

Moraxella conjunctivitis

Subacute

Minimal discharge, moderate irritation (circumscribed in the angle of the eye with accompanying blepharoconjunctivitis). Corneal ulceration may occur.



Moraxella lacunata (Morax-Axenfeld diplobacillus): large Gram-negative diplobacilli

Topical: broad-spectrum antibiotic





0.25 – 0.5% zinc sulfate eyedrops are considered to be an effective specific treatment

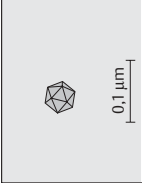
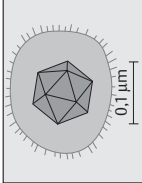
Continued →



Table 4.2 (Continued)

Cause	Clinical course	Symptoms and findings	Pathogen	Treatment
Chlamydia	Inclusion conjunctivitis Acute to chronic	Moderately reddened eye, typical viscous discharge, sticky eyes, tarsal follicles on the upper and lower eyelids, superficial punctate keratoconjunctivitis, spread of pannus across the limbus of the cornea, occasional peripheral sub-epithelial corneal infiltrates	 Chlamydia trachomatis (serotype D-K)	<ul style="list-style-type: none"> ❖ Topical: erythromycin or tetracycline for 2–3 weeks ❖ Systemic: erythromycin or tetracycline for at least 3 weeks Beware: disorder will recur if medication is discontinued too early
Trachoma	Chronic	Rare in temperate countries but endemic in warm climates. Lymph follicles on the palpebral conjunctiva of the upper eyelid, cicatricial entropion, ptosis, trichiasis, corneal scarring, xerosis of the conjunctiva. Four stages of the disorder are distinguished.	 Chlamydia trachomatis (serotype A-C)	As in inclusion conjunctivitis





<p>Viruses</p>	<ul style="list-style-type: none"> ❖ Epidemic keratoconjunctivitis 	<p>Acute</p> <p>Highly contagious conjunctivitis. Watery mucoid discharge, chemosis, eyelid edema, reddening and swelling of the plica semilunaris and lacrimal caruncle (<i>characteristic sign</i>), swollen preauricular lymph nodes; often there will be a moderate influenza infection. Nummular keratitis will appear after 8–15 days (<i>characteristic sign</i>).</p>	 <ul style="list-style-type: none"> ❖ Adenovirus (adenoid pharyngeal conjunctival); types 18 and 19 are most frequent. 	<ul style="list-style-type: none"> ❖ No specific treatment is possible. Symptomatic moistening treatment. ❖ Prophylaxis: meticulous hygiene. Human interferon (Berofor) prevents infection in exposed patients (extremely expensive).
<ul style="list-style-type: none"> ❖ Herpes simplex conjunctivitis ❖ Herpes zoster ophthalmicus 	<p>Acute, mild</p>	<p>Keratitis and keratoconjunctivitis always accompanied by crops of vesicles on an erythematous base on the eyelids</p>	 <ul style="list-style-type: none"> ❖ Herpes virus ❖ Varicella-zoster virus 	<p>Topical: acyclovir ointment</p> <ul style="list-style-type: none"> ❖ Systemic: acyclovir IV if necessary

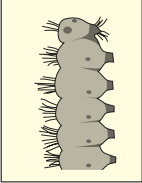
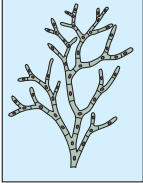
Continued →



Table 4.2 (Continued)

Cause	Clinical course	Symptoms and findings	Pathogen	Treatment
Parasites	Onchocerciasis (river blindness)	Conjunctivitis from microfilaria, progressing to keratitis, iridocyclitis, uveitis, and conjunctival scarring. This is most frequent cause of blindness in Africa.	 <p>Onchocerca volvulus (transmitted by the flies of the genus <i>Simulium</i>)</p>	Systemic treatment with ivermectin now available (treatment takes years)
Loa loa	Chronic	Conjunctivitis from microfilaria. The parasites are visible with the naked eye under the conjunctiva and will flee the light of the slit lamp). The disorder is endemic in west Africa	 <p>Loa loa (female 5–7 × 0.5 cm; male 3–3.5 × 0.3 cm)</p>	Surgical removal of the worms from the conjunctiva



Parasites	Nodose conjunctivitis	Chronic	<p>Very rare conjunctivitis. Caterpillar hairs accidentally find their way into the conjunctival sac. The hairs have barbs and work their way deep into the tissue. Granulomas develop on the conjunctiva. Blindness can result when these hairs penetrate into the interior of the eye.</p>	 <p>Caterpillar hairs</p> <p>Surgical removal of the caterpillar hairs, topical steroid therapy</p>
Fungi	Mycotic conjunctivitis	Acute	<p>Frequently associated with mycotic keratitis or secondary to mycotic canalculitis</p>	 <p>Hyphae</p> <p>As with mycotic keratitis: systemic and topical antimycotic therapy</p>

* See Appendix for side effects of medications



Inclusion Conjunctivitis

Epidemiology: Inclusion conjunctivitis is *very frequent* in temperate countries. The incidence in western industrialized countries ranges between 1.7% and 24% of all sexually active adults depending on the specific population studied.

Etiology: Oculogenital infection (*Chlamydia trachomatis* serotype D–K) is also caused by direct contact. In the newborn (see neonatal conjunctivitis), this occurs at birth through the cervical secretion. In adults, it is primarily transmitted during sexual intercourse, and rarely from infection in poorly chlorinated swimming pools.

Symptoms: The eyes are only moderately red and slightly sticky from viscous discharge.

Diagnostic considerations: Tarsal follicles are observed typically on the upper and lower eyelids, and pannus will be seen to spread across the limbus of the cornea. As this is an oculogenital infection, it is essential to determine whether the mother has any history of vaginitis, cervicitis, or urethritis if there is clinical suspicion of neonatal infection. Gynecologic or urologic examination is indicated in appropriate cases. Chlamydia may be detected in conjunctival smears, by immunofluorescence, or in tissue cultures. Typical cytologic signs include basophilic cytoplasmic inclusion bodies (Fig. 4.13).

Treatment: In adults, the disorder is treated with tetracycline or erythromycin eyedrops or ointment over a period of four to six weeks. The oculogenital mode of infection entails a risk of reinfection. Therefore, patients and sexual

Chlamydial conjunctivitis.

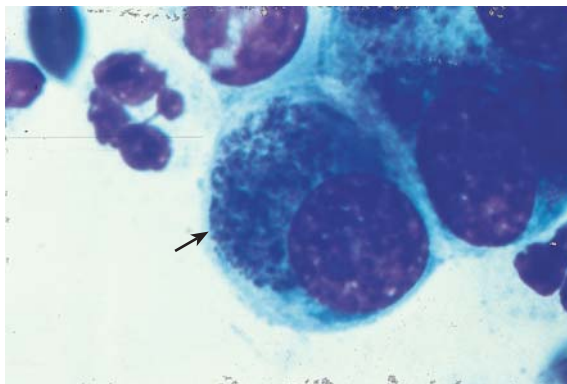


Fig. 4.13 Cytologic smear showing typical basophilic cytoplasmic inclusion bodies.



partners of treated patients should all be treated simultaneously with oral tetracycline. *Children* should be treated with erythromycin instead of tetracycline (see the table in the Appendix for side effects of medications).

Prognosis: The prognosis is good when the sexual partner is included in therapy.

Trachoma

Trachoma (*Chlamydia trachomatis* serotype A–C) is rare in temperate countries. In endemic regions (warm climates, poor standard of living, and poor hygiene), it is among the most frequent causes of blindness (see Table 4.2 for symptoms, findings, and therapy). Left untreated, the disorder progresses through four stages (Fig. 4.14):

- ❖ **Stage I:** Hyperplasia of the lymph follicles on the upper tarsus.
- ❖ **Stage II:** Papillary hypertrophy of the upper tarsus, subepithelial corneal infiltrates, pannus formation, follicles on the limbus.
- ❖ **Stages III and IV:** Increasing scarring and symptoms of keratoconjunctivitis sicca. The progression is entropion, trichiasis, keratitis, superinfection, ulceration, perforation, and finally loss of the eye.

4.4.2.3 Viral Conjunctivitis

Epidemiology: The incidence of **epidemic keratoconjunctivitis** is high in general, and it is by far the most frequently encountered viral conjunctivitis (see Table 4.2).

Trachoma (Stage II–III).

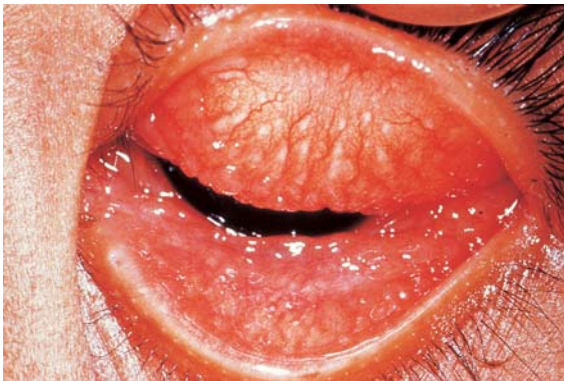

Fig. 4.14 Prominent tarsal follicles and papillae on the upper and lower eyelids.



Etiology: This highly contagious conjunctivitis is usually caused by type 18 or 19 adenovirus and is spread by direct contact (see also prophylaxis; Figs. 4.15 a and b). The incubation period is eight to ten days.

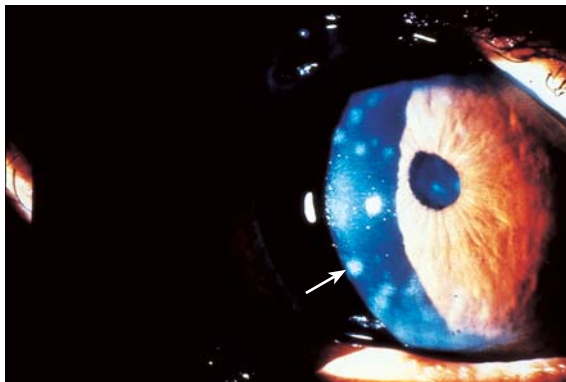
Symptoms: Onset is usually unilateral. Typical signs include severe illacrimation and itching accompanied by a watery mucoid discharge. The eyelid and often the conjunctiva are swollen. Patients often also have a moderate influenza infection.

Diagnostic considerations: Characteristic findings include reddening and swelling of the plica semilunaris and lacrimal caruncle and nummular keratitis (Fig. 4.15 b) after 8–15 days, during the healing phase.

Epidemic keratoconjunctivitis (viral conjunctivitis).

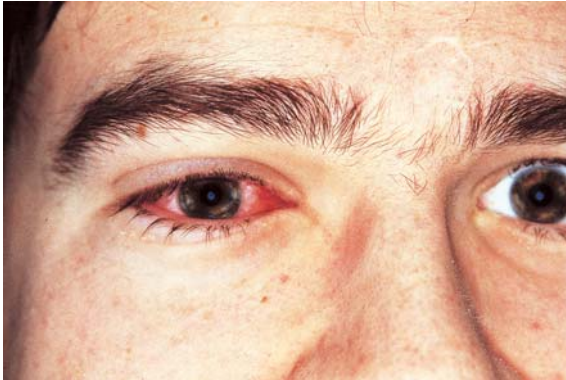

Fig. 4.15 a Acute unilateral reddening of the conjunctiva accompanied by pseudoptosis.



b After 8–10 days coin-like infiltrates (nummular keratitis) appear in the superficial corneal stroma. These may persist for months or years.



Differential diagnosis: The disease runs a well defined clinical course that is nearly impossible to influence and resolves after two weeks. No specific therapy is possible. Treatment with artificial tears and cool compresses helps relieve symptoms. Cortisone eyedrops should usually be avoided as they can compromise the immune system and prolong the clinical symptoms.

Prophylaxis: This is particularly important. Because the disease is spread by contact, the patient should refrain from rubbing his or her eyes despite a severe itching sensation and avoid direct contact with other people such as shaking hands, sharing tools, or using the same towels or wash cloths, etc.

Special **hygiene precautions** should be taken when examining patients with epidemic keratoconjunctivitis in ophthalmologic care facilities and doctors' offices to minimize the risk of infecting other patients. Patients with epidemic keratoconjunctivitis should not be seated in the same waiting room as other patients. They should not be greeted with a handshake, and they should be requested to refrain from touching objects where possible. Examination should be by indirect means only, avoiding applanation tonometry, contact lens examination, or gonioscopy. After examination, the examiner should clean his or her hands and the work site with a surface disinfectant.

4.4.2.4 Neonatal Conjunctivitis

Epidemiology: Approximately 10% of the newborn contract conjunctivitis.

Etiology (Table 4.3): The most frequent pathogens are *Chlamydia*, followed by gonococci. Neonatal conjunctivitis is less frequently attributable to *other bacteria* such as *Pseudomonas aeruginosa*, *Haemophilus*, *Staphylococcus aureus* and *Streptococcus pneumoniae*, or to herpes simplex. The infection occurs at birth. Chlamydia infections are particularly important because they are among the most common undetected maternal genital diseases in Europe, affecting 5% of all pregnant women. Neonatal conjunctivitis sometimes occurs as a result of Credé's method of prophylaxis with silver nitrate, required by law in Europe to prevent *bacterial* infection.

Symptoms: Depending on the pathogen, the inflammation will manifest itself between the second and fourteenth day of life (Table 4.3). The spectrum ranges from mild conjunctival irritation to life-threatening infection (especially with gonococcal infection). Conjunctivitis as a result of Credé's method of prophylaxis appears with hours but only leads to mild conjunctival irritation.



Acute purulent conjunctivitis in the newborn (gonococcal conjunctivitis) is considered a medical emergency. The patient should be referred to an ophthalmologist for specific diagnosis.



Table 4.3 Differential diagnosis of neonatal conjunctivitis (ophthalmia neonatorum)

Cause	Onset	Findings	Cytology and laboratory tests
Toxic (AgNO ₃ ; silver nitrate; Credé's prophylaxis)	Within hours	<ul style="list-style-type: none">❖ Hyperemia❖ Slight watery to mucoid discharge	Negative culture
Gonococci (gonococcal conjunctivitis)	2nd – 4th day of life	<ul style="list-style-type: none">❖ Acute purulent conjunctivitis	Intracellular Gram-negative diplococci; positive culture on blood agar and chocolate agar
Other bacteria (<i>Pseudomonas aeruginosa</i> , <i>Staphylococcus aureus</i> , <i>Streptococcus pneumoniae</i> , <i>Haemophilus</i>)	4th – 5th day of life	<ul style="list-style-type: none">❖ Mucopurulent conjunctivitis	Gram-positive or Gram-negative organisms; positive culture on blood agar
<i>Chlamydia</i> (inclusion conjunctivitis)	5th – 14th day of life	<ul style="list-style-type: none">❖ Mucopurulent conjunctivitis, less frequently purulent❖ Viscous mucus	Giemsa-positive cytoplasmic inclusion bodies in epithelial cells; negative culture
Herpes simplex virus	5th – 7th day of life	<ul style="list-style-type: none">❖ Watery blepharconjunctivitis❖ Corneal involvement❖ Systemic manifestations	Multinucleated giant cells, cytoplasmic inclusion bodies; negative culture

Diagnostic considerations: The tentative clinical diagnosis is made on the basis of the onset of the disease (Table 4.3) and the clinical syndrome. For example, gonococcal infections (gonococcal conjunctivitis) are typified by particularly severe accumulations of pus (Figs. 4.16a and b). The newborn's eyelid are tight and swollen because the pus accumulates under them. When the baby's eyes are opened, the pus can squirt out under pressure and cause dangerous conjunctivitis in the examiner's own eyes.



The examiner should always wear eye protection in the presence of suspected gonococcal conjunctivitis to guard against infection from pus issuing from the newborn's eyes. Gonococci can penetrate the eye even in the absence of a corneal defect and lead to loss of the eye.

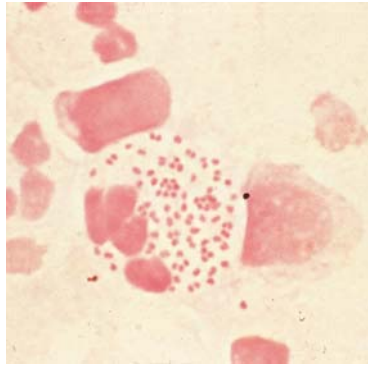
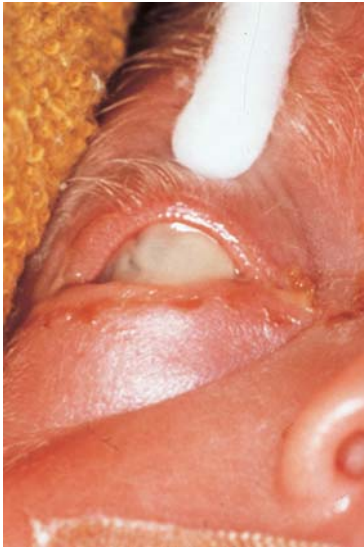**Neonatal conjunctivitis (gonococcal conjunctivitis).**

Fig. 4.16 **a** Highly infectious conjunctivitis with swelling of the eyelids and creamy purulent discharge issuing from the palpebral fissure.

b The Gram stain of the conjunctival smear reveals characteristic Gram-negative intracellular diplococci (gonococci).

The diagnosis should be confirmed by cytologic and microbiological studies. However, these studies often fail to yield unequivocal results, so that treatment must proceed on the basis of clinical findings.

Differential diagnosis: The onset of the disease is crucial to differential diagnosis (Table 4.3). Neonatal conjunctivitis must be distinguished from neonatal dacryocystitis. This disorder differs from the specific forms of conjunctivitis in it only becomes symptomatic two to four weeks after birth, with reddening and swelling of the region of the lacrimal sac and purulent discharge from the puncta. It can be readily distinguished from neonatal conjunctivitis because of these symptoms.

Treatment: *Toxic conjunctivitis* (Credé's method of prophylaxis): When the eye is regularly flushed and the eyelids cleaned, symptoms will abate spontaneously within one or two days.

Gonococcal conjunctivitis: Topical administration of broad-spectrum antibiotics (gentamicin eyedrops every hour) and systemic penicillin (penicillin G



IV 2 mill. IU daily) or cephalosporin in the presence of penicillinase-producing strains.

Chlamydial conjunctivitis: Systemic erythromycin and topical erythromycin eyedrops five times daily. There is a risk of recurrence where the dosage or duration of treatment is insufficient. It is essential to examine the parents and include them in therapy.

Herpes simplex conjunctivitis: Therapy involves application of acyclovir ointment to the conjunctival sac and eyelids as herpes vesicles will usually be present there, too. Systemic acyclovir therapy is only required in severe cases.

Prophylaxis: Credé's method of prophylaxis (application of 1% silver nitrate solution) prevents bacterial inflammation but not chlamydial or herpes infection. Prophylaxis of chlamydial infection consists of regular examination of the woman during pregnancy and treatment in appropriate cases.

4.4.2.5 Parasitic and Mycotic Conjunctivitis

Parasitic and mycotic forms of conjunctivitis (see Table 4.2) are less important in temperate climates. They are either *very rare* or occur primarily as comorbidities associated with a primary corneal disorder, such as mycotic infections of corneal ulcers.

4.4.3 Noninfectious Conjunctivitis

Table 4.4 provides an overview of pathogens, symptoms, and treatments of noninfectious conjunctivitis.

Acute conjunctivitis is frequently attributable to a series of external irritants or to dry eyes (conjunctivitis sicca). The disorder is *unpleasant but benign*. Primary symptoms include foreign-body sensation, reddening of the eyes of varying severity, and epiphora. Therapy should focus on eliminating the primary irritant and treating the symptoms.

Acute conjunctivitis should be distinguished from the group of **allergic forms of conjunctivitis**, which can be due to seasonal influences and often affect the nasal mucosa. Examples include *allergic conjunctivitis* (hay fever; Fig. 4.17) and *vernal conjunctivitis*. In *giant papillary conjunctivitis*, the inflammation is triggered by a foreign body (hard or soft contact lenses. There may also be an additional chronic microbial irritation such microbial contamination of contact lenses. *Phlyctenular keratoconjunctivitis* is a *delayed allergic reaction* to microbial proteins or toxins (staphylococcal inflammation). This disease occurs frequently in atopic individuals and is promoted by poor hygiene. The cardinal rule in allergic conjunctivitis is to avoid the causative agent. Desensitization should be performed as a *prophylactic measure* by a dermatologist or allergist. Long-term treatment includes cromoglycic acid eyedrops to prevent mast cell degranulation. *Treatment of acute allergic con-*

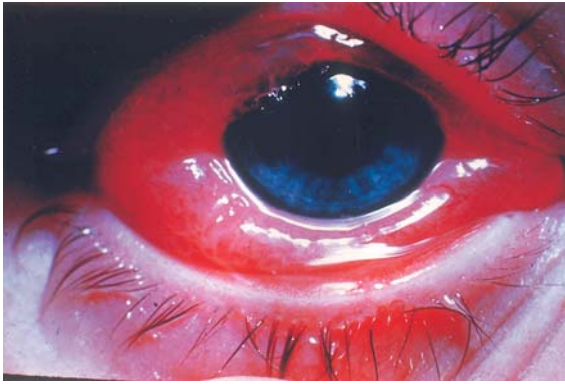
**Seasonal allergic conjunctivitis.**

Fig. 4.17 Conjunctival swelling (chemosis) in a patient with hay fever.

conjunctivitis consists of administering cooling compresses, artificial tears with preservatives, astringent eyedrops (tetryzoline and naphazoline), and, if necessary, surface-acting cortisone eyedrops (fluorometholone).

Ocular-mucocutaneous syndromes such as *Stevens–Johnson syndrome* (erythema multiforme), *Lyell's syndrome* (toxic epidermal necrolysis), and *ocular pemphigoid* (progressive shrinkage of the conjunctiva) are clinical syndromes that involve multiple toxic and immunologic causative mechanisms. The clinical course of the disorder is severe, therapeutic options are limited, and the prognosis for eyesight is poor (Fig. 4.18).

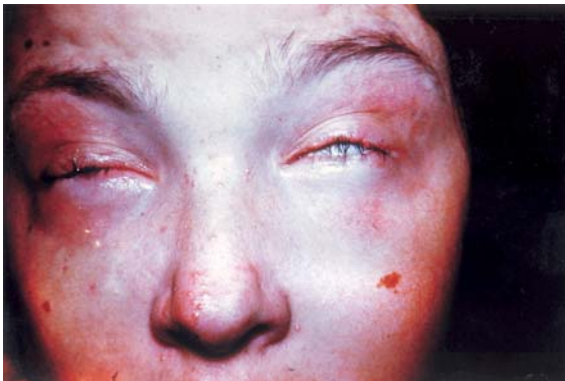Stevens–Johnson syndrome (erythema multiforme).

Fig. 4.18 After several years the conjunctival sac has fused completely (total symblepharon), effectively causing blindness.



Table 4.4 Overview of noninfectious conjunctivitis

Cause and form of conjunctivitis	Clinical course	Symptoms and findings	Other characteristic features	Treatment
Irritant Acute conjunctivitis	Acute to chronic	Foreign body sensation, conjunctival reddening, epiphora, blepharitis	<ul style="list-style-type: none"> ❖ Lack of tears (keratoconjunctivitis sicca) ❖ External irritants: smoke, heat, cold, wind (car window or open convertible top), ultraviolet light (welding, high-altitude sunlight). ❖ Positional anomalies of the eyelids or eyelashes ❖ Uncorrected refractive error (usually hyperopia) ❖ Dysfunction of binocular vision (uncompensated heterophoria) ❖ Improperly centered eyeglasses or wrong correction ❖ Overexertion, lack of sleep (burnout syndrome) 	<ul style="list-style-type: none"> ❖ Artificial tears ❖ Avoiding specific irritants ❖ Correction of anomaly or eyelash epilation ❖ Eyeglasses ❖ Prism lenses ❖ Center or replace eyeglass lenses ❖ Rest

Specific elimination of underlying cause



Allergy	Allergic conjunctivitis (hay fever)	Acute (seasonal)	Severe tearing, chemosis (can be extremely severe), watery discharge, foreign body sensation, sneezing	Typically accompanied by rhinitis; seasonal allergy to pollen, grasses, and plant allergens.	<ul style="list-style-type: none"> ❖ Desensitization ❖ Astringent eyedrops (tetryzoline, naphazoline), if necessary with surface-acting cortisone eyedrops (fluorometholone)
Vernal conjunctivitis	Acute (seasonal)	<ul style="list-style-type: none"> ❖ <i>Tarsal and conjunctival form</i>: "cobblestone" conjunctival projections on the palpebral conjunctiva of the upper eyelid, pseudoptosis, foreign body sensation, epiphora ❖ <i>Limbic form</i>: Swelling of the bulbar conjunctiva is the primary symptom, accompanied by a ring of nodules on the limbus of the cornea, foreign body sensation, and epiphora. ❖ <i>Corneal involvement</i>: Widespread corneal erosion to which mucus adheres (plaques), defensive triad of pain, blepharospasm, and epiphora. 	Occurs in boys and male adolescents during spring, either isolated in the eyes or in combination with generalized asthma; IgE-mediated reaction.	<ul style="list-style-type: none"> ❖ Brief treatment with cortisone eyedrops to control swelling ❖ Acetylcysteine gel to liquify the mucus ❖ Cromoglycic acid eyedrops as prophylaxis during the asymptomatic interval ❖ Levocabastine hydrochloride 	

Continued →



Table 4.4 (Continued)

Cause and form of conjunctivitis	Clinical course	Symptoms and findings	Other characteristic features	Treatment
Allergy	Chronic	Conjunctival reddening and irritation with pronounced papillary hypertrophy, similar to the findings and symptoms in vernal conjunctivitis	Frequently due to overwearing contact lenses (especially soft lenses); microbial component is probable (smear should be obtained)	Use of contact lenses should be discontinued until the inflammation abates. Contact lenses should be replaced or refitted; if the disorder recurs, they should be discontinued.
	Chronic	Discrete nodular areas of inflammation of the cornea or conjunctiva (phlyctenules), photophobia, epiphora, itching, rarely foreign body sensation, no pain	Usually occurs in children and young adults living in poor hygienic conditions and in countries characterized by a high rate of tuberculosis. The disease is uncommon in western countries.	Topical broad-spectrum antibiotics combined with cortisone or cortisone eyedrops alone provide rapid relief of symptoms.
Ocular-mucocutaneous syndrome	Chronic	Allergic, membranous conjunctivitis with blistering and increasing symblepharon; often the skin is also involved.	Toxic immunologic disorder, usually generalized as a reaction to medications (generally an antibiotic); life-threatening	<ul style="list-style-type: none"> ❖ Bland ointment therapy (such as Bepanthen) ❖ Rarely cortisone eye ointment ❖ Clean conjunctiva of fibrin daily ❖ Lysis of symblepharon



Toxic epidermal necrolysis (Lyell's syndrome)	Hyper-acute	Generalized blistering and shedding or necrotic skin, mucous membrane, and conjunctivitis	Extremely acute, life-threatening disorder	Stevens-Johnson and Lyell's syndromes have a similar clinical course and similar treatment as well.
Ocular pemphigoid	Chronic	Chronic bilateral conjunctivitis persisting for years; leads to increased scarring, symblepharon, and increasingly shallow conjunctival fornix that may progress to total obliteration of the conjunctival sac between the bulbar conjunctiva and the palpebral conjunctiva.	Autoimmune process with chronic episodic course; eyedrops and preservatives used in them exacerbate the process.*	<ul style="list-style-type: none"> ❖ <i>Symptomatic:</i> Artificial tears without preservatives <ul style="list-style-type: none"> – <i>Topical broad-spectrum antibiotics</i> in case of bacterial superinfection – <i>Topical steroid therapy</i> relieves symptoms. Note: this increases intraocular pressure (risk of cataract) – <i>Systemic steroids</i> in an acute episode – <i>Immunosuppressive agents:</i> cyclosporin A



Conjunctival irritation symptoms can occur with *Graves' orbitopathy*, *gout*, *rosacea*, *neurodermatitis*, *erythema multiforme*, *Sjögren's syndrome*, and *Reiter's syndrome* (triad: conjunctivitis or iridocyclitis, urethritis, and polyarthrititis). **Parinaud's oculoglandular syndrome** describes a clinical syndrome of widely varied etiology. *Granulomatous conjunctivitis* always occurs *unilaterally* and in conjunction with swollen preauricular and submandibular lymph nodes in the presence of tuberculosis, syphilis, viruses, bacteria, fungi, and parasites. The excisional biopsy of the conjunctival granuloma is itself part of the *treatment of granulomatous conjunctivitis*. The specific medications will depend on the underlying disorder.

4.5 Tumors

Primary benign conjunctival tumors (nevi, dermoids, lymphangiomas, hemangiomas, lipomas, and fibromas) occur *frequently*, as do tumor-like inflammatory changes (viral papillomas, granulomas such as suture granulomas after surgery to correct strabismus, cysts, and lymphoid hyperplasia). **Malignant conjunctival tumors** (carcinomas *in situ*, carcinomas, Kaposi's sarcomas, lymphomas, and primary acquired melanosis) are *rare*. **Benign lesions may become malignant**; for example, a nevus or acquired melanosis may develop into a malignant melanoma. This section presents only the most important tumors.

4.5.1 Epibulbar Dermoid

Epibulbar dermoid is a round dome-shaped grayish yellow or whitish *congenital* tumor. It is generally located on the limbus of the cornea, extending into the corneal stroma to a varying depth. Epibulbar dermoids can occur as *isolated lesions* or as a *symptom of oculoauriculovertebral dysplasia* (Goldenhar's syndrome). Additional symptoms of that disorder include outer ear deformities and preauricular appendages (Figs. 4.19a and b). Dermoids can contain hair and minor skin appendages. Ophthalmologists are often asked to remove them for cosmetic reasons. Surgical excision should remain strictly superficial; complete excision may risk perforating the globe as dermoids often extend through the entire wall of the eyeball.

4.5.2 Conjunctival Hemangioma

Conjunctival hemangiomas are small, cavernous proliferations of blood vessels. They are congenital anomalies and usually resolve spontaneously by the age of seven. Where this is not the case, they can be surgically removed (Fig. 4.20).



Epibulbar dermoid in oculoauriculovertebral dysplasia (Goldenhar's syndrome).

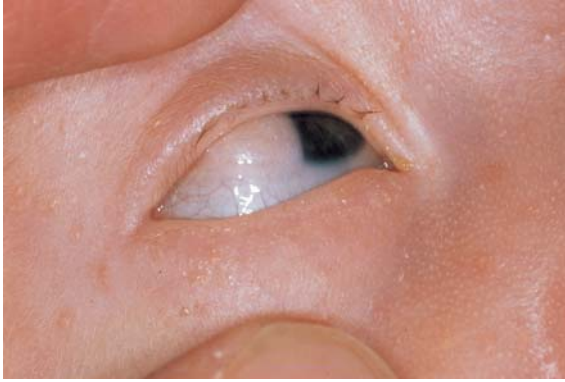
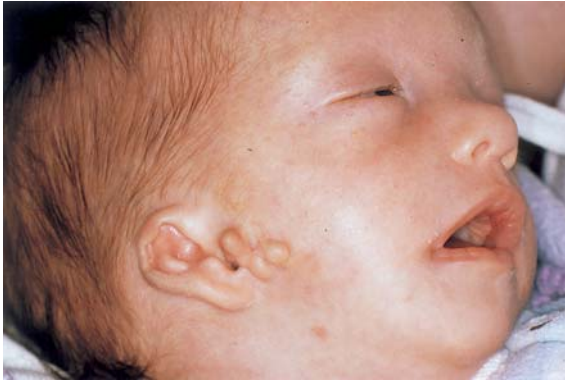
Fig. 4.19
a Epibulbar dermoid on the limbus of the cornea.



b Additional preauricular appendages.

4.5.3 Epithelial Conjunctival Tumors

4.5.3.1 Conjunctival Cysts

Conjunctival cysts are *harmless and benign*. Occurrence is most often post-operative (for example after surgery to correct strabismus), post-traumatic, or spontaneous. They usually take the form of small clear fluid-filled inclusions of conjunctival epithelium whose goblet cells secrete into the cyst and not on to the surface (Fig. 4.21). Cysts can lead to a foreign-body sensation and are removed surgically by marsupialization (removal of the upper half of the cyst).



Conjunctival hemangioma.

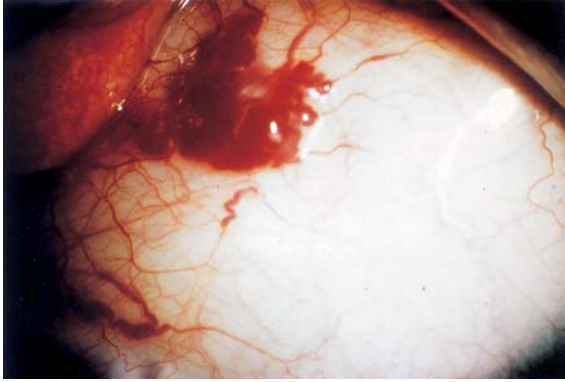


Fig. 4.20 Small cavernous proliferations of blood vessels on the conjunctiva.

Conjunctival cyst.

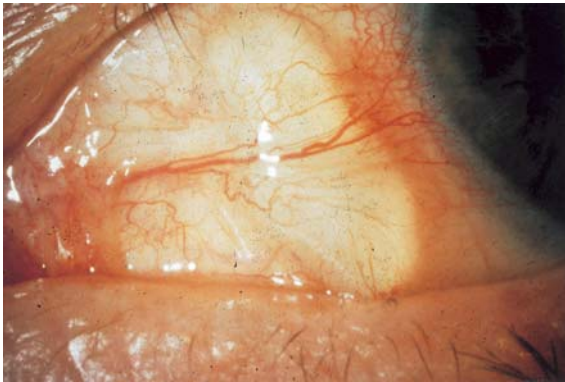


Fig. 4.21 Small, clear, fluid-filled inclusions of conjunctival epithelium.

4.5.3.2 Conjunctival Papilloma

Papillomas are of viral origin (human papillomavirus) and may develop from the bulbar or palpebral conjunctiva. They are *benign and do not turn malignant*. As in the skin, conjunctival papillomas can occur as *branching pediculate* tumors or as *broad-based* lesions on the surface of the conjunctiva (Fig. 4.22). Papillomas produce a permanent foreign-body sensation that is annoying to the patient, and the entire lesion should be surgically removed.



Conjunctival papilloma.

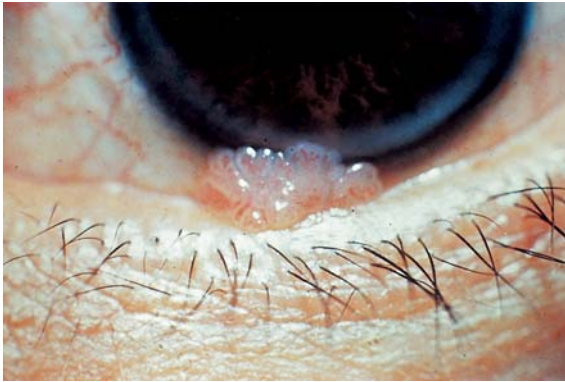

Fig. 4.22 Broad-based papilloma originating from the surface of the palpebral conjunctiva.

4.5.3.3 Conjunctival Carcinoma

Conjunctival carcinomas are usually whitish, raised, thickened areas of epithelial tissue whose surface forms a plateau. These lesions are usually keratinizing squamous cell carcinomas that develop from epithelial dysplasia (precancer) and progress to a carcinoma *in situ* (Fig. 4.23). Conjunctival carcinomas must be excised and a cytologic diagnosis obtained, and the patient must undergo postoperative radiation therapy to prevent growth deep into the orbit.

Conjunctival squamous cell carcinoma.

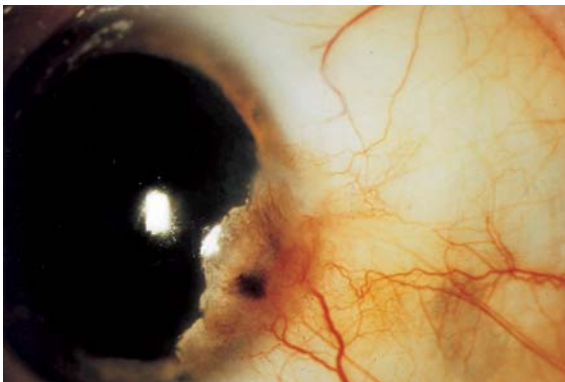


Fig. 4.23 Typical features include the whitish, raised, thickened area of epithelial tissue.



4.5.4 Melanocytic Conjunctival Tumors

4.5.4.1 Conjunctival Nevus

Birthmarks can occur on the conjunctiva as on the skin. They are usually located near the limbus in the temporal portion of the palpebral fissure, less frequently on the lacrimal caruncle. These *benign*, slightly raised epithelial or subepithelial tumors are *congenital*. Fifty percent of nevi contain hollow cystic spaces (pseudocysts) consisting of conjunctival epithelium and goblet cells. Conjunctival nevi may be pigmented (Fig. 4.24a) or unpigmented (Fig. 4.24b), and they may increase in size as the patient grows older. Increasing pigmentation of the nevus as a result of hormonal changes during pregnancy or puberty or from exposure to sunlight can simulate an increase in the size of the nevus, as can proliferation of the pseudocysts. *Conjunctival nevi can degenerate into conjunctival melanomas* (50% of conjunctival melanomas develop from a nevus). Therefore, complete excision and histologic diagnostic studies are indicated if the nevus significantly increases in size or shows signs of inflammation.



Photographs should always be taken during follow-up examinations of conjunctival nevi. Small clear watery inclusion cysts are always a sign of a conjunctival nevus.

4.5.4.2 Conjunctival Melanosis

Definition

Conjunctival melanosis is a pigmented thickening of the conjunctival epithelium (Fig. 4.24c).

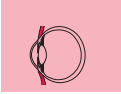
Epidemiology: Conjunctival melanosis is rare like all potentially malignant or malignant tumors of the conjunctiva.

Etiology: Unclear.

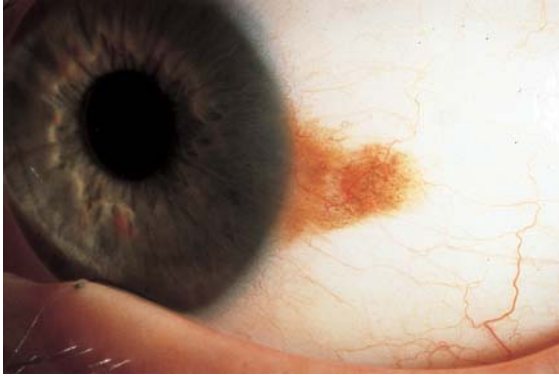Symptoms: Acquired conjunctival melanosis usually occurs after the age of 40. Typical symptoms include irregular diffuse pigmentation and thickening of the epithelium that may “come and go.”

Diagnostic considerations: Acquired conjunctival melanosis is mobile with the conjunctiva (an important characteristic that distinguishes it from congenital melanosis). It requires close observation with follow-up examinations every six months as it can develop into a malignant melanoma.

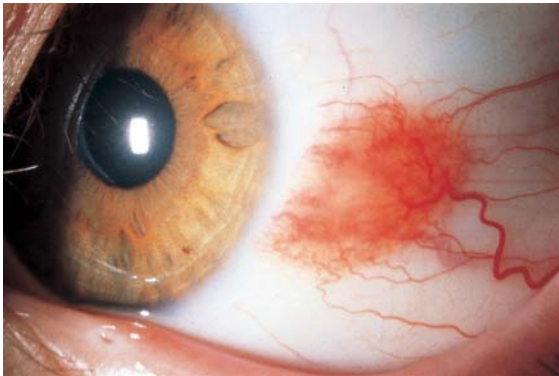
Differential diagnosis: This disorder should be distinguished from *benign congenital melanosis* (see below), which remains stable throughout the patient's lifetime and appears more bluish gray than brownish. In contrast to acquired melanosis, it is not mobile with the conjunctiva.



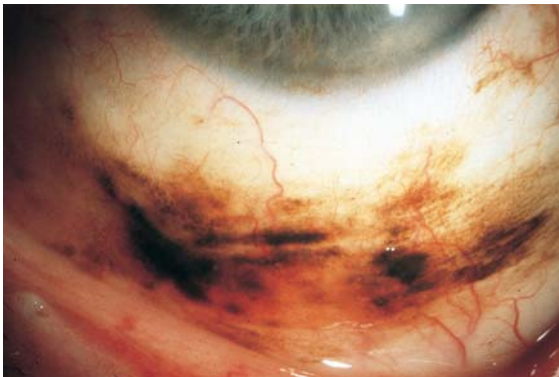Differential diagnosis of pigmented conjunctival changes.



Figs. 4.24 a–j
a Pigmented conjunctival nevus.



b Unpigmented conjunctival nevus.



c Primary acquired melanosis.

Continued →



Differential diagnosis of pigmented conjunctival changes.

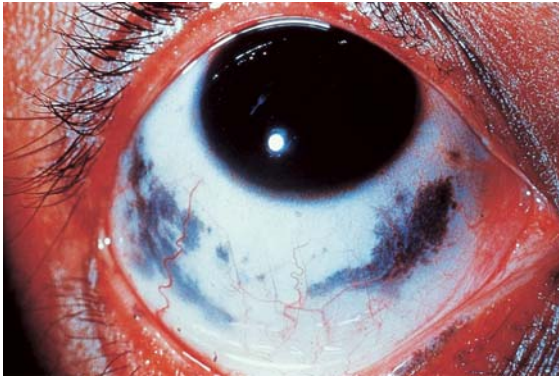
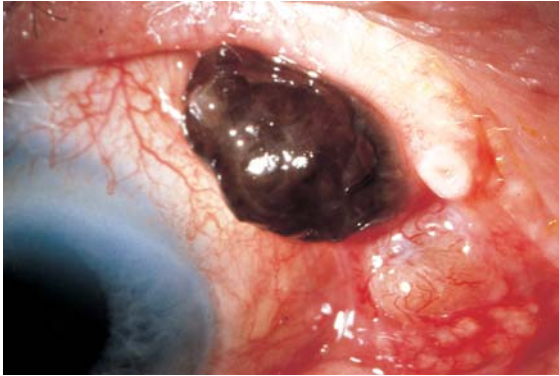
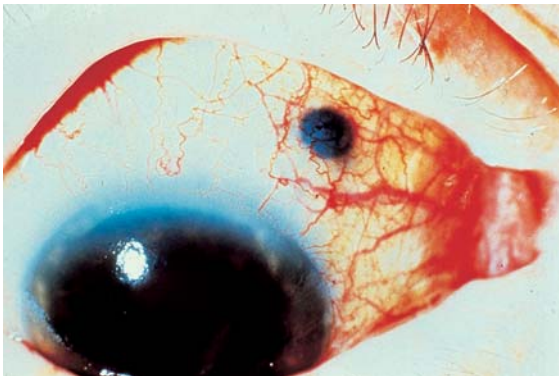

Fig. 4.24 d Con-
genital melanosis.



e Malignant con-
junctival
melanoma.



f Malignant
melanoma of the
ciliary body pen-
etrating beneath
the conjunctiva.



Differential diagnosis of pigmented conjunctival changes.

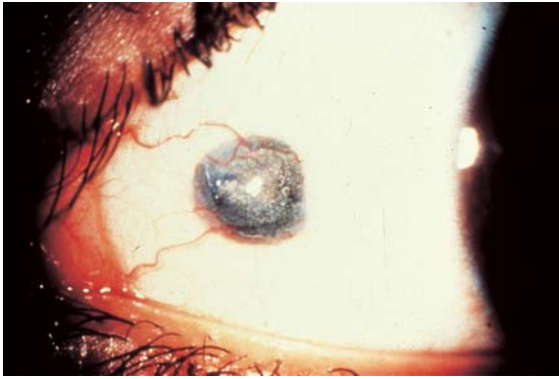
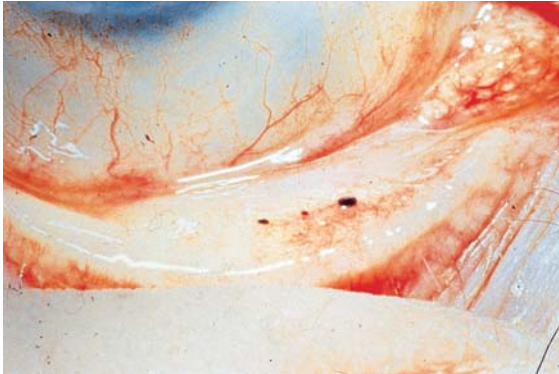
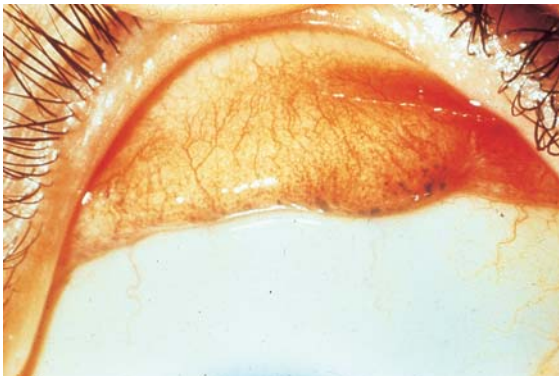


Fig. 4.24 g
Metallic foreign body that has healed within the conjunctiva.



h Adrenochrome deposits (from eyedrops containing epinephrine).



i Iron deposits from make-up (mascara)

Continued →



Differential diagnosis of pigmented conjunctival changes.

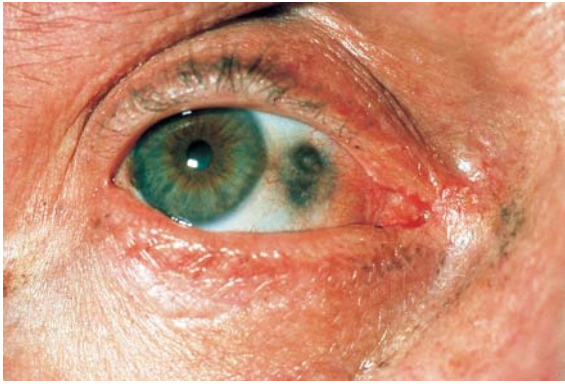


Fig. 4.24j
Ochronosis
(alkaptonuria).

Treatment: Because the disorder occurs diffusely over a broad area, treatment is often difficult. Usually it combines excision of the prominent deeply pigmented portions (for histologic confirmation of the diagnosis) with cryocoagulation of the adjacent melanosis and in some cases with postoperative radiation therapy.

Clinical course and prognosis: About 50% of conjunctival melanomas develop from conjunctival melanosis (the other 50% develop from a conjunctival nevus; see above). Conjunctival melanomas are not usually as aggressively malignant as skin melanomas. The radical resection required to remove the tumor can be a problem. Multiple recurrences will produce significant conjunctival scarring that can result in symblepharon with fusion of the eyelid skin and conjunctiva. Where the tumor has invaded the eyelids or the deeper portions of the orbit, orbital exenteration will be unavoidable to completely remove the tumor.

4.5.4.3 Congenital Ocular Melanosis

Benign congenital melanosis (Fig. 4.24d) is subepithelial in the episclera. The conjunctival epithelium is *not* involved. Pigmentation is bluish gray. In contrast to acquired melanosis, congenital melanosis remains *stable* and *stationary* throughout the patient's lifetime. In contrast to nevi and acquired melanosis, congenital melanosis remains stationary when the conjunctiva above it is moved with forceps. Congenital ocular melanosis can occur as an *isolated anomaly of the eye* or *in association with skin pigmentations* (oculodermal melanosis or Ota's nevus). Although the tumor is benign, evidence suggests



that malignant melanomas in the choroid occur more frequently in patients with congenital melanosis.

4.5.5 Conjunctival Lymphoma

Prominent areas of salmon-colored conjunctival thickening frequently occurring in the inferior fornix (Fig. 4.25) are often the first sign of lymphatic disease. Identifying the specific forms and degree of malignancy requires biopsy and histologic examination. Lesions may range from benign lymphoid hyperplasia to malignant lymphomas that are moderately to highly malignant. Because lymphomas respond to radiation, a combination of radiation therapy and chemotherapy is usually prescribed according to the specific histologic findings.

4.5.6 Kaposi's sarcoma

This is a prominent, light to dark red tumor in the conjunctival fornix or proceeding from the palpebral conjunctiva. It consists of malignant spindle cells and nests of atypical endothelial cells. Today Kaposi's sarcomas are seen most frequently as opportunistic disease in patients with AIDS (**A**cquired **I**mmune **D**eficiency **S**yndrome). The ophthalmologist can make a tentative diagnosis of AIDS on the basis of typical clinical signs on the conjunctiva and order further diagnostic studies (Fig. 4.26). Recently there has been evidence that herpes virus (HHV-8) is involved in the development of Kaposi's sarcoma.

Conjunctival lymphoma.

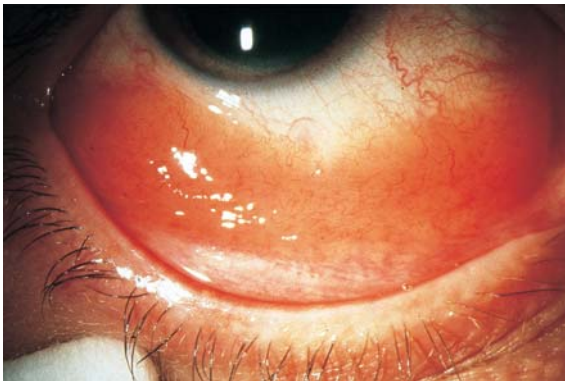

Fig. 4.25 Typical salmon-colored conjunctival tumor in the inferior fornix.

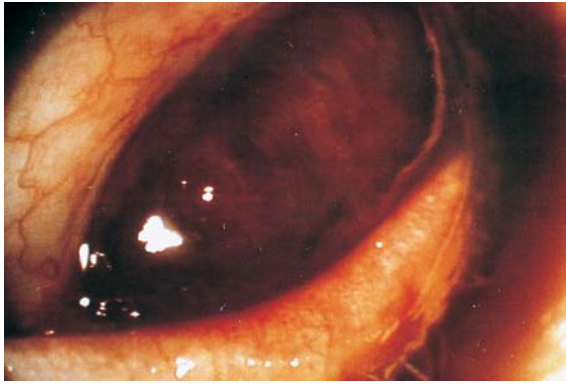**Kaposi's sarcoma.**

Fig. 4.26 Prominent dark red tumor in the conjunctival fornix in a patient with AIDS.

4.6 Conjunctival Deposits

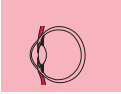
These can occur in both the conjunctiva and cornea. Some, like some tumors, lead to pigmented changes in the conjunctiva. However, their typical appearance usually readily distinguishes them from tumors (Fig. 4.24). The following conjunctival and corneal deposits and discolorations may occur:

Adrenochrome deposit (Fig. 4.24h). Prolonged use of epinephrine eyedrops (as in glaucoma therapy) produces brownish pigmented changes in the inferior conjunctival fornix and on the cornea as a result of epinephrine oxidation products (adrenochrome). This can simulate a melanocytic conjunctival tumor. Therefore, the physician should always ascertain whether the patient has a history of prolonged use of epinephrine eyedrops. No therapy is indicated.

Iron deposits (Fig. 4.24i). In women, iron deposits from eye make-up and mascara are frequently seen to accumulate in the conjunctival sac. No therapy is indicated.

Argyrosis. Prolonged use of silver-containing eyedrops can produce brownish black silver deposits in the conjunctiva.

Ochronosis (alkaptonuria: an inherited autosomal recessive deficiency of the enzyme homogentisate 1,2-dioxygenase). Approximately 70% of all patients with ochronosis exhibit brownish pigmented deposits in the skin of the eyelids, conjunctiva, sclera, and limbus of the cornea (Fig. 4.24j). The deposits increase with time. The disorder cannot be treated in the eye.

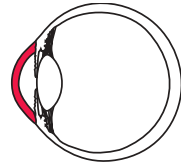


Metallic foreign bodies in the conjunctiva. A metallic foreign body that is not removed immediately will heal into the conjunctiva, where it will simulate a pigmented change in the conjunctiva (Fig. 4.24g). Obtaining a meticulous history (the examiner should always enquire about ocular trauma) will quickly reveal the cause of the anomaly. The foreign body can be removed under topical anesthesia.

Jaundice. This will lead to yellowing of the conjunctiva and sclera.

5 Cornea

Gerhard K. Lang



5.1 Basic Knowledge

Fundamental importance of the cornea for the eye: The cornea is the eye's optical window that makes it possible for humans to see. The ophthalmologist is only able to discern structures in the interior of the eye because the cornea is transparent. At 43 diopters, the cornea is the *most important refractive medium in the eye*.

Shape and location: The cornea's *curvature is greater than the sclera's curvature*. It fits into the sclera like a *watch-glass* with a shallow sulcus (the limbus of the cornea) marking the junction of the two structures.

Embryology: The corneal tissue consists of *five layers*. The cornea and the sclera are formed during the second month of embryonic development. The epithelium develops from ectoderm, and the deeper corneal layers develop from mesenchyme.

Morphology and healing (Fig. 5.1):

- ❖ The **surface** of the cornea is formed by **stratified nonkeratinized squamous epithelium** that regenerates quickly when injured. Within a hour, epithelial defects are closed by cell migration and rapid cell division. However, this assumes that the **limbus stem cells** in the limbus of the cornea are undamaged. Regular corneal regeneration will no longer be possible when these cells are compromised. An intact epithelium protects against infection; a defect in the epithelium makes it easy for pathogens to enter the eye.
- ❖ A thin **basement membrane anchors** the basal cells of the stratified squamous epithelium to **Bowman's layer**. This layer is highly resistant but cannot regenerate. As a result, injuries to Bowman's layer usually produce corneal scarring.
- ❖ Beneath Bowman's layer, many lamellae of collagen fibrils form the **corneal stroma**. The stroma is a highly bradytrophic tissue. As avascular tissue, it only regenerates slowly. However, its avascularity makes it an *immunologically privileged site* for grafting. Routine corneal transplants may be performed without prior tissue typing. An increased risk of rejec-



Anatomy of the cornea.

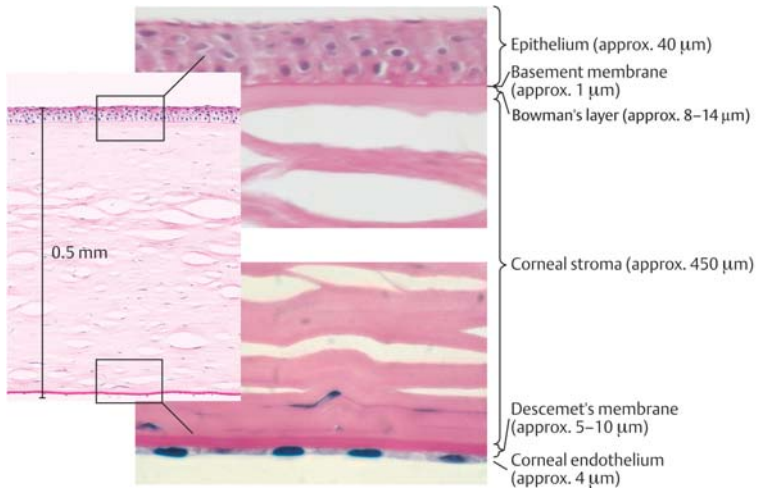


Fig. 5.1 See discussion in text.

tion need only be feared where the *recipient's cornea is highly vascularized* as may be the case following chemical injury or inflammation. Such cases require either a tissue-typed donor graft or immunosuppressive therapy with cyclosporin.

- ❖ Descemet's membrane and the corneal endothelium lie on the posterior surface of the corneal stroma adjacent to the anterior chamber. **Descemet's membrane** is a relatively strong membrane. It will continue to define the shape of the anterior chamber even where the corneal stroma has completely melted (see Descemetocele). Because it is a *genuine basement membrane*, lost tissue is regenerated by functional endothelial cells. The **corneal endothelium** is responsible for the *transparency* of the cornea (see also Transparency below). A high density of epithelial cells is necessary to achieve this. The corneal endothelium does not regenerate; defects in the endothelium are closed by cell enlargement and cell migration.

Diameter: The **normal average diameter of the adult cornea** is 11.5 mm (10–13 mm). A congenitally small cornea (**microcornea**, diameter less than 10.0 mm) or a congenitally large cornea (**megalocornea**, diameter from 13 to 15 mm) is always an abnormal finding (see Corneal Size Anomalies).



Nourishment: The five layers of the cornea have few cells and are unstructured and avascular. Like the lens, sclera, and vitreous body, the cornea is a bradytrophic tissue structure. Its metabolism is slow, which means that healing is slow. The cornea is nourished with nutritive metabolites (amino acids and glucose) from three sources:

1. Diffusion from the **capillaries at its edge**.
2. Diffusion from the **aqueous humor**.
3. Diffusion from the **tear film**.

Significance of the tear film for the cornea: The three-layer precorneal tear film ensures that the surface of the cornea remains smooth and helps to nourish the cornea (see above). Without a tear film, the surface of the epithelium would be rough, and the patient would see a blurred image. The enzyme lysozyme contained in the tear film also protects the eye against infection (see p. 50, for composition of the tear film).

Transparency: This is due to two factors.

1. The **uniform arrangement of the lamellae of collagen fibrils in the corneal stroma** and the smooth endothelial and epithelial surface produced by the intraocular pressure.
2. The **water content of the corneal stroma remains constant at 70%**. The combined action of the epithelium and endothelium maintains a constant water content; the epithelium seals the stroma off from the outside, while the endothelium acts as an ion pump to remove water from the stroma. This requires a *sufficiently high density of endothelial cells*. Endothelial cell density is age-dependent; normally it is approximately 2500 cells per mm^2 . At cell densities below 300 endothelial cells per mm^2 , the endothelium is no longer able to pump water out of the cornea, resulting in edema of the corneal stroma and endothelium.

Protection and nerve supply: The cornea is a vital structure of the eye and as a result extremely sensitive. It receives its *ample sensory supply* from the ophthalmic division of the trigeminal nerve. The slightest tactile sensation causes an eye closing reflex. Any injury to the cornea (erosion, foreign body penetration, or ultraviolet keratoconjunctivitis) exposes sensory nerve endings and causes intense pain with reflexive tearing and involuntary eye closing.



The triad of involuntary eye closing (blepharospasm), reflexive tearing (epiphora), and pain always suggests a possible corneal injury (see Chapter 18).



5.2 Examination Methods

Non-ophthalmologists can evaluate the transparency of the cornea (opacities of the stroma and epithelium suggest scarring or infiltration of the epithelium), its *surface luster* (lack of luster suggests an epithelial defect), and possible *superficial corneal injuries* (see Fig. 19.1). A simple ruler may be used to measure the size of the cornea (see Anatomy), and *sensitivity* may be tested with a cotton swab (see Fig. 1.11, p. 11).

The **ophthalmologist** uses instruments to evaluate corneal morphology and function in greater detail.

5.2.1 Slit Lamp Examination

The slit lamp is the primary instrument used in evaluating the cornea. The ophthalmologist chooses between eight and forty-power magnification for examining all levels of the cornea with a narrow beam of collimated light (Fig. 5.2).

5.2.2 Dye Examination of the Cornea

Defects in the surface of the cornea can be visualized with fluorescein or rose bengal solution (in either case, administer one drop of 1% solution). Since these dyes are not usually absorbed by the epithelium, they may be used to visualize *loss of epithelium over a wide area* (such as corneal erosion) and *extremely fine defects* (as in superficial punctate keratitis). Illumination with a cobalt blue filter enhances the fluorescent effect.

Slit lamp examination of the cornea.

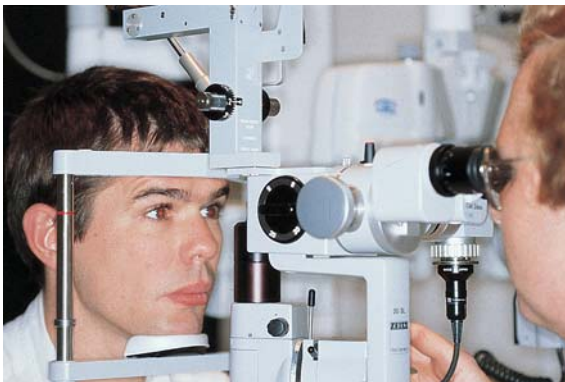

Fig. 5.2 The slit lamp (slit aperture) may be used to examine all levels of the cornea with a narrow beam of collimated light.



These dye methods can reveal corneal epithelial defects (corneal erosion) even without the use of a slit lamp, which is helpful in examining infants.

5.2.3 Corneal Topography

The **keratoscope** (Placido's disk) permits gross evaluation of the **uniformity of the surface of the cornea**. This instrument consists of a round disk marked with concentric black and white rings around a central aperture. The examiner holds the disk in his or her hand and looks through the aperture. The *mirror images of the rings on the patient's cornea* indicate the presence of astigmatism (in which case they appear distorted). However, this inexact evaluation method lacks the precision required for modern applications such as refractive surgery. Therefore, the surface of the cornea is now normally evaluated by **computerized corneal topography** (videokeratoscopy). In this examination, the contours of the cornea are measured by a computer in the same manner as the keratoscope. The refractive values of specific corneal regions are then represented in a color-coded dioptric map. Bright red, for example, represents a steep curvature with a high refractive power. This technique provides a contour map of the distribution of the refractive values over the entire cornea (Figs. 5.3a and b).

5.2.4 Determining Corneal Sensitivity

Non-ophthalmologists may perform a **simple preliminary examination of corneal sensitivity** with a distended cotton swab (see Fig. 1.11, p. 11). This examination also helps the ophthalmologist confirm the diagnosis in the presence of a suspected viral infection of the cornea or trigeminal or facial neuropathy as these disorders are associated with reduced corneal sensitivity. Ophthalmologists may use an automatic Dräger esthesiometer for **precise testing of corneal sensitivity** and for **follow-up examinations**. This instrument can incrementally raise the sensitivity stimulus. This makes it possible to determine if and how rapidly corneal sensitivity increases following a corneal transplant.

5.2.5 Measuring the Density of the Corneal Epithelium

A sufficiently high density of endothelial cells is very important for the transparency of the cornea (see Transparency). **Gross estimation** of the endothelial cell density is possible for a circumscribed area of the cornea using a **slit lamp** and indirect illumination. Both the viewing axis and illumination axis are offset from the visual axis. **Precise quantification** and morphologic evaluation of endothelial cells over large areas is only possible by means of **specular microscopy**, a technique designed especially for this purpose (Fig. 5.4). Exact



Computerized corneal topography (videokeratoscopy).

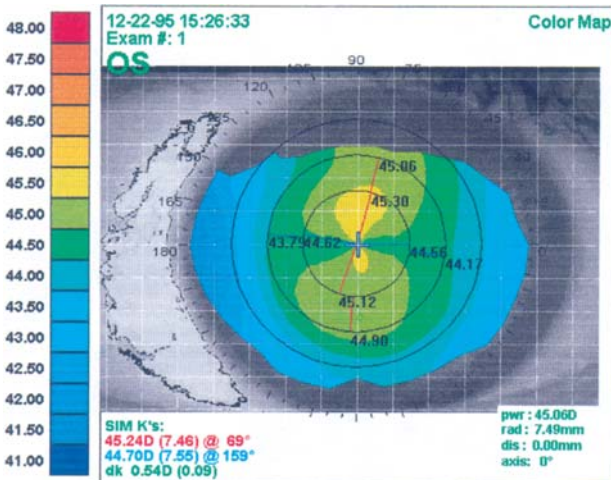
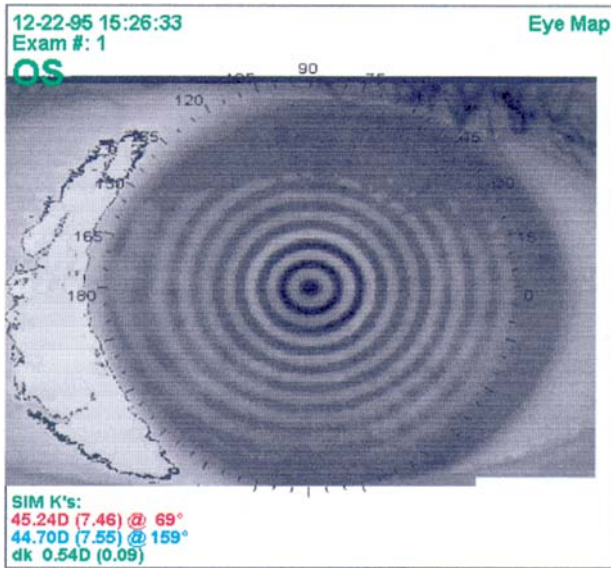


Fig. 5.3 a Regular corneal astigmatism in a normal cornea.



Computerized corneal topography (videokeratometry).

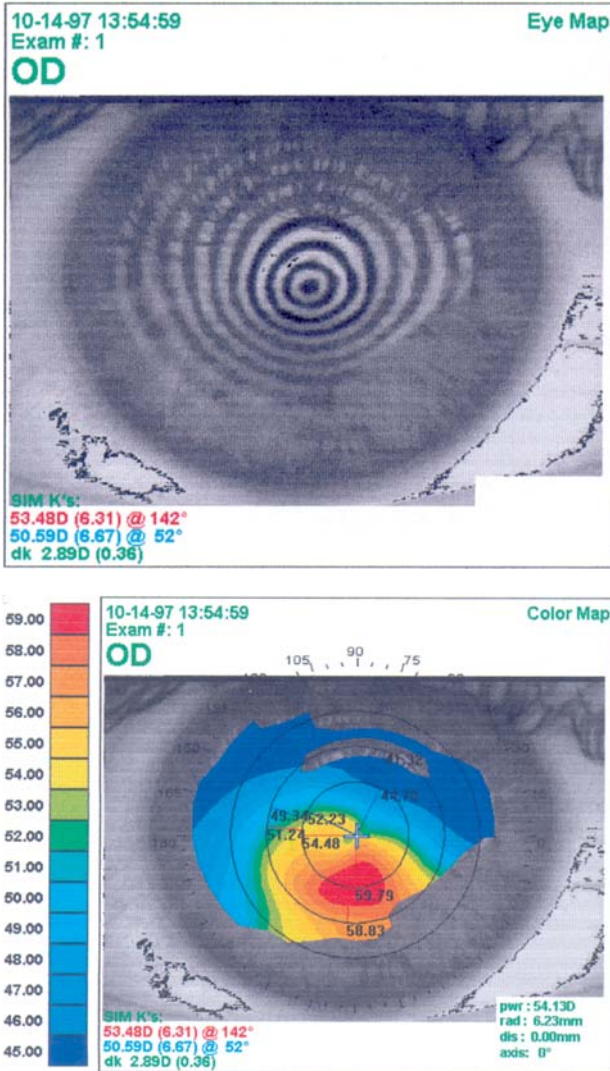


Fig. 5.3 **b** Irregular corneal astigmatism in keratoconus. The Placido disk image is shown above; the respective color mapping of refractive values in diopters is shown below.

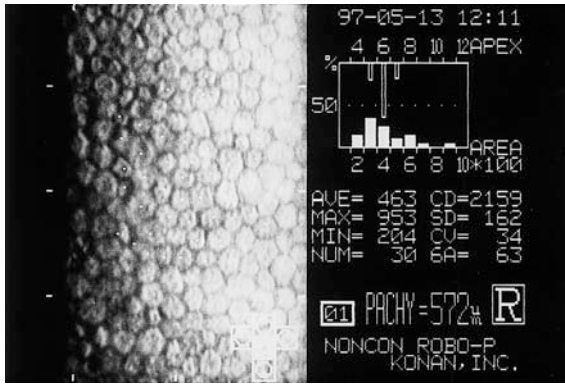
**Automatic measurement of endothelial cell density.**

Fig. 5.4 Specular microscopy permits a precise endothelial cell count (CD = 2159 endothelial cells per mm^2) while simultaneously measuring the thickness of the cornea (pachymetry; pachy = 572 μm).

analysis is necessary when the number of cells appears extremely low under slit lamp examination and the patient is a candidate for cataract surgery. If exact analysis then verifies that the number of cells is extremely low (below 300–400 cells per mm^2), cataract surgery is combined with a corneal transplant. This is done to ensure that the patient will be able to see even after cataract surgery, which sacrifices additional endothelial cells.

5.2.6 Measuring the Diameter of the Cornea

An abnormally large or small cornea (megalocornea or microcornea) will be apparent from simple visual inspection. A suspected size anomaly can be easily verified by **measuring the cornea with a ruler**. Corneal diameter may be determined more accurately with **calipers** (usually done under general anesthesia, see Fig. 10.21) or with the **Wessely keratometer**. This is a type of tube with a condensing lens with millimeter graduations at one end. The examiner places this end on the patient's eye and looks through the other end.

Megalocornea in an infant always requires further diagnostic investigation to determine whether buphthalmos is present. Microcornea may be a sign of congenital defects in other ocular tissues that could result in impaired function (microphthalmos).



5.2.7 Corneal Pachymetry

Precise measurement of the thickness of the cornea is crucial in refractive surgery (see radial keratotomy and correction of astigmatism, p.155). Improving refraction often requires making incisions through 90% of the thickness of the cornea while meticulously avoiding full penetration of the cornea. There are two pachymetry techniques for measuring corneal thickness with the high degree of precision that this surgery requires:

- ❖ Optical pachymetry with a **slit lamp and measuring attachment** may be performed on the sitting patient.
- ❖ **Ultrasonic pachymetry**; this has the advantage of greater precision and can also be performed with the patient supine.

Recent developments now permit pachymetry by means of specular microscopy (see 5.2.8 and Fig. 5.4).

5.2.8 Confocal Corneal Microscopy

Confocal corneal microscopy is a recently developed examination technique that makes it possible to scan the cornea *over a wide area* from the outer layer to the inner layer. It differs in this regard from slit lamp examination, which tends to be a *focal* examination along a shaft of light perpendicular to the eye. Confocal corneal microscopy visualizes cell structures at maximum magnification that cannot be observed in detail with a slit lamp. These include corneal nerves, amebas, and hyphae. Although not yet routinely used in clinical practice, confocal corneal microscopy appears to be a promising examination method for the future.

5.3 Developmental Anomalies

5.3.1 Protrusion Anomalies

5.3.1.1 Keratoconus

Definition

Conical, usually bilateral central deformation of the cornea with parenchymal opacification and thinning of the cornea.

Epidemiology: Keratoconus is the most *frequently encountered* deformation of the cornea. Occurrence is familial, although women are more likely to be affected than men.

Etiology: Keratoconus is probably a genetic disorder. It can occur in families with varying paths of hereditary transmission. Occasionally keratoconus is associated with trisomy 21 syndrome (Down syndrome) as well as with



atopic dermatitis and other connective-tissue disorders such as Marfan's syndrome.

Symptoms: The clinical course of the disorder is episodic; the increasing protrusion of the cornea usually produces bilateral irregular myopic astigmatism (see Fig. 5.3b). Left untreated, in rare cases keratoconus can cause tears of Descemet's membrane due to the continuous stretching. The entire cornea can then bulge out at this site. This is referred to as acute keratoconus. **Symptoms of acute keratoconus** include sudden loss of visual acuity accompanied by intense pain, photophobia, and increased tearing.

Diagnostic considerations: The diagnosis is usually made with a keratoscope or ophthalmometer (reflex images will be irregular). The examiner can also detect keratoconus without diagnostic aids by standing behind the patient and pulling the patient's upper eyelids downward. The conical protrusion of the surface of the cornea (Fig. 5.5) will then be readily apparent due to the deformation of the margin of the eyelid (*Munson's sign*).

Treatment: Degeneration of visual acuity can usually be corrected initially with eyeglasses; hard contact lenses will be required as the disorder progresses. However, after a certain point, the patient repeatedly will lose the contact lenses. Then the only possible treatment is penetrating keratoplasty (transplantation of a corneal graft from a donor into the patient's cornea).

Prognosis: The prognosis for penetrating keratoplasty in treating keratoconus is good because the cornea is avascular in keratoconus.

Keratoconus.

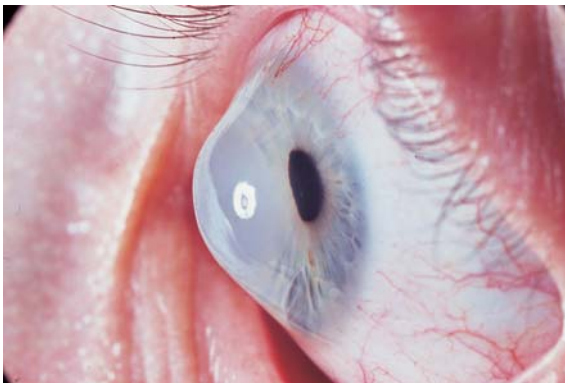


Fig. 5.5 The conical deformation of the cornea is episodic and usually produces bilateral irregular myopic astigmatism (see also Fig. 5.3b).



Keratoglobus.

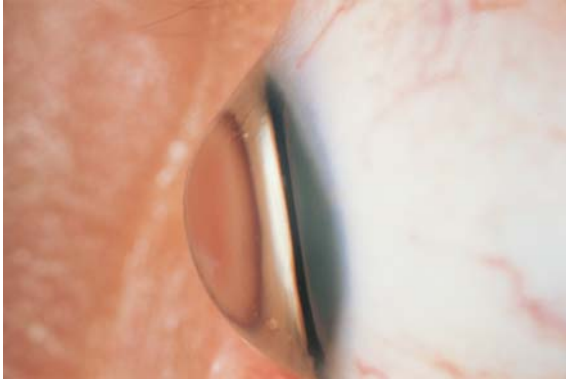


Fig. 5.6 The congenital deformation results in hemispherical protrusion that can lead to myopia.

5.3.1.2 Keratoglobus

Very rare disorders include keratoglobus, a congenital deformation resulting in hemispherical protrusion (Fig. 5.6) that tends to produce myopia, and flattening of the cornea (cornea plana) that tends to produce hyperopia.

5.3.2 Corneal Size Anomalies (Microcornea and Megalocornea)

Corneal size anomalies are usually congenital and on the whole are rare. An abnormally small cornea (**microcornea**) has a diameter less than 10.0 mm). It usually causes severe hyperopia that in advanced age often predisposes the patient to angle closure glaucoma (see Table 10.2, p.236). An abnormally large cornea (**megalocornea**) may be as large as 13–15 mm. Corneal enlargement in the newborn and infants may be acquired due to increased intraocular pressure (buphthalmos). **Combinations of microcornea and megalocornea** together with other ocular deformities may also occur.

5.4 Infectious Keratitis

5.4.1 Protective Mechanisms of the Cornea

As was discussed above, the cornea has certain defensive mechanisms required because of its constant exposure to microbes and environmental influences. The mechanisms include:

- ❖ Reflexive eye closing.
- ❖ Flushing effect of tear fluid (lysozyme).



- ❖ Its hydrophobic epithelium forms a diffusion barrier.
- ❖ Epithelium can regenerate quickly and completely.

5.4.2 Corneal Infections: Predisposing Factors, Pathogens, and Pathogenesis

When certain pathogens succeed in breaching the corneal defenses through superficial injuries or minor epithelial defects, the bradytrophic corneal tissue will respond to the specific pathogen with characteristic keratitis.

Predisposing factors that promote inflammation are:

- ❖ Blepharitis.
- ❖ Infection of the ocular appendages (for example, dacryostenosis accompanied by bacterial infestation of the lacrimal sac).
- ❖ Changes in the corneal epithelial barrier (bullous keratopathy or dry eyes).
- ❖ Contact lenses.
- ❖ Lagophthalmos.
- ❖ Neuroparalytic disorders.
- ❖ Trauma.
- ❖ Topical and systemic immunosuppressive agents.

Pathogens causing corneal infections may include:

- ❖ Viruses.
- ❖ Bacteria.
- ❖ *Acanthamoeba*.
- ❖ Fungi.

Pathogenesis: Once these pathogens have invaded the bradytrophic tissue through a superficial corneal lesion, a typical chain of events will ensue:

- ❖ **Corneal lesion.**
- ❖ Pathogens invade and **colonize the corneal stroma** (red eye).
- ❖ **Antibodies will infiltrate** the site.
- ❖ As a result, the cornea will opacify and the point of entry will open further, revealing the corneal infiltrate.
- ❖ **Irritation of the anterior chamber with hypopyon** (typically pus will accumulate on the floor of the anterior chamber; see Fig. 5.7).
- ❖ The pathogens will infest the entire cornea.
- ❖ As a result the stroma will melt down to Descemet's membrane, which is relatively strong. This is known as a **descemetocele**; only Descemet's membrane is still intact. Descemet's membrane will be seen to protrude anteriorly when examined under a slit lamp.
- ❖ As the disorder progresses, perforation of Descemet's membrane occurs and the aqueous humor will be seen to leak. This is referred to as a **perforated corneal ulcer** and is an indication for immediate surgical intervention (emergency keratoplasty; see p. 152). The patient will notice progressive loss of vision and the eye will be soft.



Bacterial corneal ulcer.

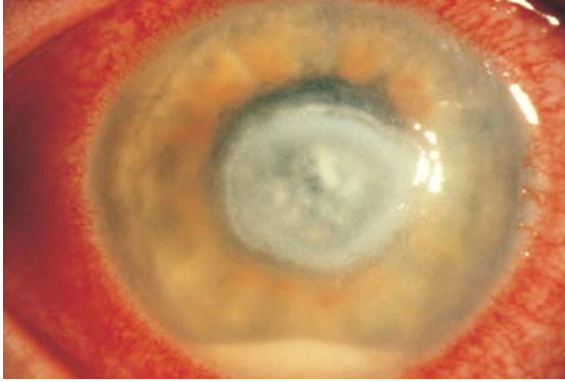
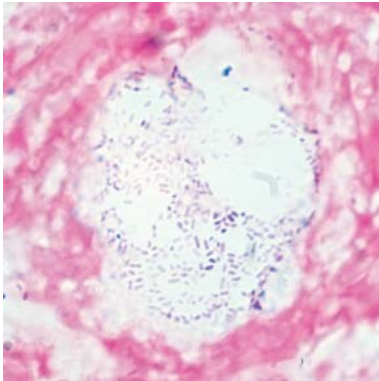


Fig. 5.7 a Clinical findings include a central bacterial corneal ulcer with hypopyon.



b Histologic findings include Gram-positive rod bacteria in the corneal stroma.

- ❖ **Prolapse of the iris** (the iris will prolapse into the newly created defect) closing the corneal perforation posteriorly. Adhesion of the iris will produce a **white corneal scar**.

This sequence of events can vary in speed and severity. Depending on the voracity of the pathogens and the state of the patient's immune system, an infiltrate can form *within a few hours* or days and quickly progress to a corneal ulcer, melting of the stroma, and even a descemetocoele. This rapidly progressing form of infectious corneal ulcer (usually bacterial) is referred to as a **serpiginous corneal ulcer**. It penetrates the cornea particularly rapidly and soon leads to intraocular involvement (the pathogens will be active beyond



the visible rim of the ulcer). A serpiginous corneal ulcer is one of the most dangerous clinical syndromes as it can rapidly lead to loss of the eye.

5.4.3 General Notes on Diagnosing Infectious Forms of Keratitis

Prompt diagnosis and treatment of corneal infections are crucial in avoiding permanent impairment of vision. The diagnosis of any type of infectious keratitis essentially includes the following steps:

- ❖ Identifying the pathogen and testing its resistance. This is done by taking a smear from the base of the ulcer to obtain sample material and inoculating culture media for bacteria and fungi. Wearers of contact lenses should also have cultures taken from the lenses to ensure that they are not the source of the bacteria or fungus.
- ❖ Slides of smears, unstained and treated with Gram and Giemsa stains, are examined to detect bacteria.
- ❖ Where a viral infection is suspected, testing corneal sensitivity is indicated as this will be diminished in *viral* keratitis.

5.4.4 Bacterial Keratitis

Epidemiology: Over 90% of all corneal inflammations are caused by bacteria.

Etiology: The pathogens listed in Table 5.1 are among the most frequent causes of bacterial keratitis in the urban population in temperate climates.

Table 5.1 The most common bacterial pathogens that cause keratitis

Bacterium	Typical characteristics of infection
<i>Staphylococcus aureus</i>	Infection progresses slowly with little pain.
<i>Staphylococcus epidermidis</i>	As in <i>Staphylococcus aureus</i> infection.
<i>Streptococcus pneumoniae</i>	Typical serpiginous corneal ulcer: the cornea is rapidly perforated with early intraocular involvement; very painful.
<i>Pseudomonas aeruginosa</i>	Bluish green mucoid exudate, occasionally with a ring-shaped corneal abscess. Progression is rapid with a tendency toward melting of the cornea over a wide area; painful.
<i>Moraxella</i>	Painless oval ulcer in the inferior cornea that progresses slowly with slight irritation of the anterior chamber.



Most bacteria are unable to penetrate the cornea as long as the epithelium remains intact. Only gonococci and diphtheria bacteria can penetrate an intact corneal epithelium.

Symptoms: Patients report moderate to severe pain (except in *Moraxella* infections; see Table 5.1), photophobia, impaired vision, tearing, and purulent discharge. *Purulent discharge* is typical of *bacterial* forms of keratitis; *viral* forms produce a *watery* discharge.

Diagnostic considerations: Positive identification of the pathogens is crucial. **Serpiginous corneal ulcers** are frequently associated with severe reaction of the anterior chamber including accumulation of cells and pus in the inferior anterior chamber (hypopyon, Fig. 5.7a) and posterior adhesions of the iris and lens (posterior synechia).

Differential diagnosis: Fungi (positive identification of the pathogen is required to exclude a fungus infection).

Treatment:



Because of the risk of perforation, any type of corneal ulcer is an emergency requiring treatment by an ophthalmologist.

Conservative therapy. Treatment is initiated with *topical antibiotics* (such as ofloxacin and polymyxin) with a very broad spectrum of activity against most Gram-positive and Gram-negative organisms until the results of pathogen and resistance testing are known. Immobilization of the ciliary body and iris by therapeutic mydriasis is indicated in the presence of *intraocular irritation* (manifested by hypopyon). Bacterial keratitis can be treated initially on an outpatient basis with eyedrops and ointments.

An *advanced ulcer*, i.e., a protracted clinical course, suggests indolence and poor compliance on the part of the patient. *Hospitalization* is indicated in these cases. Subconjunctival application of antibiotics may be required to increase the effectiveness of the treatment.

Surgical treatment. Emergency keratoplasty is indicated to treat a descemetocele or a perforated corneal ulcer (see emergency keratoplasty, p. 152). Broad areas of superficial necrosis may require a conjunctival flap to accelerate healing. Stenosis or blockage of the lower lacrimal system that may impair healing of the ulcer should be surgically corrected.



As soon as the results of bacteriologic and resistance testing are available, the physician should verify that the pathogens will respond to current therapy.

Failure of keratitis to respond to treatment may be due to one of the following **causes**, particularly if the pathogen has not been positively identified.



1. The patient is not applying the antibiotic (poor compliance).
2. The pathogen is resistant to the antibiotic.
3. The keratitis is not caused by bacteria but by one of the following pathogens:
 - ❖ Herpes simplex virus.
 - ❖ Fungi.
 - ❖ *Acanthamoeba*.
 - ❖ Rare specific pathogens such as *Nocardia* or mycobacteria (as these are very rare, they are not discussed in further detail in this chapter).

5.4.5 Viral Keratitis

Viral keratitis is frequently caused by:

- ❖ Herpes simplex virus.
- ❖ Varicella-zoster virus.
- ❖ Adenovirus.

Other *rare* causes include cytomegalovirus, measles virus, or rubella virus.

5.4.5.1 Herpes Simplex Keratitis

Epidemiology and pathogenesis: Herpes simplex keratitis is among the more common causes of corneal ulcer. About 90% of the population are carriers of the herpes simplex virus. A typical feature of the ubiquitous herpes simplex virus is an unnoticed primary infection that often heals spontaneously. Many people then remain carriers of the neurotropic virus, which can lead to recurrent infection at any time proceeding from the trigeminal ganglion. *A corneal infection is always a recurrence.* A primary herpes simplex infection of the eye will present as blepharitis or conjunctivitis. Recurrences may be triggered by external influences (such as exposure to ultraviolet light), stress, menstruation, generalized immunologic deficiency, or febrile infections.

Symptoms: Herpes simplex keratitis is usually *very painful* and associated with photophobia, lacrimation, and swelling of the eyelids. Vision may be impaired depending on the location of findings, for example in the presence of central epitheliitis.

Forms and diagnosis of herpes simplex keratitis: The following forms of herpes simplex keratitis are differentiated according to the specific layer of the cornea in which the lesion is located. Recurrences are more frequent in the stroma and endothelium.

Dendritic keratitis. This is characterized by branching epithelial lesions (necrotic and vesicular swollen epithelial cells, Fig. 5.8). These findings will be *visible with the unaided eye* after application of fluorescein dye and are



Herpes simplex keratitis: dendritic keratitis.

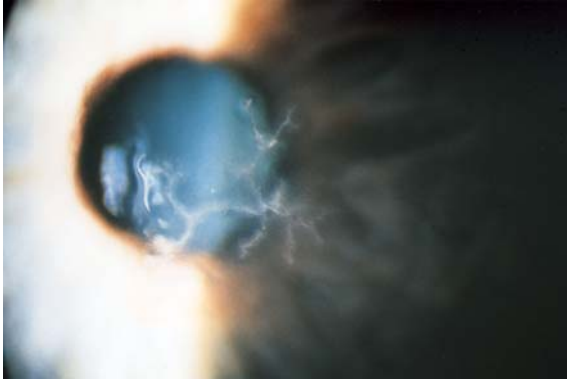


Fig. 5.8 Characteristic findings include branching epithelial lesions.

characteristic of dendritic keratitis. Corneal sensitivity is usually reduced. Dendritic keratitis may progress to stromal keratitis.

Stromal Keratitis. Purely stromal involvement without prior dendritic keratitis is characterized by an intact epithelium that will not show any defects after application of fluorescein dye. Slit lamp examination will reveal central *diskiform* corneal infiltrates (diskiform keratitis) with or without a whitish stromal infiltrate. Depending on the frequency of recurrence, superficial or deep vascularization may be present. Reaction of the anterior chamber will usually be accompanied by endothelial plaques (protein deposits on the posterior surface of the cornea that include phagocytized giant cells).

Endotheliitis. Endotheliitis or endothelial keratitis is caused by the presence of herpes viruses in the aqueous humor. This causes swelling of the endothelial cells and opacification of the adjacent corneal stroma. Involvement of the endothelial cells in the angle of the anterior chamber causes a secondary increase in intraocular pressure (*secondary glaucoma*). Other findings include inflamed cells and pigment cells in the anterior chamber, and endothelial plaques; involvement of the iris with segmental loss of pigmented epithelium is detectable by slit lamp examination.

Acute retinal necrosis syndrome. Involvement of the posterior eyeball (see herpetic retinitis) for all practical purposes is seen only in immunocompromised patients (e.g., recipients of bone marrow transplants and AIDS patients).

Treatment: Infections involving the **epithelium** are treated with trifluridine as a superficial virostatic agent. **Stromal and intraocular herpes simplex**



infections can be treated with acyclovir, which is available for topical use (in ointment form) and systemic use.



Corticosteroids are contraindicated in epithelial herpes simplex infections but may be used to treat stromal keratitis where the epithelium is intact.

5.4.5.2 Herpes Zoster Keratitis

Definition

Keratitis due to endogenous recurrence of chickenpox (caused by the varicella-zoster virus; see herpes zoster ophthalmicus).

Etiology: Proceeding from the trigeminal ganglion, the virus reinfects the region supplied by the trigeminal nerve. The eye is only affected where the ophthalmic division of the trigeminal nerve is involved. In this case, the nasociliary nerve supplying the interior of the eye will also be affected. Hutchinson's sign, vesicular lesions on the tip of the nose, will be present (see Fig. 2.14).

Diagnostic considerations: Herpes zoster ophthalmicus also occurs in superficial and deep forms, which in part are similar to herpes simplex infection of the cornea (red eye with dendritic keratitis, stromal keratitis, and keratouveitis). Corneal sensitivity is usually decreased or absent.

Treatment: The eye is treated with acyclovir ointment in consultation with a dermatologist, who will usually treat skin changes with systemic acyclovir (in the form of infusions or tablets). If the corneal epithelium is intact, the irritation of the anterior chamber can be carefully treated with steroids and immobilization of the pupil and ciliary body by therapeutic mydriasis.

5.4.6 Mycotic Keratitis

Epidemiology: Mycotic keratitis was once very rare, occurring almost exclusively in farm laborers (see Etiology for contact with possible causative agents). However, this clinical syndrome has become far more prevalent today as a result of the increased and often unwarranted use of antibiotics and steroids.

Etiology: The most frequently encountered pathogens are *Aspergillus* and *Candida albicans*. The most frequent causative mechanism is an injury with fungus-infested organic materials such as a tree branch.

Symptoms: Patients usually have only slight symptoms.

Diagnostic considerations: The red eye is apparent upon **inspection** (normally the disorder is unilateral), as is a corneal ulcer with an undermined



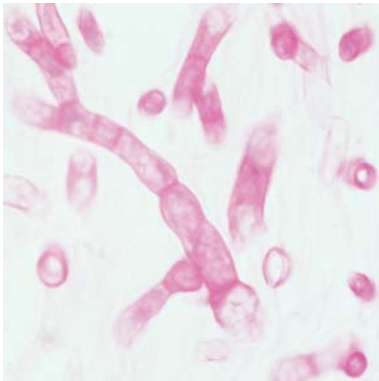
margin (Fig. 5.9). The ulcer will continue to expand beneath the visible margins (serpiginous corneal ulcer). Hypopyon may also be present (as shown in Fig. 5.9a). **Slit lamp** examination will reveal typical whitish stromal infiltrates, especially with mycotic keratitis due to *Candida albicans*. The infiltrates and ulcer spread very slowly. *Satellite lesions*, several adjacent smaller infiltrates grouped around a larger center, are characteristic but will not necessarily be present.

Identification of the pathogen. *Microbiological* identification of fungi is difficult and can be time consuming (for *histologic* identification, see Fig. 5.9b). It is important to obtain samples from beyond the visible margin of the ulcer. Fungal cultures should always be obtained where bacterial cultures are negative.

Mycotic keratitis.

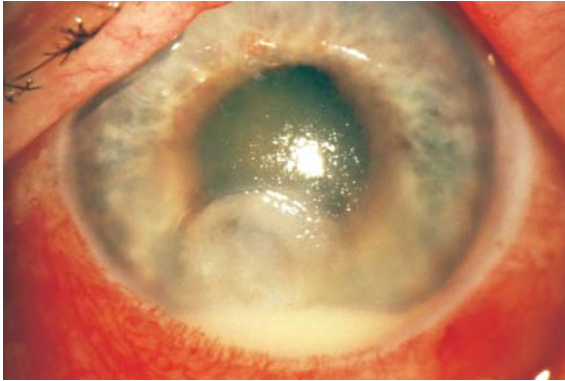

Fig. 5.9 a Clinical findings include a corneal ulcer that extends beyond the visible margin and hypopyon.



b Histologic findings include hyphae in the corneal stroma.

**Treatment:**

Conservative treatment. *Hospitalization* is recommended when beginning treatment as the disorder requires protracted therapy. Systemic therapy is only indicated in the case of an intraocular involvement. Other cases will respond well to topical treatment with antimycotic agents such as natamycin, nystatin, and amphotericin B. In general, the topical antimycotic agents will have to be specially prepared by the pharmacist.

Surgical treatment. Emergency keratoplasty (see p. 152) is indicated when the disorder fails to respond or responds too slowly to conservative treatment and findings worsen under treatment.

5.4.7 Acanthamoeba Keratitis

Epidemiology: This is a rare type of keratitis and one which may have been diagnosed too rarely in the past.

Etiology: *Acanthamoeba* is a saprophytic protozoan. Infections usually occur in *wearers of contact lenses*, particularly in conjunction with trauma and moist environments such as saunas.

Symptoms: Patients complain of intense pain, photophobia, and lacrimation.

Diagnostic considerations: The patient will often have a history of several weeks or months of unsuccessful antibiotic treatment.

Inspection will reveal a unilateral reddening of the eye. Usually there will be no discharge. The infection *can* present as a subepithelial infiltrate, as an intrastromal disciform opacification of the cornea, or as a ring-shaped corneal abscess (Fig. 5.10a).

The disorder is difficult to diagnose, and even immunofluorescence studies in specialized laboratories often fail to provide diagnostic information. Amebic cysts can be readily demonstrated only by histologic and pathologic studies of excised corneal tissue (Fig. 5.10b). Recently it has become possible to demonstrate amebic cysts with the aid of **confocal corneal microscopy** (see p. 125). Patients who wear contact lenses should have them sent in for laboratory examination.

Treatment:

Conservative treatment. Topical agents currently include propamidine (only available through international pharmacies as Prolene) and pentamidine, which must be prepared by a pharmacist. Usually broad-spectrum antibiotic eyedrops are also administered. Cycloplegia (immobilization of the pupil and ciliary body) is usually required as well.

Surgical treatment. Emergency keratoplasty (see p. 152) is indicated when conservative treatment fails.

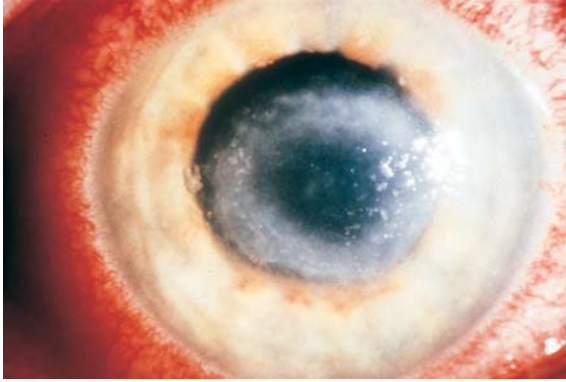
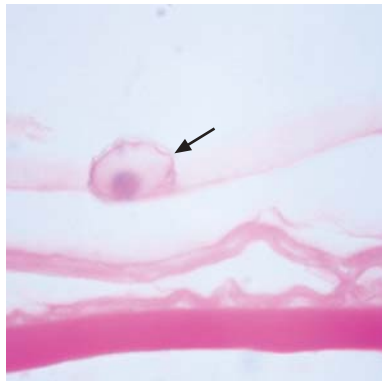
**Acanthamoeba keratitis.**

Fig. 5.10 a Clinical findings include keratitis with a ring-shaped corneal abscess.



b Histologic findings after keratoplasty include typical double-walled amebic cysts in the corneal stroma above Descemet's membrane (arrow).

5.5 Noninfectious Keratitis and Keratopathy

This category encompasses a wide variety of corneal disorders, some of which, such as keratoconjunctivitis sicca, occur very frequently. **Causes include:**

- ❖ Inflammations (blepharitis and conjunctivitis).
- ❖ Injuries (rubbing the eyes, foreign bodies beneath the upper eyelid, contact lens incompatibility, exposure to intense ultraviolet irradiation).
- ❖ Age-related changes (senile ectropion with trichiasis; spastic entropion; keratoconjunctivitis sicca).
- ❖ Surgery (cataract or glaucoma).



- ❖ Endogenous factors (facial neuropathy).
- ❖ Exogenous factors (medications or preservatives).

5.5.1 Superficial Punctate Keratitis

Definition

Superficial punctate corneal lesions due to lacrimal system dysfunction from a number causes (see etiology).

Epidemiology and etiology: Superficial punctate keratoconjunctivitis is a *very frequent finding* as it can be caused by a wide variety of exogenous factors such as foreign bodies beneath the upper eyelid, contact lenses, smog, etc. It may also appear as a secondary symptom of many other forms of keratitis (see the forms of keratitis discussed in the following section). It can also occur in association with an endogenous disorder such as Thygeson's disease.

Symptoms: Depending on the cause and severity of the superficial corneal lesions, symptoms range from a nearly asymptomatic clinical course (such as in neuroparalytic keratitis in which the cornea loses its sensitivity) to an intense foreign body sensation in which the patient has a sensation of sand in the eye with typical signs of epiphora, severe pain, burning, and blepharospasm. Visual acuity is usually only minimally compromised.

Diagnostic considerations and differential diagnosis: Fluorescein dye is applied and the eye is examined under a slit lamp. This visualizes fine epithelial defects. The specific dye patterns that emerge give the ophthalmologist information about the etiology of the punctate keratitis (Figs. 5.11 a – i).

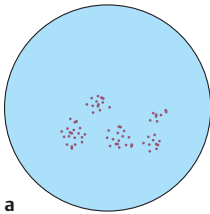
Treatment and prognosis: Depending on the cause, the superficial corneal changes will respond rapidly or less so to *treatment with artificial tears*, whereby every effort should be made to eliminate the causative agents (Fig. 5.11). Depending on the severity of findings, artificial tears of varying viscosity (ranging from eyedrops to high-viscosity gels) are prescribed and applied with varying frequency. In exposure keratitis, a high-viscosity gel or ointment is used because of its long retention time; superficial punctate keratitis is treated with eyedrops.

Keratoconjunctivitis Sicca

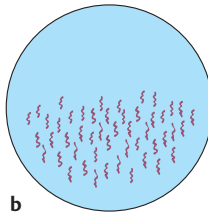
This is one of the most frequent causes of superficial keratitis. The syndrome itself is attributable to dry eyes due to lack of tear fluid and is discussed in Chapter 3.



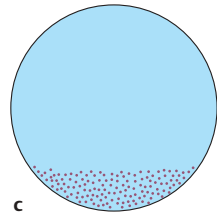
Superficial punctate keratitis.



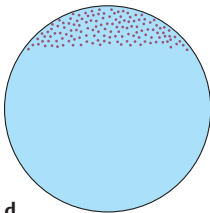
a
Superficial punctate
keratitis



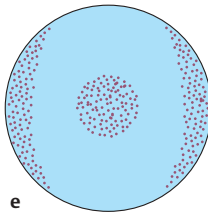
b
Filamentary keratitis



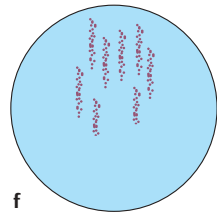
c
Entropion



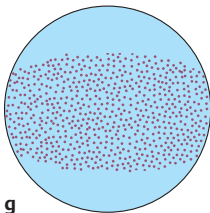
d
Thygeson's disease



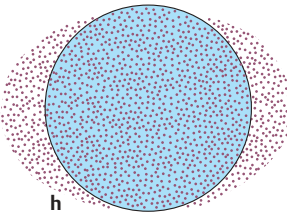
e
Contact lens lesions



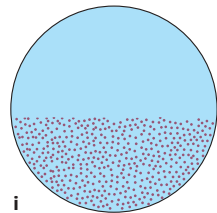
f
Foreign bodies beneath
the upper eyelid



g
Exposure to intense
ultraviolet irradiation



h
Toxic conjunctivitis



i
Exposure or ectropion

Fig. 5.11 Typical dye patterns in the various forms of superficial punctate keratitis. The cause of the disorder can be inferred from the specific pattern of corneal lesions.



5.5.2 Exposure Keratitis

Definition

Keratitis resulting from drying of the cornea in the case of lagophthalmos.

Epidemiology: Exposure keratitis is a relatively frequent clinical syndrome. For example, it may occur in association with facial paralysis following a stroke.

Etiology: Due to **facial nerve palsy**, there is insufficient closure of the eyelids over the eyeball (lagophthalmos), and the inferior third to half of the cornea remains exposed and unprotected (exposure keratitis). Superficial punctate keratitis (see above) initially develops in this region and can progress to corneal erosion (see Fig. 18.5) or ulcer.

Other **causes for exposure keratitis without facial nerve palsy** include:

- ❖ Uncompensated exophthalmos in Graves' disease.
- ❖ Insufficient eyelid closure following eyelid surgery to correct ptosis.
- ❖ Insufficient eye care in patients receiving artificial respiration on the intensive care ward.

Symptoms: Similar to superficial punctate keratitis (although usually more severe) but *unilateral*.

Diagnostic considerations: Application of fluorescein dye will reveal a typical pattern of epithelial lesions (Fig. 5.11 i).

Treatment: Application of artificial tears is usually not sufficient where eyelid motor function is impaired. In such cases, *high-viscosity gels*, *ointment packings* (for antibiotic protection), and a *watch glass bandage* are required. The watch glass bandage must be applied so as to create a moist airtight chamber that prevents further desiccation of the eye (see Fig. 2.9). In the presence of persistent facial nerve palsy that shows no signs of remission, *lateral tarsorrhaphy* is the treatment of choice. The same applies to treatment of exposure keratitis due to insufficient eyelid closure from other causes (see Etiology).



Poor corneal care in exposure keratitis can lead to superficial punctate keratitis, erosion, bacterial superinfection with corneal ulcer, and finally to corneal perforation.



5.5.3 Neuroparalytic Keratitis

Definition

Keratitis associated with palsy of the ophthalmic division of the trigeminal nerve.

Epidemiology: Palsy of the ophthalmic division of the trigeminal nerve is less frequent than facial nerve palsy.

Etiology: The trigeminal nerve is responsible for the cornea's sensitivity to exogenous influences. A conduction disturbance in the trigeminal nerve is usually a *sequela of damage to the trigeminal ganglion* from trauma, radiation therapy of an acoustic neurinoma, or surgery. It will lead to *loss of corneal sensitivity*. As a result of this loss of sensitivity, the patient will not feel any sensation of drying in the eye, and the blinking frequency drops below the level required to ensure that the cornea remains moist. As in exposure keratitis, superficial punctate lesions will form initially, followed by larger epithelial defects that can progress to a corneal ulcer if bacterial superinfection occurs.

Symptoms: Because patients with loss of trigeminal function are free of pain, they will experience only slight symptoms such as a foreign body sensation or an eyelid swelling.

Diagnostic considerations: Corneal damage, usually central or slightly below the center of the cornea, may range from superficial punctate keratitis (visible after application of fluorescein dye) to a deep corneal ulcer with perforation. The eye will be red and in extreme cases may be leaking aqueous humor.

Differential diagnosis: Corneal ulcer due to herpes virus infection.

Treatment: This is essentially *identical to treatment of exposure keratitis*. It includes moistening the cornea, antibiotic protection as prophylaxis against infection, and, if conservative methods are unsuccessful, tarsorrhaphy.

Primary and Recurrent Corneal Erosion

These changes are generally the result of a corneal trauma and are dealt with in the chapter on ocular trauma.

5.5.4 Problems with Contact Lenses

Etiology: These problems occur either with *poorly seated rigid contact lenses* that rub on the surface of the cornea or from *overwearing soft contact lenses*.



Giant papillae from contact lens incompatibility.

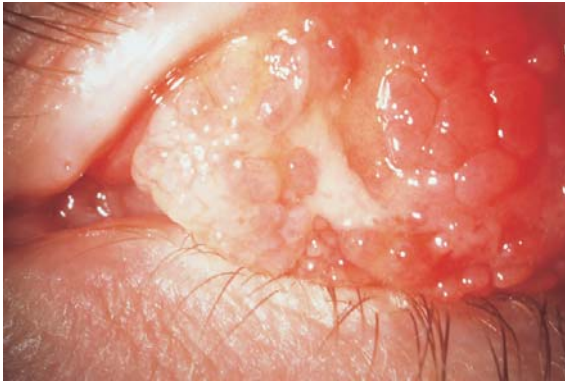

Fig. 5.12 Wart-like protrusions of connective tissue on the palpebral conjunctiva due to contact lens or preservative incompatibility (with simple eversion of the upper eyelid).

If contact lenses are worn for extended periods of time despite symptoms, severe inflammation, corneal ulceration, and vascularization of the corneal periphery may result.

Symptoms: Patients find the contact lenses increasingly uncomfortable and notice worsening of their vision. These symptoms are especially pronounced after removing the contact lenses as the lenses mask the defect in the corneal epithelium.

Diagnostic considerations: The ophthalmologist will detect typical corneal changes after applying fluorescein dye (Fig. 5.11 e). Keratoconjunctivitis on the superior limbus with formation of giant papillae, wart-like protrusions of connective tissue frequently observed on the superior tarsus (Fig. 5.12), are signs of contact lens or preservative incompatibility.

Treatment: The patient should temporarily discontinue wearing the contact lenses, and inflammatory changes should be controlled with steroids until the irritation of the eye has abated.



Protracted therapy with topical steroids should be monitored regularly by an ophthalmologist as superficial epithelial defects heal poorly under steroid therapy. Protracted high-dosage steroid therapy causes a secondary increase in intraocular pressure and cataract in one-third of all patients.

The specific ophthalmologic findings will determine whether the patient should be advised to permanently discontinue wearing contact lenses or whether changing contact lenses and cleaning agents will be sufficient.



5.5.5 Bullous Keratopathy

Definition

Opacification of the cornea with epithelial bullae due to loss of function of the endothelial cells.

Epidemiology: Bullous keratopathy is among the most frequent indications for corneal transplants.

Etiology: The transparency of the cornea largely depends on a functioning endothelium with a high density of endothelial cells (see Transparency). Where the endothelium has been severely damaged by inflammation, trauma, or major surgery in the anterior eye, the few remaining endothelial cells will be unable to prevent *aqueous humor from entering the cornea*. This results in hydration of the cornea with stromal edema and epithelial bullae (see Figs. 5.13a and b). Loss of endothelial cells may also have genetic causes (see Fuchs' endothelial dystrophy).

Symptoms: The gradual loss of endothelial cells causes *slow deterioration of vision*. The patient typically will have poorer vision in the morning than in the evening, as corneal swelling is greater during the night with the eyelids closed.

Diagnostic considerations: Slit lamp examination will reveal thickening of the cornea, epithelial edema, and epithelial bullae.

Differential diagnosis: Bullous keratopathy can also occur with glaucoma. However, in these cases the intraocular pressure is typically increased.

Treatment: Where the damage to the endothelial cells is not too far advanced and only occasional periods of opacification occur (such as in the morning), *hyperosmolar solutions* such as 5% Adisorbonac can improve the patient's eyesight by removing water. However, this is generally only a temporary solution. Beyond a certain stage a *corneal transplant* (penetrating keratoplasty; see p. 152) is indicated.



Bullous keratopathy.

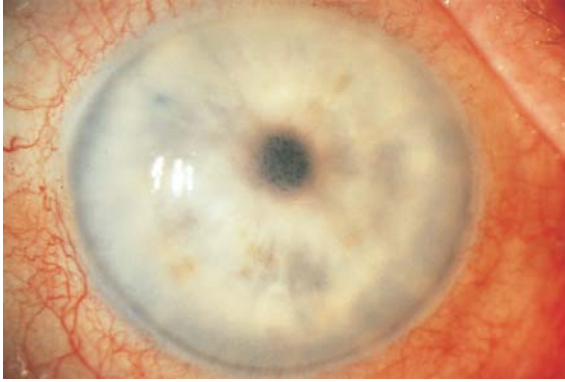


Fig. 5.13
a Corneal edema due to a lack of endothelial cells.



b Image obtained by specular microscopy shows destruction of the endothelial cells (right side of image). In comparison, the left side (a wide-angle view) and the middle (magnified view) of the image show an intact endothelium with a clearly visible honeycomb structure. The actual size of the area shown on the left side of the image is about 0.5 mm².



5.6 Corneal Deposits, Degenerations, and Dystrophies

As bradytrophic avascular tissue, the cornea is particularly susceptible to deposits of foreign material and degeneration (see 5.6.2).

5.6.1 Corneal Deposits

5.6.1.1 Arcus Senilis

This is a **grayish-white ring-shaped fatty deposit near the limbus** that can occur at any age but usually appears in advanced age (Fig. 5.14). Arcus senilis is *usually bilateral* and is a frequently encountered phenomenon. It occurs as a result of lipid deposits from the vessels of the limbus along the entire periphery of the cornea, which normally increase with advanced age. A lipid-free clear zone along the limbus will be discernible. Patients younger than 50 years who develop arcus senilis should be examined to exclude hypercholesterolemia as a cause. Arcus senilis *requires no treatment* as it does not cause any visual impairments.

The **deposits and pigmentations** discussed in the following section do not generally impair vision.

5.6.1.2 Corneal Verticillata

Bilateral gray or brownish epithelial deposits that extend in a swirling pattern from a point inferior to the pupil. This corneal change typically occurs with the use of certain *medications*, most frequently with chloroquine and amio-

Arcus senilis.

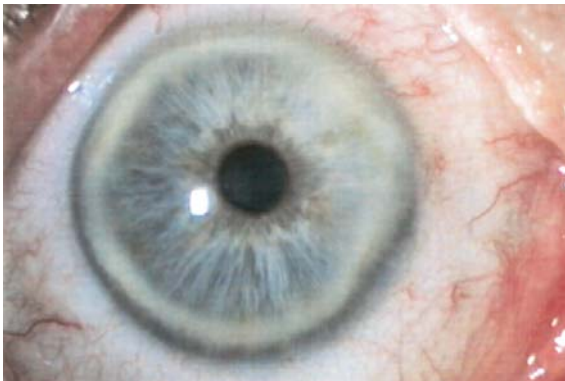

Fig. 5.14 Typical grayish-white, ring-shaped fatty deposits near the limbus.



darone. *Fabry's disease* (glycolipid lipidosis) can also exhibit these kinds of corneal changes, which can help to confirm the diagnosis.

5.6.1.3 Argyrosis and Chrysiasis

Topical medications containing silver and habitual exposure to silver in electroplating occupations lead to *silver deposits in the conjunctiva and the deep layers of the cornea* (**argyrosis**). Systemic gold therapy (more than 1–2 g) will lead to *gold coloration of the peripheral corneal stroma* (**chrysiasis**).

5.6.1.4 Iron Lines

Any irregularity in the surface of the cornea causes the eyelid to distribute the tear film irregularly over the surface of the cornea; a small puddle of tear fluid will be present at the site of the irregularity. *Iron deposits* form in a characteristic manner at this site in the corneal epithelium. The most frequently observed iron lines are the **physiologic iron deposits** at the site where the eyelids close (the Hudson-Stähli line), Stocker-Busacca line with pterygium, Ferry's line with a filtering bleb after glaucoma surgery, and Fleischer ring with keratoconus. Iron lines have also been described **following surgery** (radial keratotomy; photorefractive keratectomy; keratoplasty) and **in the presence of corneal scars**.

5.6.1.5 Kayser-Fleischer Ring

This **golden brown to yellowish green corneal ring** is caused by copper deposits at the level of Descemet's membrane in Wilson's disease (liver and lens degeneration with decreased serum levels of ceruloplasmin). This ring is so characteristic that the ophthalmologist often is the first to diagnose this rare clinical syndrome.

5.6.2 Corneal Degeneration

5.6.2.1 Calcific Band Keratopathy

After many years of chronic inflammation of the anterior chamber (chronic uveitis and keratitis) with shrinkage of the eyeball or in patients with juvenile polyarthritis, *calcific deposits occur in Bowman's layer*, causing a **transverse zone of opacification in the region of the palpebral fissure**. The limbus region will remain clear (Fig. 5.15). This change *significantly* impairs vision. The opacification can be completely removed and vision restored by chelating the calcifications with a sodium EDTA solution.



Calcific band keratopathy.

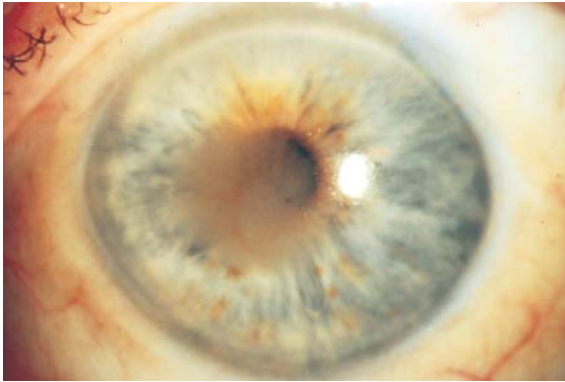
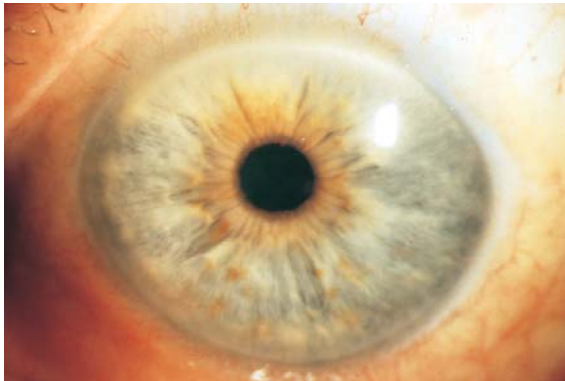


Fig. 5.15
a Brownish-white calcific deposits occur in Bowman's layer, severely impairing the patient's vision.



b Findings after chelation of the calcific deposits with an EDTA solution.

5.6.2.2 Peripheral Furrow Keratitis

This includes a *heterogeneous group of disorders in terms of morphology and etiology*. All are noninfectious and lead to **thinning and melting of the peripheral cornea** that may progress to perforation. *Etiologic* factors include:

- ❖ Autoimmune processes (collagenosis, marginal keratitis, and sclerokeratitis).
- ❖ Trophic dysfunctions (pitting due to lack of tear film).
- ❖ Unknown degenerative processes (Terrien's marginal degeneration or Mooren's ulcer).



These corneal changes are most frequently observed in *patients with rheumatoid arthritis*. Treating the underlying disorder is essential in these cases. Otherwise the changes are rare. **Keratomalacia** is a **special form** of the disorder in which *vitamin A deficiency* causes xerosis of the conjunctiva combined with night blindness. This disorder remains one of the most frequent causes of blindness in the developing countries in which malnutrition is prevalent.

5.6.3 Corneal Dystrophies

Definition

This term refers to a group of corneal metabolic dysfunctions that always lead to *bilateral* opacification of the various layers of the cornea (see Classification below).

Epidemiology: Corneal dystrophy tends to be *rare*. The most frequent form is Fuchs' endothelial dystrophy, followed by dystrophy in the corneal stroma.

Etiology: The various corneal dystrophies are *genetic disorders*. They usually manifest themselves in the first or second decade of life except for Fuchs' endothelial dystrophy, which only becomes symptomatic between the ages of 40 and 50.

Classification: The following forms of dystrophy are differentiated according to the individual layers of the cornea in which they occur:

- ❖ **Epithelial corneal dystrophy.**
- ❖ **Stromal corneal dystrophy.** The most prevalent forms include:
 - Granular dystrophy (hyaline deposits, Fig. 5.16).
 - Lattice dystrophy (amyloid deposits).
 - Macular dystrophy (deposits of acidic mucopolysaccharides, Fig. 5.17).
- ❖ **Endothelial dystrophy**, such as:
 - Fuchs' endothelial dystrophy (the most frequently encountered form of corneal dystrophy).

Symptoms and diagnostic considerations: All patients suffer from a steadily increasing loss of visual acuity due to the generally gradual opacification of the cornea. This loss of visual acuity may progress to the point where a corneal transplant becomes necessary.

Macular dystrophy is the most rapidly debilitating form of the **stromal dystrophies**, resulting in a severe loss of visual acuity in the second decade of life. **Epithelial and stromal corneal dystrophies** are also often accompanied by painful and recurrent corneal erosion. **Fuchs' endothelial dystrophy** involves a gradual loss of endothelial cells that in time leads to *bullous keratopathy* (hydration of the cornea with stromal edema and epithelial bullae). The



Granular stromal corneal dystrophy.

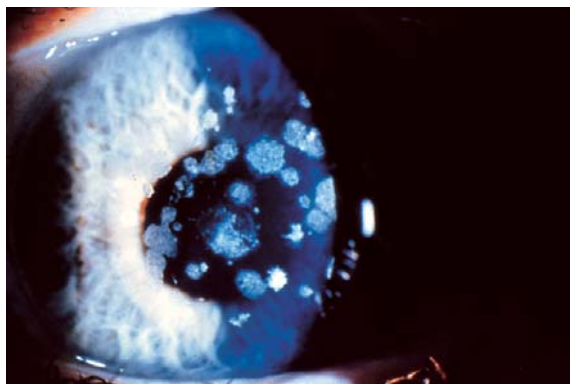
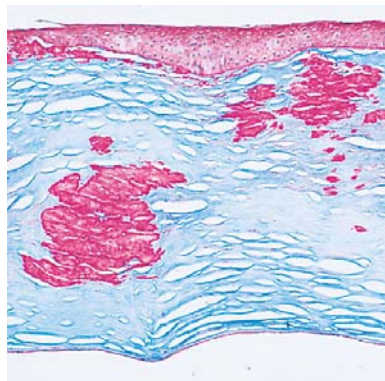


Fig. 5.16 a Clinical findings include fragmented opacities surrounded by areas of clear cornea between the deposits.



b Histologic findings demonstrating hyaline deposits under Masson's trichrome stain.

patient typically will have poorer vision in the morning than in the evening, as corneal swelling is greater during the night with the eyelids closed.

Treatment: Depending on the severity of the loss of visual acuity (see above), a *corneal transplant* (penetrating keratoplasty; see p. 152) may be indicated. Because the cornea remains avascular in these disorders, the prognosis is good.

In **Fuchs' endothelial dystrophy**, a corneal transplant is the treatment of choice. Where the symptoms are not too far advanced, *frequent application of hyperosmolar solutions* can remove water from the cornea. However, this is generally only a temporary solution. The corneal transplant is performed in combination with a cataract extraction; patients with Fuchs' endothelial dys-



Macular stromal corneal dystrophy.

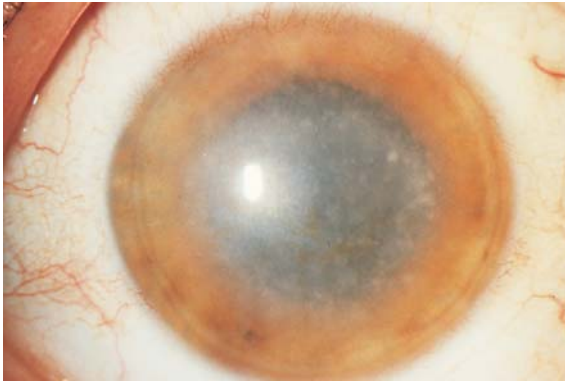
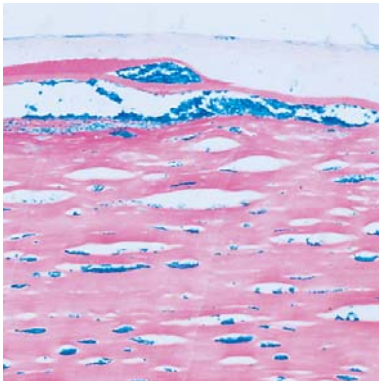


Fig. 5.17 a Clinical findings include nodular opacities surrounded by areas of clear cornea between the deposits.



b Histologic findings demonstrating deposits of acidic mucopolysaccharides under AMP stain.

trophy that affects their vision are usually older and also have a cataract. The two procedures are combined because corneal decompensation often results from Fuchs' endothelial dystrophy following the surgical trauma of cataract extraction (see 5.2.5).

5.7 Corneal Surgery

Corneal surgery includes **curative** or therapeutic procedures and **refractive** procedures (Fig. 5.18).

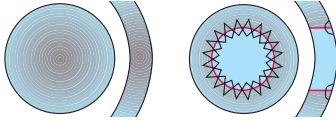
- ❖ **Curative** corneal procedures are intended to improve vision by eliminating *corneal opacification*.



Therapeutic and refractive corneal procedures.

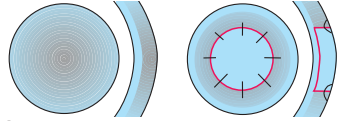
Therapeutic procedures

Penetrating keratoplasty



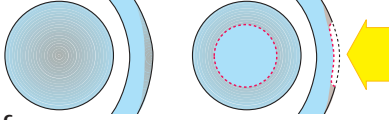
a

Lamellar keratoplasty



b

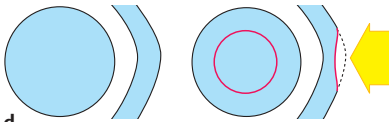
Phototherapeutic keratectomy



c

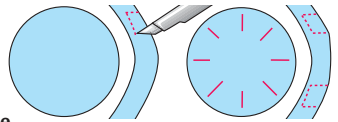
Refractive procedures

Photorefractive keratectomy



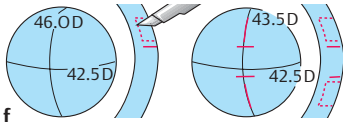
d

Radial keratotomy



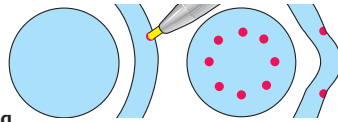
e

Keratotomy correction of astigmatism



f

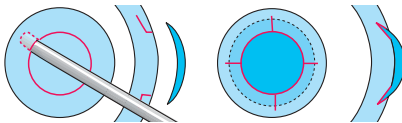
Holmium laser correction of hyperopia



g

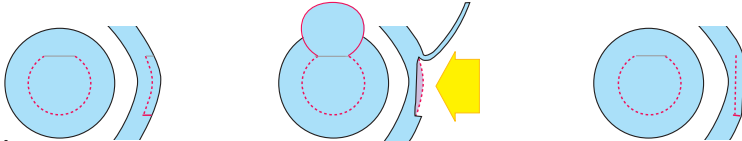
Epikeratophakia

Epikeratophakic keratoplasty



h

Excimer laser *in situ* keratomileusis (LASIK)



i

= Excimer laser

Figs. 5.18 a–i See explanations in text.



- ❖ **Refractive** corneal procedures change the refractive power of a *clear* cornea.

5.7.1 Curative Corneal Procedures

5.7.1.1 Penetrating Keratoplasty (Fig. 5.18 a)

Principle: This involves replacement of diseased corneal tissue with a full-thickness donor graft of corneal tissue of varying diameter. A clear, regularly refracting button of donor cornea is placed in an opacified or irregularly refracting cornea. The corneal button is sutured with a continuous single or double suture (Fig. 5.19) or with interrupted sutures. (For special considerations in corneal transplants, see also Morphology and healing.)

Penetrating keratoplasty can be performed as an **elective procedure** to improve visual acuity or as an emergency procedure (**emergency keratoplasty**). Emergency keratoplasty is indicated to treat a perforated or nonhealing corneal ulcer to remove the perforation site and save the eye (*tectonic keratoplasty*).

Indications: Corneal diseases that affect the full thickness of the corneal stroma (corneal scars, dystrophy, or degeneration) or protrusion anomalies such as keratoconus or keratoglobus with or without central corneal opacification.

Allograft Rejection (Complications): The body's immune system can respond with a chronic focal allograft rejection (Fig. 5.20) or a diffuse allograft rejection (Fig. 5.21). The graft will become opacified.

Penetrating keratoplasty.

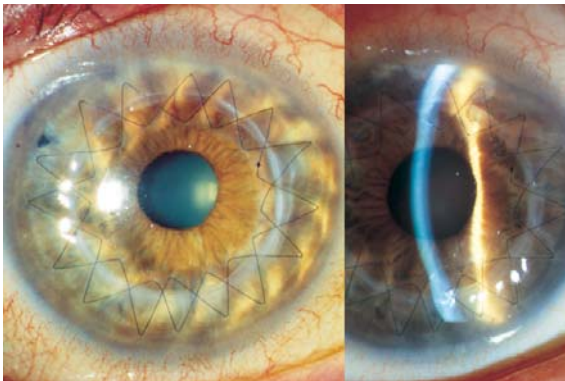


Fig. 5.19 The donor corneal button is sutured with a continuous double suture.



Chronic focal allograft rejection.

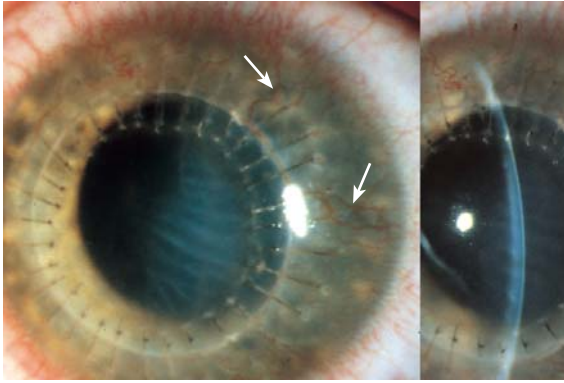
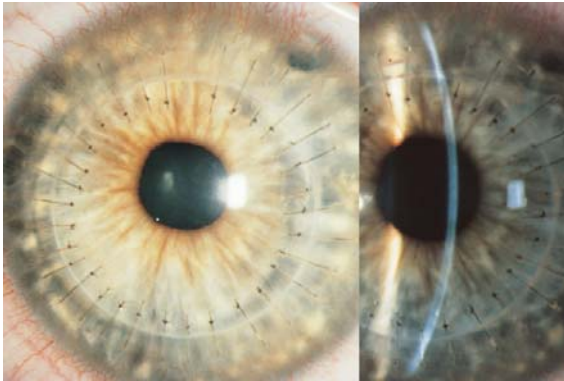


Fig. 5.20 a The reaction proceeds from vascular branches extending to the graft (arrows). The graft shows focal opacification (left image) and is thickened (right image) with a progressive frontal line (Khodadoust's line).



b The same eye after two weeks of topical and systemic steroid therapy. The graft is again clear and of normal thickness.

5.7.1.2 Lamellar Keratoplasty (Fig. 5.18b)

Principle: This involves replacement of a superficial stromal opacification with a partial-thickness donor graft of clear corneal tissue.

This surgery requires the corneal epithelium, Descemet's membrane, and the deeper layers of the cornea to be intact and healthy as it is only suitable for removing superficial opacifications down to about the middle of the cornea. The donor corneal button is then sutured with one or two continuous sutures or with interrupted sutures.



Acute diffuse allograft rejection.

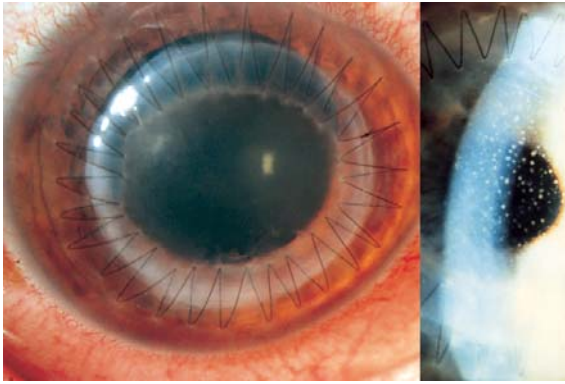

Fig. 5.21 **a** The graft is opacified and thickened. **b** The slit lamp image reveals precipitates posterior to the cornea.

Indications: Corneal opacifications and scars affecting the superficial corneal stroma (post-traumatic, degenerative, dystrophic, or postinflammatory opacifications). This method is not suitable for treating corneal ulcers.

Allograft Rejection (Complications): Allograft rejection is less frequent than in the case of penetrating keratoplasty. There is also less danger of infection as lamellar keratoplasty does not involve opening the globe.

5.7.1.3 Phototherapeutic Keratectomy (Fig. 5.18c)

Principle: Superficial corneal scars can be ablated with an excimer laser (wavelength of 193 nm). The lesion is excised parallel to the surface of the cornea to avoid refractive effects. The edges of the ablated area are merged smoothly with the rest of the corneal surface, eliminating any irregularities.

Indications: Indications are identical to those for lamellar keratoplasty. However, this method is only suitable for ablation of relatively superficial corneal opacifications, i.e., in the upper 20% of the corneal stroma.

Disadvantage: Despite attempting ablation parallel to the surface of the cornea, phototherapeutic keratectomy often creates a hyperopic effect.



5.7.2 Refractive Corneal Procedures

5.7.2.1 Photorefractive Keratectomy (Fig. 5.18 d)

Principle: Tissue is ablated to change the corneal curvature and to achieve a refractive correction. *Flattening* the corneal curvature **corrects myopia**, whereas *steepening* the curvature **corrects hyperopia**. The amount of tissue removed at different sites can be varied with layer-by-layer excimer laser ablation and the use of apertures. This makes it possible to correct for myopia, by removing more tissue from the center of the cornea, or for hyperopia, by removing more tissue from the periphery.

Indications: Best results are achieved in correcting myopia of less than 6 diopters. At present stable correction can be achieved in 85–95% of all cases of myopia up to 16 diopters, with deviation of ± 1 diopter from the target within one year. Correction of hyperopia has also been attempted.

5.7.2.2 Radial Keratotomy (Fig. 5.18 e)

Principle: Correction of myopia by *flattening the central dome of the cornea* with four to sixteen radial incisions extending through as much as 90% of the thickness of the cornea. This increases the steepness of the corneal periphery and lowers the center of the cornea, reducing its refractive power. This method does not influence the optical center of the cornea (Fig. 5.22).

Indications and prognosis: The method is suitable for moderate myopia (less than 6 diopters). The effect achieved is influenced by the initial refraction, intraocular pressure, corneal thickness, and the patient's age and sex. A

Radial keratotomy.

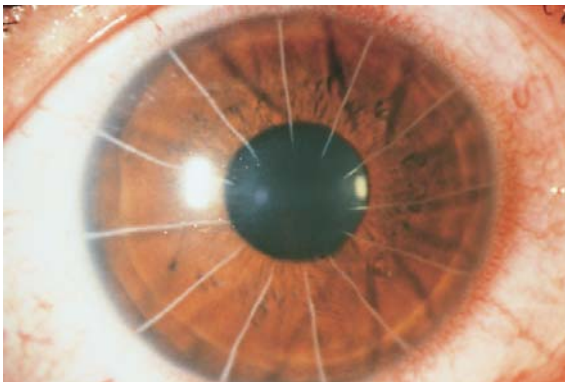


Fig. 5.22 Myopia is corrected with radial incisions in the cornea (twelve in this case). This flattens the dome of the central cornea and increases the steepness of the corneal periphery.



disadvantage is refractive fluctuations of up to 1.5 diopters during the course of the day. In one-fifth of all cases refraction becomes unstable within a year.

5.7.2.3 Photorefractive Keratectomy Correction of Astigmatism

Principle: Surgical reduction of severe regular astigmatism by flattening the steep meridian in the center of the cornea by increasing the steepness of the corneal periphery. *Irregular* astigmatism cannot be corrected.

Indication: Severe *regular* astigmatism.

5.7.2.4 Holmium Laser Correction of Hyperopia

Principle: The laser is focused on the corneal stroma to create shrinkage effects. Placing these areas symmetrically steepens the central cornea, which can correct severe hyperopia.

Indication: Hyperopia correction up to 8 diopters.

5.7.2.5 Epikeratophakic Keratoplasty (Epikeratophakia)

Principle: Severe myopia and hyperopia are corrected by suturing specially prepared hyperopic or myopic partial-thickness corneal grafts on to the recipient's cornea. This involves special trephination and preparation of the recipient's cornea. The donor graft is then fitted into the prepared cornea and sutured in place. The donor corneal button is prepared as a frozen section and shaped to the required refractive power; these implants can be ordered from eye banks.

Indications: Any severity of hyperopia or myopia can be corrected.

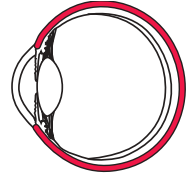
5.7.2.6 Excimer Laser *in situ* Keratomileusis (LASIK)

Principle: Myopia is corrected with preservation of Bowman's layer. A superficial corneal flap (approx. 160 μm) is created with a microkeratome. The keratome is withdrawn, the flap is reflected, and the exposed underlying corneal stroma is ablated with an excimer laser to correct the myopia. Then the flap is repositioned on the corneal bed and fixed in place by force of its own adhesion.

Indication: Even severe myopia (up to 10–12 diopters) can be corrected with this method.

6 Sclera

Gerhard K. Lang



6.1 Basic Knowledge

Function: The sclera and the cornea form the rigid outer covering of the eye. All six ocular muscles insert into the sclera.

Morphology: The sclera is fibrous, whitish opaque, and consists of nearly acellular connective tissue with a higher water content than the cornea. The sclera is thickest (1 mm) anteriorly at the limbus of the cornea where it joins the corneal stroma and at its posterior pole. It is thinnest (0.3 mm) at the equator and beneath the insertions of the rectus muscles. The site where the fibers of the optic nerve enter the sclera is known as the lamina cribrosa. In the angle of the anterior chamber, the sclera forms the trabecular network and the canal of Schlemm. The aqueous humor drains from there into the intrascleral and episcleral venous plexus through about 20 canaliculi.

Neurovascular supply: Vortex veins and the short anterior and posterior ciliary arteries penetrate the sclera. The ciliary nerves course through the sclera from posterior to anterior.

6.2 Examination Methods

The anterior portion of the sclera about as far back as the equator can be examined directly with a **slit lamp**. Evaluation of the sclera posterior to the equator requires indirect methods such as **ultrasound**.

Transillumination can provide evidence of possible abnormal changes in the posterior sclera. However, this method is not as precise as an ultrasound study.

6.3 Color Changes

The sclera is normally dull white like porcelain. Altered color suggests one of the following changes:

- ❖ **Conjunctival** and/or **ciliary injection** and inflammation will give the sclera a red appearance.



- ❖ A sclera that is **very thin** will appear **blue** because of the underlying choroid (this occurs in the newborn, in osteogenesis imperfecta, and following inflammation; see Fig. 6.4).
- ❖ In **jaundice**, the sclera turns **yellow**.
- ❖ In **ochronosis** (alkaptonuria), the sclera will take on **brownish** color. This should be distinguished from pigmented changes in the conjunctiva.

6.4 Staphyloma and Ectasia

Staphyloma refers to a bulging of the sclera in which the underlying uveal tissue in the bulge is also thinned or degenerated. By far the most common form is *posterior staphyloma in severe myopia*, a bulging of the entire posterior pole of the eyeball (Fig. 6.1). Staphyloma can also occur secondary to scleritis (see Fig. 6.4).

Ectasia is a thinning and bulging of the sclera without uveal involvement, as can occur secondary to inflammation.

Both staphyloma and ectasia are secondary or incidental findings. No treatment is available.

6.5 Trauma

The sclera is frequently involved in penetrating trauma. Deep injuries that extend far posteriorly usually also involve the choroid and retina. Surgery to treat larger injuries extending 8 mm past the limbus should also include a retinal repair (retinal cryopexy or retinal tamponade).

6.6 Inflammations

Inflammations are the most clinically significant scleral changes encountered in ophthalmologic practice. They more often involve the anterior sclera (episcleritis and anterior scleritis) than the posterior sclera (posterior scleritis).

Classification: Forms of scleral inflammation are differentiated as follows:

- ❖ **Location:** anterior or posterior, i.e., anterior or posterior to the equator of the globe.
- ❖ **Depth:**
 - Superficial (episcleritis).
 - Deep (scleritis).
- ❖ **Nature:**
 - Diffuse (usually scleritis).
 - Circumscribed or segmental (episcleritis).
 - Nodular, with formation of small mobile nodules (scleritis and episcleritis).



Posterior staphyloma in a highly myopic eye.

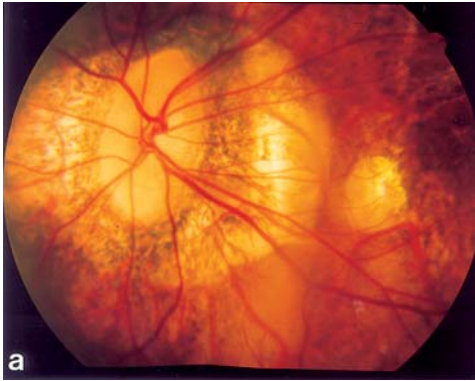
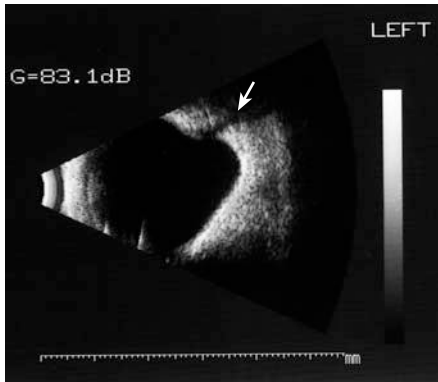


Fig. 6.1 a Ophthalmologic image of posterior staphyloma of the sclera.



b Ultrasound image showing the posterior scleral bulge and oblique course of the optic nerve through the sclera.

- Necrotizing (scleritis only).
- Non-necrotizing (scleritis only).

6.6.1 Episcleritis

Definition

Circumscribed, usually segmental, and generally *nodular* inflammation of the episclera (connective tissue between sclera and conjunctiva).

Epidemiology: Episcleritis is the most common form of scleral inflammation.



Segmental episcleritis.

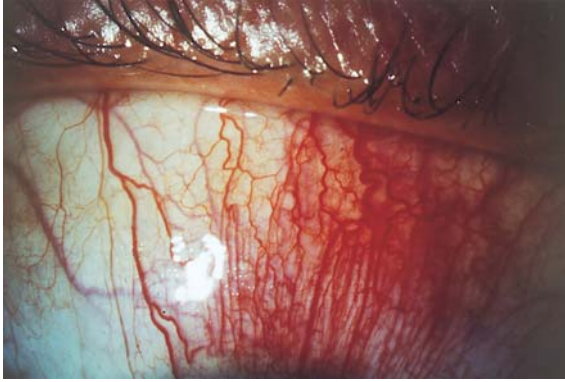

Fig. 6.2 Typical hyperemia and inflammation of the radial episcleral blood vessels.

Etiology: Episcleritis is rarely attributable to one of the systemic underlying disorders listed in Table 6.1, and is only occasionally due to bacterial or viral inflammation. Often episcleritis will have no readily discernible cause.

Symptoms: Episcleritis can be unilateral or bilateral. It is usually associated with segmental reddening and slight tenderness to palpation.

Findings: The episcleral vessels lie within the fascial sheath of the eyeball (Tenon's capsule) and are arranged radially. In episcleritis, these vessels and the conjunctival vessels above them become hyperemic (Fig. 6.2). Tenon's capsule and the episclera are infiltrated with inflammatory cells, but the sclera itself is not swollen. The presence of small *mobile* nodules is typical of nodular episcleritis.

Differential diagnosis: The disorder should be distinguished from conjunctivitis (see next paragraph) and scleritis (6.6.2).



The conjunctival blood vessels are the most superficial; the episcleral vessels lie within Tenon's capsule and are arranged radially. When vasoconstrictive eyedrops are applied, the conjunctival injection will disappear but not the episcleral injection. This makes it possible to distinguish conjunctivitis from episcleritis.

Treatment and prognosis: Episcleritis usually resolves spontaneously within one to two weeks, although the nodular form can persist for extended periods of time. Severe symptoms are treated with topical steroids (eyedrops) or with a nonsteroidal anti-inflammatory agent.



6.6.2 Scleritis

Definition

Diffuse or localized inflammation of the sclera. Scleritis is classified according to location:

- ❖ **Anterior** (inflammation anterior to the equator of the globe).
- ❖ **Posterior** (inflammation posterior to the equator of the globe).

Anterior scleritis is further classified according to its nature:

- ❖ **Non-necrotizing anterior scleritis** (nodular or diffuse).
- ❖ **Necrotizing anterior scleritis** (with or without inflammation).

Epidemiology: Scleritis is far less frequent than episcleritis. Patients are generally older, and women are affected more often than men.

Etiology: Approximately 50% of scleritis cases (which tend to have severe clinical courses) are attributable to systemic autoimmune or rheumatic disease (Table 6.1), or are the result of immunologic processes associated with infection. This applies especially to anterior scleritis. Posterior scleritis is not usually associated with any specific disorder. As with episcleritis, scleritis is only occasionally due to bacterial or viral inflammation.

Symptoms and findings: All forms except for scleromalacia perforans are associated with *severe pain* and general reddening of the eye.

Anterior non-necrotizing scleritis (nodular form). The nodules consist of edematous swollen sclera and are *not mobile* (in contrast to episcleritis).

Table 6.1 Systemic diseases that can cause scleritis

Frequent causes	Rare causes
❖ Rheumatoid arthritis	❖ Tuberculosis
❖ Polymyositis	❖ Lues
❖ Dermatomyositis	❖ Borreliosis
❖ Ankylosing spondylitis	❖ Reiter's syndrome
❖ Spondylarthritis	
❖ Vasculitis	
❖ Wegener's granulomatosis	
❖ Herpes zoster ophthalmicus	
❖ Syphilis	
❖ Gout	



Diffuse non-necrotizing scleritis.

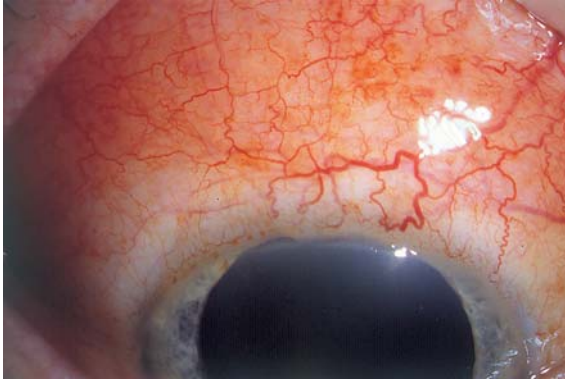


Fig. 6.3 Typical signs include thickening and edema of the sclera and deep, diffuse reddening.

Anterior necrotizing scleritis (diffuse form). The inflammation is more severe than in the nodular form. It can be limited to a certain segment or may include the entire anterior sclera (Fig. 6.3).

Anterior necrotizing scleritis with inflammation. Circumscribed reddening of the eyes is a typical sign. There may be deviation or injection of the blood vessels of the affected region, accompanied by avascular patches in the episcleral tissue. As the disorder progresses, the sclera thins as the scleral lamellae of collagen fibrils melt, so that the underlying choroid shows through (Fig. 6.4). The inflammation gradually spreads from its primary focus. Usually it is associated with uveitis.

Anterior necrotizing scleritis without inflammation (scleromalacia perforans). This form of scleritis typically occurs in *female patients* with a long history of seropositive rheumatoid arthritis. The clinical course of the disorder is usually asymptomatic and begins with a yellow necrotic patch on the sclera. As the disorder progresses, the sclera also thins so that the underlying choroid shows through. This is the *only* form of scleritis that *may be painless*.

Posterior scleritis. Sometimes there will be no abnormal findings in the anterior eye, and pain will be the only symptom. Associated inflammation of the orbit may result in proptosis (exophthalmos) and impaired ocular motility due to myositis of the ocular muscles. Intraocular findings may include exudative retinal detachment and/or choroid detachment. Macular and optic disk edema are frequently present.



Circumscribed scleral staphyloma secondary to scleritis.

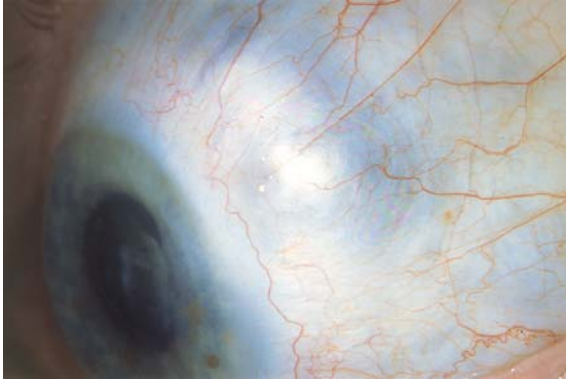


Fig. 6.4 The underlying choroid shows through at the bulge where the sclera is thinned, giving it a bluish tinge.



The reddening in scleritis is due to injection of the deeper vascular plexus on the sclera and to injection of the episclera. Inspecting the eye in daylight will best reveal the layer of maximum injection.

Differential diagnosis: Conjunctivitis and episcleritis (see that section).

Treatment:

Anterior non-necrotizing scleritis. Topical or systemic *nonsteroidal* anti-inflammatory therapy.

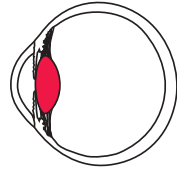
Anterior necrotizing scleritis with inflammation. Systemic *steroid* therapy is usually required to control pain. If corticosteroids do not help or are not tolerated, immunosuppressive agents may be used.

Anterior necrotizing scleritis without inflammation (scleromalacia perforans). As no effective treatment is available, grafts of preserved sclera or lyophilized dura may be required to preserve the globe if the course of the disorder is fulminant.

Posterior scleritis. Treatment is the same as for anterior necrotizing scleritis with inflammation.

7 Lens

Gerhard K. Lang



7.1 Basic Knowledge

Function of the lens: The lens is one of the essential refractive media of the eye and focuses incident rays of light on the retina. It adds a variable element to the eye's total refractive power (10–20 diopters, depending on individual accommodation) to the fixed refractive power of the cornea (approximately 43 diopters).

Shape: The fully developed lens is a **biconvex, transparent structure**. The curvature of the posterior surface, which has a radius of 6 mm, is greater than that of the anterior surface, which has a radius of 10 mm.

Weight: The lens is approximately 4 mm thick, and its weight increases with age to five times its weight at birth. An adult lens weighs about 220 mg.

Position and suspension: The lens lies in the posterior chamber of the eye between the posterior surface of the iris and the vitreous body in a **saucer-shaped depression of the vitreous body** known as the hyaloid fossa. Together with the iris it forms an optical diaphragm that separates the anterior and posterior chambers of the eye. Radially arranged **zonule fibers** that insert into the lens around its equator connect the lens to the ciliary body. These fibers hold the lens in position (Fig. 7.1) and transfer the tensile force of the ciliary muscle (see Accommodation).

Embryology and growth: The lens is a **purely epithelial structure** without any nerves or blood vessels. It moves into its intraocular position in the first month of fetal development as surface ectoderm invaginates into the primitive optic vesicle, which consists of neuroectoderm. A *purely ectodermal structure*, the lens differentiates during gestation into central geometric lens fibers, an anterior layer of epithelial cells, and an acellular hyaline capsule (Figs. 7.2a and b). The normal **direction of growth** of epithelial structures is centrifugal; fully developed epithelial cells migrate to the surface and are peeled off. However, the lens grows in the *opposite* direction. The youngest cells are always on the surface and the oldest cells in the center of the lens. The growth of primary lens fibers forms the **embryonic nucleus**. At the **equator**, the epithelial cells further differentiate into lens fiber cells (Fig. 7.2).



Shape of the lens and its position in the eye.

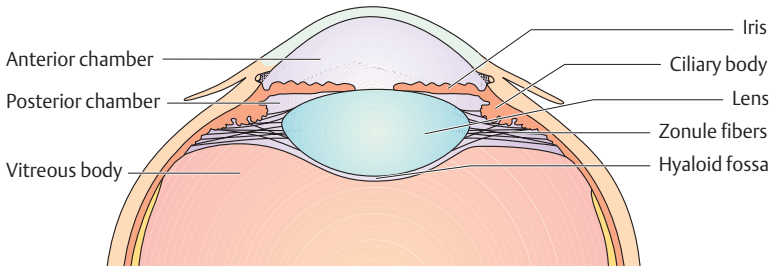


Fig. 7.1 The lens is a biconvex structure suspended on the zonule fibers. It lies in the hyaloid fossa and separates the anterior and posterior chambers of the eye.

Embryology of the lens.

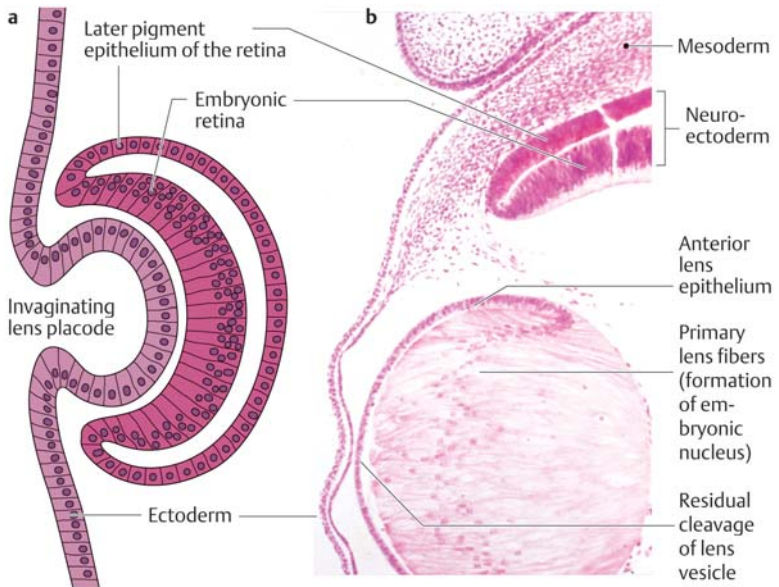


Fig. 7.2 **a** First month of fetal development: The ectoderm invaginates and is isolated in what becomes the optic cup. **b** The lens vesicle is completely invaginated. The primary lens fibers grow and begin to form the embryonic nucleus.



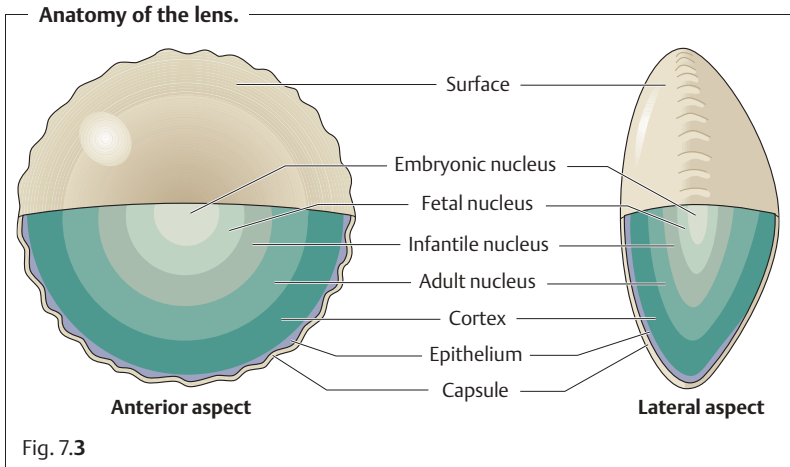
These new secondary fibers displace the primary fibers toward the center of the lens. Formation of a **fetal nucleus** that encloses the embryonic nucleus is complete at birth. Fiber formation at the equator, which continues throughout life, produces the **infantile nucleus** during the first and second decades of life, and the **adult nucleus** during the third decade. Completely enclosed by the lens capsule, the lens never loses any cells so that its tissue is continuously compressed throughout life (Fig. 7.3 **a** and **b**). The various density zones created as the lens develops are readily discernible as discontinuity zones (Fig. 7.4).

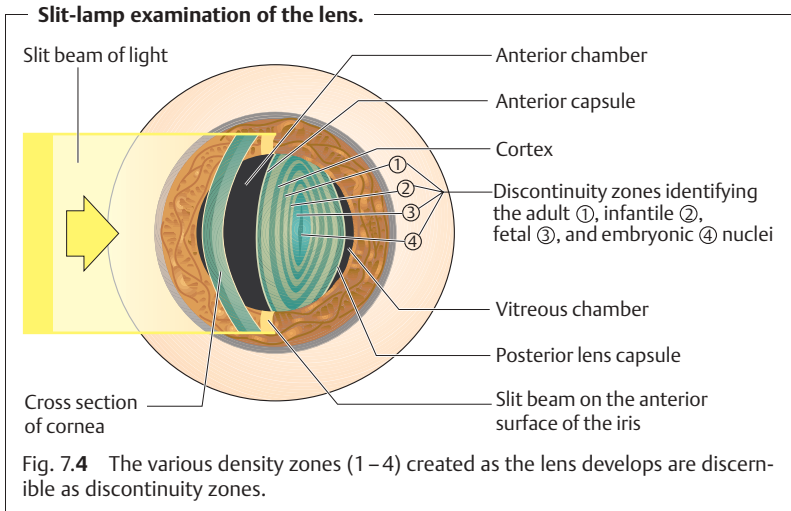
Metabolism and aging of the lens: The lens is nourished by **diffusion from the aqueous humor**. In this respect it resembles a tissue culture, with the aqueous humor as its substrate and the eyeball as the container that provides a constant temperature.



The metabolism and detailed biochemical processes involved in aging are complex and not completely understood. Because of this, it has not been possible to influence cataract development (see Cataract, p. 170) with medications.

The metabolism and growth of the lens cells are self-regulating. Metabolic activity is essential for the preservation of the integrity, transparency, and optical function of the lens. The epithelium of the lens helps to maintain the ion equilibrium and permit **transportation of nutrients, minerals, and water into the lens**. This type of transportation, referred to as a **“pump-leak system,”** permits active transfer of sodium, potassium, calcium, and amino acids





from the aqueous humor into the lens as well as passive diffusion through the posterior lens capsule. Maintaining this equilibrium (homeostasis) is essential for the transparency of the lens and is closely related to the water balance. The **water content of the lens** is normally stable and in equilibrium with the surrounding aqueous humor. The water content of the lens decreases with age, whereas the content of insoluble lens proteins (albuminoid) increases. The lens becomes harder, less elastic (see Loss of accommodation), and less transparent. A **decrease in the transparency of the lens with age** is as unavoidable as wrinkles in the skin or gray hair. Manifestly reduced transparency is present in 95% of all persons over the age of 65, although individual exceptions are not uncommon. The central portion or nucleus of the lens becomes sclerosed and slightly yellowish with age.

7.2 Examination Methods

Cataracts: Retroillumination of the lens (Brückner's test) is the *quickest preliminary examination method* for lens opacities (Cataracts, see section 7.4). Under a light source or ophthalmoscope (set to 10 diopters), opacities will appear black in the red pupil (Fig. 7.5). The lens can be examined *in greater detail and in three dimensions* under **focal illumination with a slit lamp** with the pupil maximally dilated. The extent, type, location, and density of opacities and their relation to the visual axis may be evaluated. Mature lens opaci-



Retroillumination of the lens (Brückner's test).

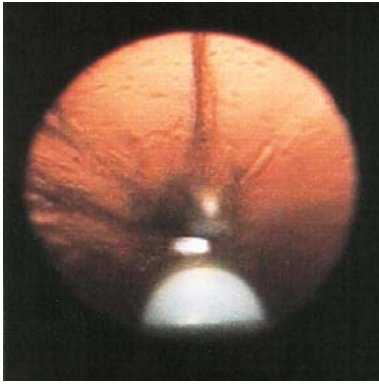


Fig. 7.5 Opacities appear black in the red pupil.

ties may be diagnosed with the unaided eye by the presence of a white pupil (leukocoria).



Where the fundus is not visible in the presence of a mature lens opacity, ultrasound studies (one-dimensional A-scan and two-dimensional B-scan studies) are indicated to exclude involvement of the deeper structures of the eye.

Iridodonesis and phacodonesis: Tremulous motion of the iris and lens observed during slit-lamp examination suggests subluxation of the lens (see p. 195).

7.3 Developmental Anomalies of the Lens

Anomalies of lens shape are very rare. **Lenticonus** is a circumscribed conical protrusion of the anterior pole (anterior lenticonus) or posterior pole (posterior lenticonus). A hemispherical protrusion is referred to as **lentiglobus**. Symptoms include myopia and reduced visual acuity. Some patients with Alport's syndrome (kidney disease accompanied by sensorineural hearing loss and anomalies of lens shape) have *anterior* lenticonus. *Posterior lenticonus* may be associated with a lens opacity (Fig. 7.6). Treatment is the same as for congenital or juvenile cataract.

Microphakia refers to a lens of abnormally small diameter. Any interruption of the development of the eye generally leads to microphakia. This can occur for example in Weill-Marchesani syndrome (see Table 7.5).

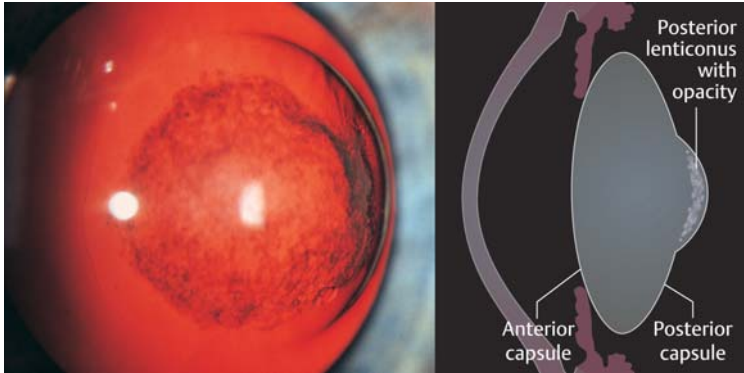
**Posterior lenticonus.**

Fig. 7.6 Conical protrusion of the posterior pole, here associated with a posterior subcapsular opacity.

7.4 Cataract

Definition

A cataract is present when the transparency of the lens is reduced to the point that the patient's vision is impaired. The term **cataract** comes from the Greek word *katarraktes* (downrushing; waterfall) because earlier it was thought that the cataract was a congealed fluid from the brain that had flowed in front of the lens.

General symptoms: Development of the cataract and its symptoms is generally an *occult process*. Patients experience the various symptoms such as seeing only shades of gray, visual impairment, blurred vision, distorted vision, glare or star bursts, monocular diplopia, altered color perception, etc. to varying degrees, and these symptoms will vary with the specific type of cataract (see Table 7.3 and Figs. 7.7a and b).



Diagnosis of a cataract is generally very unsettling for patients, who immediately associate it with surgery. One should therefore refer only to a cataract when it has been established that surgery is indicated. If the cataract has not progressed to an advanced stage or the patient can cope well with the visual impairment, one should refer instead to a “lens opacity.”

**Cataract symptoms.**

Fig. 7.7 a Visual image without a cataract.



b Visual image with a cataract: gray areas and partial loss of image perception.

Classification: Cataracts may be classified according to several different criteria.

- ❖ Time of occurrence (acquired or congenital cataracts).
- ❖ Maturity.
- ❖ Morphology.

No one classification system is completely satisfactory. We prefer the system in Table 7.1.



Table 7.1 Classification of cataracts according to time of occurrence

Acquired cataracts (over 99% of all cataracts)	<ul style="list-style-type: none">❖ Senile cataract (over 90% of all cataracts)❖ Cataract with systemic disease<ul style="list-style-type: none">- Diabetes mellitus- Galactosemia- Renal insufficiency- Mannosidosis- Fabry's disease- Lowe's syndrome- Wilson's disease- Myotonic dystrophy- Tetany- Skin disorders❖ Secondary and complicated cataracts<ul style="list-style-type: none">- Cataract with heterochromia- Cataract with chronic iridocyclitis- Cataract with retinal vasculitis- Cataract with retinitis pigmentosa❖ Postoperative cataracts<ul style="list-style-type: none">- Most frequently following vitrectomy and silicone oil retinal tamponade- Following filtering operations❖ Traumatic cataracts<ul style="list-style-type: none">- Contusion or perforation rosette- Infrared radiation (glassblower's cataract)- Electrical injury- Ionizing radiation❖ Toxic cataract<ul style="list-style-type: none">- Corticosteroid-induced cataract (most frequent)- Less frequently from chlorpromazine, miotic agents, or busulfan
Congenital cataracts (less than 1% of all cataracts)	<ul style="list-style-type: none">❖ Hereditary cataracts<ul style="list-style-type: none">- Autosomal dominant- Recessive- Sporadic- X-linked❖ Cataracts due to early embryonic (trans-placental) damage<ul style="list-style-type: none">- Rubella (40–60%)- Mumps (10–22%)- Hepatitis (16%)- Toxoplasmosis (5%)



7.4.1 Acquired Cataract

7.4.1.1 Senile Cataract

Epidemiology: Senile cataract is by far the most frequent form of cataract, accounting for 90% of all cataracts. About 5% of all 70-year-olds and 10% of all 80-year-olds suffer from a cataract requiring surgery.

! Ninety percent of all cataracts are senile cataracts.

Etiology: The precise causes of senile cataract have not been identified. As occurrence is often familial, it is important to obtain a detailed family history.

Classification and forms of senile cataracts: The classification according to **maturity** (Table 7.2) follows the degree of visual impairment and the maturity, which earlier was important to determine the time of surgery. We follow a **morphologic classification** as morphologic aspects such as the hardness and thickness of the nucleus now influence the surgical procedure (Table 7.3):

Nuclear cataract. In the fourth decade of life, the pressure of peripheral lens fiber production causes hardening of the entire lens, especially the nucleus. The nucleus takes on a *yellowish brown color (brunescens nuclear cataract)*. This may range from reddish brown to nearly black discoloration of the entire lens (black cataract). Because they increase the refractive power of the lens, nuclear cataracts lead to lenticular myopia and occasionally produce a second focal point in the lens with resulting monocular diplopia (Fig. 7.8).

! Nuclear cataracts develop very slowly. Due to the lenticular myopia, near vision (even without eyeglasses) remains good for a long time.

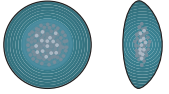

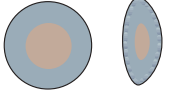
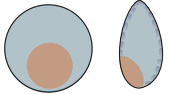
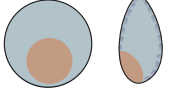
Cortical cataract. Nuclear cataracts are often associated with changes in the lens cortex. It is interesting to note that patients with cortical cataracts tend to have acquired hyperopia in contrast to patients with nuclear cataracts, who tend to be myopic (see above).

Table 7.2 Classification of cataracts according to maturity

Cataract form	Visual acuity
Developing cataract	Still full (0.8–1.0)
Immature cataract	Reduced (0.4–0.5)
Developed cataract	Severely reduced (1/50–0.1)
Mature cataract Hypermature cataract	Light and dark perception, perception of hand movements in front of the eye



Table 7.3 Overview of forms of senile cataract

Cataract form	Morphology	Incidence	Symptoms
Nuclear cataract		About 30%, particularly in more severe myopia	<ul style="list-style-type: none"> - Shades of gray (like looking through frosted glass) - Blurred vision - Distorted vision - Intense glare in bright light - Diminished contrast - Changes in color perception (rare)
Subcapsular cataract <div style="display: flex; align-items: center;"> <div style="margin-right: 10px;">anterior</div> <div style="margin-right: 10px;">posterior</div> </div>		About 50%	
Posterior sub-capsular cataract		About 20%	
Mature cataract		Final stage	
Hypermature cataract			



Visual acuity	Progression	Peculiarities, glare, eyesight in twilight	Diagnosis and prognosis for vision
<ul style="list-style-type: none"> - Impairment is relatively <i>late</i> - Increasing poor <i>distance vision</i> - <i>Near vision</i> remains due to myopic effect of cataract 	Slow	<ul style="list-style-type: none"> - Eyesight in twilight is often better than in daylight because the mydriasis in darkness allows light past the opacity - Glare is less pronounced - Monocular diplopia due to two focal points in the lens. 	<ul style="list-style-type: none"> - Morphology by transillumination (Brückner's test) - Detailed diagnosis in slit-lamp examination - Prediction of expected post-operative visual acuity: <i>laser interference visual acuity testing</i>
<ul style="list-style-type: none"> - <i>Early loss of visual acuity</i> - Hyperopic effect of cataract compromises <i>distance vision</i> less than <i>near vision</i> 	Rapid (temporary improvement in visual acuity due to stenopeic effect)	<ul style="list-style-type: none"> - Patient is severely hampered by glare (sun, snow, headlights). Patients typically prefer dark glasses and wide-brimmed hats. - Marked improvement of vision <i>in twilight</i> and <i>at night</i> (nyctalopia) 	
<ul style="list-style-type: none"> - <i>Early loss of visual acuity</i> - <i>Near vision</i> particularly affected, <i>distance vision</i> less so 	Rapid		
Visual acuity reduced to perception of light and dark; perception of hand movements in front of the eye at best.	All cataract forms will progress to a mature or hypermature form given enough time.	In intense light, patient will perceive gross movements and persons as silhouettes.	<ul style="list-style-type: none"> - Leukocoria (white pupil) detectable with unaided eye. - Slit-lamp permits differentiation. - Retinoscopy to determine visual acuity is often ineffective with dense opacities.

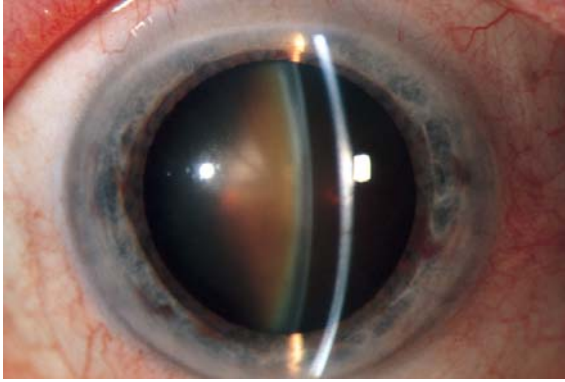
**Nuclear cataract.**

Fig. 7.8 The nucleus of the lens has a yellowish brown color due to the pressure of peripheral lens fiber production.

Whereas changes in *nuclear* cataracts are due to hardening, *cortical* changes are characterized by *increased water content*. Several morphologic changes will be apparent upon slit-lamp examination with maximum mydriasis:

- ❖ **Vacuoles:** Fluid accumulations will be present in the form of small narrow cortical vesicles. The vacuoles remain small and increase in number.
- ❖ **Water Fissures:** Radial patterns of fluid-filled fissures will be seen between the fibers.
- ❖ **Separation of the lamellae:** Not as frequent as water fissures, these consist of a zone of fluid between the lamellae (often between the clear lamellae and the cortical fibers).
- ❖ **Cuneiform cataract:** This is a frequent finding in which the opacities radiate from the periphery of the lens like spokes of a wheel.



Cortical cataracts progress more rapidly than nuclear cataracts. Visual acuity may temporarily improve during the course of the disease. This is due to a stenopeic effect as light passes through a clear area between two radial opacities.

Posterior subcapsular cataract. This is a *special form of cortical cataract* that begins in the visual axis. Beginning as a small cluster of granular opacities, this form of cataract expands peripherally in a disk-like pattern. As opacity increases, the rest of the cortex and the nucleus become involved (the usual spectrum of senile cataract).



- !** Posterior subcapsular cataract leads to early, rapid, and severe loss of visual acuity. Near vision is usually significantly worse than distance vision (near-field miosis). Dilating eyedrops can improve visual acuity in this form of cataract.

Mature cataract. The lens is diffusely white due to *complete opacification of the cortex*. A yellow lens nucleus is often faintly discernible (Fig. 7.9). Where water content is increased, a lens with a mature cataract can swell and acquire a silky luster (intumescent cataract in which the capsule is under pressure). The increasing thickness of the lens increases the resistance of the pupil and with it the risk of angle closure glaucoma.

- !** Vision is reduced to perception of light and dark, and the interior of the eye is no longer visible. Cataract surgery is indicated to restore visual acuity.

Hypermature cataract. If a mature cataract progresses to the point of complete liquification of the cortex, the dense brown nucleus will subside within the capsule. Its superior margin will then be visible in the pupil as a dark brown silhouette against the surrounding grayish white cortex. The pressure in the lens capsule decreases. The contents of the limp and wrinkled capsular bag gravitate within the capsule. This condition, referred to as

Mature cataract.

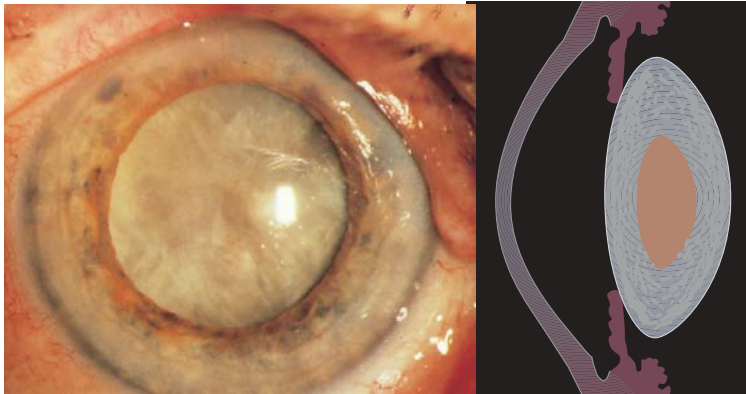


Fig. 7.9

- ❖ There is diffuse, complete opacification of the lens. A brownish nucleus is faintly visible posterior to the cortical layer.
- ❖ Interior of the eye is no longer visible.
- ❖ Visual acuity is reduced to perception of light and dark.



Morgagni's cataract, is the final stage in a cataract that has usually developed over the course of two decades. The approximate onset of the cataract can usually be inferred from such findings (Figs. 7.10a and b).



Prompt cataract extraction not only restores visual acuity but also prevents development of phacolytic glaucoma.

Hyper mature cataract.

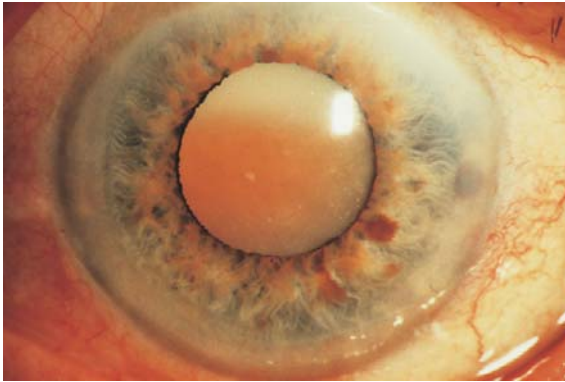
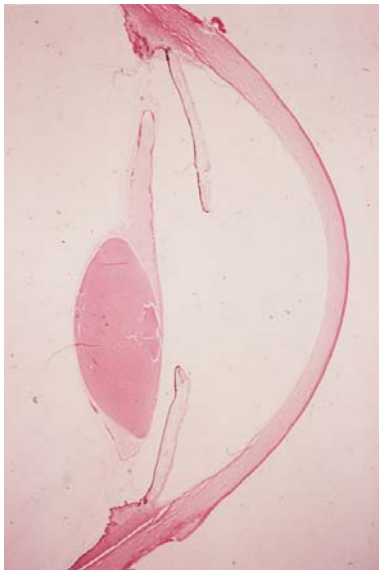


Fig. 7.10 a The brown nucleus has subsided in the liquified cortex.



b Histologic image obtained at autopsy shows the position of the subsided nucleus and the shrunken capsular bag.



When the lens capsule becomes permeable for liquified lens substances, it will lose volume due to leakage. The capsule will become wrinkled. The escaping lens proteins will cause intraocular irritation and attract macrophages that then cause congestion of the trabecular network (*phacolytic glaucoma*: see Secondary open angle glaucoma).

! Emergency extraction of the hypermature cataract is indicated in phacolytic glaucoma to save the eye.

7.4.2 Cataract in Systemic Disease

Epidemiology. Lens opacities can occasionally occur as a sign of systemic disease.

Forms of cataracts in systemic disease:

Diabetic cataract. The typical diabetic cataract is rare in young diabetic patients. Transient metabolic decompensation promotes the occurrence of a typical radial snowflake pattern of cortical opacities (snowflake cataract). Transient hyperopia and myopia can occur.

! Diabetic cataract progresses rapidly. Senile cataracts are observed about five times as often in older diabetics as in patients the same age with normal metabolism. These cataracts usually also occur two to three years earlier.

Galactosemic cataract. This *deep posterior cortical opacity* begins after birth. Galactosemia is a rare cause of early cataract in children lacking an enzyme required to metabolize galactose. The newborn receives ample amounts of galactose in the mother's milk. Due a lack of uridyl transferase, or less frequently galactokinase, galactose cannot be metabolized to glucose, and the body becomes inundated with galactose or with galactose and galactose-1-phosphate. If the disorder is diagnosed promptly and the child is maintained on a galactose-free diet, the opacities of the first few weeks of life will be reversible.

! Galactosemic cataract is the only form of cataract that responds to conservative therapy.

Dialysis cataract. Hemodialysis to eliminate metabolic acidosis in renal insufficiency can disturb the osmotic equilibrium of lens metabolism and cause swelling of the cortex of the lens.

Other *rare metabolic diseases* that can cause cataract include mannosidosis, Fabry's disease, Lowe's syndrome (oculocerebrorenal syndrome), and Wilson's disease (hepatolenticular degeneration).

Cataract with myotonic dystrophy. Opacities first occur between the ages of 30 and 50, initially in a thin layer of the anterior cortex and later also in the



subcapsular posterior cortex in the form of rosettes. Detecting these opacities is important for *differential diagnosis* as cataracts do not occur in Thomsen's disease (myotonia congenita) or Erb's progressive muscular dystrophy.

Symptoms that *confirm the diagnosis* include cataract, active signs of myotonia (delayed opening of the fist), and passive signs of myotonia (decreased relaxation of muscles in the extremities following direct percussion of the muscle and absence of reflexes).

Tetany cataract. The opacity lies within a broad zone inferior to the anterior lens capsule and consists of a series of gray punctate lesions. Symptoms that *confirm the diagnosis* include low blood calcium levels, a positive hyperventilation test, and signs of tetany: positive Chvostek, Trousseau, and Erb signs.

Dermatogenous cataract. This may occur with chronic neurodermatitis, less frequently with other skin disorders such as scleroderma, poikiloderma, and chronic eczema. Characteristic signs include an anterior crest-shaped thickening of the protruding center of the capsule (Fig. 7.11).

7.4.3 Complicated Cataracts

This form of cataract can occur as a complication of any protracted intraocular inflammation, especially heterochromia, chronic iridocyclitis, retinal vasculitis, and retinitis pigmentosa. The result is a pumice-like posterior subcapsular cataract that progresses axially toward the nucleus. This form of cataract produces extreme light scattering (Fig. 7.12).

7.4.4 Cataract after Intraocular Surgery

Cataracts usually develop earlier in the operated eye as compared to the opposite, non-operated eye after intraocular surgery. This applies especially to filtering operations. A secondary cataract will generally occur following vitrectomy and silicone oil tamponade.

7.4.5 Traumatic Cataract

The incidence of these lens opacities is higher in men than in women due to occupational and sports injuries. The following types of traumatic cataracts are differentiated:

Frequent traumatic cataracts:

- ❖ **Contusion cataract:** Contusion of the eyeball will produce a rosette-shaped subcapsular opacity on the anterior surface of the lens. It will normally remain unchanged but will migrate into the deeper cortex over time due to the apposition of new fibers (Fig. 7.13).



Dermatogenous cataract.

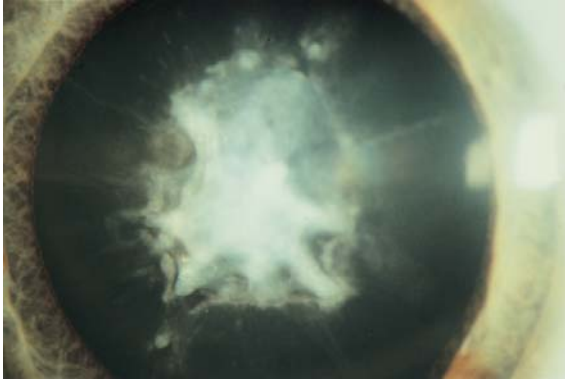


Fig. 7.11 Typical symptoms include a crest-shaped whitish opacity beneath the anterior lens capsule along the visual axis.

Complicated cataract in chronic iridocyclitis.

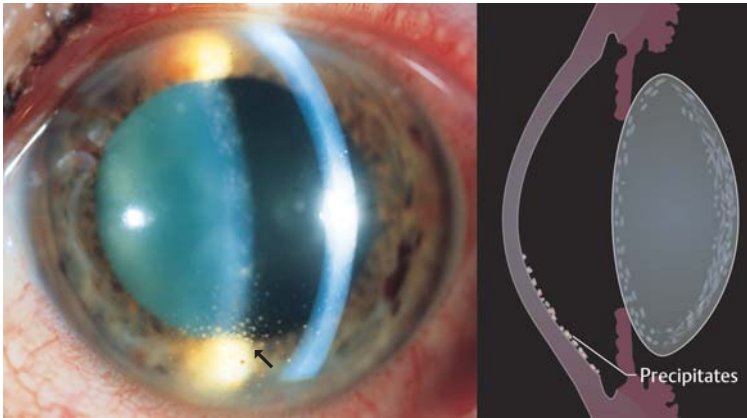


Fig. 7.12 This diffuse opacity proceeds from the posterior subcapsular cataract. Inflammatory precipitates indicative of chronic uveitis are also visible on the posterior surface of the cornea (arrow).



Contusion cataract.

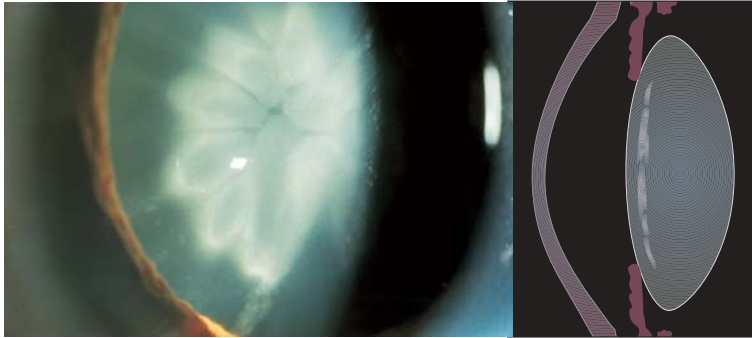


Fig. 7.13 A contusion rosette posterior to the anterior lens capsule develops following severe blunt trauma to the eyeball.

Rarer traumatic cataracts:

- ❖ **Infrared radiation cataract** (glassblower's cataract): This type of cataract occurs after decades of prolonged exposure to the infrared radiation of fire without eye protection. Characteristic findings include splitting of the anterior lens capsule, whose edges will be observed to curl up and float in the anterior chamber. Occupational safety regulations have drastically reduced the incidence of this type of cataract.
- ❖ **Electrical injury:** This dense subcapsular cataract can be caused by lightning or high-voltage electrical shock.
- ❖ **Cataract from ionizing radiation:** See Chapter 18.

7.4.6 Toxic Cataract

Steroid cataract. Prolonged topical or systemic therapy with corticosteroids can result in a posterior subcapsular opacity. The exact dose-response relationship is not known (Fig. 7.14).

Other toxic cataracts can result from chlorpromazine, miotic agents (especially cholinesterase inhibitors), and busulfan (Myleran) used in the treatment of chronic myelocytic leukemia.

7.4.7 Congenital Cataract

There are many congenital cataracts. They are either hereditary or acquired through the placenta.



Cortisone cataract.

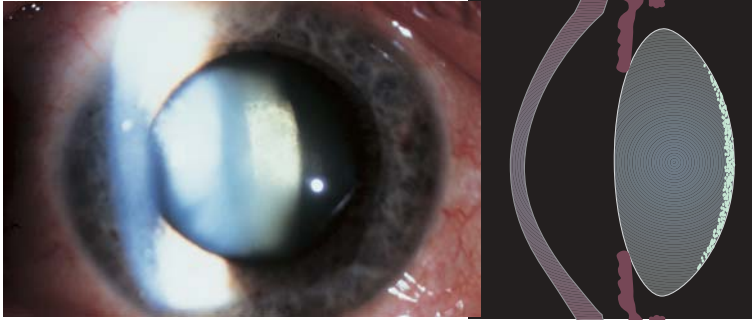


Fig. 7.14 A dense pumice-like opacity develops in the posterior capsule following prolonged systemic steroid therapy for bronchial asthma.

7.4.7.1 Hereditary Congenital Cataracts

Familial forms of congenital cataracts may be autosomal dominant, autosomal recessive, sporadic, or X-linked. They are easily diagnosed on the basis of their characteristic symmetric morphology.

Forms of hereditary congenital cataract:

Lamellar or zonular cataract. Opacities are located in one layer of lens fibers, often as “riders” only in the equatorial region (Fig. 7.15).

Nuclear cataract. This is a variant of the lamellar cataract in which initially only the outer layer of the embryonic nucleus is affected (Fig. 7.16).

Coronary cataract. This is characterized by fine radial opacities in the equatorial region.

Cerulean cataract. This is characterized by fine round or club-shaped blue peripheral lens opacities.



Most familial lens opacities do not impair vision and are not progressive.

This also applies to rare lens opacities involving the capsule such as anterior and posterior polar cataracts, anterior pyramidal cataract, and Mittendorf’s dot (remnant of the embryonic hyaloid artery on the posterior capsule of the lens; see Chapter 11).



Lamellar cataract.

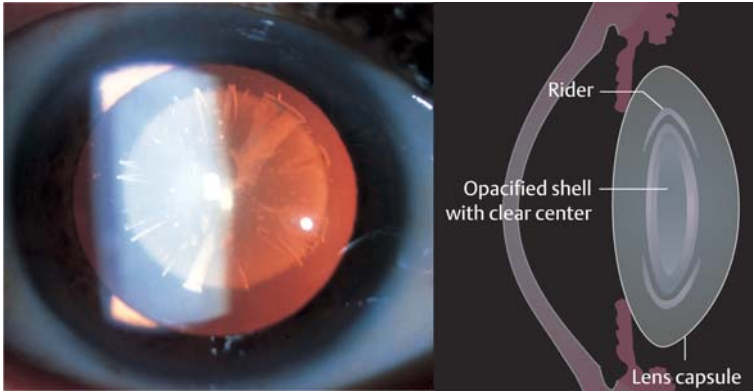


Fig. 7.15 The lens opacities (“riders”) are located in only one layer of lens fibers, often only in the equatorial region as shown here.

Nuclear cataract.

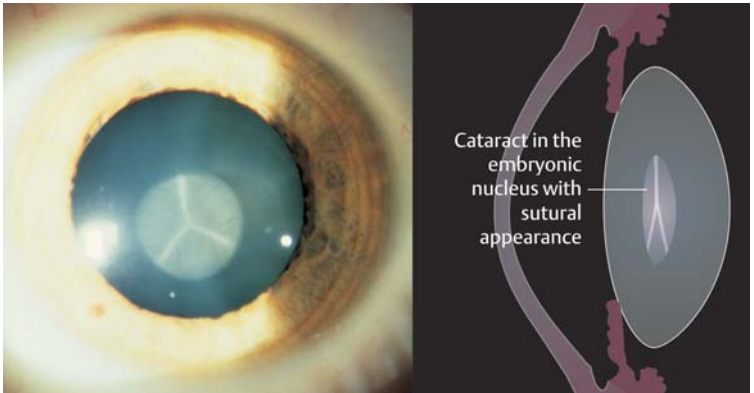


Fig. 7.16 This variant of the lamellar cataract affects only the outer layer of the embryonic nucleus, seen here as a sutural cataract.



7.4.7.2 Cataract from Transplacental Infection in the First Trimester of Pregnancy

A statistical study by Pau (1986) cites the following incidences of congenital cataract with respect to systemic disease contracted by the mother during the first trimester of pregnancy:

- ❖ Rubella 40–60%.
- ❖ Mumps 10–22%.
- ❖ Hepatitis 16%.
- ❖ Toxoplasmosis 5%.

Most of these cases involved *total cataracts* due to virus infection contracted by the mother during early pregnancy. This infection occurred during the fifth to eighth week of pregnancy, the phase in which the lens develops. Because the protective lens capsule has not yet been formed at this time, viruses can invade and opacify the lens tissue.

The most frequent cause of cataract is a rubella infection contracted by the mother, which also produces other developmental anomalies (Gregg's syndrome involving lens opacity, an open ductus arteriosus, and sensorineural hearing loss). The cataract is bilateral and total and may be diagnosed by the presence of leukocoria (white pupil) and chorioretinal scarring secondary to choroiditis.

7.4.8 Treatment of Cataracts

7.4.8.1 Medical Treatment

In spite of theoretical approaches in animal research, the effectiveness of conservative cataract treatment in humans has not been demonstrated.



At present there are no available conservative methods to prevent, delay, or reverse the development of a cataract. Galactosemic cataracts (see p. 179) are the only exception to this rule.

7.4.8.2 Surgical Treatment

Cataract surgery is the most frequently performed procedure in ophthalmology.

When is surgery indicated?

Earlier surgical techniques were dependent upon the maturity of the cataract. This is no longer the case in modern cataract surgery.

- ❖ In the presence of **bilateral cataracts**, the eye with the worse visual acuity should undergo surgery when the patient feels visually handicapped.



However, this threshold will vary depending on the patient's occupational requirements.

- ❖ In the presence of a **unilateral cataract**, the patient is often inclined to postpone surgery as long as vision in the healthy eye is sufficient.
- ❖ In the presence of a **mature cataract**, it is important to advise the patient to undergo surgery as soon as possible.

Will the operation be successful?

The prospect of a successful outcome is important for the patient. Most patients define a successful outcome in terms of a significant improvement in vision. Therefore, it is important that the patient undergoes a thorough pre-operative eye examination to exclude any ocular disorders, aside from the cataract, that may worsen visual acuity and compromise the success of the cataract operation. Such disorders include uncontrolled glaucoma, uveitis, macular degeneration, retinal detachment, atrophy of the optic nerve, and amblyopia.



A detailed history of the patient's other ocular disorders and vision prior to development of the cataract should be obtained before surgery.

Several methods aid in making a **prognosis with respect to expected visual acuity** (retinal resolution) following cataract surgery. These include:

- ❖ *Retinoscopy to determine visual acuity.*
- ❖ *Evaluation of the choroid figure* (in severe opacifications such as a mature cataract).

Reliability of cataract surgery

Cataract surgery is now performed as a microsurgical technique under an operating microscope. Modern techniques, microsurgical instruments, atraumatic suture material (30 μm thin nylon suture thread), and specially trained surgeons have made it possible to successfully perform cataract surgery *without serious complications in 98% of all patients*. The procedure lasts about 30 minutes and, like the postoperative phase, is painless.

Duration of hospitalization

The patient may be *hospitalized for 3 days*, depending on the adequacy of postoperative care at home. Older patients who live alone may be unable to care adequately for themselves and maintain the regime of prescribed medications for the operated eye in the immediate postoperative phase. The operation *may be performed as an outpatient procedure* if the ophthalmologist's practice is able to ensure adequate care.



Possible types of anesthesia

Cataract extraction may be performed under *local anesthesia* or *general anesthesia*. Today, most operations are performed under local anesthesia. Aside from the patient's wishes, there are medical reasons for preferring one form of anesthesia over another:

General anesthesia: This is recommended for patients who are extremely apprehensive and nervous, deaf, or mentally retarded; it is also indicated for patients with Parkinson's disease or rheumatism, who are unable to lie still without pain.

Local anesthesia (retrobulbar, peribulbar, or topical anesthesia): This is recommended for patients with increased anesthesia risks.

Preoperative consultation regarding options for achieving refractive correction (Table 7.4)

Intraocular lens: In 95–98% of all cataract extractions, an intraocular lens (IOL) is implanted in place of the natural lens (*posterior chamber lens*). An eye with an artificial lens is referred to as a *pseudophakia*. The power of the lens required is determined preoperatively by biometry. The IOL refractive power is determined by ultrasonic measurement of axis length, IOL refraction constants, and the refractive power of the cornea. There are two types of intraocular lenses:

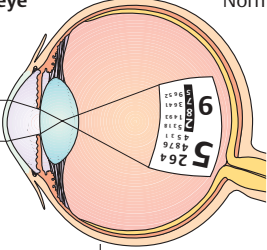
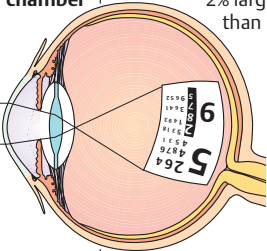
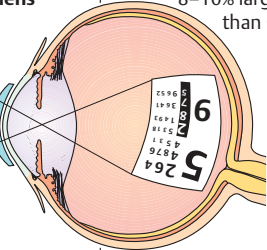
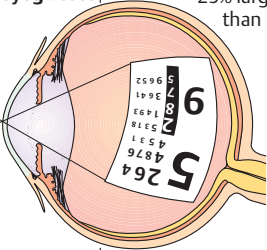
- ❖ **Monofocal IOLs.** The patient can select whether the strength of the artificial lens is suitable for distance vision or near vision.
- ❖ **Bifocal or multifocal IOLs.** These allow close and remote objects to appear in focus. However, it should be noted that bifocal and multifocal lenses do not achieve the optical imaging quality of monofocal lenses.

Cataract eyeglasses: The development of the intraocular lens has largely supplanted correction of postoperative aphakia with cataract lenses. Long the standard, this method is *now only necessary in exceptional cases*. Cataract eyeglasses cannot be used for correcting *unilateral aphakia* because the difference in the size of the retinal images is too great (aniseikonia). Therefore, cataract eyeglasses are only suitable for correcting *bilateral aphakia*. Cataract eyeglasses have the disadvantage of limiting the field of vision (*peripheral and ring scotoma*).

Contact lenses (soft, rigid, and oxygen-permeable): These lenses permit a near normal field of vision and are *suitable for postoperative correction of unilateral cataracts* as the difference in image size is negligible. However, many older patients have difficulty learning how to cope with contact lenses.



Table 7.4 Comparison of normal eye (1), correction of cataract with posterior chamber intraocular lens (2), contact lens (3), cataract eyeglasses (4)

Correction	Monocular image size	Binocular vision: combination	Advantage/ disadvantage
Normal eye ① 	Normal	① can be combined with ② and ③. Difference in image size is small enough for the brain to fuse the images.	Field of vision: full Normal vision
Posterior chamber IOL ② 	2% larger than ①	② can be combined with ①, ②, and ③.	Field of vision: full IOL: No care necessary Visual acuity: (even without eyeglasses) good visual acuity, good orientation
Contact lens ③ 	8–10% larger than ①	③ can be combined with ①, ②, and ③.	Field of vision: full Contact lenses: Care and handling often difficult for older patients Visual acuity: Good with contact lenses, poor orientation without them. Irritation possible; dry eyes preclude contact lenses.
Cataract eyeglasses ④ 	25% larger than ①	④ can only be combined with ④.	Field of vision: Limited (peripheral scotoma) Cataract eyeglasses: Simple to use, heavy, unsatisfactory cosmetic appearance Visual acuity: good with eyeglasses, poor orientation without eyeglasses



Surgical Techniques

The operation is performed on only one eye at a time. The procedure on the fellow eye is performed after about a week if once the first eye has stabilized.

Historical milestones:

- ❖ **Couching** (reclination): For 2000 years until the 19th century, a pointed instrument was used to displace the lens into the vitreous body out of the visual axis.
- ❖ **1746:** J. Daviel performed the **first extracapsular cataract extraction** by removing the contents of the lens through an inferior approach.
- ❖ **1866:** A. von Graefe performed the first removal of a cataract through a **superior limbal incision with capsulotomy**.

Intracapsular cataract extraction: *Until the mid 1980s, this was the method of choice.* Today intracapsular cataract extraction is used only with subluxation or dislocation of the lens. The entire lens is frozen in its capsule with a cryoprobe and removed from the eye through a large superior corneal incision (Fig. 7.17).

Extracapsular cataract extraction: Procedure (Figs. 7.18a – c): The anterior capsule is opened (capsulorrhexis). Then only the cortex and nucleus of the lens are removed (extracapsular extraction); the posterior capsule and zonule suspension remain intact. This provides a stable base for implantation of the posterior chamber intraocular lens.



Extracapsular cataract extraction with implantation of a posterior chamber intraocular lens is now the method of choice.

Intracapsular cataract extraction.

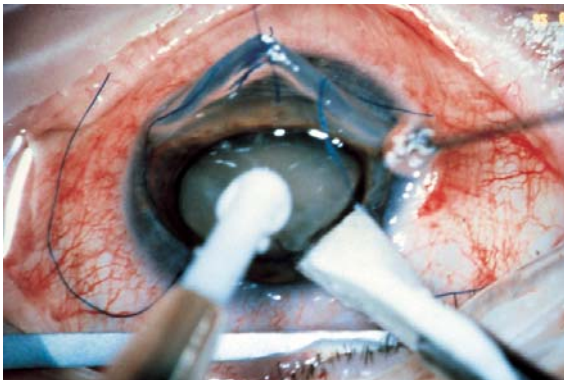


Fig. 7.17 The lens is frozen in its capsule with a cryoprobe and removed from the eye through a large superior corneal incision. The photograph is from the surgeon's perspective.



Extracapsular cataract extraction.

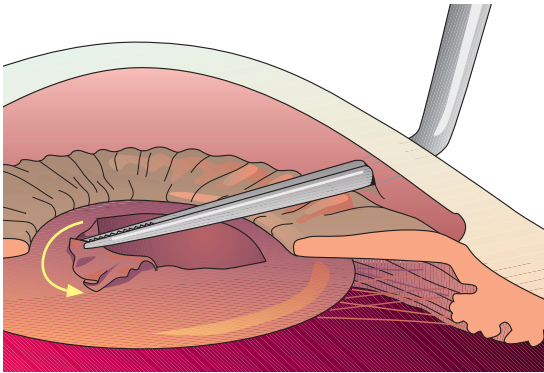
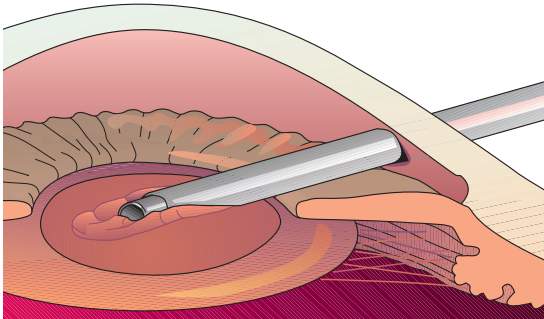
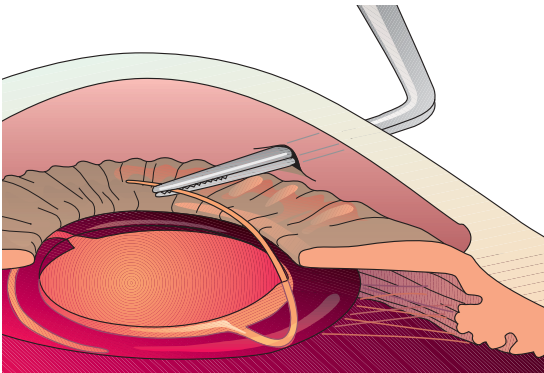


Fig. 7.18 a The anterior capsule of the lens is opened with a continuous curvilinear capsulorhexis.



b The nucleus is destroyed by ultrasound (phacoemulsification), and the fragments of the nucleus and cortex are aspirated.



c A posterior chamber intraocular lens is implanted in the capsular bag.



Today *phacoemulsification* (emulsifying and aspirating the nucleus of the lens with a high-frequency ultrasonic needle) is the preferred technique for removing the nucleus. Where the nucleus is very hard, the entire nucleus is expressed or aspirated. Then the softer portions of the cortex are removed by suction with an aspirator/irrigator attachment in an aspiration/irrigation maneuver. The posterior capsule is then polished, and an intraocular lens (IOL) is implanted in the empty capsular bag (Fig. 7.19a and b). Phacoemulsification and IOL implantation require an incision only 3–6 mm in length. Where a tunnel technique is used to make this incision, no suture will be necessary as the wound will close itself.

Patient with posterior chamber intraocular lens.

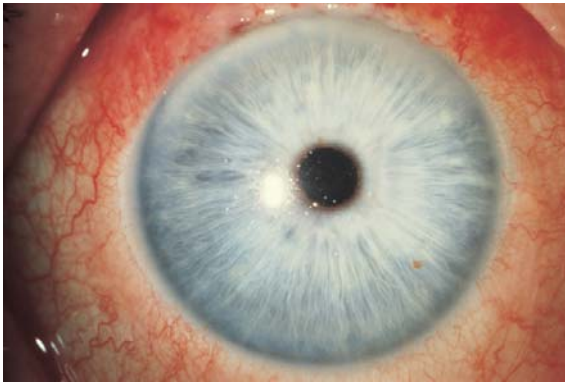
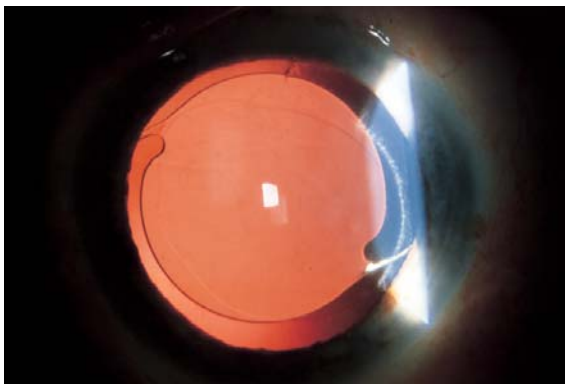


Fig. 7.19 a The IOL is not noticeable in a normal pupil that is not under the influence of medication.



b The same patient after dilation of the pupils with a mydriatic. The IOL is discernible under retroillumination.



Advantages over intracapsular cataract extraction. Extracapsular cataract extraction usually does not achieve the same broad exposure of the retina that intracapsular cataract extraction does, particularly where a secondary cataract is present. However, the extracapsular cataract extraction maintains the integrity of the anterior and posterior chambers of the eye, and the vitreous body cannot prolapse anteriorly as after intracapsular cataract extraction. At 0.1–0.2%, the incidence of retinal detachment after extracapsular cataract extraction is about ten times less than after intracapsular cataract extraction, which has an incidence of 2–3%.

7.4.8.3 Secondary Cataract

Epidemiology: Approximately 30% of all cataract patients develop a secondary cataract after extracapsular cataract extraction.

Etiology: Extracapsular cataract extraction removes only the anterior central portion of the capsule and leaves epithelial cells of the lens intact along with remnants of the capsule. These epithelial cells are capable of reproducing and can produce a secondary cataract of fibrous or regenerative tissue in the posterior capsule that diminishes visual acuity (Fig. 7.20a).

Treatment: A neodymium:yttrium-aluminum-garnet (Nd:YAG) laser can incise the posterior capsule in the visual axis without requiring invasive eye surgery. This immediately improves vision (Fig. 7.20b).

7.4.8.4 Special Considerations in Cataract Surgery in Children

Observe changes in the child's behavior: Children with congenital, traumatic, or metabolic cataract will not necessarily communicate their visual impairment verbally. However, it can be diagnosed from these **symptoms**:

- ❖ Leukocoria.
- ❖ Oculodigital phenomenon: The child presses his or her finger against the eye or eyes because this can produce light patterns the child finds interesting.
- ❖ Strabismus: the first sign of visual impairment (Fig. 7.21).
- ❖ The child cries when the normal eye is covered.
- ❖ The child has difficulty walking or grasping.
- ❖ Erratic eye movement is present.
- ❖ Nystagmus.

Operate as early as possible: Retinal fixation and cortical visual responses develop within the first six months of life. This means that children who undergo surgery after the age of one year have *significantly poorer chances* of developing normal vision.



Secondary cataract.

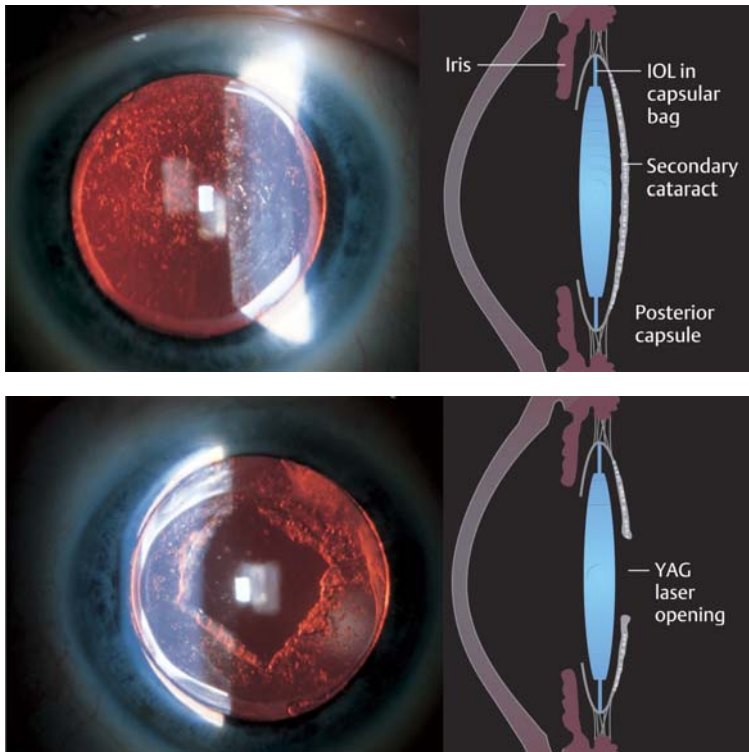


Fig. 7.20 **a** Regenerative secondary cataracts lead to diminished visual acuity and increased glare. **b** Nd:YAG laser capsulotomy: the posterior capsulotomy removes the obstruction of the visual axis, and immediately improves vision.



Children with congenital cataract should undergo surgery as early as possible to avoid amblyopia.

The prognosis for successful surgery is less favorable for *unilateral cataracts* than for bilateral cataracts. This is because the amblyopia of the cataract eye puts it at an irreversible disadvantage in comparison with the fellow eye as the child learns how to see.

Plan for the future when performing surgery: After opening the extremely elastic anterior lens capsule, one can aspirate the soft infantile cortex and

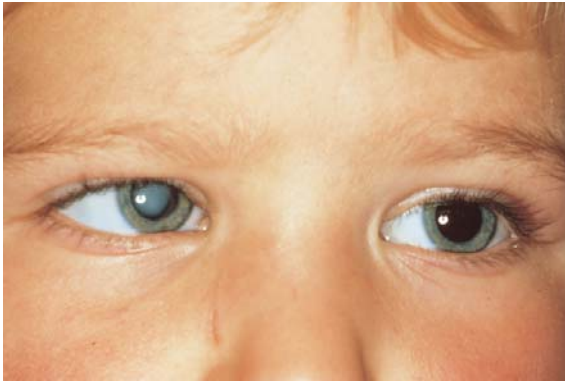**Congenital cataract.**

Fig. 7.21 One-and-one-half-year-old child with congenital cataract (leukocoria) and esotropia of the right eye.

nucleus. *Secondary cataracts are frequent complications in infants.* Therefore, the procedure should include a *posterior capsulotomy with anterior vitrectomy* to ensure an unobstructed visual axis. The operation *preserves the equatorial portions of the capsule* to permit subsequent implantation of a posterior chamber intraocular lens in later years.

Refraction changes constantly: The refractive power of the eye changes dramatically within a short period of time as the eye grows. The refraction in the eye of a newborn is 30–35 diopters and drops to 15–25 diopters within the first year of life. Refractive compensation for a **unilateral cataract** is achieved with a *soft contact lens* (Fig. 7.22). The use of soft contact lenses in infants is difficult and requires the parents' intensive cooperation. Refractive correction of **bilateral cataracts** is achieved with *cataract eyeglasses*.

! Refraction should be evaluated by retinoscopy (see Chapter 16) every two months during the first year of life and every three to four months during the second year, and contact lenses and eyeglasses should be changed accordingly.

Implantation of posterior chamber intraocular lenses for congenital cataract is not yet recommended in children under three years of age. This is because experience with the posterior chamber intraocular lens and present follow-up periods are significantly less than the life expectancy of the children. In addition, there is no way to adapt the refractive power of the lens to changing refraction of the eye as the child grows.

Orthoptic postoperative therapy is required: *Unilateral cataracts* in particular require orthoptic postoperative therapy in the operated eye to close the



Refractive compensation with soft contact lens.

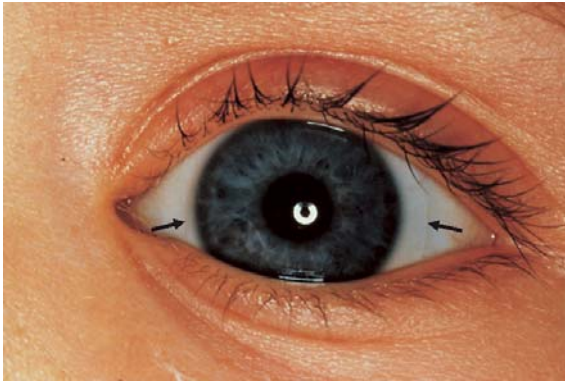


Fig. 7.22 In a unilateral cataract, a contact lens provide refractive compensation (the arrows indicate the edge of the contact lens).

gap with respect to the normal fellow eye. Regular evaluation of retinal fixation is indicated, as is amblyopia treatment (see patching).

7.5 Lens Dislocation

Definition

- ❖ **Subluxation (partial dislocation):** The suspension of the lens (the zonule fibers) is slackened, and the lens is only partially within the hyaloid fossa (Fig. 7.23).
- ❖ **Luxation (complete dislocation):** The lens is torn completely free and has migrated into the vitreous body or, less frequently, into the anterior chamber.

Etiology: There are several causes of lens dislocation (Table 7.5). *Most frequently*, it is due to **trauma** (see contusion of the eyeball). Later in life, **pseudoexfoliation** may also lead to subluxation or luxation of the lens. **Hereditary causes** and **metabolic disease** produce lens displacement *early* yet on the whole are *rare*. *Additional rare causes* include **hyperlysinemia** (characterized by retarded mental development and seizures) and **sulfite oxidase deficiency** (which leads to mental retardation and excretion of cysteine in the urine).



The most frequent atraumatic causes of lens dislocation are Marfan's syndrome, homocystinuria, and Weill-Marchesani syndrome.



Table 7.5 Etiology of lens displacement

Causes	Lens displacement
❖ Hereditary causes (rare)	
<ul style="list-style-type: none">– Ectopia lentis: isolated and monosymptomatic.– Marfan's syndrome: characterized by arachnodactyly, long limbs, and laxness of joints.– Weill-Marchesani syndrome: symptoms include short stature and brachydactyly.– Homocystinuria (metabolic disease): characterized by oligophrenia, osteoporosis, and skeletal deformities.	<ul style="list-style-type: none">– Complete or partial displacement of the lens (for example, into the anterior chamber).– Lens is abnormally round; lens displacement is usually superior and temporal; zonule fibers are elongated but frequently intact.– Lens is abnormally round and often too small; lens is usually eccentric and displaced inferiorly.– Lens displacement is usually medial and inferior; torn zonule fibers appear as a “permanent wave” on the lens.
❖ Acquired causes	
<ul style="list-style-type: none">– Trauma (probably the most frequent cause).– Pseudoexfoliation (in advanced age).– Ciliary body tumor (rare).– Large eyes with severe myopia and buphthalmos (rare).	<ul style="list-style-type: none">– Zonule defects due to deformation can cause subluxation or luxation of the lens.– Zonule weakness due to loosening of the insertion of the fibers on the lens can cause lens displacement.– Lens is displaced by tumor.– Zonule defects due to excessive longitudinal growth can cause lens displacement.

Symptoms: Slight displacement may be of no functional significance to the patient. More pronounced displacement produces severe optical distortion with loss of visual acuity.

Diagnostic considerations: Cardinal symptoms include tremulous motion of the iris and lens when the eye moves (iridodonesis and phacodonesis). These symptoms are detectable under slit-lamp examination.

Treatment: Optical considerations (see symptoms) and the risk of secondary angle closure glaucoma from protrusion of the iris and dislocation of the lens into the anterior chamber are indications for removal of the lens.

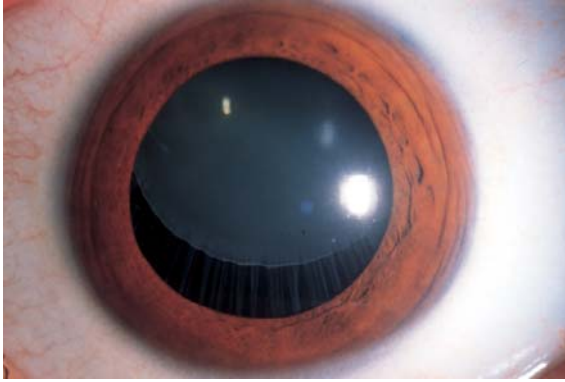
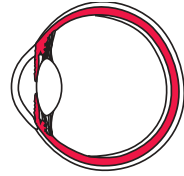
**Subluxation of the lens in Marfan's syndrome.**

Fig. 7.23 The lens is displaced superiorly and medially. As the zonule fibers are intact, a certain measure of accommodation is still possible.

8 Uveal Tract (Vascular pigmented layer)

Gabriele E. Lang and Gerhard K. Lang



8.1 Basic Knowledge

Structure: The uveal tract (also known as the vascular pigmented layer, vascular tunic, and uvea) takes its name from the Latin *uva* (grape) because the dark pigmentation and shape of the structure are reminiscent of a grape. The uveal tract consists of the following structures:

- ❖ **Iris,**
- ❖ **Ciliary body,**
- ❖ **Choroid.**

Position: The uveal tract lies between the sclera and retina.

Neurovascular supply: Arterial supply to the uveal tract is provided by the *ophthalmic artery*.

- ❖ The *short posterior ciliary arteries* enter the eyeball with the optic nerve and supply the *choroid*.
- ❖ The *long posterior ciliary arteries* course along the interior surface of the sclera to the *ciliary body* and the *iris*. They form the major arterial circle at the root of the iris and the minor arterial circle in the collarette of the iris. The *anterior ciliary arteries* originate from the vessels of the rectus muscles and communicate with the *posterior ciliary vessels*.

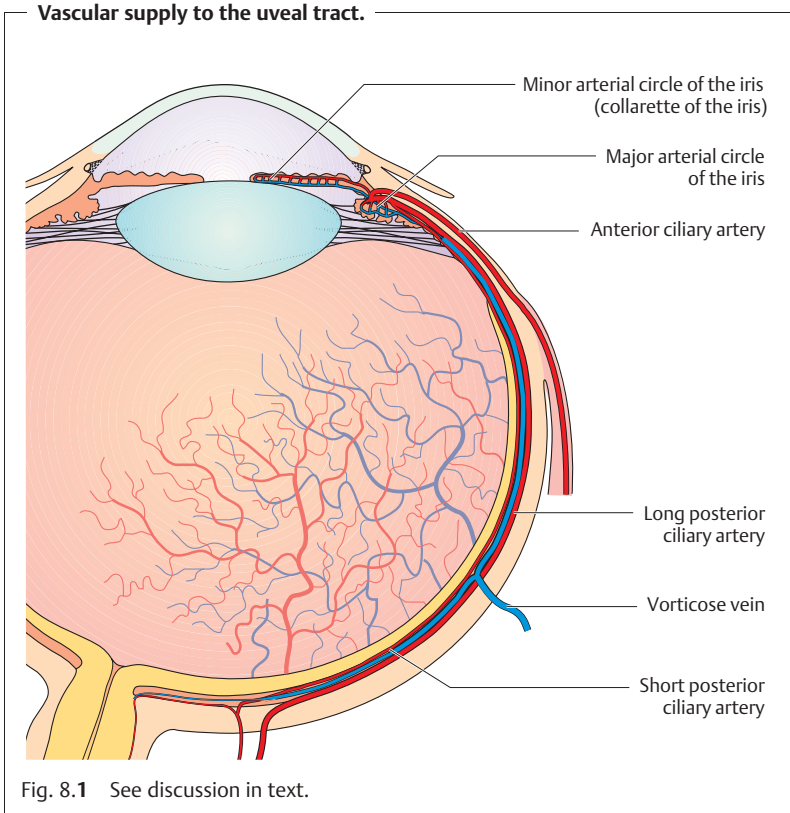
Venous blood drains through four to eight *vorticoses or vortex veins* that penetrate the sclera posterior to the equator and join the superior and inferior ophthalmic veins (Fig. 8.1). **Sensory supply** is provided by the *long and short ciliary nerves*.

8.1.1 Iris

Structure and function: The iris consists of two layers:

- ❖ The **anterior mesodermal stromal layer.**
- ❖ The **posterior ectodermal pigmented epithelial layer.**

The posterior layer is opaque and protects the eye against excessive incident light. The anterior surface of the lens and the pigmented layer are so close together near the pupil that they can easily form adhesions in inflammation.



The **collarrete of the iris** covering the minor arterial circle of the iris divides the stroma into *pupillary* and *ciliary* portions. The pupillary portion contains the **sphincter muscle**, which is supplied by parasympathetic nerve fibers, and the **dilator pupillae muscle**, supplied by sympathetic nerve fibers. These muscles regulate the contraction and dilation of the pupil so that the iris may be regarded as the **aperture** of the optical system of the eye.



Pupil dilation is sometimes sluggish in preterm infants and the newborn because the dilator pupillae muscle develops relatively late.

Surface: The normal iris has a richly textured surface structure with **crypts** (tissue gaps) and interlinked **trabeculae**. A faded surface structure *can* be a sign of inflammation (see iridocyclitis).



Color: The color of the iris varies in the individual according to the **melanin content of the melanocytes (pigment cells)** in the *stroma* and *epithelial layer*. Eyes with a high melanin content are dark brown, whereas eyes with less melanin are grayish-blue. **Caucasians at birth** always have a grayish-blue iris as the *pigmented layer* only develops gradually during the first year of life. Even in **albinos** (see impaired melanin synthesis), the eyes have a grayish-blue iris because of the melanin deficiency. Under slit lamp retroillumination they appear reddish due to the fundus reflex.

8.1.2 Ciliary Body

Position and structure: The **ciliary body** extends from the root of the iris to the ora serrata, where it joins the choroid. It consists of *anterior pars plicata* and the *posterior pars plana*, which lies 3.5 mm posterior to the limbus. Numerous **ciliary processes** extend into the posterior chamber of the eye. The suspensory ligament, the zonule, extends from the pars plana and the intervals between the ciliary processes to the lens capsule.

Function: The *ciliary muscle* is responsible for **accommodation**. The double-layered *epithelium covering the ciliary body* **produces the aqueous humor**.

8.1.3 Choroid

Position and structure: The choroid is the **middle tunic of the eyeball**. It is bounded on the interior by *Bruch's membrane*. The choroid is highly vascularized, containing a vessel layer with large blood vessels and a capillary layer. The blood flow through the choroid is the *highest in the entire body*.

Function: The choroid **regulates temperature** and supplies **nourishment to the outer layers of the retina**.

8.2 Examination Methods

The *slit lamp* is used to examine the **surface of the iris** under a focused beam of light. *Normally no vessels will be visible*.



Iris vessels are only visible in atrophy of the iris, inflammation, or as neovascularization in rubeosis iridis (see Fig. 8.12).

Where vessels are present, they can be visualized by *iris angiography* after intravenous injection of fluorescein sodium dye.

Defects in the pigmented layer of the iris appear red under retroillumination with a slit lamp (see Fig. 8.6). *Slit lamp biomicroscopy* visualizes individual cells such as melanin cells at 40-power magnification.

The *anterior chamber* is *normally transparent*. Inflammation can increase the permeability of the **vessels of the iris** and compromise the barrier



between blood and aqueous humor. *Opacification of the aqueous humor* by proteins may be observed with the aid of a *slit lamp* when the eye is illuminated with a lateral focal beam of light (Tyndall effect). This method can also be used to diagnose *cells in the anterior chamber* in the presence of inflammation.

Direct inspection of the **root of the iris** is not possible because it does not lie within the line of sight. However, it can be indirectly visualized by *gonioscopy*. Inspection of the **posterior portion of the pars plana** requires a *three-mirror lens*. The globe is also indented with a metal rod to permit visualization of this part of the ciliary body (for example in the presence of a suspected malignant melanoma of the ciliary body).

The pigmented epithelium of the retina permits only limited evaluation of the **choroid** by *ophthalmoscopy* and *fluorescein angiography* or indocyanine green angiography. Changes in the choroid such as tumors or hemangiomas can be visualized by ultrasound examination. Where a **tumor is suspected**, transillumination of the eye is indicated. After administration of topical anesthesia, a fiberoptic light source is placed on the eyeball to *visualize the shadow of the tumor on the red of the fundus*.

8.3 Developmental Anomalies

8.3.1 Aniridia

Aniridia is the **absence of the iris**. This **generally bilateral** condition is *transmitted as an autosomal dominant trait* or occurs *sporadically*. Aniridia may also be traumatic and can result from penetrating injuries. However, peripheral remnants of the iris are usually still present so that ciliary villi and zonule fibers will be visualized under slit-lamp examination (Fig. 8.2).



In sporadic aniridia, a Wilms' tumor of the kidney should be excluded.

Vision is severely compromised as a result of the foveal hypoplasia. The disorder is frequently associated with nystagmus, amblyopia, buphthalmos, and cataract.



Visual acuity will generally be reduced in the presence of nystagmus.



Aniridia.

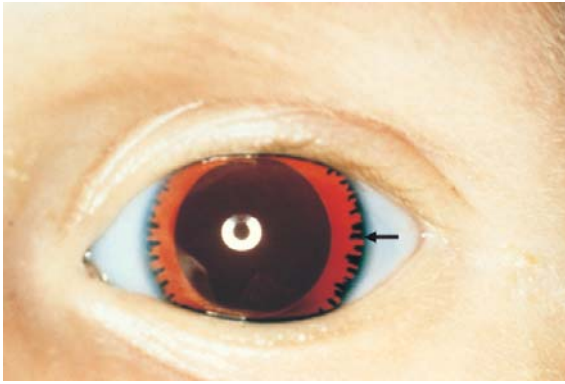


Fig. 8.2 The ciliary villi (arrow) and the lens are visible under slit-lamp retroillumination.

8.3.2 Coloboma

Another congenital anomaly results from **incomplete fusion of the embryonic optic cup**, which normally occurs in about the sixth week of pregnancy. These anomalies are known as **colobomas**. They are directed medially and inferiorly and can involve the iris (Fig. 8.3), ciliary body, zonule fibers, choroid, and optic nerve (Fig. 8.4). **Bridge colobomas** exhibit remnants of the iris or choroid. Involvement of the choroid and optic nerve frequently leads to *reduced visual acuity*.

Surgical iris colobomas in cataract and glaucoma surgery are usually opened superiorly. In this manner, they are covered by the upper eyelid so the patient will not usually experience blinding glare.

Traumatic iris colobomas are caused by avulsion of the iris (iridolysis; Fig. 8.5).



Congenital iris coloboma.

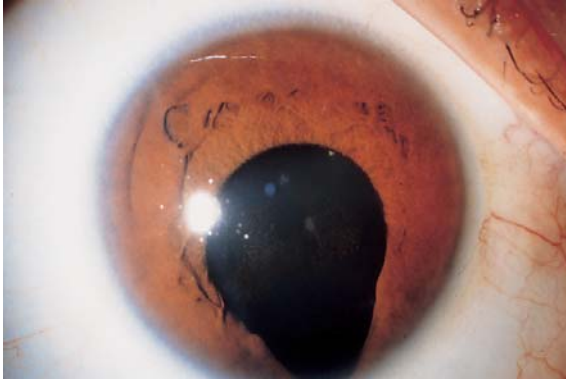


Fig. 8.3 The congenital iris coloboma is located medially and inferiorly. The pupil merges with the coloboma without any sharp demarcation.

Coloboma of the retina, choroid, and optic nerve.

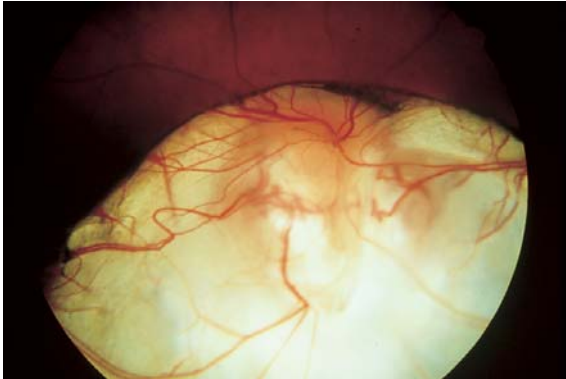




Fig. 8.4 The coloboma of the retina, choroid, and optic nerve exposes the underlying white sclera.




Various iris changes.




Congenital medial and inferior iris coloboma



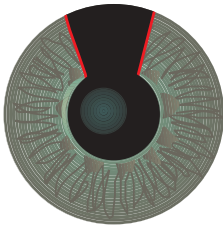
Cloverleaf pupil due to posterior synechiae



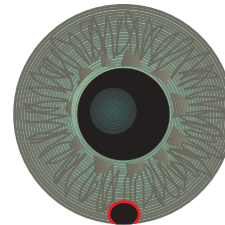
Traumatic iris avulsion (iridolysis)



Surgical basal iris coloboma



Surgical segmental iris coloboma



Ando's surgical iridectomy

Fig. 8.5 See discussion on p. 203.



8.4 Pigmentation Anomalies

8.4.1 Heterochromia

Impaired development of the pigmentation of the iris can lead to a congenital **difference in coloration between the left and right iris (heterochromia)**. One iris containing varying pigmentation is referred to as **iris bicolor**. Isolated heterochromia is not necessarily clinically significant (simple heterochromia), yet it can be a sign of abnormal changes. The following types are differentiated:

- ❖ **Fuchs' heterochromic cyclitis** (etiology unclear): This refers to *recurrent iridocyclitis* (simultaneous inflammation of several portions of the uveal tract) in adults, with *precipitates on the posterior surface of the cornea* without formation of posterior synechiae (adhesions between the iris and lens). The eye is *free of external irritation*. This disorder is often associated with complicated cataract and increased intraocular pressure (glaucoma).
- ❖ **Sympathetic heterochromia**: In *unilateral impairment of the sympathetic nerve supply*, the affected iris is significantly lighter. Heterochromia with unilaterally lighter pigmentation of the iris also occurs in iridocyclitis, acute glaucoma, and anterior chamber hemorrhage (hyphema).
- ❖ **Melanosis of the iris**: This refers to *dark pigmentation* of one iris.

Aside from the difference in coloration between the two irises, neither sympathetic heterochromia nor melanosis leads to further symptoms. The only form of heterochromia that leads to abnormal changes is Fuchs' heterochromic cyclitis. The possible complications involved require specific treatment.

8.4.2 Albinism

Albinism (from the Latin *albus* = white) is a congenital **metabolic disease that leads to hypopigmentation of the eye**. The following types are differentiated:

- ❖ **ocular albinism** (involving only the eyes) and
- ❖ **oculocutaneous albinism** (involving the eyes, skin, and hair).

In albinism the iris is light blue because of the melanin deficiency resulting from impaired melanin synthesis. Under slit-lamp retroillumination, the *iris appears reddish* due to fundus reflex (Fig. 8.6). Ophthalmoscopy will detect *choroidal vessels* (Fig. 8.7). Associated foveal aplasia results in significant *reduction in visual acuity* and *nystagmus*. Most patients are also *photophobic* because of the missing filter function of the pigmented layer of the iris.

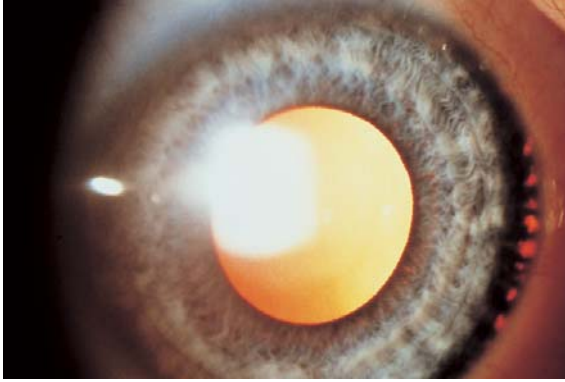
**Ocular albinism.**

Fig. 8.6 The peripheral iris appears red under retroillumination.

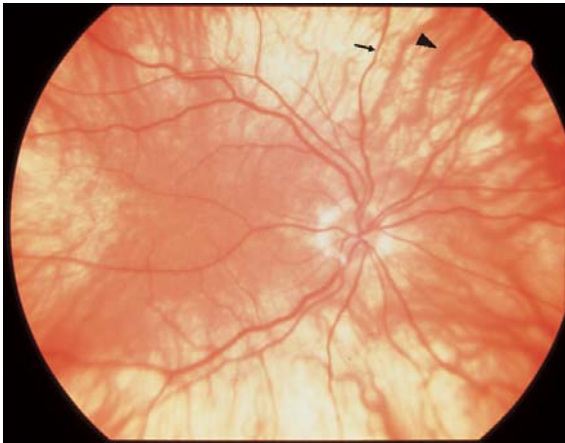
Fundus in ocular albinism.

Fig. 8.7 Typical features include the choroidal vessels, which are visualized by ophthalmoscopy (choroidal vessel, thick arrowhead; retinal vessel, arrow).



8.5 Inflammation

Inflammations of the uveal tract are classified according to the various portions of the globe:

- ❖ Anterior uveitis (**iritis**).
- ❖ Intermediate uveitis (**cyclitis**).
- ❖ Posterior uveitis (**choroiditis**). However, some inflammations involve the middle portions of the uveal tract such as **iridocyclitis** (inflammation of the iris and ciliary body) or **panuveitis** (inflammation involving all segments).

8.5.1 Acute Iritis and Iridocyclitis

Epidemiology: **Iritis** is the most frequent form of uveitis. It usually occurs in combination with cyclitis. About three-quarters of all **iridocyclitis** cases have an acute clinical course.

Etiology: Iridocyclitis is frequently attributable to **immunologic causes** such as allergic or hyperergic reaction to bacterial toxins. In some rheumatic disorders it is known to be frequently associated with the expression of specific human leukocyte antigens (HLA) such as HLA-B27. Iridocyclitis can also be a **symptom of systemic disease** such as ankylosing spondylitis, Reiter's syndrome, sarcoidosis, etc. (Table 8.1). **Infections** are less frequent and occur secondary to penetrating trauma or sepsis (bacteria, viruses, mycosis, or parasites). *Phacogenic inflammation*, possibly with glaucoma, can result when the lens becomes involved.

Symptoms: Patients report dull pain in the eye or forehead accompanied by impaired vision, photophobia, and excessive tearing (epiphora).



In contrast to choroiditis, acute iritis or iridocyclitis is painful because of the involvement of the ciliary nerves.

Diagnostic considerations: Typical signs include:

- ❖ **Ciliary injection:** The episcleral and perilimbal vessels may appear blue and red.
- ❖ **Combined injection:** The conjunctiva is also affected.

The **iris** is **hyperemic** (the iris vessels will be visible in a light-colored iris). The **structure** appears **diffuse** and **reactive miosis** is present.

Vision is impaired because of cellular infiltration of the anterior chamber and protein or fibrin accumulation (visible as a **Tyndall effect**). The precipitates accumulate on the posterior surface of the cornea in a triangular configuration known as Arlt's triangle. Exudate accumulation on the floor of the anterior chamber is referred to as **hypopyon** (Fig. 8.8). Viral infections may be accompanied by bleeding into the anterior chamber (**hyphema**; Fig. 8.9). Corneal edema can also develop in rare cases.



Table 8.1 Causes of uveitis according to location

Form of uveitis	Possible causes
HLA-B27-associated iridocyclitis	<ul style="list-style-type: none"> ❖ Idiopathic ❖ Ankylosing spondylitis ❖ Reiter's syndrome ❖ Regional enteritis ❖ Ulcerative colitis ❖ Psoriasis
Non-HLA-B27-associated iridocyclitis	<ul style="list-style-type: none"> ❖ Idiopathic ❖ Viral ❖ Tuberculosis ❖ Sarcoidosis ❖ Syphilis ❖ Leprosy ❖ Rheumatoid arthritis (Still-Chauffard syndrome) ❖ Heterochromic cyclitis ❖ Phacogenic uveitis ❖ Trauma
Iridocyclitis and choroiditis	<ul style="list-style-type: none"> ❖ Toxoplasmosis ❖ Sarcoidosis ❖ Tuberculosis ❖ Syphilis ❖ Behçet's disease ❖ Sympathetic ophthalmia ❖ Borreliosis ❖ Brucellosis ❖ Yersiniosis ❖ Listeriosis ❖ Malignant tumors
Choroiditis	<ul style="list-style-type: none"> ❖ Toxoplasmosis ❖ Sarcoidosis ❖ Syphilis ❖ Behçet's disease ❖ Histoplasmosis ❖ Toxocara



Hypopyon in acute iridocyclitis.

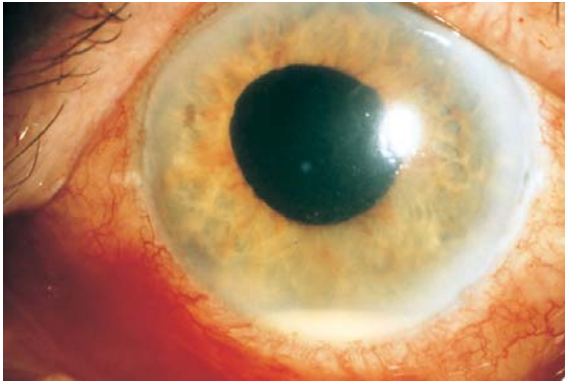


Fig. 8.8 The purulent exudate accumulates as a pool on the floor of the anterior chamber.

Hyphema.

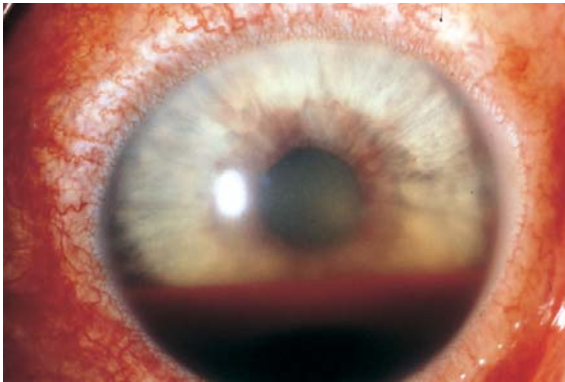

Fig. 8.9 Bleeding into the anterior chamber can occur in rubeosis iridis, trauma, or, in rare cases, iridocyclitis.



Corneal edemas and Tyndall effects (accumulations of protein in the anterior chamber) can be diagnosed when the eye is illuminated with a lateral beam of light from a focused light or slit lamp.

Differential diagnosis: See Table 8.2.



In acute iritis, the depth of the anterior chamber is normal and reactive miosis is present. In contrast, in acute glaucoma the anterior chamber is shallow and the pupil is dilated (Table 8.2).



Table 8.2 Differential diagnosis of iritis and acute glaucoma

Differential criteria	Acute iritis	Acute glaucoma
Symptoms	Dull pain and photophobia	Intense pain and vomiting
Conjunctiva	Combined injection	Combined injection
Cornea	Clear	Opacified, edematous
Anterior chamber	Normal depth; cells and fibrin are present	Shallow
Pupil	Narrowed (reactive miosis)	Dilated, not round
Globe	Normal pressure	Rock hard

Complications: These include:

- ❖ **Secondary open angle glaucoma** with an increase in intraocular pressure.
- ❖ Adhesions between the iris and posterior surface of the cornea (**anterior synechiae**).
- ❖ Adhesions between the iris and lens (**posterior synechiae**; Fig. 8.10).

Treatment: Topical and, in appropriate cases, systemic antibiotic or antiviral therapy is indicated for iridocyclitis due to a pathogen (with a corneal ulcer, penetrating trauma, or sepsis).

Posterior synechiae secondary to iridocyclitis (cloverleaf pupil).

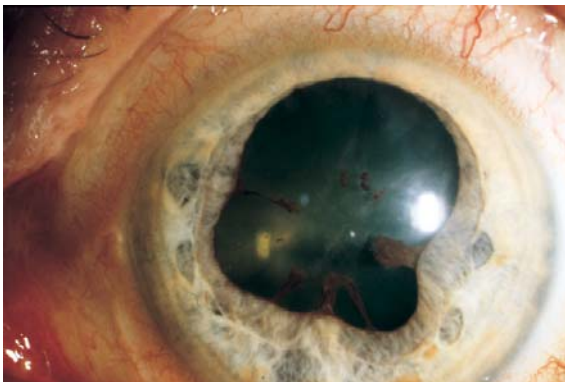

Fig. 8.10 Acute iridocyclitis produces adhesions between the iris and lens (see also Fig. 8.5).



A conjunctival smear, or a blood culture in septic cases, is obtained to identify the pathogen. Antibiotic therapy should begin immediately as microbiological identification of the pathogen is not always successful.

Therapeutic mydriasis in combination with steroid therapy is indicated to **minimize the risk of synechiae**.

Where no pathogen can be identified, high-dose topical steroid therapy (prednisolone eyedrops every hour in combination with subconjunctival injections of soluble dexamethasone) is administered. To minimize the risk of *posterior synechiae*, the pupil must be maximally dilated (atropine, scopolamine, cyclopentolate, and possibly epinephrine and epinephrine eye-drops).



The mydriatic effect of dilating eyedrops may be reduced in iritis. This may necessitate the use of longer-acting medications such as atropine, which may have to be applied several times daily.

Occasionally it is possible to break off **existing synechiae** in this manner, and patches of iris tissue will remain on the anterior surface of the lens. **Secondary open angle glaucoma** is treated by administering beta blockers in eye-drop form and, in applicable cases, carbonic anhydrase inhibitors (acetazolamide; see Table 10.3).

Prognosis: Symptoms usually improve within a few days when proper therapy is initiated. The disorder can progress to a chronic stage.

8.5.2 Chronic Iritis and Iridocyclitis

Epidemiology: About one quarter of all **iridocyclitis** cases have a chronic clinical course.

Etiology: See Table 8.1.

Symptoms: See acute iridocyclitis. Chronic iridocyclitis may exhibit minimal symptoms.

Diagnostic considerations: See acute iridocyclitis.

Differential diagnosis: The disorder should be distinguished from acute glaucoma, conjunctivitis, and keratitis.

Complications: Total obliteration of the pupil by posterior synechiae is referred to a **pupillary block**. Because the aqueous humor can no longer circulate, **secondary angle closure glaucoma with iris bombé** occurs. **Occlusion of the pupil** also results in fibrous scarring in the pupil. This can lead to the development of posterior subcapsular opacities in the lens (**secondary cataract**). Recurrent iridocyclitis can also lead to calcific band keratopathy.



Treatment: In **pupillary block** with a secondary angle closure glaucoma, a *Nd:YAG laser iridotomy* may be performed to create a shunt to allow the aqueous humor from the posterior chamber to circulate into the anterior chamber. In the presence of a **secondary cataract**, a cataract *extraction* may be performed when the inflammation has abated.

Prognosis: Because of the chronic recurrent course of the disorder, it frequently involves complications such as synechiae or cataract that may progress to blindness from shrinkage of the eyeball.

8.5.3 Choroiditis

Epidemiology: There are few epidemiologic studies of choroiditis. The annual incidence is assumed to be four cases per 100 000 people.

Etiology: See Table 8.1.

Symptoms: Patients are free of pain, although they report blurred vision and floaters.



Choroiditis is painless as the choroid is devoid of sensory nerve fibers.

Diagnostic considerations: Ophthalmoscopy reveals isolated or multiple choroiditis foci. In *acute disease* they appear as ill-defined white dots (Fig. 8.11). *Once scarring has occurred* the foci are sharply demarcated with a yellowish-brown color. Occasionally the major choroidal vessels will be visible through the atrophic scars.

Multifocal choroiditis.

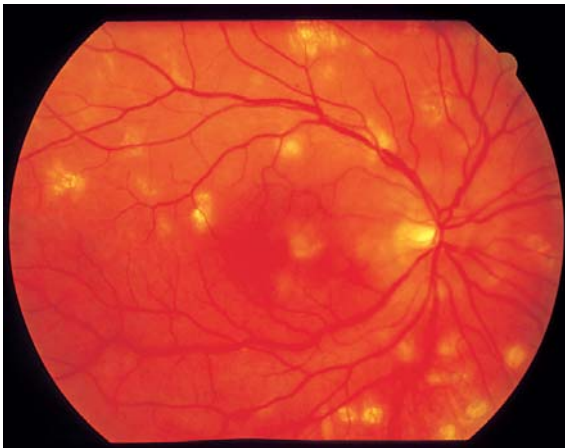


Fig. 8.11 The foci of acute inflammation are yellowish and ill-defined; older lesions are yellowish-brown and sharply demarcated.



No cells will be found in the vitreous body in a **primary choroidal process**. However, inflammation proceeding from the retina (**retinochoroiditis**) will exhibit *cellular infiltration of the vitreous body*.

Differential diagnosis: This disorder should be distinguished from retinal inflammations, which are accompanied by cellular infiltration of the vitreous body and are most frequently caused by viruses or *Toxoplasma gondii*.

Treatment: Choroiditis is treated either with antibiotics or steroids, depending on its etiology.

Prognosis: The inflammatory foci will heal within two to six weeks and form chorioretinal scars. The scars will result in localized scotomas that will reduce visual acuity if the macula is affected.

8.5.4 Sympathetic Ophthalmia

Definition

Specific bilateral inflammation of the uveal tract due to chronic irritation of one eye, caused by a perforating wound to the eye or intraocular surgery, produces transferred uveitis in the fellow eye.

Epidemiology: Sympathetic ophthalmia is very rare.

Etiology: Sympathetic uveitis can occur in an *otherwise unaffected eye* even years after penetrating injuries or intraocular surgery in the fellow eye, especially where there was chronic irritation. Tissues in the injured eye (uveal tract, lens, and retina) act as antigens and provoke an autoimmune disorder in the unaffected eye.

Symptoms: The earliest symptoms include limited range of accommodation and photophobia. Later there is diminished visual acuity and pain.

Diagnostic considerations: Clinical symptoms include combined injections, cells and protein in the anterior chamber and vitreous body, papillary and retinal edema, and granulomatous inflammation of the choroid.

Differential diagnosis: The disorder should be distinguished from iridocyclitis and choroiditis from other causes (see Table 8.1).

Treatment: The injured eye, which is usually blind, must be enucleated to eliminate the antigen. High-dose topical and systemic steroid therapy is indicated. Concurrent treatment with immunosuppressives (cyclophosphamide and azathioprine) may be necessary.

Clinical course and complications: The disorder has a chronic clinical course and may involve severe complications of uveitis such as secondary glaucoma,



secondary cataract, retinal detachment, and shrinkage of the eyeball. Sympathetic ophthalmia can lead to blindness in particularly severe cases.



When the injured eye is blind, prophylactic enucleation is indicated before the onset of sympathetic ophthalmia in the fellow eye. An early sign of sympathetic ophthalmia is a limited range of accommodation with photophobia.

8.6 Neovascularization in the Iris: Rubeosis Iridis

Definition:

Rubeosis iridis is neovascularization in the iris that occurs in various retinal disorders.

Etiology: The most frequent causes of rubeosis iridis (Fig. 8.12) are *proliferative diabetic retinopathy* and *retinal vein occlusion*. Retinal periphlebitis is a less frequent cause of neovascularization in the iris.

Symptoms and diagnostic considerations: Neovascularization in the stroma of the iris is *asymptomatic* for the patient. Neovascularization in the angle of the anterior chamber is irreversible and produces secondary angle closure glaucoma with the typical *symptoms of acute glaucoma*: loss of visual acuity, intense pain, conjunctival and ciliary injection, and a “rock hard” eyeball upon palpation (see Fig. 10.17).

Differential diagnosis: Acute glaucoma due to other causes such as acute angle closure glaucoma should be excluded.

Neovascularization in the iris: rubeosis iridis.

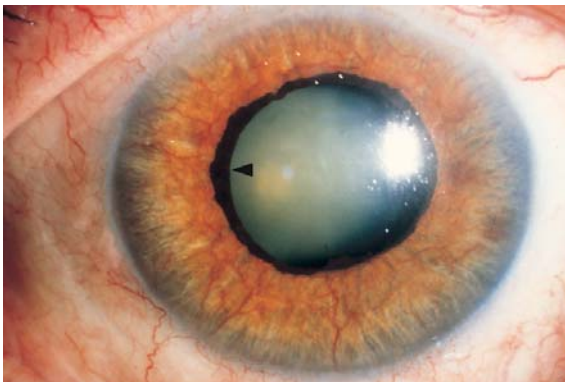


Fig. 8.12 Protrusion of the pigmented layer (arrow) indicates that the rubeosis iridis has been present for at least several weeks.



Treatment, prognosis, and prophylaxis: Rubeosis iridis is essentially tantamount to the *loss of an eye*. Usually it leads to *irreversible blindness*. Prompt laser treatment of retinal disorders is crucial to prevent rubeosis iridis. Secondary angle closure glaucoma is treated by transscleral freezing of the ciliary body (cyclocryotherapy) to reduce intraocular pressure. Where this fails or the eye shrinks (phthisis bulbi) and the patient experiences intense pain, enucleation of the eye is indicated.

! Prompt laser treatment is important in proliferative diabetic retinopathy to prevent rubeosis iridis.

8.7 Tumors

8.7.1 Malignant Tumors (Uveal Melanoma)

With an incidence of one per ten thousand, malignant uveal melanoma is the most common primary intraocular tumor. It usually occurs as a choroidal melanoma, and is almost always unilateral. *Tumors in the iris* are detected earlier than tumors located in the *ciliary body* and *choroid* (Fig. 8.13).

❖ **Iris melanomas:** These tumors are *often initially asymptomatic*. However, metastatic melanoma cells in the angle of the anterior chamber can lead to *secondary glaucoma*. Circumscribed iris melanomas are removed by *segmental iridectomy*.

Choroidal melanoma.

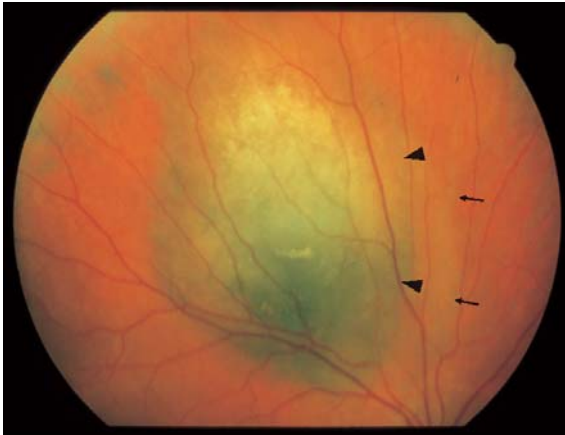

Fig. 8.13 A prominent yellowish-brown choroidal tumor (thick arrowheads) accompanied by serous retinal detachment (arrows).



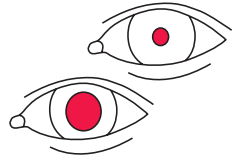
- ❖ **Ciliary body melanomas:** Symptoms include changes in accommodation and refraction resulting from displacement of the lens. Ciliary body melanomas are resected *en bloc*.
- ❖ **Choroidal melanomas:** These tumors become clinically symptomatic when involvement of the macula *reduces visual acuity* or the patient notices a shadow in his or her field of vision as a result of the tumor and the accompanying *retinal detachment*. The diagnosis is confirmed with the aid of transillumination, ultrasound, and fluorescein angiography. Choroidal tumors are treated with radioactive isotopes delivered by plaques of radioactive material (*brachytherapy*). *Enucleation* is indicated for tumors whose diameter exceeds 8 mm and whose prominence exceeds 5 mm.
- ❖ **Uveal metastases** most frequently develop from carcinomas of the breast or lung. They are usually flat with little pigmentation.

8.7.2 Benign Choroidal Tumors

Choroidal nevi occur in 11% of the population. They can lead to secondary neovascularization with retinal edema. In very rare cases where the macula is involved, choroidal nevi can lead to impaired vision. However, benign choroidal tumors are normally asymptomatic.

9 Pupil

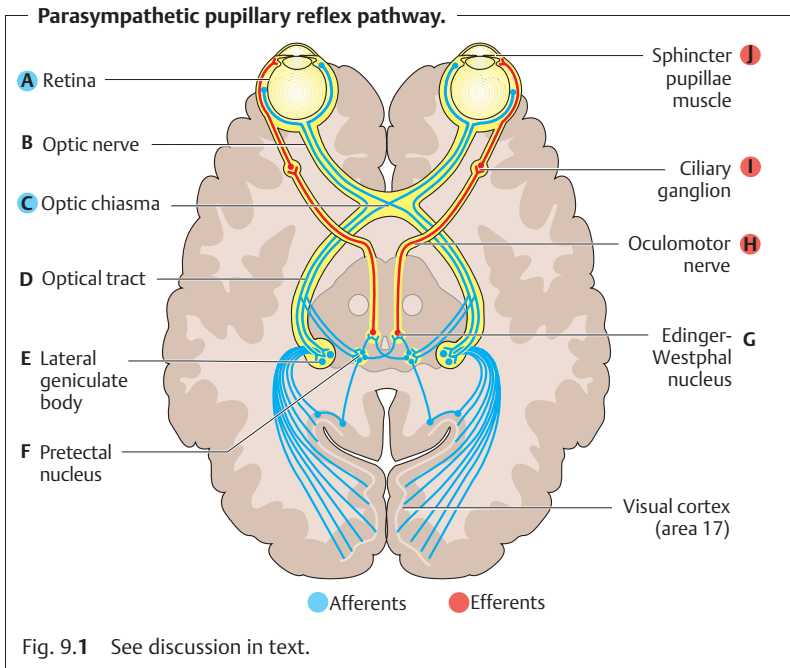
Oskar Gareis and Gerhard K. Lang



9.1 Basic Knowledge

Function: The pupil refers to the central opening in the iris. It acts as an aperture to improve the quality of the resulting image by controlling the amount of light that enters the eye.

Pupillary light reflex: This reflex arc consists of an afferent path that detects and transmits the light stimulus and an efferent path that supplies the muscles of the iris (Fig. 9.1).





Afferent path. This path begins at the light receptors of the retina (Fig. 9.1, A), continues along the optic nerve (B), the optic chiasma (C) where some of the fibers cross to the opposite side. The path continues along the optical tracts (D) until shortly before the lateral geniculate body (E). There the *afferent reflex path* separates from the visual pathway and continues to the pretectal nuclei (F) and from there to *both* Edinger-Westphal nuclei (G). Each of the two pretectal nuclei conduct impulses to *both* Edinger-Westphal nuclei. This bilateral connection has several consequences:

- ❖ Both pupils will normally be the same size (*isocoria*) even when one eye is blind. Deviations up to 1 mm are normal
- ❖ Both pupils will narrow even when only one eye is illuminated (*consensual light reflex*).

Efferent parasympathetic path. This path begins in the *Edinger-Westphal nucleus* (G). Its nerve fibers form the parasympathetic part of the oculomotor nerve (H) and travel to the ciliary ganglion (I) in the orbit. Postganglionic nerve fibers pass through the short ciliary nerves to the effector organ, the *sphincter pupillae muscle* (J).

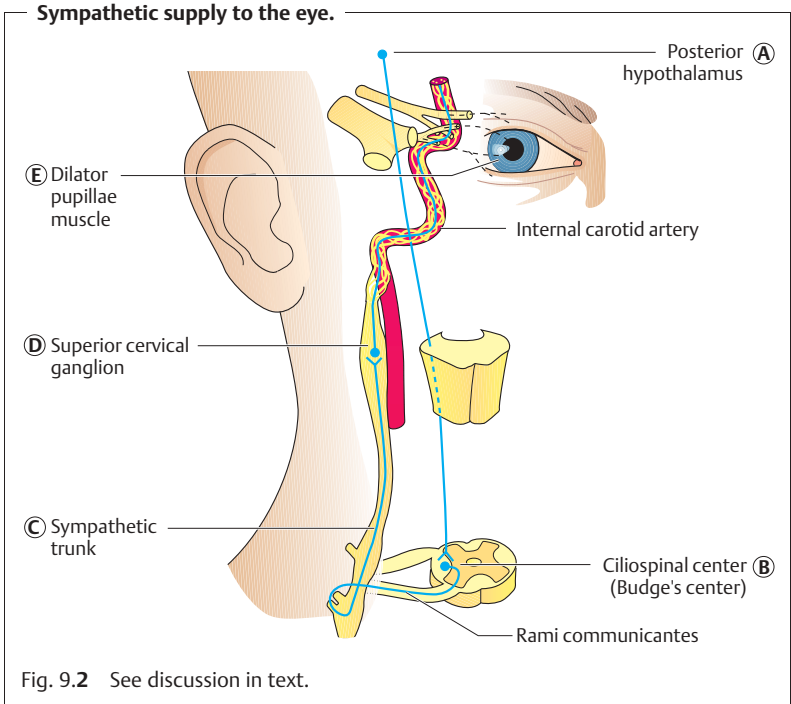
Perlia's nucleus and the Edinger-Westphal nuclei are also responsible for the **near reflex**, which consists of accommodation, convergence, and miosis.

Efferent sympathetic nerve supply to the pupil. Three neurons connected by synapses supply the pupil (Fig. 9.2):

- ❖ The *central first neuron* begins in the posterior hypothalamus (A), passes the brain stem and the medulla oblongata to the ciliospinal center (Budge's center; B) in the cervical spinal cord (C8–T2).
- ❖ The *preganglionic second neuron* extends from the ciliospinal center through the white rami communicantes and sympathetic trunk (C) to the superior cervical ganglion (D). It is vulnerable to certain lesions such as Pancoast tumors because it is immediately adjacent to the tip of the lung.
- ❖ The *postganglionic third neuron* extends from the superior cervical ganglion as a neural plexus along the internal carotid artery, ophthalmic artery, and long ciliary nerves to the effector organ, the *dilator pupillae muscle* (E).

Normal pupil size: Pupil size ranges from approximately 1 mm (**miosis**) to approximately 8 mm (**mydriasis**).

- ❖ Pupils tend to be wider in teenagers and in darkness. They are also wider with joy, fear, or surprise due to increased sympathetic tone, and when the person inhales deeply.
- ❖ Pupils tend to be narrower in the newborn due to parasympathetic tone, in the elderly due to decreased mesencephalic inhibition and sympathetic diencephalic activity, in light, during sleep, and when the person is fatigued (due to decreased sympathetic activity).



9.2 Examination Methods

Complete examination of the pupil includes testing direct and indirect light reflexes, the swinging flashlight test, testing the near reflex, and morphologic evaluation of the iris. A synopsis of all findings is required to determine whether a disorder is due to ocular or cerebral causes (see 9.4).

9.2.1 Testing the Light Reflex (Table 9.1)

Light reflex is tested in subdued daylight where the pupil is slightly dilated. The patient gazes into the distance to neutralize near-field miosis.

Direct light reflex: The examiner first covers both of the patient's eyes, then uncovers one eye. Normally the pupil will constrict after a latency period of about 0.2 seconds. The other eye is tested in the same manner.

Indirect or consensual light reflex: The examiner separates the patient's eyes by placing his or her hand on the bridge of the patient's nose. This pre-



Table 9.1 Characteristic pupil findings in unilateral lesions of the pupillary reflex pathway

Localization of the lesion (unilateral)	Direct light reflex	Indirect light reflex		Swinging flashlight test	Findings
		ipsilateral	contralateral		
Afferent pupillary pathway (optic nerve, retina)	Slight lesion	+	++	Slight constrictions, quicker dilation	Isocoria
	Severe lesion	-	++	Dilation	
Efferent pupillary pathway	Oculomotor lesion	-	-	No response	Anisocoria
	Ciliary ganglion lesion	+	++	Delayed constriction, delayed dilation	

Legend: - = response absent, + = weak response, ++ = strong response



vents incident light from *directly striking* the eye being examined, which would elicit a *direct light reflex*. The examiner then illuminates the other eye while observing the reaction of the covered, non-illuminated eye. *Normally both pupils will constrict*, even in the non-illuminated eye.

Swinging flashlight test: This test is used to diagnose a *discrete unilateral or unilaterally more pronounced sensory deficit* in the eye (optic nerve and/or retina). Often damage to the optic nerve or retina is only partial, such as in partial atrophy of the optic nerve, maculopathy, or peripheral retinal detachment. In these cases, the remaining healthy portions of the afferent pathway are sufficient to trigger constriction of the pupil during testing of the direct light reflex. This constriction will be less than in the healthy eye but may be difficult to diagnose from discrete pupillary reflex findings alone. Therefore, the *reflexive behavior of both eyes should be evaluated in a direct comparison* to detect differences in the rapidity of constriction and subsequent dilation. This is done by moving a light source alternately from one eye to the other in what is known as a swinging flashlight test.

Reproducible results can only be obtained if the examiner strictly adheres to this **test protocol**:

- ❖ The patient focuses on a remote object in a room with subdued light. This neutralizes convergence miosis, and the pupils are slightly dilated, making the pupillary reflex more easily discernible.
- ❖ The examiner alternately illuminates both eyes with a relatively bright light, taking care to maintain a *constant distance, duration of illumination, and light intensity* so that both eyes must adapt to the same conditions.
- ❖ The examiner evaluates the *initial constriction* upon illumination and the *subsequent dilation* of the pupil.

Where the pupil constricts more slowly and dilates more rapidly than in the fellow eye, one refers to a *relative afferent pupillary defect*. The defect is “relative” because the difference in pupillary reflex only occurs when there is a difference in the sensory defect to the left and right eyes.

9.2.2 Evaluating the Near Reflex

The **near reflex triad** consists of:

1. Convergence of the visual axes.
2. Accommodation.
3. Constriction of the pupils (miosis).

The near reflex is tested by having the patient focus on a distant object and then on an object in the near field. Usually this is the patient’s finger, which is brought to within 10 cm of the eyes. *The near reflex is intact* if both eyes continuously converge with accommodation and miosis appropriate for the patient’s age as the object is moved to within 10 cm of the eyes. The examiner



should take care to avoid illuminating the pupil, which will produce a light reflex with miosis.

9.3 Influence of Pharmacologic Agents on the Pupil (Table 9.2)

Table 9.2 Influence of pharmacologic agents on the pupil

Substance group and individual active ingredients	Mechanism and duration of action	Indication and special considerations
Miotics		
Parasympathomimetics		
❖ Direct parasympathomimetics	– Act on acetylcholine receptors of the sphincter pupillae muscle (miosis) and the ciliary muscle (increased accommodation)	Glaucoma therapy
– Acetylcholine	– Extremely short duration of action (several minutes)	Intraocular application only (cataract surgery); ineffective as eyedrops (rapid breakdown)
– Pilocarpine	– Effective for 5–7 hours	Standard medication in glaucoma therapy
– Aceclidine	– Effective for 5–7 hours – <i>Weaker</i> miotic effect than pilocarpine	Standard medication in glaucoma therapy
– Carbachol	– Effective for 7–9 hours – <i>Stronger</i> miotic effect than pilocarpine	Standard medication in glaucoma therapy
❖ Indirect parasympathomimetics	– Act by inhibiting acetylcholine	Glaucoma therapy Side effects: cataract, iris cysts, may increase risk of retinal detachment; therefore not the medication of first choice in glaucoma therapy
– Physostigmine	– Effective for 2–3 days	
– Prostigmin	– Effective for 1 day	



Table 9.2 (Continued)

Substance group and individual active ingredients	Mechanism and duration of action	Indication and special considerations
Mydriatics		
Parasympatholytics		
– Tropicamide	– Act by blocking acetylcholine receptors of the sphincter pupillae muscle (mydriasis) and the ciliary muscle (accommodation paralysis) – Effective for approximately 4–6 hours (shortest acting mydriatic)	Used for diagnostic purposes
– Cyclopentolate	– Effective for approximately 12–24 hours – More cycloplegic than mydriatic	Used diagnostically for objective measurement of refraction Used therapeutically to relax the ciliary body (in iritis)
– Homatropine	– Effective for approximately 1–2 days	Used therapeutically (in iritis)
– Scopolamine	– Effective for approximately 1 week	Used therapeutically for protracted mydriasis, for example following surgical repair of retinal detachment or in iridocyclitis
– Atropine	– Effective for less than one week (longest acting mydriatic)	For all therapy requiring protracted mydriasis, for example following surgical repair of retinal detachment and in iridocyclitis
Sympathomimetics		
❖ Direct sympathomimetics	– Act on the adrenaline receptors of the dilator pupillae muscle	Primarily for diagnostic purposes

Continued →



Table 9.2 (Continued)

Substance group and individual active ingredients	Mechanism and duration of action	Indication and special considerations
Sympathomimetics		
– Epinephrine	– Only slightly effective; rapidly broken down by amino oxidases	Used in the diagnosis of Horner's syndrome and in intraocular application for better mydriasis during surgery
– Phenylephrine	– Effective for approximately six hours (onset and duration of action identical to tropicamide; see parasympatholytics) – Advantage: does not cause accommodation paralysis	Used for diagnostic purposes due to its short duration of action
❖ Indirect sympathomimetics	– Inhibit reabsorption of norepinephrine	For diagnostic purposes
– Cocaine 4%	– Effective for approximately six hours	Today used as eyedrops only for diagnostic purposes and in Horner's syndrome
! ! Drug-induced mydriasis is contraindicated in patients with a shallow anterior chamber due to the risk of acute angle closure glaucoma.		

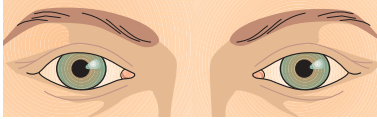
9.4 Pupillary Motor Dysfunction

Pupillary motor dysfunction must be distinguished from a number of differential diagnoses that include not only ocular disorders but neurologic and internal disorders. Diagnosis is difficult because *isocoria* or *anisocoria* are *unspecific clinical symptoms*. Therefore, functional tests are indicated to confirm the diagnosis. The following section uses diagrams of the initially presenting clinical symptoms to illustrate the various types of pupillary dysfunction. The text presents the differential diagnoses with the functional studies used to confirm the respective diagnosis.



Isocoria with constricted or dilated pupils is primarily of interest to the neurologist and less so the ophthalmologist. These disorders are therefore discussed at the end of the section.

9.4.1 Isocoria with Normal Pupil Size



Relative Afferent Pupillary Defect

Causes: Unilateral sensory disorder such as retinal detachment, neuritis of the optic nerve, atrophy of the optic nerve, or retinal vascular occlusion.

Diagnostic considerations:

- ❖ Direct light reflex is decreased or absent (relative afferent pupillary defect) in the affected eye.
- ❖ The consensual light reflex in the affected eye is weak or absent but normal in the unaffected eye.
- ❖ The swinging flashlight test reveals dilation in the affected eye when illuminated (*Marcus Gunn pupil*) or reduced constriction and earlier dilation in the presence of lesser lesions (afferent pupillary defect).
- ❖ Near reflex is normal.
- ❖ Unilaterally reduced visual acuity and/or field of vision.



Unilateral blindness (afferent defect) does not produce anisocoria.

Bilateral Afferent Pupillary Defect

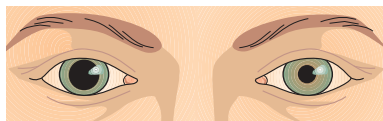
Causes: Bilateral sensory disorder such as maculopathy or atrophy of the optic nerve.

Diagnostic considerations:

- ❖ Delayed direct and consensual light reflexes.
- ❖ The swinging flashlight test produces identical results in both eyes (where disorder affects both sides equally).
- ❖ Near reflex is normal.
- ❖ Bilaterally reduced visual acuity and/or field of vision.



9.4.2 Anisocoria with Dilated Pupil in the Affected Eye



Complete Oculomotor Palsy

Causes:

- ❖ Processes in the base of the skull such as tumors, aneurysms, inflammation, or bleeding.

Diagnostic considerations:

- ❖ Direct and consensual light reflexes without constriction in the affected eye (fixed pupil).
- ❖ Near reflex miosis is absent.
- ❖ Impaired motility and double vision.



Sudden complete oculomotor palsy (loss of motor and parasympathetic function) is a sign of a potentially life-threatening disorder. In unconscious patients, unilateral mydriasis is often the only clinical sign of this.

Tonic Pupil

Causes: Postganglionic damage to the parasympathetic pathway, presumably in the ciliary ganglion, that frequently occurs with diabetes mellitus, alcoholism, viral infection, and trauma.

Diagnostic considerations:

- ❖ Direct and consensual light reflexes show absent or delayed reaction, possibly with worm-like segmental muscular contractions.
- ❖ Dilation is also significantly delayed.
- ❖ Near reflex is slow but clearly present; accommodation with delayed relaxation is present.
- ❖ Motility is unimpaired.
- ❖ Pharmacologic testing with 0.1% pilocarpine.
 - Significant miosis in the affected eye (denervation hypersensitivity).
 - No change in the pupil of the unaffected eye (too weak).
- ❖ Adie's tonic pupil syndrome: The tonic pupil is accompanied by absence of the Achilles and patellar tendon reflexes.



Tonic pupil is a relatively frequent and completely harmless cause of unilateral mydriasis.



Iris Defects

Causes:

- ❖ Trauma (aniridia or sphincter tears).
- ❖ Secondary to acute angle closure glaucoma.
- ❖ Synechiae (post-iritis or postoperative).

Diagnostic considerations: Patient history and slit-lamp examination.

Following Eyedrop Application (Unilateral Administration of a Mydriatic)

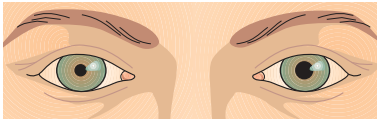Simple anisocoria

Causes: Presumably due to asymmetrical supranuclear inhibition of the Edinger-Westphal nucleus.

Diagnostic considerations:

- ❖ Direct and consensual light reflexes and swinging flashlight test show constant difference in pupil size.
- ❖ Near reflex is normal.
- ❖ Pharmacologic testing: Cocaine test (4% cocaine eyedrops are applied to both eyes and pupil size is measured after one hour): bilateral pupil dilation indicates an intact neuron chain.

9.4.3 Anisocoria with a Constricted Pupil in the Affected Eye



Horner's Syndrome

Causes: Damage to the sympathetic pathway.

- ❖ Central (first neuron):
 - Tumors.
 - Encephalitis.
 - Diffuse encephalitis.
- ❖ Peripheral (second neuron):
 - Syringomyelia.
 - Diffuse encephalitis.
 - Trauma.
 - Rhinopharyngeal tumors.
 - Goiter.



- Aneurysm.
- Processes in the tip of the lung.
- ❖ Peripheral in the strict sense (third neuron):
 - Vascular processes.
 - Internal carotid aneurysm.

Clinical Picture:

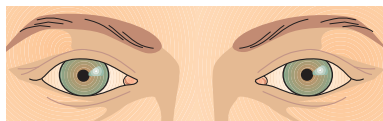- ❖ Miosis (approximately 1–2 mm difference) due to failure of the dilator pupillae muscle.
- ❖ Ptosis (approximately 1–2 mm difference) due to failure of the muscle of Müller.
- ❖ Enophthalmos due to failure of the rudimentary lower eyelid retractors. This makes the lower eyelid project so that the eye appears smaller. This condition only represents a type of pseudoenophthalmos.
- ❖ Decreased sweat gland secretion (only present in preganglionic disorders as the sweat glands receive their neural supply via the external carotid).

Diagnostic considerations:

- ❖ Direct and consensual light reflexes are intact, which distinguishes this disorder from a parasympathetic lesion); the pupil dilates more slowly (dilation deficit).
- ❖ Near reflex is intact.
- ❖ Pharmacologic testing with cocaine eyedrops:
 - **Peripheral Horner's syndrome:** *On the affected side, there is slight mydriasis (decrease in norepinephrine due to nerve lesion). On the unaffected side, there is significant mydriasis.*
 - **Central Horner's syndrome:** *On the affected side, the pupil is dilated. On the unaffected side, the pupil is also dilated (the norepinephrine in the synapses is not inhibited).*

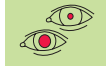Following Eyedrop Application (Unilateral Administration of a Miotic as in Glaucoma Therapy)

9.4.4 Isocoria with Constricted Pupils



Argyll-Robertson Pupil

Causes: The precise location of the lesion is not known; presumably the disorder is due to a lesion in the pretectal region and the Edinger-Westphal nucleus such as tabes dorsalis (Argyll-Robertson phenomenon), encephalitis,



diffuse encephalitis, syringomyelia, trauma, bleeding, tumors, and alcoholism.

Diagnostic considerations:

- ❖ Direct and consensual light reflexes are absent.
- ❖ Near reflex is intact or there is overcompensation (the Edinger-Westphal nucleus is being controlled via the convergence center).
- ❖ The pupil is not round, and constriction is not always symmetrical.
- ❖ There is no reaction to darkness or pharmacologic stimuli.

Bilateral Pupillary Constriction due to Pharmacologic Agents

Causes:

- ❖ Morphine.
- ❖ Deep general anesthesia.
- ❖ Pilocarpine eyedrops.

Toxic Bilateral Pupillary Constriction

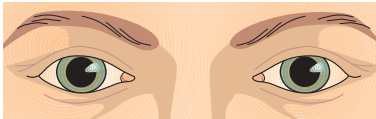Causes: Mushroom poisoning.

Inflammatory Bilateral Pupillary Constriction

Causes:

- ❖ Encephalitis.
- ❖ Meningitis.

9.3.5 Isocoria with Dilated Pupils



Parinaud's Oculoglandular Syndrome

Causes: Tumors such as pineal gland tumors that selectively damage fibers between the pretectal nuclei and the Edinger-Westphal nucleus.

Diagnostic considerations:

- ❖ Fixed dilated pupils that do not respond to light.
- ❖ Normal near reflex.
- ❖ Limited upward gaze (due to damage to the vertical gaze center) and retraction nystagmus.



Intoxication

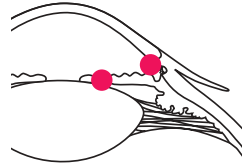
Causes: Atropine, spasmolytic agents, anti-parkinson agents, antidepressants, botulism (very rare but important), carbon monoxide, cocaine.

Disorders

- ❖ Migraine.
- ❖ Schizophrenia.
- ❖ Hyperthyreosis.
- ❖ Hysteria.
- ❖ Epileptic seizure.
- ❖ Increased sympathetic tone (Bumke's anxiety pupils).
- ❖ Coma.
- ❖ Agony.

10 Glaucoma

Gerhard K. Lang



10.1 Basic Knowledge

Definition

Glaucoma is a disorder in which increased intraocular pressure damages the optic nerve. This eventually leads to blindness in the affected eye.

- ❖ **Primary** glaucoma refers to glaucoma that is not caused by other ocular disorders.
- ❖ **Secondary** glaucoma may occur as the result of another ocular disorder or an undesired side effect of medication or other therapy.

Epidemiology: Glaucoma is the *second most frequent cause of blindness* in developing countries after diabetes mellitus. Fifteen to twenty per cent of all blind persons lost their eyesight as a result of glaucoma. In Germany, approximately 10% of the population over 40 has increased intraocular pressure. Approximately 10% of patients seen by ophthalmologists suffer from glaucoma. Of the German population, 8 million persons are at risk of developing glaucoma, 800 000 have already developed the disease (i.e., they have glaucoma that has been diagnosed by an ophthalmologist), and 80 000 face the risk of going blind if the glaucoma is not diagnosed and treated in time.



Early detection of glaucoma is one of the highest priorities for the public health system.

Physiology and pathophysiology of aqueous humor circulation (Fig. 10.1):

The average *normal intraocular pressure of 15 mm Hg* in adults is significantly higher than the average tissue pressure in almost every other organ in the body. Such a high pressure is important for the optical imaging and helps to ensure several things:

- ❖ Uniformly smooth curvature of the surface of the cornea.
- ❖ Constant distance between the cornea, lens, and retina.
- ❖ Uniform alignment of the photoreceptors of the retina and the pigmented epithelium on Bruch's membrane, which is normally taut and smooth.

The aqueous humor is formed by the ciliary processes and secreted into the posterior chamber of the eye (Fig. 10.1 [A]). At a rate of about 2–6 μl per

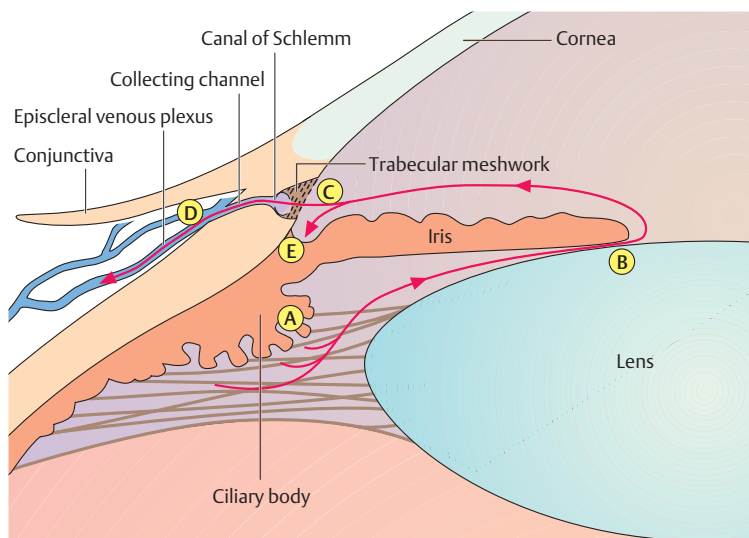
**Physiology of aqueous humor circulation.**

Fig. 10.1 As it flows from the nonpigmented cells of the ciliary epithelia (A) to beneath the conjunctiva (D), the aqueous humor overcomes physiologic resistance from two sources: the resistance of the pupil (B) and the resistance of the trabecular meshwork (C).

minute and a total anterior and posterior chamber volume of about 0.2–0.4 ml, about 1–2% of the aqueous humor is replaced each minute.

The aqueous humor passes through the pupil into the anterior chamber. As the iris lies flat along the anterior surface of the lens, the aqueous humor cannot overcome this pupillary resistance (**first physiologic resistance**; Fig. 10.1 [B]) until sufficient pressure has built up to lift the iris off the surface of the lens. Therefore, the flow of the aqueous humor from the posterior chamber into the anterior chamber is not continuous but pulsatile.

Any increase in the resistance to pupillary outflow (*pupillary block*) leads to an increase in the pressure in the posterior chamber; the iris inflates anteriorly on its root like a sail and presses against the trabecular meshwork (Table 10.2). This is the *pathogenesis of angle closure glaucoma*.

Various factors can increase the resistance to pupillary outflow (Table 10.1). The aqueous humor flows out of the angle of the anterior chamber through two channels:

- ❖ The trabecular meshwork (Fig. 10.1 [C]) receives about 85% of the outflow, which then drains into the canal of Schlemm. From here it is con-

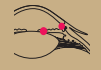

Table 10.1 Factors that increase resistance to pupillary outflow and predispose to angle closure glaucoma

<p>Increased contact between the margin of the pupil and lens with:</p>	<ul style="list-style-type: none"> ❖ Small eyes ❖ Large lens (increased lens volume) due to: <ul style="list-style-type: none"> – Age (lens volume increases with age by a factor of six) – Diabetes mellitus (osmotic swelling of the lens) ❖ Miosis <ul style="list-style-type: none"> – Age (atrophy of the sphincter and dilator muscles) – Medications (miotic agents in glaucoma therapy) – Iritis (reactive miosis) – Diabetic iridopathy (thickening of the iris) ❖ Posterior synechiae (adhesions between lens and iris)
<p>Increased viscosity of the aqueous humor with:</p>	<ul style="list-style-type: none"> ❖ Inflammation (protein, cells, or fibrin in the aqueous humor) ❖ Bleeding (erythrocytes in the aqueous humor)

ducted by 20–30 radial collecting channels into the episcleral venous plexus (D).

- ❖ A uveoscleral vascular system receives about 15% of the outflow, which joins the venous blood (E).

The trabecular meshwork (C) is the **second source of physiologic resistance**. The trabecular meshwork is a body of loose sponge-like avascular tissue between the scleral spur and Schwalbe's line. Increased resistance is present in *open angle glaucoma*.

Classification: Glaucoma can be classified according to the specific pathophysiology (Table 10.2).

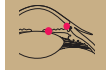

The many various types of glaucoma are nearly all attributable to increased resistance to outflow and not to heightened secretion of aqueous humor.



Table 10.2 Classification of glaucoma

Form of glaucoma		Incidence
Open angle glaucoma	Primary	Over 90% of all glaucomas
	Secondary	2–4% of all glaucomas
Angle closure glaucoma	Primary (pupillary block glaucoma)	About 5% of all glaucomas
	Secondary	2–4% of all glaucomas
Juvenile glaucoma		1% of all glaucomas
Absolute glaucoma	This is not a separate form of glaucoma, rather it describes an often painful eye blinded by glaucoma	



Angle (anatomic)	Angle (gonioscopy)	Outflow impediment
Open	Completely open. Structures appear normal.	In the trabecular meshwork
Open	Completely open. Trabecular meshworks and secondary occluding cells visible.	Erythrocytes, pigment, and inflammatory cells occlude the trabecular meshwork.
Blocked	Occluded. No angle structures visible	Iris tissue occludes the trabecular meshwork.
Blocked	Occluded. No angle structures visible. Occluding structures visible.	Displacement of the trabecular meshwork produces anterior synechiae, scarring, and neovascularization (rubeosis iridis)
Undifferentiated	Open. Occluding embryonic tissue and lack of differentiation visible.	In the trabecular meshwork (which is not fully differentiated and/or is occluded by embryonic tissue)



10.2 Examination Methods

10.2.1 Oblique Illumination of the Anterior Chamber

The anterior chamber is illuminated by a beam of light tangential to the plane of the iris. In eyes with an anterior chamber of *normal depth*, the iris is uniformly illuminated. This is a sign of a deep anterior chamber with an open angle (see Fig. 1.12).

In eyes with a *shallow anterior chamber* and an angle that is partially or completely closed, the iris protrudes anteriorly and is not uniformly illuminated (see Fig. 1.12).

10.2.2 Slit-Lamp Examination

The *central and peripheral depth of the anterior chamber* should be evaluated on the basis of the thickness of the cornea. An anterior chamber that is less than three times as deep as the thickness of the cornea in the center with a peripheral depth less than the thickness of the cornea suggests a narrow angle (Fig. 10.2). Gonioscopy is essential for further evaluation.



To evaluate the depth of the anterior chamber with a slit-lamp biomicroscope, select a narrow setting for the light beam. The beam should strike the eye at a slight angle to the examiner's line of sight.

10.2.3 Gonioscopy

The angle of the anterior chamber is evaluated with a gonioscope placed directly on the cornea (Fig. 10.3a and b).

Slit-lamp examination to evaluate the depth of the anterior chamber.

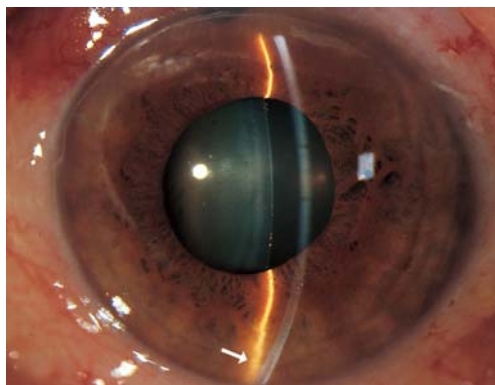
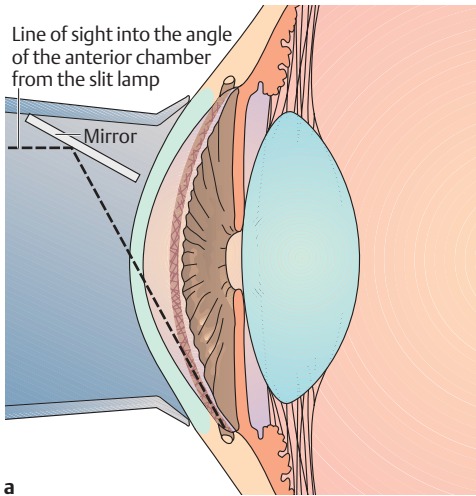


Fig. 10.2 The depth of the anterior chamber is less than the thickness of the cornea on its periphery. The corneal reflex and iris reflection touch each other (arrow), indicating a shallow anterior chamber. Gonioscopy is indicated.

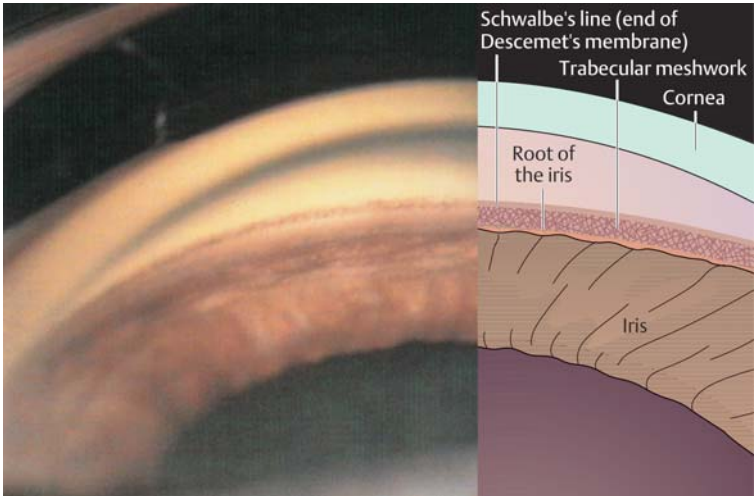


Gonioscopy and morphology of the angle structures.



a

Fig. 10.3
a Schematic diagram of gonioscopy. The angle of the anterior chamber can be visualized with a gonioscope placed on the cornea.
b Gonioscopic image of the angle.



b



Gonioscopy can differentiate the following conditions:

- ❖ Open angle: open angle glaucoma.
- ❖ Occluded angle: angle closure glaucoma.
- ❖ Angle access is narrowed: configuration with imminent risk angle of an acute closure glaucoma.
- ❖ Angle is occluded: secondary angle closure glaucoma, for example due to neovascularization in rubeosis iridis.
- ❖ Angle open but with inflammatory cellular deposits, erythrocytes, or pigment in the trabecular meshwork: secondary open angle glaucoma.



Gonioscopy is the examination of choice for identifying the respective presenting form of glaucoma.

10.2.4 Measuring Intraocular Pressure

Palpation (Fig. 1.15, p. 15): Comparative palpation of both eyeballs is a preliminary examination that can detect increased intraocular pressure.

- ❖ If the examiner can indent the eyeball, which fluctuates under palpation, pressure is less than 20 mm Hg.
- ❖ An eyeball that is not resilient but rock hard is a sign of about 60–70 mm Hg of pressure (acute angle closure glaucoma).

Schiotz indentation tonometry (Figs. 10.4a and b): This examination *measures the degree to which the cornea can be indented* in the supine patient. The lower the intraocular pressure, the deeper the tonometer pin sinks and the greater distance the needle moves.

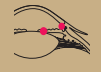Indentation tonometry often provides inexact results. For example the rigidity of the sclera is reduced in myopic eyes, which will cause the tonometer pin to sink more deeply for that reason alone. Because of this, indentation tonometry has been largely supplanted by applanation tonometry.

Applanation tonometry: This method is the *most common method of measuring intraocular pressure*. It permits the examiner to obtain a measurement on a sitting patient within a few seconds (Goldmann's method, see Fig. 10.5 a–c) or on a supine patient (Draeger's method). A flat tonometer tip has a diameter of 3.06 mm for applanation of the cornea over a corresponding area (7.35 mm²). This method eliminates the rigidity of the sclera as a source of error (see also tonometric self-examination).



Intraocular pressure of 22 mm Hg is regarded as suspicious. Caution: Infection is possible in the presence of conjunctivitis.

Pneumatic non-contact tonometry: The electronic tonometer directs a 3 ms blast of air against the cornea. The tonometer records the deflection of the cornea and calculates the intraocular pressure on the basis of this deformation.



Schiötz indentation tonometry.

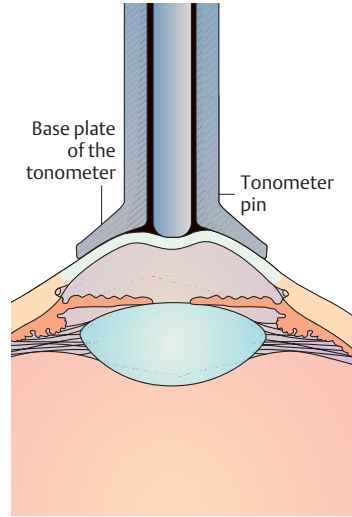
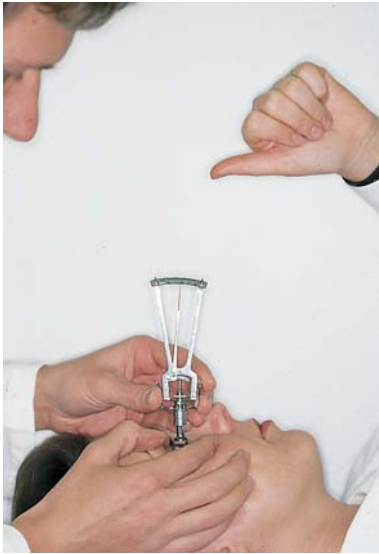

Fig. 10.4 **a** The tonometer is placed on the anesthetized cornea. The examiner retracts both eyelids and the patient focuses on his or her thumb with the other eye.

b Detail view of the tonometer pin indenting the cornea. The harder the eyeball, the shallower the indentation and the smaller the movement of the indicator needle.

Advantages:

- ❖ Does not require the use of a topical anesthetic.
- ❖ Non-contact measurement eliminates risk of infection (may be used to measure intraocular pressure in the presence of conjunctivitis).

Disadvantages:

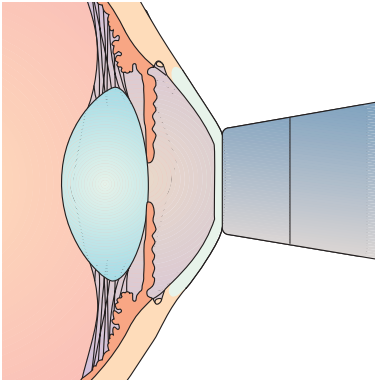
- ❖ Calibration is difficult.
- ❖ Precise measurements are possible only within low to middle range pressures.
- ❖ Cannot be used in the presence of corneal scarring.
- ❖ Examination is unpleasant for the patient.
- ❖ Air flow is loud.
- ❖ The instrument is more expensive to purchase than an applanation tonometer.



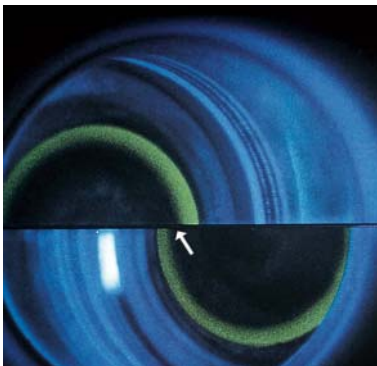
Goldmann applanation tonometry.

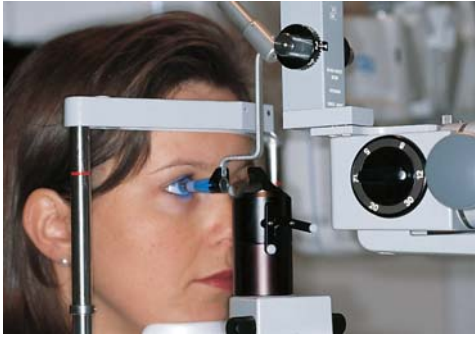

Fig. 10.5
a Slit-lamp measurement of intraocular pressure: After application of anesthetizing eyedrops containing fluorescein, the tonometer tip is placed on the cornea.



b The cornea is applanated (flattened) over an area measuring precisely 7.35 mm^2 . The external pressure required is directly proportional to intraocular pressure.



c View through a slit lamp: The pressure reading is taken when the two inner menisci of the fluorescein arcs touch (arrow).



Measuring the twenty-four-hour pressure curve (Fig. 10.6): This examination is performed to analyze *fluctuations of the pressure level over a 24-hour period* in patients with suspected glaucoma.



A single measurement may not be representative. Only a 24-hour curve provides reliable information about the pressure level.

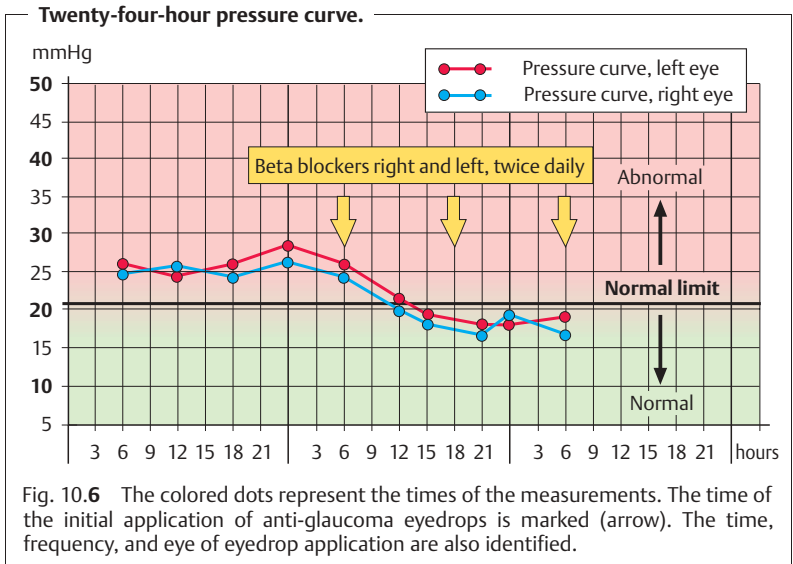
Intraocular pressure fluctuates in a rhythmic pattern. The highest values frequently occur at night or in the early morning hours. In normal patients, these fluctuations in intraocular pressure rarely exceed 4–6 mm Hg.

Pressure is measured on the ward at 6:00 a.m., noon, 6:00 p.m., 9:00 p.m., and midnight. Outpatient 24-hour pressure curves without nighttime and early morning measurements are less reliable.



In glaucoma patients maintained on eyedrops, special attention should be given to the time of application. Pressure is measured immediately prior to applying the eyedrops. In this manner, measurements are obtained when the effect of the eyedrops is weakest.

Tonometric self-examination: Recent developments have made it possible for patients to measure intraocular pressure themselves at home in a manner similar to self-monitoring of blood pressure and blood glucose (Fig. 10.7). The patient tonometer makes it possible to obtain a 24-hour pressure curve from



**Tonometric self-examination.**

Fig. 10.7 The patient places the tonometer on his or her forehead and uses the fixation light to align it in the proper position. The head of the tonometer then automatically presses against the cornea, measures intraocular pressure, and retracts. Pressure is indicated in a digital display.

any number of measurements obtained under normal everyday conditions. A patient tonometer may be prescribed in applicable cases (such as increased risk of acute glaucoma). However, using the device requires a certain degree of skill on the part of the patient. Patients who have problems applying eye-drops are best advised not to attempt to use a patient tonometer. Younger and well motivated patients are the best candidates for tonometric self-examination.

10.2.5 Optic Disk Ophthalmoscopy

The optic disk has a physiologic indentation known as the optic cup. In the presence of persistently elevated intraocular pressure, the optic cup becomes enlarged and can be evaluated by ophthalmoscopy.

Stereoscopic examination of the optic disk through a slit-lamp biomicroscope fitted with a contact lens provides a three-dimensional image. The optic cup may be examined stereoscopically with the pupil dilated.



The optic nerve is the eye's "glaucoma memory." Evaluating this structure will tell the examiner whether damage from glaucoma is present and how far advanced it is.



Normal optic cup (Fig. 10.8): The normal anatomy can vary widely. Large normal optic cups are nearly always *round* and differ from the *vertical* elongation of the optic cup seen in eyes with glaucoma.

Documenting the optic disk: Recording findings in sketches is suitable for routine documentation and follow-up examination of the optic disk. **Photographing the optic disk with a fundus camera** permits longer-term follow-up. *Stereoscopic photography* also provides a *three-dimensional image*. Optic disk measurement and tomography can provide *precise measurements of the optic nerve*.

Optic disk measurement. The area of the optic disk, optic cup, and neuroretinal rim (vital optic disk tissue) can be measured by planimetry on *two-dimensional photographs* of the optic nerve.

Normal optic disk.

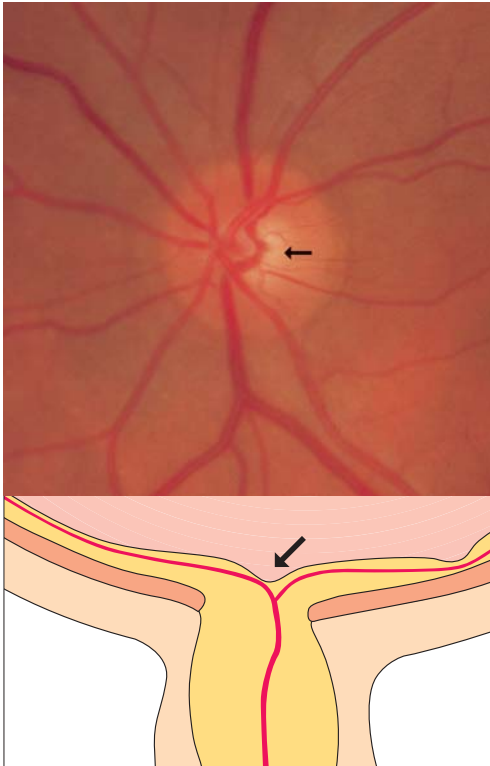


Fig. 10.8 The optic disk is sharply demarcated. It is level with the retina, and its color indicates vital tissue. The small central optic cup (arrow) is discernible as brighter area.



Optic disk tomography. Modern laser scanning ophthalmoscopes permit *three-dimensional documentation* of the optic nerve (Fig. 10.9).

Glaucomatous changes in the optic nerve: Glaucoma produces typical *changes in the shape of the optic cup*. Progressive destruction of nerve fibers, fibrous and vascular tissue, and glial tissue will be observable. This tissue atrophy leads to an *increase in the size of the optic cup* and to *pale discoloration of the optic disk* (Fig. 10.10).



Progressive glaucomatous changes in the optic disk are closely associated with increasing visual field defects (Figs. 10.11 a – d).

10.2.6 Visual Field Testing

Detecting glaucoma as early as possible requires documenting glaucomatous visual field defects at the earliest possible stage. We know that glaucomatous visual field defects initially manifest themselves in the superior paracentral nasal visual field or, less frequently, in the inferior field, as relative scotomas that later progress to absolute scotomas (Fig. 10.11 a – d).

Optic disk tomography.

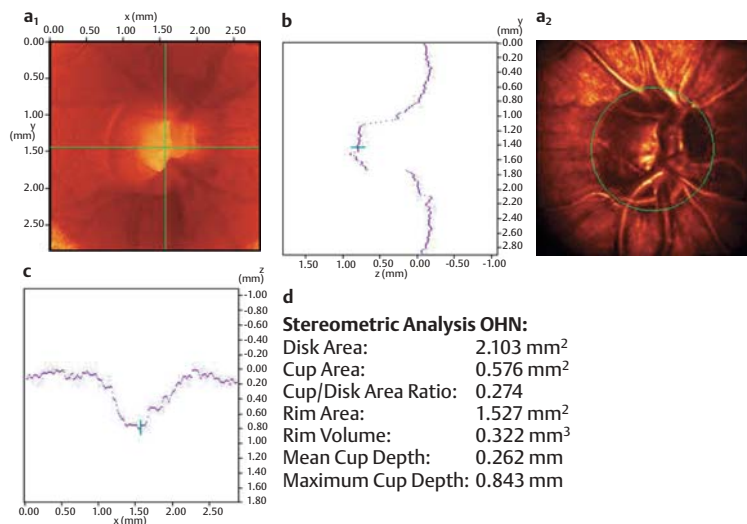


Fig. 10.9 A laser beam scans the optic disk (**a₁** and **a₂**) to produce a vertical map (**b**) and horizontal map (**c**) of the height and depth of the optic disk. The computer then calculates crucial data for the optic disk and presents a stereometric analysis (**d**).



Glaucomatous lesions in the optic nerve.

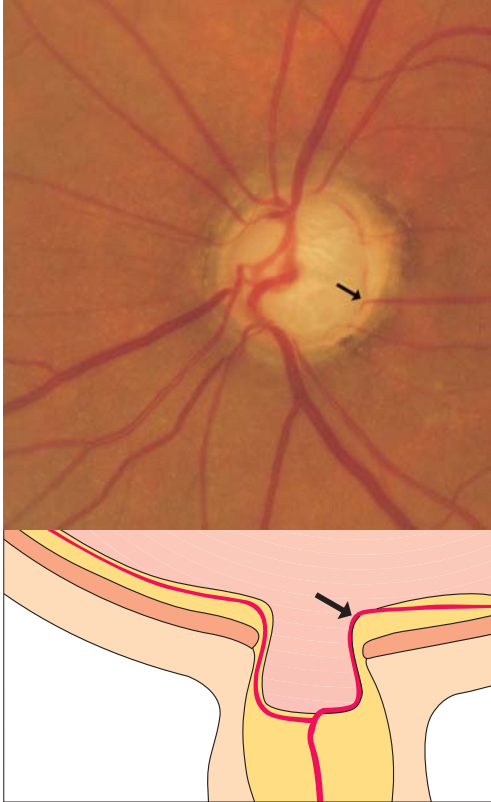


Fig. 10.10 The optic disk is sharply demarcated and pale (a sign of tissue atrophy). The optic cup is enlarged and almost completely covers the disk. The blood vessels abruptly plunge into the deep cup, indicated by their typical bayonet-shaped kinks in the image (arrow).

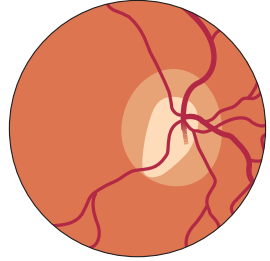
Computerized static perimetry (measurement of the sensitivity to differences in light) is superior to any kinetic method in detecting these early glaucomatous visual field defects. Computer-controlled semiautomatic grid perimetry devices such as the Octopus or Humphrey field analyzer are used to examine the central 30 degree field of vision (modern campimetry; Fig. 10.12).

Reproducible visual field findings are important in follow-up to exclude any enlargement of the defects.

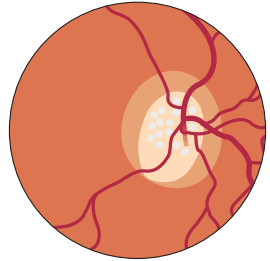


Overview of glaucomatous visual field defects.

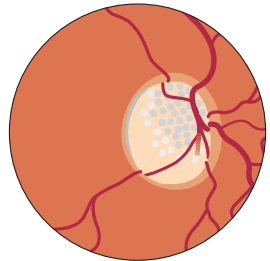
Peripheral optic cup in a temporal and inferior location (with damage to the optic nerve fibers in this area).



Increase in the size of the optic cup with thinning of the vital rim. The lamina cribrosa is visible.



Advanced generalized thinning of the neuroretinal rim with an increasingly visible lamina cribrosa and nasal displacement of the blood vessels.



Total glaucomatous atrophy of the optic nerve: Complete atrophy of the neuroretinal rim, kettle-shaped optic cup, bayonet kinks in the blood vessels on the margin of the optic disk, some of which disappear. The lamina cribrosa is diffusely visible. Only remnants of the atrophic tissue of the optic disk remain. The optic disk is surrounded by a ring of chorioretinal atrophy (glaucomatous halo) due to pressure atrophy of the choroid and lysis of the retinal pigmented epithelium.

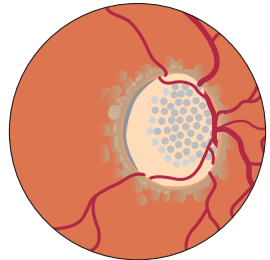
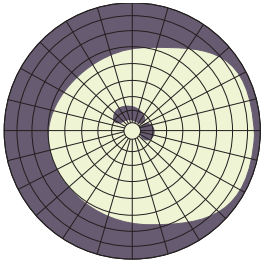
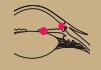
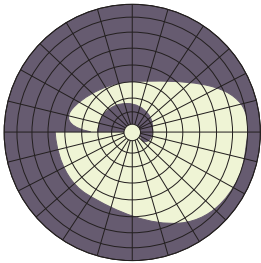


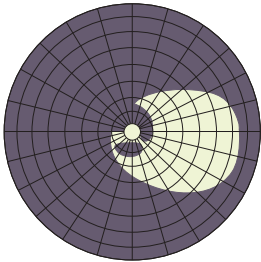
Fig. 10.11



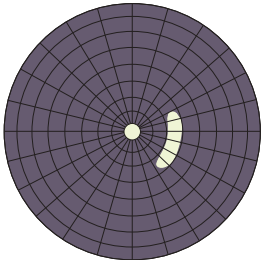
An enlarged blind spot and a superior paracentral nasal scotoma. The paracentral scotomas precede the enlargement of the blind spot.



Narrowing of the peripheral superior paracentral visual field. The insular paracentral scotomas converge and extend to the blind spot.



Further loss of superior nasal visual field. Circumscribed horizontal penetration of the Bjerrum's scotoma into the nasal half of the field of vision. A new inferior nasal scotoma is a sign of a superior temporal nerve fiber lesion.



A small central and peripheral residual field of vision remains. The arc-shaped scotoma has expanded into a ring-shaped scotoma surrounding the focal point. As the focal point degenerates, the center of vision disappears and only a peripheral residual field of vision remains.

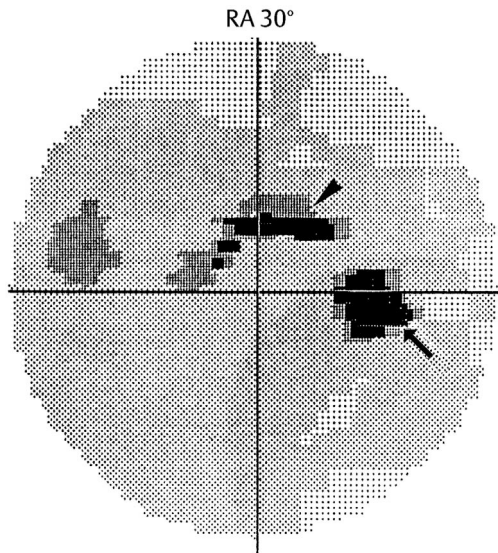
**Thirty degree visual field test for glaucoma screening.**

Fig. 10.12 The central field of vision is examined for scotomas with an automatic perimeter as studies of early glaucoma have shown that the initial defects occur in this area (see Fig. 10.11 a – d). The figure shows the visual field defect in the early stages of glaucoma. The blind spot is slightly enlarged (arrow), and an arc-shaped paracentral Bjerrum's scotoma is present (arrowhead). The standardized examination conditions in automatic perimetry not only permit early detection of glaucoma; the reproducible results also aid in the prompt diagnosis of worsening findings.

10.2.7 Examination of the Retinal Nerve Fiber Layer

The retinal nerve fibers have a characteristic arrangement, which explains the typical visual field defects that occur in primary open angle glaucoma. In addition to the early progressive optic nerve and visual field defects, *arc-shaped defects* also occur in the nerve fiber layer. These defects may be observed in light with red components (Fig. 10.13).



Examination of the retinal nerve fiber layer.

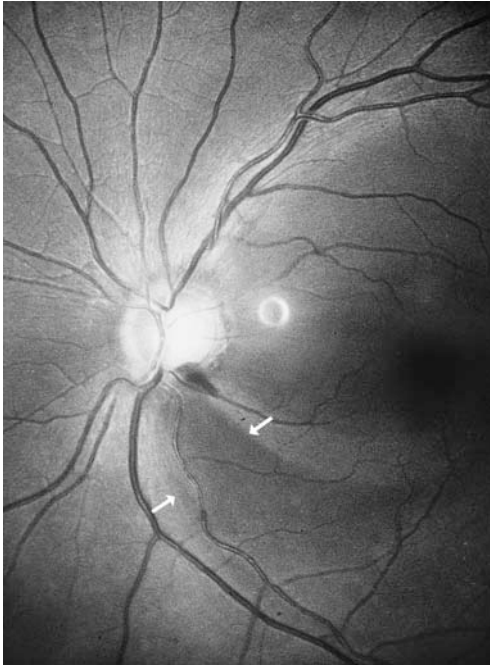


Fig. 10.13 The arc-shaped nerve fiber defect (between the arrows) is a sign of an early glaucomatous optic nerve lesion.

10.3 Primary Glaucoma

10.3.1 Primary Open Angle Glaucoma

Definition

Primary open angle glaucoma begins in middle-aged and elderly patients with minimal symptoms that progressively worsen. The angle of the anterior chamber characteristically remains open throughout the clinical course of the disorder.

Epidemiology: Primary open angle glaucoma is *by far the most common form of glaucoma* and accounts for over 90% of adult glaucomas. The incidence of the disorder significantly increases beyond the age of 40, reaching a peak between the ages of 60 and 70. Its prevalence among 40-year-olds is 0.9% as compared to 4.7% among patients over the age of 50.



There appears to be a *genetic predisposition* for primary open angle glaucoma. Over one- third of glaucoma patients have relatives with the same disorder.



Patients with a positive family history are at greater risk of developing the disorder.

Etiology (See also physiology and pathophysiology of aqueous humor circulation): The cause of primary open angle glaucoma is not known, although it is known that **drainage of the aqueous humor is impeded**. The primary lesion occurs in the neuroretinal tissue of the optic nerve as compression neuropathy of the optic nerve.

Symptoms: The majority of patients with primary open angle glaucoma do not experience any subjective symptoms for years. However, a small number of patients experience occasional **unspecific symptoms** such as headache, a burning sensation in the eyes, or blurred or decreased vision that the patient may attribute to lack of eyeglasses or insufficient correction. The patient may also perceive rings of color around light sources at night, which has traditionally been regarded as a symptom of angle closure glaucoma.



Primary open angle glaucoma often does not exhibit typical symptoms for years. Regular examination by an ophthalmologist is crucial for early diagnosis.

Primary open angle glaucoma can be far advanced before the patient notices an extensive visual field defect in one or both eyes.

It is crucial to diagnose the disorder as early as possible because the prognosis for glaucoma detected in its early stages is far better than for advanced glaucoma. Where increased intraocular pressure remains undiagnosed or untreated for years, glaucomatous optic nerve damage and the associated visual field defect will increase to the point of blindness.

Diagnostic considerations: Measurement of intraocular pressure. Elevated intraocular pressure in a routine ophthalmic examination is an alarming sign.

Twenty-four-hour pressure curve. Fluctuations in intraocular pressure of over 5–6 mm Hg may occur over a 24-hour period.

Gonioscopy. The angle of the anterior chamber is open and appears as normal as the angle in patients without glaucoma.

Ophthalmoscopy. Examination of the optic nerve reveals whether glaucomatous cupping has already occurred and how far advanced the glaucoma is. Where the optic disk and visual field are normal, ophthalmoscopic examination of the posterior pole under green light may reveal fascicular nerve fiber defects as early abnormal findings.



Perimetry. Noise field perimetry is suitable as a *screening test* as it makes the patient aware of scotomas and makes it possible to detect and describe them. The patient is shown a flickering monitor displaying what resembles image noise on a television set. The patient will not see the flickering points in the region of the scotoma. After this test, the defect should be quantified by more specific methods. Automatic grid perimetry is suitable for the *early stages* of glaucoma. Special programs (such as the G1 program on the Octopus perimeter and the 30–2 program on the Humphrey perimeter devices) reveal the earliest glaucomatous changes. In *advanced glaucoma*, kinetic hand perimetry with the Goldmann perimeter device is a useful preliminary examination to evaluate the remaining field of vision.

Differential diagnosis: Two disorders are important in this context:

Ocular hypertension. Patients with ocular hypertension have significantly increased intraocular pressure over a period of years without signs of glaucomatous optic nerve damage or visual field defects. Some patients in this group will continue to have elevated intraocular pressure but will not develop glaucomatous lesions; the others will develop primary open angle glaucoma. The probability that a patient will develop definitive glaucoma increases the higher the intraocular pressure, the younger the patient, and the more compelling the evidence of a history of glaucoma in the family.

Low-tension glaucoma. Patients with low-tension glaucoma exhibit typical progressive glaucomatous changes in the optic disk and visual field without elevated intraocular pressure. These patients are very difficult to treat because management cannot focus on the control of intraocular pressure. Often these patients will have a history of hemodynamic crises such as gastrointestinal or uterine bleeding with significant loss of blood, low blood pressure, and peripheral vascular spasms (cold hands and feet). Patients with glaucoma may also experience further worsening of the visual field due to a drop in blood pressure.



Caution should be exercised when using cardiovascular and anti-hypertension medications in patients with glaucoma.

Treatment: Indications for initiating treatment.

- ❖ *Glaucomatous changes in the optic cup:* Medical treatment should be initiated where there are signs of glaucomatous changes in the optic cup or where there is a difference of more than 20% between the optic cups of the two eyes.
- ❖ *Any intraocular pressure exceeding 30 mm Hg* should be treated.
- ❖ *Increasing glaucomatous changes in the optic cup or increasing visual field defects:* Regardless of the pressure measured, these changes show that the current pressure level is too high for the optic nerve and that additional medical therapy is indicated. This also applies to patients with advanced



glaucomatous damage and threshold pressure levels (around 22 mm Hg). The strongest possible medications are indicated in these cases to lower pressure as much as possible (10–12 mm Hg).

- ❖ **Early stages:** It is often difficult to determine whether therapy is indicated in the early stages, especially where intraocular pressure is elevated slightly above threshold values. Patients with low-tension glaucoma exhibit increasing cupping of the optical disk even at normal pressures (less than 22 mm Hg), whereas patients with elevated intraocular pressure (25–33 mm Hg) may exhibit an unchanged optic nerve for years.

Patients with suspected glaucoma and risk factors such as a family history of the disorder, middle myopia, glaucoma in the other eye, or differences between the optic cup in the two eyes should be monitored closely. Follow-up examinations should be performed three to four times a year, especially for patients not undergoing treatment.

Medical therapy. Available options in medical treatment of glaucoma (see also Fig. 10.1):

- ❖ Inhibit aqueous humor production.
- ❖ Increase trabecular outflow.
- ❖ Increase uveoscleral outflow.

Fig. 10.14 and Table 10.3 list the various active ingredients and substance groups available for medical treatment of glaucoma. For the sake of completeness, Fig. 10.14 also lists traditional substances that are no longer used today; these include substances that have too many side effects or have been replaced by more efficient medications. Table 10.3 lists only those medications that are actually used today.

Principles of medical treatment of primary open angle glaucoma:

- ❗ Medical therapy is the treatment of choice for primary open angle glaucoma. Surgery is indicated only where medical therapy fails.

There is no one generally applicable therapy plan. However, several *principles* may be formulated:

- ❖ Where miosis is undesirable, therapy should begin with beta blockers (Table 10.3).
- ❖ Where miosis is not a problem (as is the case with aphakia), therapy begins with miotic agents.
- ❖ Miotic agents may be supplemented with beta blockers, epinephrine derivatives, guanethidine, dorzolamide and/or latanoprost maximum topical therapy).
- ❖ Osmotic agents or carbonic anhydrase inhibitors (administered orally or intravenously) inhibit the production of aqueous humor. They can be administered temporarily in addition to topical medications. Their side effects usually make them unsuitable for prolonged treatment. The general rule is to try to use the weakest possible medications required to



Options in medical treatment of glaucoma.

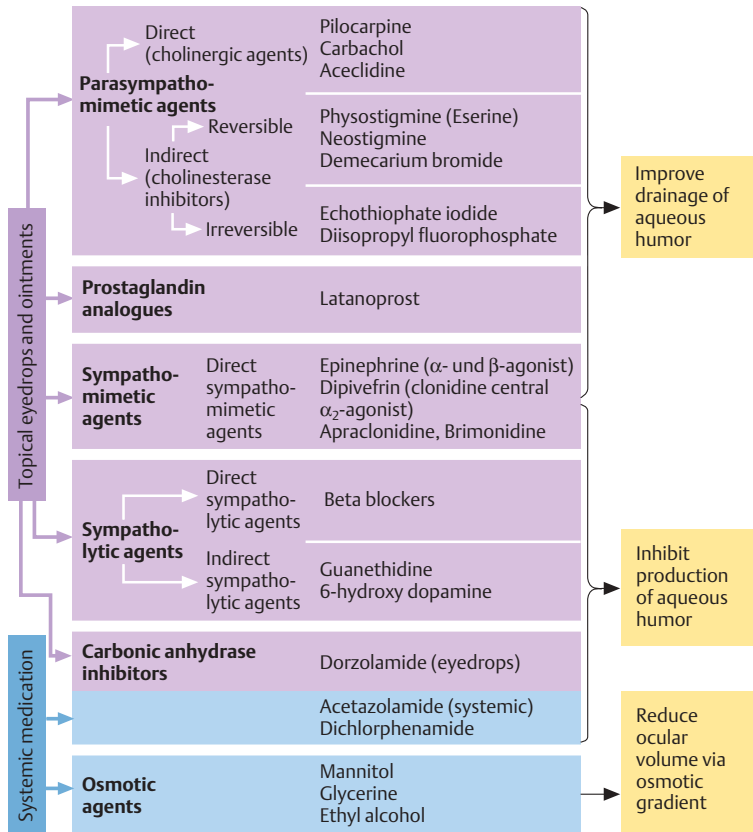


Fig. 10.14

achieve normal pressure over a 24-hour period: as much as necessary, and as little as possible.

- ❖ The effectiveness of any pressure-reducing therapy should be verified by pressure analysis on the ward or on an outpatient basis.
- ❖ The effect of the eyedrops should not interfere with the patient's ability to work. Tolerance, effects, and side effects of the eyedrops should be repeatedly verified on an individual basis during the course of treatment.

**Surgical treatment of primary open angle glaucoma. Indications:**

- ❖ Medical therapy is insufficient.
- ❖ The patient does not tolerate medical therapy. Reactions include allergy, reduced vision due to narrowing of the pupil, pain, and ciliary spasms, and ptosis.
- ❖ The patient is not a suitable candidate for medical therapy due to lack of compliance or dexterity in applying eyedrops.

Table 10.3 Medical treatment of glaucoma

Active ingredients and preparations (examples)	Mode of action	Indications	Side effects
Parasympathomimetic agents <ul style="list-style-type: none">❖ Direct parasympathomimetic agents:<ul style="list-style-type: none">– Pilocarpine– Carbachol– Aceclidine	<ul style="list-style-type: none">❖ Improve drainage of aqueous humor in primary open angle glaucoma. The effect is probably purely mechanical via contraction of the ciliary muscle and tension on the trabecular meshwork and scleral spur.❖ In acute angle closure glaucoma, the forced narrowing of the pupil and the extraction of the iris from the angle of the anterior chamber are most important.	<ul style="list-style-type: none">❖ Primary open angle glaucoma❖ Acute angle closure glaucoma	<ul style="list-style-type: none">❖ Younger patients frequently do not tolerate the temporary myopia due to contraction of the ciliary muscle.❖ Miosis with worsening of the night vision and narrowing of the peripheral field of vision.

Continued →



Table 10.3 (Continued)

Active ingredients and preparations (examples)	Mode of action	Indications	Side effects
<ul style="list-style-type: none"> ❖ Indirect parasympathomimetic agents: cholinesterase inhibitors – Neostigmine 	<ul style="list-style-type: none"> ❖ Improve drainage. Contraction of the ciliary muscle and sphincter pupillae muscle is more pronounced than with other miotic agents. 	<ul style="list-style-type: none"> ❖ Primary open angle glaucoma if other miotic agents are no longer effective. 	<ul style="list-style-type: none"> ❖ Cholinesterase inhibitors are no longer routinely used today because of their significant ocular and systemic side effects. They are only used in isolated cases such as when other medications fail to control intraocular pressure.
<ul style="list-style-type: none"> Direct sympathomimetic agents – Dipivefrin (epinephrine derivative) 	<ul style="list-style-type: none"> ❖ Improve drainage of aqueous humor and reduce production of aqueous humor. ❖ Used in combination with pilocarpine and carbonic anhydrase inhibitors, these agents also reduce intraocular pressure. 	<ul style="list-style-type: none"> ❖ Primary open angle glaucoma 	<ul style="list-style-type: none"> ❖ 10–15% of patients develop an allergy. ❖ Paradoxical increase in intraocular pressure occasionally occurs. ❖ Epinephrine derivatives have been shown to cause cystoid maculopathy in patients with aphakia. ❖ Oxidation products of epinephrine derivatives form deposits in the conjunctiva (adrenochrome deposits) and can lead to obstruction of the canaliculus (see Fig. 4.24 h).

Continued →



Table 10.3 (Continued)

Active ingredients and preparations (examples)	Mode of action	Indications	Side effects
Clonidine:	❖ Reduces intraocular pressure by about 20%, primarily by vasoconstriction without influencing the size of the pupil and accommodation.	❖ Particularly suitable for young patients with primary open angle glaucoma.	❖ Lowers blood pressure. Should be used only in low concentrations (1/16% and 1/8%) because the effect on intraocular pressure is the same as with higher concentrations but the side effects are significantly less.
Apraclonidine:	❖ Also reduces aqueous humor production. In contrast to clonidine, this agent does not reduce systemic blood pressure.	❖ Very good reduction of intraocular pressure in decompensated glaucoma.	❖ Beware of cardiovascular disease.
Brimonidine:	❖ Improves drainage of aqueous humor by reducing episcleral venous pressure and reducing aqueous humor production by decreasing ciliary body perfusion.	As with apraclonidine.	As with apraclonidine.

Continued →



Table 10.3 (Continued)

Active ingredients and preparations (examples)	Mode of action	Indications	Side effects
<p>Sympatholytic agents</p> <p>❖ Direct sympatholytic agents: beta blockers</p> <ul style="list-style-type: none"> – Timolol: – Betaxolol: – Carteolol: – Levobunolol: – Metipranolol: <p>❖ Indirect sympatholytic agents:</p> <ul style="list-style-type: none"> – Guanethidine: 	<p>❖ Reduce pressure by decreasing production of aqueous humor <i>without</i> influencing pupil size and accommodation.</p> <p>❖ Decrease aqueous humor production.</p>	<p>❖ Primary open angle glaucoma</p> <p>❖ Secondary open angle glaucoma</p> <p>❖ Secondary angle closure glaucoma</p> <p>❖ Reduce pressure only slightly.</p>	<p>❖ Reduce heart rate and increase bronchospasms in asthma patients.</p> <p>Contraindications: Beta blockers should be used with caution in patients with obstructive lung disease, cardiac insufficiency, or cardiac arrhythmia and only after consulting an internist. Absorption from topical application can produce systemic side effects.</p> <p>❖ Red eyes.</p>

Continued →



Table 10.3 (Continued)

Active ingredients and preparations (examples)	Mode of action	Indications	Side effects
Prostaglandin analogues: – Latanoprost:	<ul style="list-style-type: none">❖ Increase uveoscleral aqueous humor drainage.	<ul style="list-style-type: none">❖ Suitable for all patients with primary open angle glaucoma.❖ Adjunctive therapy with beta blockers, epinephrine derivatives, pilocarpine, and carbonic anhydrase inhibitors.	<ul style="list-style-type: none">❖ No known systemic side effects.❖ Local changes in the color of the iris in 16% of all patients.
Carbonic anhydrase inhibitors: – Dorzolamide: – Acetazolamide: – Dichlorphenamide:	<ul style="list-style-type: none">❖ Reduces aqueous humor production. The enzyme carbonic anhydrase contributes to the production of aqueous humor via active secretion of bicarbonate.	<ul style="list-style-type: none">❖ Acute glaucoma.❖ Surgical procedures that can increase intraocular pressure.	<ul style="list-style-type: none">❖ Prolonged therapy causes malaise, nausea, depression, anorexia, weight loss, and decreased libido in 40–50% of glaucoma patients.

Continued →



Table 10.3 (Continued)

Active ingredients and preparations (examples)	Mode of action	Indications	Side effects
Osmotic agents: – Mannitol: – Glycerine:	❖ Decrease intraocular pressure presumably by producing an osmotic pressure gradient by means of the hyperosmotic substances released into the bloodstream. This draws water from the fluid-filled spaces, especially from the vitreous body and aqueous humor.	❖ Exclusively indicated in acute increases of intraocular pressure such as angle closure glaucoma due to its short duration of action (only a few hours).	

Argon laser trabeculoplasty:

- ❖ Principle: Laser burns in the trabecular meshwork cause tissue contraction that widens the intervening spaces and improves outflow through the trabecular meshwork.
- ❖ Technique: Fifty to 100 focal laser burns are placed in the anterior trabecular meshwork (Fig. 10.15).
- ❖ Comment: Laser surgery in the angle of anterior chamber is possible only if the angle is open. The surgery itself is largely painless, may be performed as an outpatient procedure, and involves few possible complications. These may include bleeding from vascular structures near the angle and synechiae between the iris and individual laser burns. Argon laser trabeculoplasty can bring improvement with intraocular pressures up to 30 mm Hg. It decreases intraocular pressure by about 6–8 mm Hg for about two years. Argon laser trabeculoplasty is only effective in about every second patient. The full effect occurs about four to six weeks postoperatively.

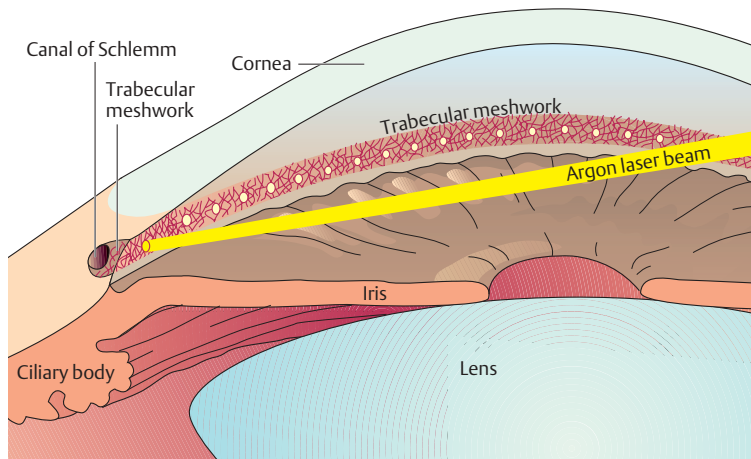
**Argon laser trabeculoplasty.**

Fig. 10.15 An argon laser beam is focused on the trabecular meshwork through a gonioscope and slit lamp. Approximately 100 laser burns are placed in a circle in the trabecular meshwork to improve aqueous humor drainage.

Filtration surgery:

- ❖ Principle: The aqueous humor is drained through the anterior chamber through a subconjunctival scleral opening, circumventing the trabecular meshwork. Formation of a thin-walled filtration bleb is a sign of sufficient drainage of aqueous humor.
- ❖ Technique (Fig. 10.16a – c): First a conjunctival flap is raised, which may be either fornix-based or limbal-based. Then a partial-thickness scleral flap is raised. Access to the anterior chamber is gained via a *goniotomy* performed with a 1.5 mm trephine at the sclerocorneal junction or via a rectangular *trabeculectomy* performed with a scalpel and dissecting scissors. A peripheral iridectomy is then performed through this opening. The scleral flap is then loosely closed and covered with conjunctiva.
- ❖ Comment: A permanent reduction in intraocular pressure is achieved in 80–85% of these operations.

Cyclodialysis:

- ❖ Principle: The aqueous humor is drained through an opening into the suprachoroidal space.
- ❖ Technique: A full-thickness scleral incision is made down to the ciliary body 4 mm posterior to the limbus. The sclera is then separated from the

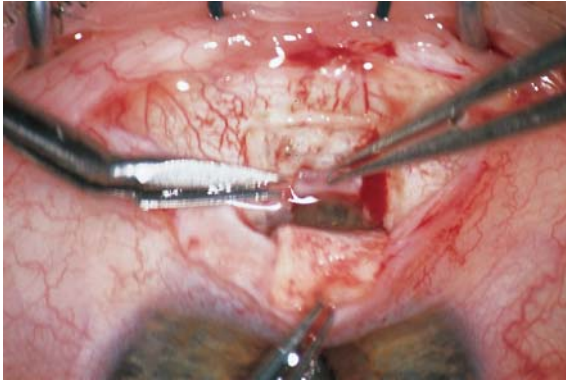
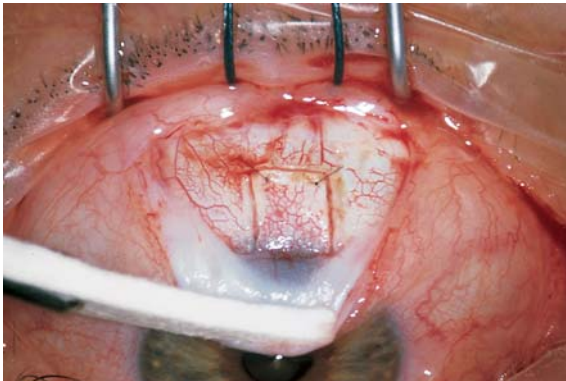
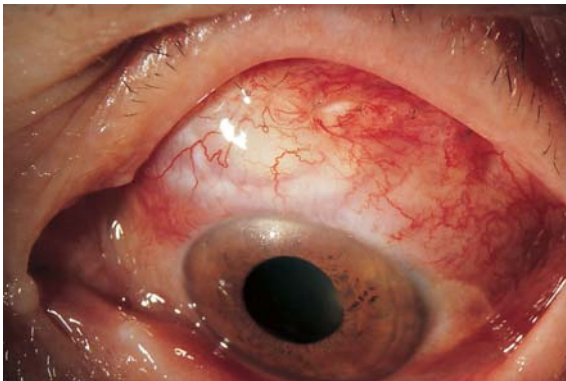
**Filtration surgery.**

Fig. 10.16
a The trabecular meshwork is excised with dissecting scissors.



b The partial-thickness scleral flap is closed with two sutures.



c The postoperative photograph shows a prominent bleb beneath the conjunctiva.



ciliary body with a retractor and retracted anteriorly into the anterior chamber. The ciliary body atrophies in the area of the incision, which also helps to decrease the production of aqueous humor.

- ❖ **Comment:** This procedure is less common today than it was in the 1980 s. One reason for this is that it is difficult to gauge accurately the atrophy to the ciliary body. Occasionally severe hypotonia of the globe will result, which then requires surgical intervention to close the dialysis opening.

Cycloablation:

- ❖ **Principle:** Atrophy is induced in portions of the ciliary body through the intact sclera to reduce intraocular pressure by decreasing the amount of tissue producing aqueous humor.
- ❖ **Technique:**
 - *Cyclocryotherapy:* A cryoprobe is used to freeze the ciliary body at several points through the sclera. This procedure can be repeated if necessary; the interventions have a cumulative effect.
 - *Cyclodiathermy:* This method is similar to cyclocryotherapy except that a diathermy needle is advanced through the sclera into the ciliary body to cauterize it with heat. The procedure may be performed with or without prior dissection of a partial-thickness scleral flap.
 - *Laser cycloablation* induces atrophy in the ciliary body using YAG laser or high-energy diode laser pulses.
 - *Ultrasound disruption* induces atrophy in the ciliary body with high-frequency ultrasound waves. These last two forms of therapy have been developed to induce atrophy more effectively, more accurately, and in more controlled doses, which is less traumatic for the eye.
- ❖ **Comment:** All these forms of cycloablation are irreversible and cause permanent hypotonia. Therefore, they represent the last line of treatment options.

Prophylaxis: No prophylactic action can be taken to prevent primary open angle glaucoma.



Early diagnosis is crucial and can only be made by an ophthalmologist. By the age of 40 at the latest, patients should have their intraocular pressure measured regularly. The ophthalmologist performs regular glaucoma screening examinations of intraocular pressure and pupil. Therefore, the first pair of reading eyeglasses should always be prescribed by an ophthalmologist.

Prognosis: The prognosis depends greatly on the stage at which primary open angle glaucoma is diagnosed. As a general rule, therapy is more effective the earlier it can be initiated.



10.3.2 Primary Angle Closure Glaucoma

Definition

Acute episodic increase in intraocular pressure to several times the normal value (10–20 mm Hg) due to sudden blockage of drainage. Production of aqueous humor and trabecular resistance are normal.

Epidemiology: The incidence among persons over the age of 60 is one per thousand. Women are three times as likely to be affected as men. Inuit are more frequently affected than other ethnic groups, whereas the disorder is rare in blacks.

Etiology: (See also physiology and pathophysiology of aqueous humor circulation): Anatomically predisposed eyes with **shallow anterior chambers** (see Fig. 10.1) pose a relative impediment to the flow of aqueous humor through the pupil. This **pupillary block** increases the pressure in the posterior chamber (Fig. 10.18a). The pressure displaces the iris anteriorly toward the trabecular meshwork, suddenly blocking the outflow of aqueous humor (**angle closure**). A typical glaucoma attack occurs unilaterally due to widening of the pupil either in dark surroundings and/or under emotional stress (dismay or fear). A typical situation is the evening mystery movie on television. Iatrogenic pharmacologic mydriasis and systemic psychotropic drugs can also trigger a glaucoma attack.



Bear in mind that mydriatic agents entail a risk of triggering a glaucoma attack by widening the pupil. Therefore, it is important to evaluate the depth of the anterior chamber in every patient even prior to a routine fundus examination.

Symptoms: Acute onset of intense pain. The elevated intraocular pressure acts on the corneal nerves (the ophthalmic nerve or first branch of the trigeminal nerve) to cause dull pain. This pain may be referred to the temples, back of the head, and jaws via the three branches of the trigeminal nerve, which can mask its ocular origin.

Nausea and vomiting occur due to irritation of the vagus nerve and can simulate abdominal disorders. The generalized symptoms such as headache, vomiting, and nausea may dominate to the extent that the patient fails to notice local symptoms.

Diminished visual acuity. Patients notice obscured vision and colored halos around lights in the affected eye. These symptoms are caused by the corneal epithelial edema precipitated by the enormous increase in pressure.

Prodromal symptoms. Patients report transitory episodes of blurred vision or the appearance of colored halos around lights prior to the attack. These



prodromal symptoms may go unnoticed or may be dismissed as unimportant by the patient in mild episodes where the eye returns to normal. Early identification of those risk patients with shallow anterior chambers and gonioscopic findings is important as damage to the structures of the angle may be well advanced before clinical symptoms appear.

! The full clinical syndrome of acute glaucoma will not always be present. The diminished visual acuity may go unnoticed if the other eye has normal vision. Patients' subjective perception of pain intensity can vary greatly.

Diagnostic considerations (Fig. 10.17):

! The diagnosis is made on the basis of a triad of symptoms:

- ❖ Unilateral red eye with conjunctival or ciliary injection.
- ❖ Fixed and dilated pupil.
- ❖ Hard eyeball on palpation.

Acute glaucoma attack: pupillary block.

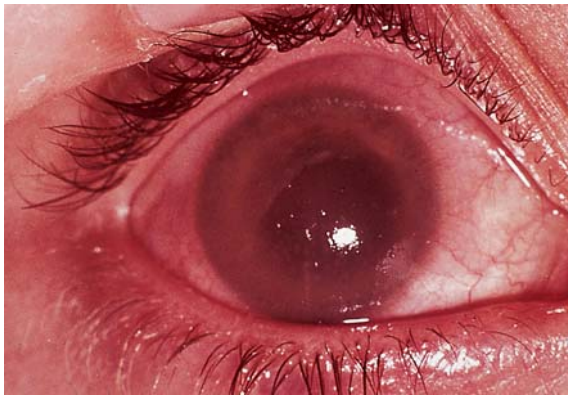


Fig. 10.17 Typical symptoms include:

- ❖ Conjunctival and ciliary injection (red eye).
- ❖ Corneal edema.
- ❖ Dull, non-reflecting surface with dull corneal reflex.
- ❖ Opacification of the corneal stroma that obscures the view of the fundus. The iris appears faded, and the anterior chamber is shallow.
- ❖ The pupil is oval instead of round, and is fixed and moderately dilated.
- ❖ Intraocular pressure is elevated; the eye is rock hard to palpation.
- ❖ Severe headache and gastrointestinal symptoms are present.



Other findings.

- ❖ The cornea is dull and steamy with epithelial edema.
- ❖ The anterior chamber is shallow or completely collapsed. This will be apparent when the eye is illuminated by a focused lateral light source (Fig. 1.12, p. 12) and upon slit-lamp examination. Inspection of the shallow anterior chamber will be difficult. Details of the surface of the iris will be visible, and the iris will appear faded.
- ❖ The fundus is generally obscured due to opacification of the corneal epithelium. When the fundus can be visualized as symptoms subside and the cornea clears, the spectrum of changes to the optic disk will range from a normal vital optic disk to an ill-defined hyperemic optic nerve. In the latter case, venous congestion will be present. The central artery of the retina will be seen to pulse on the optic disk as blood can only enter the eye during the systolic phase due to the high intraocular pressure.
- ❖ Visual acuity is reduced to perception of hand motions.

Differential diagnosis: Misdiagnosis is possible as the wide variety of symptoms can simulate other disorders.

- ❖ **General symptoms** such as headache, vomiting, and nausea often predominate and can easily be mistaken for *appendicitis* or a *brain tumor*.
- ❖ **In iritis and iridocyclitis**, the eye is also red and the iris appears faded. However, intraocular pressure tends to be decreased rather than elevated.

Treatment:




An acute glaucoma attack is an emergency, and the patient requires immediate treatment by an ophthalmologist. The underlying causes of the disorder require surgical treatment, although initial therapy is conservative.

Medical therapy. Goals of conservative therapy:

- ❖ Decrease intraocular pressure.
- ❖ Allow the cornea to clear (important for subsequent surgery).
- ❖ Relieve pain.

Time factor in reducing intraocular pressure:



Principles of medical therapy in primary angle closure glaucoma (see Fig. 10.3):

- ❖ Osmotic reduction in the volume of the vitreous body is achieved via systemic *hyperosmotic solutions* (oral glycerin, 1.0–1.5 g/kg of body weight, or intravenous mannitol, 1.0–2.0 g/kg of body weight).



- ❖ Production of aqueous humor is decreased by *inhibiting carbonic anhydrase* (intravenous acetazolamide, 250–500 mg). Both steps are taken initially to reduce intraocular pressure to below 50–60 mm Hg.
- ❖ The iris is withdrawn from the angle of the anterior chamber by administering *topical miotic agents*. Pilocarpine 1% eyedrops should be applied every 15 minutes. If this is not effective, pilocarpine can be applied more often, every five minutes, and in concentrations up to 4%. Miotic agents are not the medications of first choice because the sphincter pupillae muscle is ischemic at pressures exceeding 40–50 mm Hg and will not respond to miotic agents. Miotic agents also relax the zonule fibers, which causes anterior displacement of the lens that further compresses the anterior chamber. This makes it important to first initiate therapy with hyperosmotic agents to reduce the volume of the vitreous body.
- ❖ Symptomatic therapy with *analgesic agents, antiemetic agents, and sedatives* may be initiated where necessary.

Mechanical indentation of the cornea: Simple repetitive indentation of the central cornea with a muscle hook or glass rod for approximately 15–30 seconds presses the aqueous humor into the periphery of the angle of the anterior chamber, which opens the angle. If this manipulation succeeds in keeping the trabecular meshwork open for a few minutes, it will permit aqueous humor to drain and reduce intraocular pressure. This improves the response to pilocarpine and helps clear up the cornea.

Surgical management (shunt between the posterior and anterior chambers). Once the cornea is clear, the *underlying causes of the disorder are treated surgically* by creating a shunt between the posterior and anterior chambers.

Neodymium:yttrium-aluminum-garnet laser iridotomy (nonincisional procedure): The Nd:YAG laser can be used to create an opening in the peripheral iris (iridotomy) by tissue lysis without having to open the globe (Figs. 10.18 a–c). The operation can be performed under topical anesthesia (Fig. 10.19).

Peripheral iridectomy (incisional procedure): Where the cornea is still swollen with edema or the iris is very thick, an open procedure may be required to create a shunt. A limbal incision is made at 12 o'clock under topical anesthesia or general anesthesia, through which a basal iridectomy is performed. Today peripheral iridectomy is rarely performed, in only in 1–2% of all cases.

Prophylaxis: When the patient reports clear prodromal symptoms and the angle of the anterior chamber appears constricted, the safest prophylaxis is to perform a *Nd:YAG laser iridotomy* or *peripheral iridectomy*. If one eye has already suffered an acute attack, the fellow eye should be treated initially every 4–6 hours with pilocarpine 1% to minimize the risk of a glaucoma attack. The second eye should then be treated with a Nd:YAG laser to prevent glaucoma once surgical stabilization of the first eye has been achieved.



Acute angle closure glaucoma: etiology and treatment.

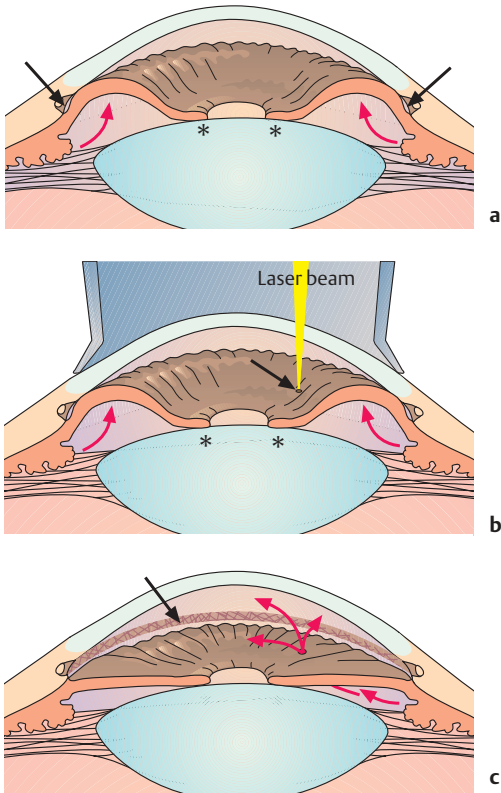


Fig. 10.18 a The pupillary block (asterisk) prevents the outflow of aqueous humor into the anterior chamber. The pressure in the posterior chamber increases (red arrows), and the peripheral iris is pressed against the trabecular meshwork. This blocks drainage of the aqueous humor and creates an acute angle closure (arrow).

b A Nd:YAG laser beam focused through a contact lens burns a circumscribed hole in the tissue of the iris to create a shunt between the posterior and anterior chambers (arrow). This permits the aqueous humor to flow into the anterior chamber despite the persisting pupillary block (asterisk).

c The aqueous humor trapped in the posterior chamber now flows through this newly created opening in the iris, equalizing the pressure in the two chambers and circumventing the pupillary block. The iris recedes into its normal position, the trabecular meshwork (arrow) is opened again, the aqueous humor can drain normally, and normal intraocular pressure is restored. No future pupillary block can form following Nd:YAG laser iridotomy.



Nd:YAG laser iridotomy.

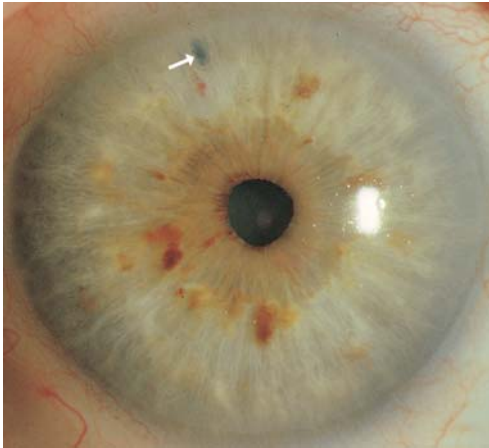


Fig. 10.19 The Nd:YAG laser opening in the iris (arrow) creates a shunt between the posterior and anterior chambers.

Prognosis: One can usually readily release a pupillary block and lower intraocular pressure in an initial attack with medication and permanently prevent further attacks with surgery. However, recurrent acute angle closure glaucoma or angle closure persisting longer than 48 hours can produce peripheral synechia between the root of the iris and the trabecular meshwork opposite it. These persisting cases of angle closure glaucoma cannot be cured by Nd:YAG laser iridotomy or iridectomy, and the angle closure will persist despite surgery. Filtration surgery is indicated in these cases.



Where intraocular pressure is controlled and the cornea is clear, gonioscopy is indicated to demonstrate that the angle is open again and to exclude persistent angle closure.

10.4 Secondary Glaucomas

Definition

These glaucomas are caused by other ocular diseases or factors such as inflammation, trauma, bleeding, tumors, medication, and physical or chemical influences (see Table 10.1).



10.4.1 Secondary Open Angle Glaucoma

Definition

The anatomic relationships between the root of the iris, the trabecular meshwork, and peripheral cornea are not disturbed. However, the trabecular meshwork is congested and the resistance to drainage is increased.

The most important forms: Pseudoexfoliative glaucoma. This form occurs particularly frequently in Scandinavian countries. Deposits of amorphous acellular material form throughout the anterior chamber and congest the trabecular meshwork.

Pigmentary glaucoma. Young myopic men typically are affected. The disorder is characterized by release of pigment granules from the pigmentary epithelium of the iris that congest the trabecular meshwork.

Cortisone glaucoma. Thirty-five to forty per cent of the population react to three-week topical or systemic steroid therapy with elevated intraocular pressure. Increased deposits of mucopolysaccharides in the trabecular meshwork presumably increase resistance to outflow; this is reversible when the steroids are discontinued.

Inflammatory glaucoma. *Two mechanisms* contribute to the increase in intraocular pressure:

1. The *viscosity of the aqueous humor increases* as a result of the influx of protein from inflamed iris vessels.
2. The *trabecular meshwork becomes congested* with inflammatory cells and cellular debris.

Phacolytic glaucoma. This is acute glaucoma in eyes with mature or hypermature cataracts. Denatured lens protein passes through the intact lens capsule into the anterior chamber and is phagocytized. The trabecular meshwork becomes congested with protein-binding macrophages and the protein itself.

10.4.2 Secondary Angle Closure Glaucoma

Definition

In secondary angle closure glaucoma as in primary angle closure glaucoma, the increase in intraocular pressure is due to blockage of the trabecular meshwork. However, the primary configuration of the anterior chamber is not the decisive factor.

The most important causes: Rubeosis iridis. Neovascularization draws the angle of the anterior chamber together like a zipper (neovascular glaucoma).



Ischemic retinal disorders such as *diabetic retinopathy* and *retinal vein occlusion* can lead to rubeosis iridis with progressive closure of the angle of the anterior chamber. Other forms of retinopathy or intraocular tumors can also cause rubeosis iridis. The prognosis for eyes with neovascular glaucoma is poor (see Fig. 10.20a and b).

Trauma. Post-traumatic presence of blood or exudate in the angle of the anterior chamber and prolonged contact between the iris and trabecular meshwork in a collapsed anterior chamber (following injury, surgery, or insufficient treatment of primary angle closure) can lead to anterior synechiae and angle closure without rubeosis iridis.

Neovascular glaucoma: secondary angle closure glaucoma with rubeosis iridis.

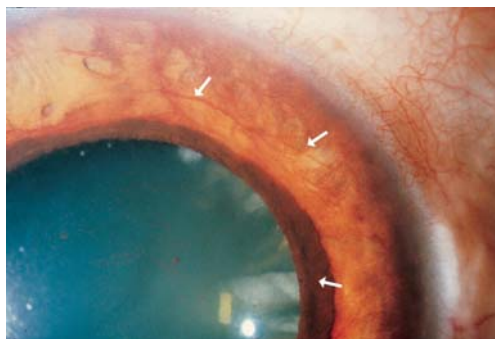
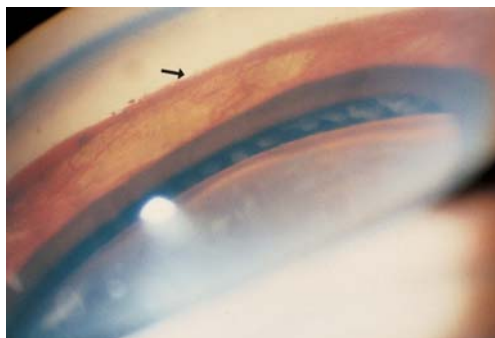

Fig. 10.20
a Rubeosis iridis: Neovascularization (arrow) is visible on the surface of the iris. Contraction everts the posterior pigmented epithelium of the iris on to the anterior surface of the iris (arrow) in a condition known as ectropion uveae.



b Gonioscopy: The angle of the anterior chamber is closed, and the trabecular meshwork is no longer visible (arrow). Rubeosis iridis has drawn the angle of the anterior chamber together like a zipper.



Treatment of secondary glaucomas:

! Medical therapy of secondary glaucomas is usually identical to the treatment of primary chronic open angle glaucoma.

Secondary glaucomas may be caused by many different factors, and the angle may be open or closed. Therefore, treatment will depend on the etiology of the glaucoma. The underlying disorder is best treated first. Glaucomas with uveitis (such as iritis or iridocyclitis) initially are treated conservatively with anti-inflammatory and antiglaucoma agents. Surgery is indicated where conservative treatment is not sufficient.

! The prognosis for secondary glaucomas is generally worse than for primary glaucomas.

10.5 Childhood Glaucomas

Definition

Any abnormal increase in intraocular pressure during the first years of life will cause dilatation of the wall of the globe, and especially of the cornea. The result is a characteristic, abnormally large eye (buphthalmos) with a progressive increase in corneal diameter. This is also referred to as hydrophthalmos or hydrophthalmia.

Epidemiology: Glaucomas in children occur once every 12000–18000 births and account for about 1% of all glaucomas. Primary congenital glaucoma is an inherited autosomal recessive disorder. It is bilateral in approximately 70% of all cases; boys are affected in approximately 70% of all cases; and glaucoma manifests itself before the age of six months in approximately 70% of all cases.

! Today there is widespread public awareness of glaucoma in adults. Unfortunately, this does not yet apply to glaucoma in children.

Etiology: (See also physiology and pathophysiology of aqueous humor circulation): The iris inserts anteriorly far in the trabecular meshwork (Fig. 10.2). Embryonic mesodermal tissue in the form of a thin transparent membrane (Barkan's membrane) covers the trabecular meshwork and impedes the flow of aqueous humor into the canal of Schlemm. Other abnormal ocular or systemic findings are lacking.

Aside from isolated buphthalmos, other ocular changes can lead to secondary hydrophthalmos. These include:

- ❖ Hydrophthalmia with ocular developmental anomalies.
- ❖ Hydrophthalmia with systemic disease.
- ❖ Secondary buphthalmos resulting from acquired eye disorders.



Regardless of the cause of the increase in intraocular pressure, the objective signs and clinical symptoms of childhood forms of glaucoma are identical and should be apparent to any examining physician.

Symptoms: Classic signs include photophobia, epiphora, corneal opacification, and unilateral or bilateral enlargement of the cornea. These changes may be present from birth (in congenital glaucoma) or may develop shortly after birth or during the first few years of life.

Children with this disorder are irritable, poor eaters, and rub their eyes often. The behavior of some children may lead one to suspect mental retardation.

! Physicians should be alert to parents who boast about their child's "big beautiful eyes" and should measure intraocular pressure.

It is essential to diagnose the disorder as early in the child's life as possible to minimize the risk of loss of or irreparable damage to the child's vision.

Diagnostic considerations: These examinations may be performed without general anesthesia in many children. However, general anesthesia will occasionally be necessary to confirm the diagnosis especially in older children (Fig. 10.21).

Congenital glaucoma.

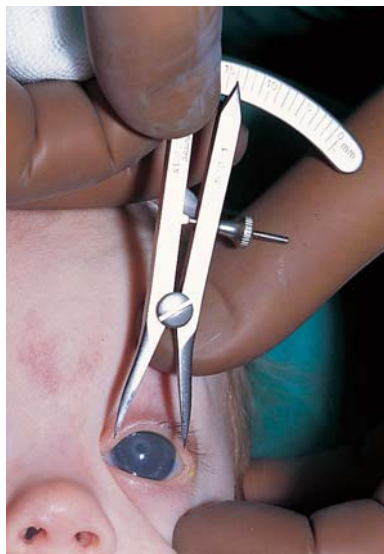

Fig. 10.21 Examination of a three-month-old infant with buphthalmos under general anesthesia. Findings include a corneal diameter of 14.0 mm (normal diameter is approximately 9.5 mm) and stromal opacification.



Measurement of intraocular pressure. One should generally attempt to measure intraocular pressure by applanation tonometry (tonometry with a hand-held tonometer).



Measurement is facilitated by giving the hungry infant a bottle during the examination. Feeding distracts the baby, and a measurement usually can be obtained easily. Such a measurement is usually far more accurate than one obtained under general anesthesia as narcotics, especially barbiturates and halothane, reduce intraocular pressure.

Optic disk ophthalmoscopy. The optic cup is a very sensitive indicator of intraocular pressure, particularly in the phase in which permanent visual field defects occurs. Asymmetry in the optic cup can be helpful in diagnosing the disorder and in follow-up.

Special considerations: A glaucomatous optic cup in children may well be reversible. Often it will be significantly smaller within several hours of a successful trabeculotomy.

Inspection of the cornea. The cornea will appear whitish and opacified due to epithelial edema. Breaks in Descemet's membrane can exacerbate an epithelial or stromal edema. These lesions, known as Haab's striae, will exhibit a typical horizontal or curvilinear configuration.

The enlarged corneal diameter is a characteristic finding. The cornea normally measures 9.5 mm on average in normal newborn infants. Enlargement to more than 10.5 mm suggests childhood glaucoma. Chronically elevated intraocular pressure in children under the age of three will lead to enlargement of the entire globe.

Gonioscopy of the angle of the anterior chamber. Examination of the angle of the anterior chamber provides crucial etiologic information. The angle will not be fully differentiated. Embryonic tissue will be seen to occlude the trabecular meshwork.

Differential diagnosis: Large eyes. A large corneal diameter can occur as a harmless anomaly (megalocornea).

Corneal opacification. Diffuse corneal opacification with epithelial edema occurs in congenital hereditary endothelial dystrophy. Opacification without epithelial edema occurs in mucopolysaccharidosis (Hurler's syndrome, Scheie's syndrome, Morquio's syndrome, and Maroteaux-Lamy syndrome).

Striae in Descemet's membrane. In contrast to the horizontal Haab's striae in congenital glaucoma, endothelial breaks can also occur as a result of injury during a forceps delivery (vertical striae), in keratoconus, and in deep keratitis.



None of these differential diagnoses are accompanied by elevated intraocular pressure.

Treatment: Childhood glaucomas are treated surgically. The prognosis improves the earlier surgery is performed.

Principle and procedure of goniotomy. With a gonioscope in place on the eye, the goniotomy scalpel is advanced through the anterior chamber to the trabecular meshwork. The trabecular meshwork can now be incised as far the canal of Schlemm over an arc of about 120 degrees to permit drainage of the aqueous humor. Often two or three goniotomies at different locations are required to control intraocular pressure. These operations can only be performed when the cornea is clear enough to allow visualization of the structures of the anterior chamber.

Principle and procedure of trabeculotomy. After a conjunctival flap and split-thickness scleral flap have been raised, access to the canal of Schlemm is gained through a radial incision, and the canal is probed with a trabeculotome. Then the trabeculotome is rotated into the anterior chamber (Fig. 10.22). This tears through the inner wall of the canal, the trabecular meshwork, and any embryonic tissue covering it to open a drainage route for the aqueous humor.

A higher rate of success is attributed to trabeculotomy when performed as an initial procedure. This operation can also be performed when the cornea is largely opacified.

Prognosis: Goniotomies and trabeculotomies are not always successful.

Even after apparently successful initial trabecular surgery, these children require a lifetime of follow-up examinations (initially several times a year and later once every year) as elevated intraocular pressure can recur, in which case repeat goniotomy or trabeculotomy is indicated.



Trabeculotomy.

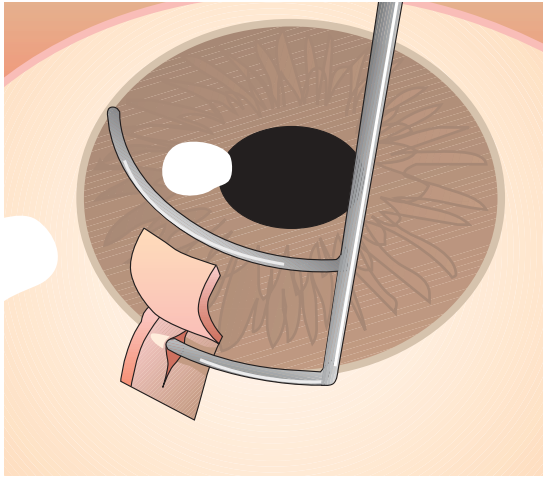
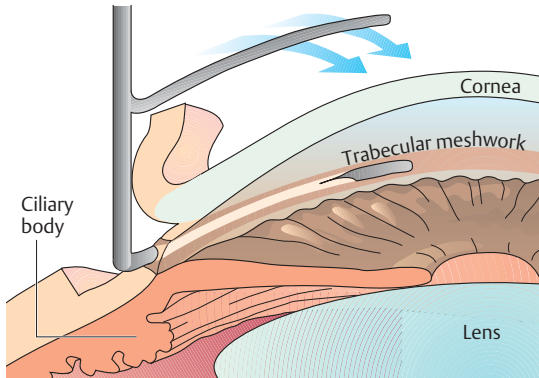
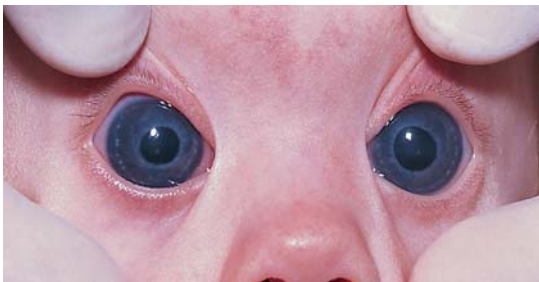

Fig. 10.22
a A 12 o'clock incision is made to expose the canal of Schlemm, which is then probed with a trabeculotome. Then the trabeculotome is rotated into the anterior chamber, tearing through the embryonic tissue occluding the angle. The aqueous humor can now readily drain into the canal of Schlemm.



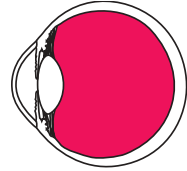
b The surgeon can observe the rotation of the trabeculotome directly through a gonioscope placed on the eye during the operation.



c Right and left eyes following successful trabeculotomy (photograph shows the same child as in Fig. 10.21). Both eyes exhibit a clear cornea (normal corneal light reflex) and normal intraocular pressure.

11 Vitreous Body

Christoph W. Spraul and Gerhard K. Lang



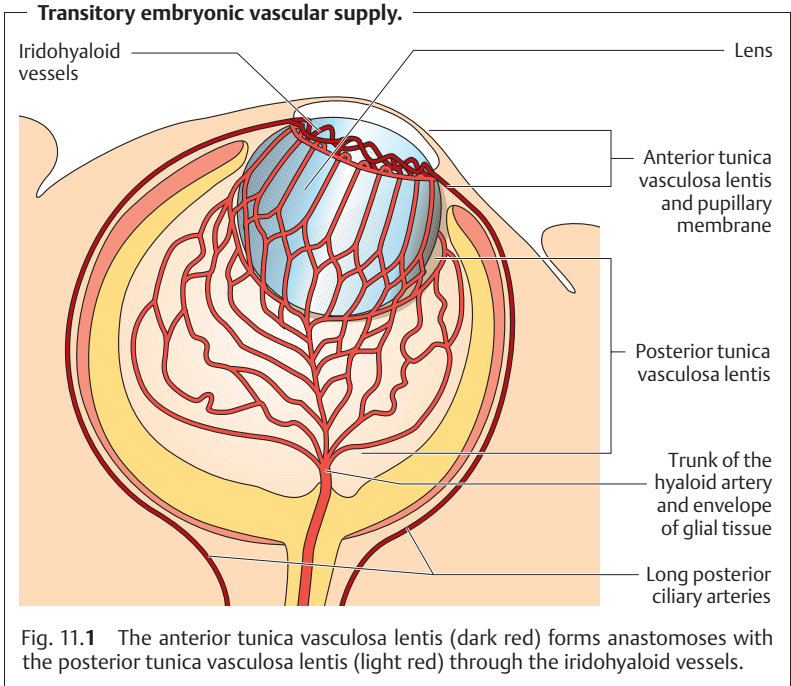
11.1 Basic Knowledge

Importance of the vitreous body for the eye: The vitreous body stabilizes the globe although the eye can remain intact without the vitreous body (see vitrectomy). It also prevents retinal detachment.

Embryology: The development of the vitreous body can be divided into three phases:

- ❖ **First phase** (first month of pregnancy; fetus measures 5–13 mm cranium to coccyx): The **primary vitreous** forms during this period. This phase is characterized by the entry of mesenchyme into the optic cup through the embryonic choroidal fissure. The main *function of the primary vitreous* is to supply the developing lens with nourishment. In keeping with this function, it consists mainly of a vascular plexus, the *anterior and posterior tunica vasculosa lentis*, that covers the anterior and posterior surfaces of the lens. This vascular plexus is supplied by the hyaloid artery and its branches (Fig. 11.1). This vascular system and the primary vitreous regress as the posterior lens capsule develops at the end of the second month of pregnancy.
- ❖ **Second phase** (second month of pregnancy; fetus measures 14–70 mm cranium to coccyx): The **secondary vitreous** forms during this period. This avascular vitreous body consisting of fine undulating collagen fibers develops from what later becomes the retina. In normal development it expands to compress the central primary vitreous into a residual central canal (**hyaloid canal** or **Cloquet's canal**).
- ❖ **Third phase** (third month of pregnancy; fetus measures 71–110 mm cranium to coccyx): The **tertiary vitreous** develops from existing structures in the secondary vitreous. The secondary vitreous remains. The *zonule fibers* that form the suspensory ligament of the lens develop during this period.

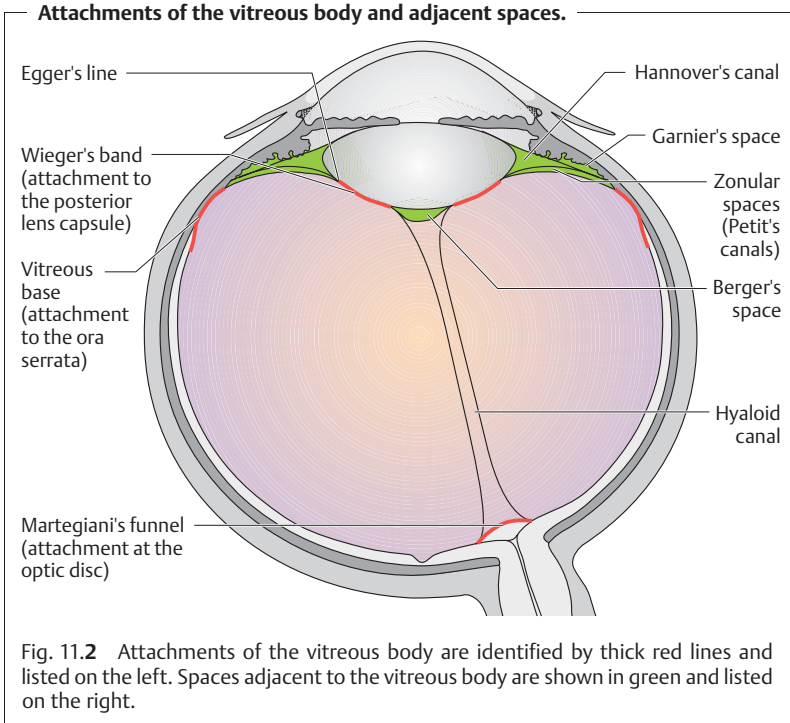
Composition of the vitreous body: The gelatinous vitreous body consists of 98% water and 2% collagen and hyaluronic acid. It fills the vitreous chamber, which accounts for approximately two-thirds of the total volume of the eye.



Stabilization and confines of the vitreous body: With their high negative electrostatic potential, the hyaluronic acid molecules fill the three-dimensional collagen fiber network and provide mechanical stability. *Condensation of peripheral collagen fibrils* creates a **boundary membrane (hyaloid membrane)**, which is *not a basement membrane*. It is attached to adjacent structures at the following locations (Fig. 11.2):

- ❖ At the **ligament of Wieger** along the posterior capsule of the lens.
- ❖ At the **vitreous base** at the ora serrata.
- ❖ At the **funnel of Martegiani** (approximately 10 μm wide) surrounding the periphery of the optic disk.

The connections between the vitreous body and retina are generally loose although there may be firm focal adhesions. These firmer focal attachments cause problems during vitreous detachment because they do not permit the vitreous body to become completely detached. The focal adhesions between the vitreous body and retina produce focal traction forces that act on the retina and can cause retinal tears and detachment.



Neurovascular supply: The vitreous body contains neither blood vessels nor nerves. As a result, pathogens can multiply undisturbed for a relatively long time before the onset of an immune response from adjacent structures.

11.2 Examination Methods

The anterior third of the vitreous body can be readily examined with a **slit lamp**. An additional **contact lens** or **hand-held condensing lens** (+60, +78, and +90 diopters) is required to examine the posterior portions. **Indirect ophthalmoscopy** or **retroillumination** (Brückner's test) is usually used to examine the vitreous body in its entirety. Opacities will appear as dark shadows. **Ultrasound examination** of the vitreous body is performed in cases such as a mature cataract where visualization by other methods is not possible.



11.3 Aging Changes

11.3.1 Synchysis

The regular arrangement of collagen fibers gradually deteriorates in middle age. The fibers condense to flattened filamentous structures. This process, known as liquefaction, creates small fluid-filled lacunae in the central vitreous body that initially are largely asymptomatic (patients may report floaters). However, once liquefaction has progressed beyond a certain point, the vitreous body can collapse and detach from the retina.

11.3.2 Vitreous Detachment

Definition

Complete or partial detachment of the vitreous body from its underlying tissue. The most common form is *posterior vitreous detachment* (see Fig. 11.3 a); *anterior* or *basal vitreous detachment* is much rarer.

Epidemiology: Six percent of patients between the ages of 54 and 65 and 65% of all patients between the ages of 65 and 85 have posterior vitreous detachment. Patients with axial myopia have a predisposition to early vitreous detachment. Presumably the vitreous body collapses earlier in these patients because it must fill a “longer” eye with a larger volume.

Etiology: Liquefaction causes collapse of the vitreous body. This usually begins posteriorly where the attachments to the underlying tissue are least well developed. Detachment in the anterior region (*anterior vitreous detachment*) or in the region of the vitreous base (*basal vitreous detachment*) usually only occurs where strong forces act on the globe as in ocular trauma.

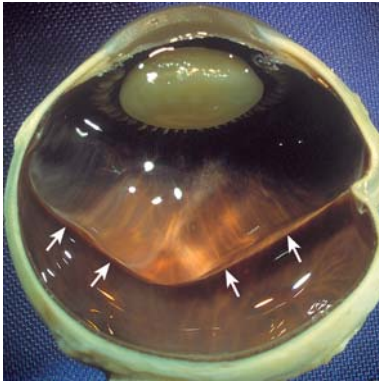
Symptoms and findings: *Collapse of the vitreous body* leads to vitreous densities that the patient perceives as mobile opacities. These floaters (also known as flies or cobwebs) may take the form of circular or serpentine lines or points. The vitreous body may detach partially or completely from the retina. An increased risk of retinal detachment is present only with *partial vitreous detachment*. In this case, the vitreous body and retina remain attached, with the result that eye movements in this region will place traction on the retina. The patient perceives this phenomenon as **flashes of light**. If the traction on the retina becomes too strong, it can tear (see retinal tears in posterior vitreous detachment, Fig. 11.3 b – c). This increases the risk of retinal detachment and vitreous bleeding from injured vessels.



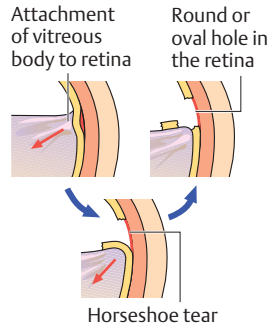
Floaters and especially flashes of light require thorough examination of the ocular fundus to exclude a retinal tear.



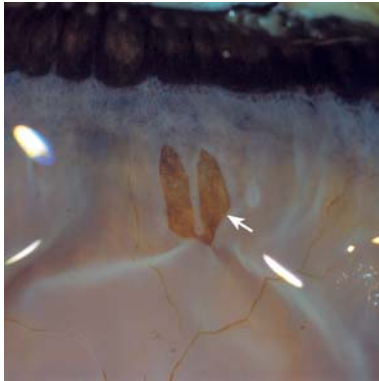
Retinal tears in posterior vitreous detachment.



a



b



c

Fig. 11.3 **a** Complete posterior vitreous detachment (arrows). **b** This can produce traction at the posterior attachment of the base of the vitreous body to the retina, causing retinal tears. **c** Autopsy finding of a manifest retinal tear with traction of the vitreous body at the edge of the opening (arrow).

Diagnostic considerations: The symptoms of vitreous detachment require examination of the entire fundus of the eye to exclude a retinal defect. In cases such as lens opacification or vitreous hemorrhage where visualization is not possible, an ultrasound examination is required to evaluate the vitreous body and retina.



Vitreous detachment in the region of the attachment at the optic disk (*funnel of Martegiani*) will appear as a smokey ring (*Weiss' ring*) under ophthalmoscopy.



Weiss' ring.

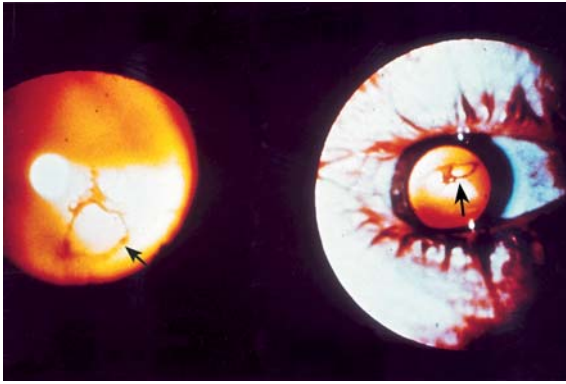


Fig. 11.4 The smokey ring appears when the vitreous body detaches from its attachment at the optic disk at the funnel of Martegiani (arrow).

Treatment: The symptoms of vitreous detachment resolve spontaneously once the vitreous body is completely detached. However, the complications that can accompany partial vitreous detachment require treatment. These include retinal tears, retinal detachment (for treatment see Chapter 12, Retina), and vitreous hemorrhage.

11.4 Abnormal Changes in the Vitreous Body

11.4.1 Persistent Fetal Vasculature (Developmental Anomalies)

The embryonic vascular system in the vitreous body and lens normally disappears completely, leaving only the *hyaloid canal*. Persistence of the vascular system is referred to as **persistent fetal vasculature**. The following section describes the varying degrees of severity of this syndrome as they relate to the vitreous body. Persistence of the anterior tunica vasculosa lentis leads to a persistent pupillary membrane.

11.4.1.1 Mittendorf's Dot

Mittendorf's dot is a small visually asymptomatic opacity in the posterior lens capsule located approximately 0.5 mm medial to the center. This is the site where the hyaloid artery enters the embryonic lens. This harmless change occurs in up to 2% of the total population. Normal lens fiber development *can* be disturbed where *large* portions of the hyaloid arterial system remain, although this occurs very rarely. These patients develop posterior polar cataracts.



11.4.1.2 Bergmeister's Papilla

11.4.1.3 Persistent Hyaloid Artery

Isolated persistence of the hyaloid artery is rare. Usually this phenomenon is accompanied by persistence of the hyperplastic primary vitreous (see next section). A persistent hyaloid artery will appear as a whitish cord in the hyaloid canal proceeding from the optic disk and extending to the posterior capsule of the lens. Isolated persistence of the hyaloid artery is asymptomatic and does not require treatment.

11.4.1.4 Persistent Hyperplastic Primary Vitreous (PHPV)

Definition

Persistence of the embryonic primary vitreous (hyaloid arterial system including the posterior tunica vasculosa lentis).

Epidemiology: This developmental anomaly is also very rare.

Symptoms and findings: Usually the disorder is *unilateral*.

Anterior variant of PHPV. With this *more frequent* variant, a *white pupil* (leukocoria or amaurotic cat's eye) typically will be discovered shortly after birth. This is caused by the whitish plate of connective tissue posterior to the lens. Depending on the severity, it will be accompanied by more or less severe changes in the lens leading to more or less severely impaired vision. In extreme cases, the lens resembles an opacified membrane (*membranous cataract*). In rare cases, fatty tissue will develop (*lipomatous pseudophakia*), and even more rarely *cartilage will develop in the lens*. Retrolenticular scarring draws the ciliary processes toward the center, and they will be visible in the pupil. Growth of the eye is retarded. This results in *microphthalmos* unless drainage of the aqueous humor is also impaired, in which case *buphthalmos* (*hydrophthalmos*) will be present.

Posterior variant of PHPV. Retinal detachment and *retinal dysplasia* can occur where primarily posterior embryonic structures persist. The whitish plate of connective tissue will only be visible where anterior changes associated with persistent hyperplastic primary vitreous are also present. The reduction in visual acuity will vary depending on the severity of the retinal changes.

Diagnostic considerations: A definitive diagnosis is usually possible on the basis of the characteristic clinical picture (see symptoms and findings) and additional ultrasound studies (when the posterior segment is obscured by lens opacities).



Differential diagnosis: Other causes of leukocoria (Table 11.1) should be excluded. Retinoblastoma, the most important differential diagnosis, can usually be excluded on the basis of ultrasound or CT studies. In the presence of a retinoblastoma, these studies will reveal an intraocular mass with calcifications. In contrast to PHPV, *microphthalmos* will not be present.

! Leukocoria should be regarded as a retinoblastoma until proven otherwise.

Treatment: The disorder is not usually treated as neither conservative therapy nor surgery can improve visual acuity. Surgery is indicated only where complications such as progressive collapse of the anterior chamber, secondary increase in intraocular pressure, vitreous hemorrhage, and retinal detachment are present or imminent. The only goal is to save the eye and maintain existing visual acuity.

Table 11.1 Differential diagnosis of leukocoria

Possible causes	Differential criteria
Congenital cataract (4–8:20 000)	Early infancy, unilateral or bilateral, normal globe size.
Retinoblastoma (1:20 000)	Infancy, normal globe size, unilateral (two-thirds) or bilateral (one-third), calcifications in tumor.
Retinopathy of prematurity, grade V (1:20 000)	Early infancy, usually bilateral, no microphthalmos, preterm birth with oxygen therapy.
Exudative retinitis (Coats' disease)	Childhood, unilateral.
Persistent hyperplastic primary vitreous	Usually unilateral, usually microphthalmos, congenital, centrally displaced ciliary processes.
Tumors	Astrocytoma, medulloepithelioma.
Exudative retinal detachment	In toxocariasis, angiomas of retinae (von Hippel-Lindau tumor), diffuse choroidal hemangioma.
Other causes	Norrie's disease, incontinentia pigmenti (Bloch-Sulzberger disease), juvenile retinoschisis, retinal dysplasia, vitreous abscess, myelinated nerve fibers, coloboma of the optic disk (morning glory disk), foreign bodies in the vitreous chamber.



Clinical course and prognosis: The clinical course and prognosis depend primarily on the severity of the disorder. However, adequate surgical intervention can often save the eye and stabilize visual acuity even if at a very low level.

11.4.2 Abnormal Opacities of the Vitreous Body

11.4.2.1 Asteroid Hyalosis

These usually unilateral opacities of the vitreous body (75% of all cases) are not all that infrequent. They are thought to be linked to diabetes mellitus and hypercholesterolemia. The disorder is characterized by white calcific deposits that are associated with the collagen fibers of the vitreous body and therefore are not very mobile. Most patients are not bothered by these opacities. However, the examiner's view of the fundus can be significantly obscured by "snow flurries" of white opacities. Interestingly, these opacities do not interfere with fluorescein angiography. Vitrectomy to remove the opacities is rarely necessary and is performed only when the opacities adversely affect the patient, i.e., when visual acuity is diminished.

11.4.2.2 Synchysis Scintillans

These *very rare* opacities of the vitreous body usually occur unilaterally following recurrent intraocular inflammation or bleeding. In contrast to asteroid hyalosis, these opacities are free floating cholesterol crystals in the vitreous chamber that respond to gravity. Fractile crystals are typical. Surgery is only indicated in rare cases in which the opacities impair visual acuity.

11.4.2.3 Vitreous Amyloidosis

This *rare* inherited autosomal dominant disorder begins at about the age of 20, progresses for decades, and finally leads to diminished visual acuity. Amyloidosis causes characteristic amyloid deposits around the collagen fibers of the vitreous body except for the hyaloid canal, which remains unaffected. The amyloid exhibits histologically typical staining. The disorder can be treated by vitrectomy.

11.4.3 Vitreous Hemorrhage

Definition

Bleeding into the vitreous chamber or a space created by vitreous detachment.

Epidemiology: The annual incidence of this disorder is seven cases per 100 000.



Etiology: A vitreous hemorrhage may involve one of three possible **pathogenetic mechanisms** (Fig. 11.5):

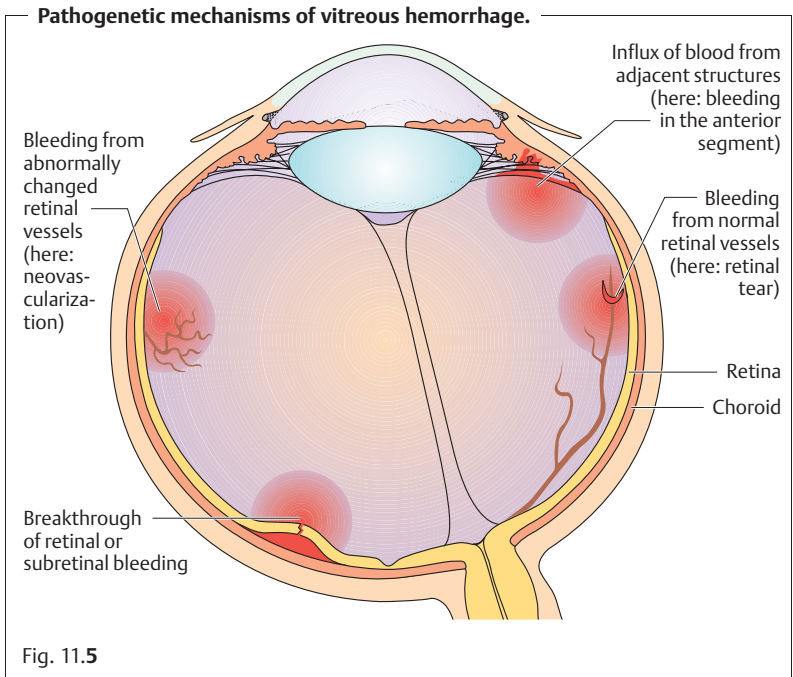
- ❖ 1. Bleeding from *normal retinal vessels* as can occur as a result of mechanical vascular damage in acute vitreous detachment or retinal tear.
- ❖ 2. Bleeding from *retinal vessels with abnormal changes* as can occur as a result of retinal neovascularization in ischemic retinopathy or retinal macroaneurysms.
- ❖ 3. *Influx of blood from the retina or other sources* such as the subretinal space or the anterior segments of the eye.

More frequent causes of vitreous hemorrhage include:

- ❖ Posterior vitreous detachment with or without retinal tears (38%).
- ❖ Proliferative diabetic retinopathy (32%).
- ❖ Branch retinal vein occlusion (11%).
- ❖ Age-related macular degeneration (2%).
- ❖ Retinal macroaneurysm (2%).

Less frequent causes of vitreous hemorrhage include:

- ❖ Arteriosclerosis.
- ❖ Retinal periphlebitis.





- ❖ Terson's syndrome (subarachnoid hemorrhage, increase in intraocular pressure, acutely impaired drainage of blood from the eye, dilation and rupture of retinal vessels, retinal and vitreous hemorrhage).
- ❖ Penetrating trauma.
- ❖ Retinal vascular tumors.

Symptoms: Patients often report the sudden occurrence of black opacities that they may describe as “*swarms of black bugs*” or “*black rain*.” These are distinct from the brighter and less dense floaters seen in synchysis and vitreous detachment. Severe vitreous hemorrhage can significantly reduce *visual acuity*. Approximately 10 μ l of blood are sufficient to reduce visual acuity to perception of hand movements in front of the eye.

Diagnostic considerations: *Hemorrhages into the vitreous body itself* do not exhibit any characteristic limitations but spread *diffusely* (the blood cannot form a fluid meniscus in the *gelatinous* vitreous body) and coagulation occurs quickly (Fig. 11.6). Vitreous hemorrhages require examination with an ophthalmoscope or contact lens. The contact lens also permits examination of the retina at a higher resolution so that the examiner is better able to diagnose small retinal tears than with an ophthalmoscope. Ultrasound studies are indicated where severe bleeding significantly obscures the fundus examination. *Bleeding in the tissues adjacent to the vitreous body*, i.e., in the retrohyaloid space, Berger's space, or Petit's space (Fig. 11.2), can produce a *characteristic fluid meniscus*. This meniscus will be visible under slit-lamp examination (Fig. 11.6b).

Treatment: Patients with acute vitreous hemorrhage should be placed in an *upright resting position*. This has two beneficial effects:

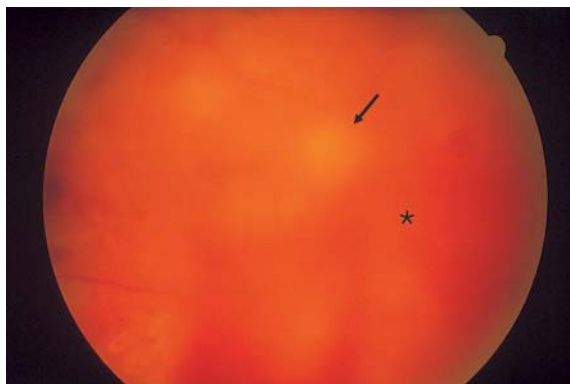- ❖ 1. The bleeding usually does not continue to spread into the vitreous body.
- ❖ 2. The blood in the retrohyaloid space will settle more quickly.

Next the *cause of the vitreous hemorrhage* should be treated, for example a retinal tear may be treated with a laser. Vitrectomy will be required to drain any vitreous hemorrhage that is not absorbed.

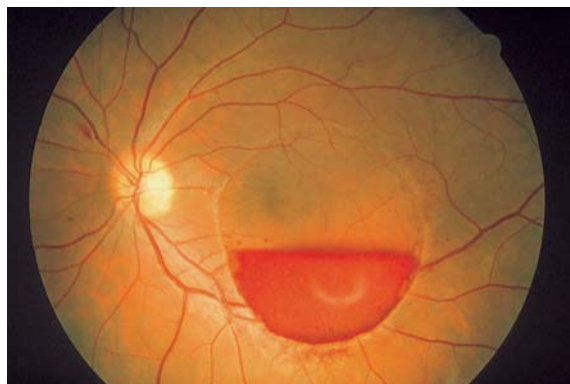
Clinical course and prognosis: Absorption of a vitreous hemorrhage is a long process. The clinical course will depend on the location, cause, and severity of the bleeding. Bleeding in the vitreous body itself is absorbed particularly slowly.



Forms of vitreous hemorrhage.



Figs. 11.6 a and b
a Diffuse vitreous hemorrhage. The view of the fundus is obscured by the vitreous hemorrhage; details are clouded or completely obscured. The star indicates the center of the vitreous hemorrhage; the arrow indicates the optic disk.



b Retrohyaloid bleeding with formation of a fluid meniscus. The image shows bleeding into a space created by a circular vitreous detachment. Gravity has caused the erythrocytes to sink and form a horizontal surface.

11.4.4 Vitritis and Endophthalmitis

Definition

This refers to acute or chronic intraocular inflammation due to microbial or immunologic causes. In the strict sense, any intraocular inflammation is **endophthalmitis**. However, in clinical usage and throughout this book, endophthalmitis refers only to inflammation caused by a microbial action that also involves the vitreous body (vitritis). On the other hand, **isolated vitritis** without involvement of the other intraocular structures is inconceivable due to the avascularity of the vitreous chamber.



Epidemiology: Microbial vitritis or endophthalmitis occurs most frequently as a result of penetrating trauma to the globe. Rarely (in 0.5% of all cases) it is a complication of inciseive intraocular surgery.

Etiology: Because the vitreous body consists of only a few cellular elements (hyalocytes), inflammation of the vitreous body is only possible when the inflammatory cells can gain access to the vitreous chamber from the uveal tract or retinal blood vessels. This may occur via one of the following mechanisms:

- ❖ **Microbial pathogens**, i.e., bacteria, fungi, or viruses, enter the vitreous chamber either through direct contamination (for example via penetrating trauma or inciseive intraocular surgery) or metastatically as a result of sepsis. The virulence of the pathogens and the patient's individual immune status determine whether an *acute*, *subacute*, or *chronic* inflammation will develop. Bacterial inflammation is far more frequent than viral or fungal inflammation. However, the metastatic form of endophthalmitis is observed in immunocompromised patients. Usually the inflammation is fungal (mycotic endophthalmitis), and most often it is caused by one of the *Candida* species.
- ❖ **Inflammatory (microbial or autoimmune) processes, in structures adjacent to the vitreous body**, such as uveitis or retinitis can precipitate a secondary reaction in the vitreous chamber.



Acute endophthalmitis is a serious clinical syndrome that can result in loss of the eye within a few hours.

Symptoms: Acute vitreous inflammation or endophthalmitis. Characteristic symptoms include acute loss of visual acuity accompanied by deep dull ocular pain that responds only minimally to analgesic agents. Severe reddening of the conjunctiva is present. In contrast to bacterial or viral endophthalmitis, mycotic endophthalmitis begins as a subacute disorder characterized by slowly worsening chronic visual impairment. Days or weeks later, this will also be accompanied by severe pain.

Chronic vitreous inflammation or endophthalmitis. The clinical course is far less severe, and the loss of visual acuity is often moderate.

Diagnostic considerations: The patient's history and the presence of typical symptoms provide important information.

Acute vitreous inflammation or endophthalmitis. Slit-lamp examination will reveal massive conjunctival and ciliary injection accompanied by hypopyon (collection of pus in the anterior chamber). Ophthalmoscopy will reveal yellowish-green discoloration of the vitreous body occasionally referred to as a *vitreous body abscess*. If the view is obscured, ultrasound studies can help to evaluate the *extent of the involvement of the vitreous body in endophthalmitis*. Roth's spots (white retinal spots surrounded by hemor-



rhage) and circumscribed retinochoroiditis with a vitreous infiltrate will be observed in the initial stages (during the first few days) of *mycotic endophthalmitis*. In advanced stages, the vitreous infiltrate has a creamy whitish appearance, and retinal detachment can occur.

Chronic vitreous inflammation or endophthalmitis. Inspection will usually reveal only moderate conjunctival and ciliary injection. Slit-lamp examination will reveal infiltration of the vitreous body by inflammatory cells.

A conjunctival smear, a sample of vitreous aspirate, and (where sepsis is suspected) blood cultures should be obtained for microbiological examination to identify the pathogen. Negative microbial results do not exclude possible microbial inflammation; the clinical findings are decisive. See Chapter 12 for diagnosis of retinitis and uveitis.

Differential diagnosis: The diagnosis is made by clinical examination in most patients. Intraocular lymphoma should be excluded in chronic forms of the disorder that fail to respond to antibiotic therapy.

Treatment: Microbial inflammations require pathogen-specific systemic, topical, and intravitreal therapy, where possible according to the strain's documented resistance to antibiotics. *Mycotic endophthalmitis* is usually treated with amphotericin B and steroids. Immediate vitrectomy is a therapeutic option whose indications have yet to be clearly defined.

Secondary vitreous reactions in the presence of underlying retinitis or uveitis should be addressed by treating the underlying disorder.

Prophylaxis: Intraocular surgery requires extreme care to avoid intraocular contamination with pathogens. Immunocompromised patients (such as AIDS patients or substance abusers) and patients with indwelling catheters should undergo regular examination by an ophthalmologist.



Decreased visual acuity and eye pain in substance abusers and patients with indwelling catheters suggest *Candida* endophthalmitis.

Clinical course and prognosis: The prognosis for **acute microbial endophthalmitis** depends on the virulence of the pathogen and how quickly effective antimicrobial therapy can be initiated. Extremely virulent pathogens such as *Pseudomonas* and delayed initiation of treatment (not within a few hours) worsen the prognosis for visual acuity. With postoperative inflammation and poor initial visual acuity, an immediate vitrectomy can improve the clinical course of the disorder. The prognosis is usually far better for **chronic forms** and secondary vitritis in uveitis/vitritis.



11.4.5 Vitreoretinal Dystrophies

11.4.5.1 Juvenile Retinoschisis

Juvenile retinoschisis is an inherited X-linked recessive disorder that *affects only males*. A retinal schisis at the macula sometimes referred to clinically as a “*spoke phenomenon*” usually develops between the ages of 20 and 30. This is associated with a significant loss of visual acuity. A peripheral retinal schisis is also present in about half of these cases. This splitting of the retina is presumably due to traction of the vitreous body. This *splitting occurs in the nerve fiber layer* in contrast to typical senile retinoschisis, in which *splitting occurs in the outer plexiform layer*.

11.4.5.2 Wagner’s Disease

This disorder is also inherited (autosomal dominant) and involves central liquefaction of the vitreous body. This “visual void” in the vitreous chamber and fibrillary condensation of the vitreous stroma associated with a cataract characterize *vitreoretinal degeneration in Wagner’s disease*.

11.5 The Role of the Vitreous Body in Various Ocular Changes and Following Cataract Surgery

11.5.1 Retinal Detachment

The close connection between the vitreous body and retina can result in retinal tears in vitreous detachment, which in turn can lead to **rhegmatogenous retinal detachment** (from the Greek word “rhegma,” breakage).

These retinal defects provide an opening for cells from the retinal pigment epithelium to enter the vitreous chamber. These pigment cells migrate along the surface of the retina. As they do so, they act similarly to myofibroblasts and lead to the formation of subretinal and epiretinal membranes and cause *contraction of the surface of the retina*. This clinical picture is referred to as **proliferative vitreoretinopathy** (PVR). The rigid retinal folds and vitreous membranes in proliferative vitreoretinopathy significantly complicate reattachment of the retina. Usually this requires modern techniques of vitreous surgery.

11.5.2 Retinal Vascular Proliferation

Retinal vascular proliferation can occur in retinal ischemia in disorders such as diabetic retinopathy, retinopathy in preterm infants, central or branch retinal vein occlusion, and sickle-cell retinopathy. *Growth of this retinal neovascularization into the vitreous chamber* usually occurs only where vitreous detachment is absent or partial because these proliferations require a substrate to grow on. Preretinal proliferations often lead to *vitreous hemorrhage*.



Fibrotic changes produce traction of the retina resulting in a *tractional* retinal detachment.

11.5.3 Cataract Surgery

Increased postoperative inflammation in the anterior segment can progress through the *hyaloid canal* to the posterior pole of the eye and a cystoid macular edema can develop. This complication occurs particularly frequently following cataract surgery in which the posterior lens capsule was opened with partial loss of vitreous body. (Hruby-Irvine-Gass syndrome is the development of cystoid macular edema following intracapsular cataract extraction with incarceration of the vitreous body in the wound).

11.6 Surgical Treatment: Vitrectomy

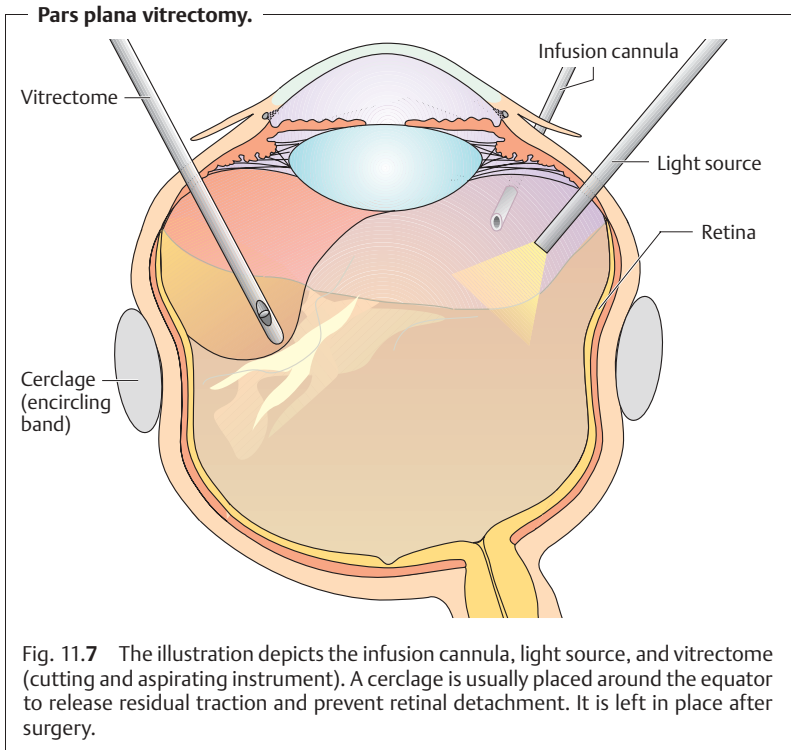
Definition

Surgical removal and replacement of the vitreous body with Ringer's solution, gas, or silicone oil.

Indication: The primary indications include:

- ❖ Unabsorbed vitreous hemorrhage.
- ❖ Tractional retinal detachment.
- ❖ Proliferative vitreoretinopathy.
- ❖ Removal of intravitreal displaced lenses or foreign bodies.
- ❖ Severe postoperative or post-traumatic inflammatory vitreous changes.

Procedure: The vitreous body cannot simply be aspirated from the eye as the vitreoretinal attachments would also cause retinal detachment. The procedure requires *successive, piecemeal cutting and aspiration with a vitrectome* (a specialized cutting and aspirating instrument). Cutting and aspiration of the vitreous body is performed with the aid of simultaneous infusion to prevent the globe from collapsing. The surgical site is illuminated by a fiberoptic light source. The three instruments (infusion cannula, light source, and vitrectome), all 1 mm in diameter, are introduced into the globe through the pars plana, which is why the procedure is referred to as a *pars plana vitrectomy* (PPV). This site entails the least risk of iatrogenic retinal detachment (Fig. 11.7). The surgeon holds the vitrectome in one hand and the light source in the other. The procedure is performed under an operating microscope with special contact lenses placed on the corneal surface. Once the vitreous body and any vitreous membranes have been removed (Fig. 11.7), the retina can be treated intraoperatively with a laser (for example, to treat proliferative diabetic retinopathy or repair a retinal tear). In many cases, such as with an unabsorbed vitreous hemorrhage, it is sufficient to fill the eye with Ringer's solution following vitrectomy.



Filling the eye with Ringer's solution is not sufficient to treat a **complicated retinal detachment** with epiretinal or subretinal membranes and contraction of the surface of the retina (see proliferative vitreoretinopathy). In these cases, the detached retina must be flattened from anterior to posterior and held with a tamponade of fluid with a very high specific gravity such as a perfluorocarbon liquid (Fig. 11.8a). These "heavy" liquids can also be used to float artificial lenses that have become displaced in the vitreous body. The artificial lenses have a lower specific gravity than these liquids and will float on them (Fig. 11.8b). At the end of the operation, these heavy liquids must be replaced with gases, such as a mixture of air and sulfur hexafluoride, that are spontaneously absorbed within a few days or with silicone oil (which must be removed in a second operation). Postoperative patient positioning should reflect the fact that maximum gas pressure will be in the superior region (Fig. 11.9a) due to its buoyancy. Complicated retinal detachments will require a prolonged internal tamponade. Silicone oil has proven effective for this pur-



Use of “heavy” liquids in vitreoretinal surgery.

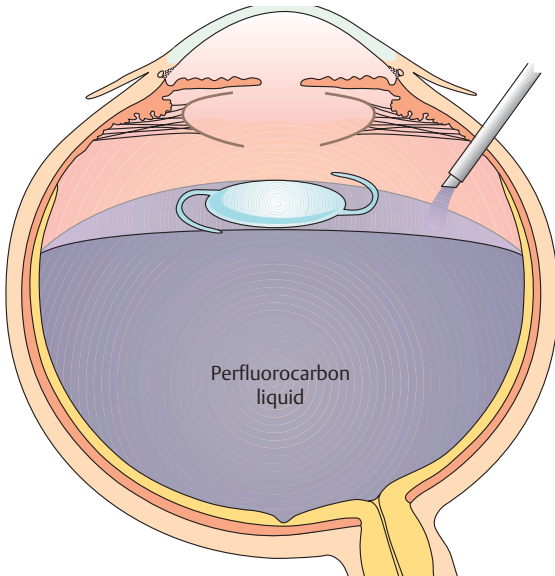
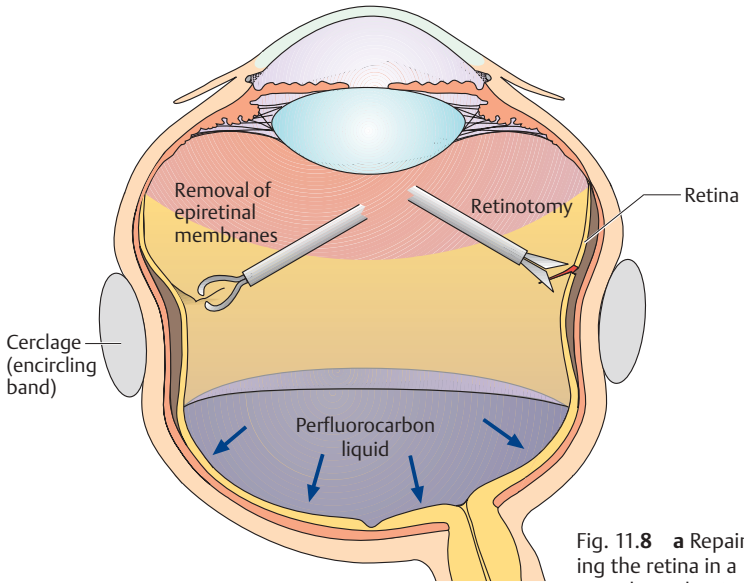


Fig. 11.8 **a** Repairing the retina in a complicated retinal detachment using a liquid with a high specific gravity. The high specific gravity of the liquid flattens out the retina. The liquid acts as a “third hand” when manipulating the retina, simplifying maneuvers such as removal of epiretinal membranes and retinotomies. **b** Floating a displaced intraocular lens.

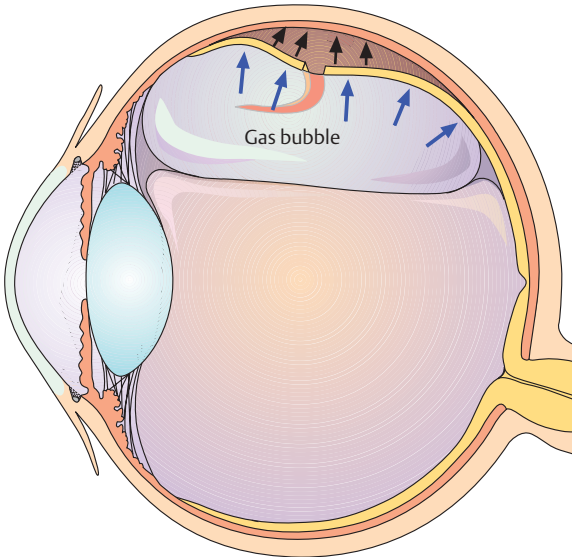
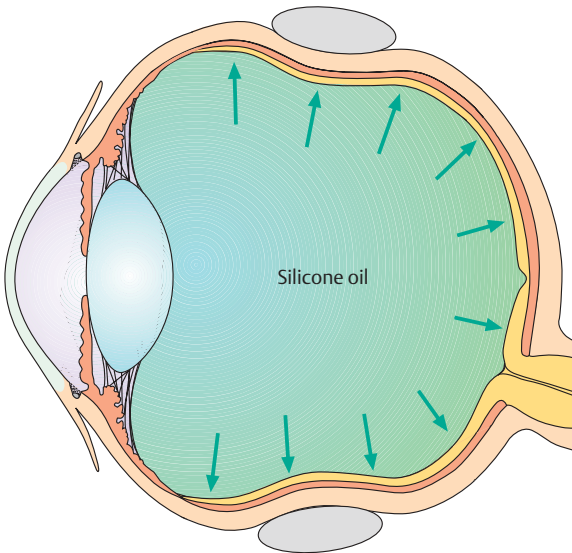
**Use of gas and silicone oil in vitreoretinal surgery.**

Fig. 11.9 a An intraocular gas bubble exerts pressure primarily in the superior area (blue arrows) due to its buoyancy. This must be considered when positioning the patient postoperatively; the patient should be positioned so that the foramen lies in this region.



b Completely filling the globe with silicone oil fixes the retina to its underlying tissue at practically every location (arrows).

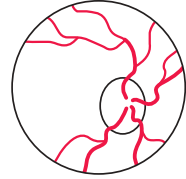


pose as it completely fills the vitreous chamber and exerts permanent pressure on the entire retina (Fig. 11.9b). However, silicone oil inevitably causes cataract formation and occasionally corneal changes and glaucoma. Therefore, it must be removed in a second operation.

Complications: Vitrectomy nearly always leads to subsequent lens opacification, and rarely to retinal tears, bleeding, or endophthalmitis.

12 Retina

Gabriele K. Lang and Gerhard K. Lang



12.1 Basic Knowledge

The retina is the *innermost* of three successive layers of the globe. It comprises two parts:

- ❖ A **photoreceptive part (pars optica retinae)**, comprising the first nine of the 10 layers listed below.
- ❖ A **nonreceptive part (pars caeca retinae)** forming the epithelium of the ciliary body and iris.

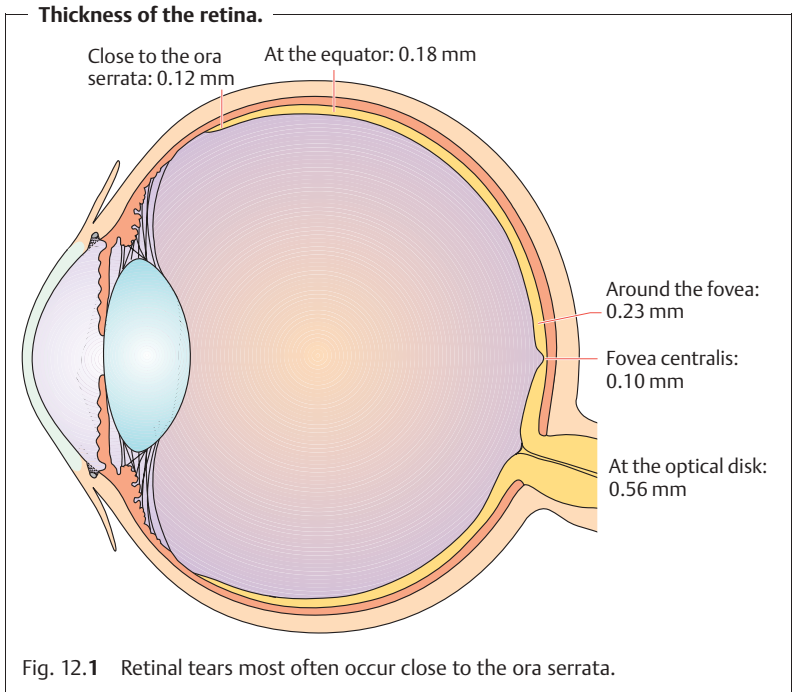
The pars optica retinae merges with the pars caeca retinae at the *ora serrata*.

Embryology: The retina develops from a *diverticulum of the forebrain* (proencephalon). Optic vesicles develop which then invaginate to form a double-walled bowl, the optic cup. The outer wall becomes the pigment epithelium, and the inner wall later differentiates into the nine layers of the retina. The retina remains linked to the forebrain throughout life through a structure known as the retinohypothalamic tract.

Thickness of the retina (Fig. 12.1)

Layers of the retina: Moving inward along the path of incident light, the individual layers of the retina are as follows (Fig. 12.2):

1. Inner limiting membrane (glial cell fibers separating the retina from the vitreous body).
2. Layer of optic nerve fibers (axons of the third neuron).
3. Layer of ganglion cells (cell nuclei of the multipolar ganglion cells of the third neuron; “data acquisition system”).
4. Inner plexiform layer (synapses between the axons of the second neuron and dendrites of the third neuron).
5. Inner nuclear layer (cell nuclei of the bipolar nerve cells of the second neuron, horizontal cells, and amacrine cells).
6. Outer plexiform layer (synapses between the axons of the first neuron and dendrites of the second neuron).
7. Outer nuclear layer (cell nuclei of the rods and cones = first neuron).
8. Outer limiting membrane (sieve-like plate of processes of glial cells through which rods and cones project).



9. Layer of rods and cones (the actual photoreceptors).
10. Retinal pigment epithelium (a single cubic layer of heavily pigmented epithelial cells).
11. Bruch's membrane (basal membrane of the choroid separating the retina from the choroid).

Macula lutea: The macula lutea is a flattened oval area in the center of the retina approximately 3–4 mm (15 degrees) temporal to and *slightly below* the optic disk. Its diameter is roughly equal to that of the optic disk (1.7–2 mm). The macula appears *yellow* when examined under green light, hence the name macula lutea (yellow spot). Located in its center is the avascular fovea

Fig. 12.2 **a** Layers of the retina and examination methods used to diagnose abnormal processes in the respective layers (EOG = electro-oculogram; ERG = electroretinogram; VEP = visual evoked potential). **b** Histologic image of the 10 layers of the retina.



Histology and function of the layers of the retina.

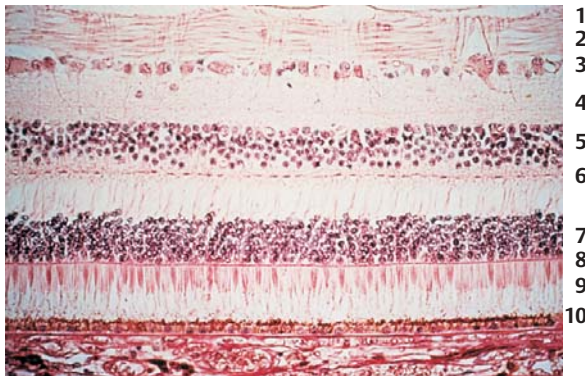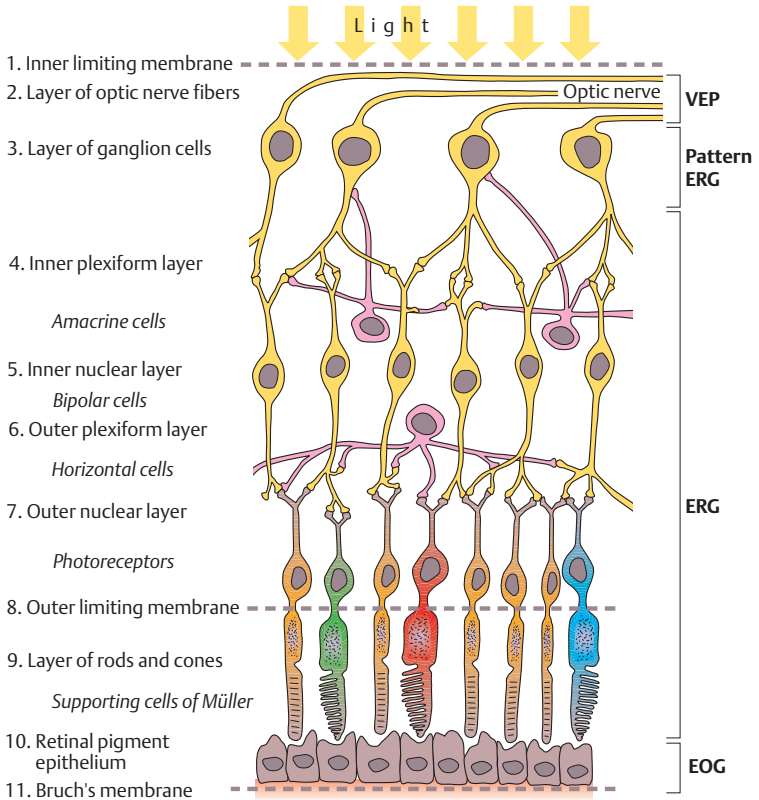


Fig. 12.2



centralis, the point at which visual perception is sharpest. The fovea centralis contains only cones (no rods) each with its own neural supply, which explains why this region has such distinct vision. Light stimuli in this region can directly act on the sensory cells (first neuron) because the bipolar cells (second neuron) and ganglion cells (third neuron) are displaced peripherally.

Vascular supply to the retina: The **inner layers** of the retina (the inner limiting membrane through the inner nuclear layer) are supplied by the central artery of the retina. This originates at the ophthalmic artery, enters the eye with the optic nerve, and branches on the inner surface of the retina. The central artery is a genuine artery with a diameter of 0.1 mm. It is a terminal artery without anastomoses and divides into four main branches (see Fig. 12.8).

! Because the central artery is a terminal artery, occlusion will lead to retinal infarction.

The **outer layers** (outer plexiform layer through the pigment epithelium) contain no capillaries. They are nourished by diffusion primarily from the richly supplied capillary layer of the choroid. The **retinal arteries** are normally *bright red*, have bright red reflex strips (see Fig. 12.8) that become paler with advancing age, and do not show a pulse. The **retinal veins** are *dark red* with a narrow reflex strip, and may show spontaneous pulsation on the optic disk.

! Pulsation in the retinal veins is normal; pulsation in the retinal arteries is abnormal.

The walls of the vessels are transparent so that only the blood will be visible on ophthalmoscopy. In terms of their structure and size, the retinal vessels are arterioles and venules, although they are referred to as arteries and veins. **Venous diameter** is normally 1.5 times greater than **arterial diameter**. Capillaries are not visible.

Nerve supply to the retina: The neurosensory retina has no sensory supply.

! Disorders of the retina are painless because of the absence of sensory supply.

Light path through the retinal layers: When electromagnetic radiation in the visible light spectrum (wavelengths of 380–760 nm) strikes the retina, it is absorbed by the photopigments of the outer layer. Electric signals are created in a multi-step photochemical reaction. They reach the photoreceptor synapses as action potentials where they are relayed to the second neuron. The signals are relayed to the third and fourth neurons and finally reach the visual cortex.

! Light must pass through three layers of cell nuclei before it reaches the photosensitive rods and cones. This inverted position of the photoreceptors is due to the manner in which the retina develops from a diverticulum of the forebrain.



Sensitivity of the retina to light intensity: The retina has two types of photoreceptors, the rods and the cones. The 110–125 million **rods** permit *mesopic* and *scotopic* vision (twilight and night vision). They are about 500 times more photosensitive than the cones and contain the photopigment rhodopsin.



Twilight vision decreases after the age of 50, particularly in patients with additional age-related miosis, cataract, and decreased visual acuity. Therefore, glaucoma patients undergoing treatment with miotic agents should be advised of the danger of operating motor vehicles in twilight or at night.

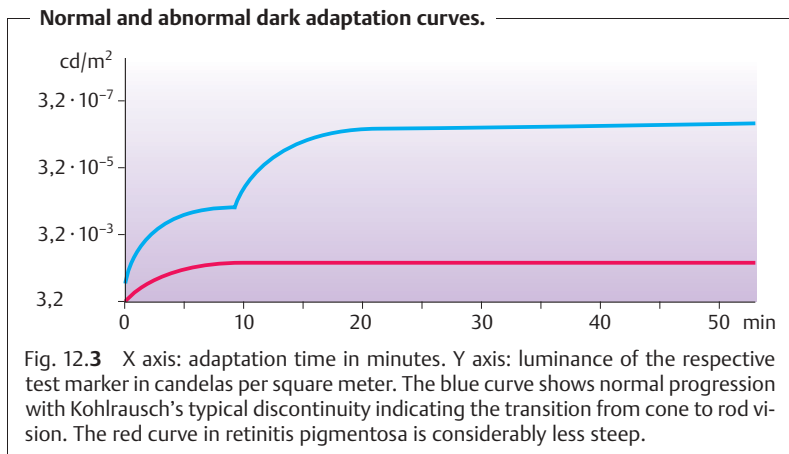
The six to seven million **cones** in the macula are responsible for *photopic* vision (daytime vision), resolution, and color perception. There are **three types of cones**:

- ❖ blue cones,
- ❖ green cones,
- ❖ red cones.

Their photopigments contain the same retinal but different opsins. Beyond a certain **visual field luminance**, a transition from dark adaptation to light adaptation occurs. Luminance refers to the luminous flux per unit solid angle per unit projected area, measured in candelas per square meter (cd/m^2). The cones are responsible for vision up to a luminance of $10 \text{ cd}/\text{m}^2$, the rods up to $0.01 \text{ cd}/\text{m}^2$ (twilight vision is $0.01–10 \text{ cd}/\text{m}^2$; night vision is less than $0.01 \text{ cd}/\text{m}^2$).

Adaptation is the adjustment of the sensitivity of the retina to varying degrees of light intensity. This is done by dilation or contraction of the pupil and shifting between cone and rod vision. In this manner, the human eye is able to see in daylight and at night. In *light adaptation*, the rhodopsin is bleached out so that rod vision is impaired in favor of cone vision. Light adaptation occurs far more quickly than dark adaptation. In *dark adaptation*, the rhodopsin quickly regenerates within five minutes (immediate adaptation), and within 30 minutes to an hour there is a further improvement in night vision (long-term adaptation). An *adaptometer* may be used to determine the light intensity threshold. First the patient is adapted to bright light for 10 minutes. Then the examining room is darkened and the light intensity threshold is measured with light test markers. These measurements can be used to obtain an adaptation curve (Fig. 12.3).

Sensitivity to glare: Glare refers to *disturbing brightness within the visual field sufficiently greater than the luminance to which the eyes are adapted* such as the headlights of oncoming traffic or intense reflected sunlight. Because the retina is adapted to a lesser luminance, vision is impaired in these cases. Often the glare will cause blinking or elicit an eye closing reflex. Sensitivity to glare can be measured with a special device. Patients are shown a series of visual symbols in rapid succession that they must recognize despite intense glare.



The sensitivity to glare or the speed of adaptation and readaptation of the eye is important in determining whether the patient is fit to operate a motor vehicle.

12.2 Examination Methods

Visual Acuity see Chapter 1.

12.2.1 Examination of the Fundus

Direct ophthalmoscopy (Fig. 12.4a; see also Fig. 1.13): A direct ophthalmoscope is positioned close to the patient's eye. The examiner sees a 16-power magnified image of the fundus.

Advantages. The high magnification permits *evaluation of small retinal findings* such as diagnosing retinal microaneurysms. The dial of the ophthalmoscope contains various different plus and minus lenses and can be adjusted as necessary. These lenses compensate for refractive errors in both the patient

Fig. 12.4

a Direct ophthalmoscopy: the examiner sees an erect fundus image of the patient. **b** Indirect ophthalmoscopy: the examiner sees a virtual inverted fundus image. **c** Position of examiner and patient for indirect ophthalmoscopy.



Ophthalmoscopy.

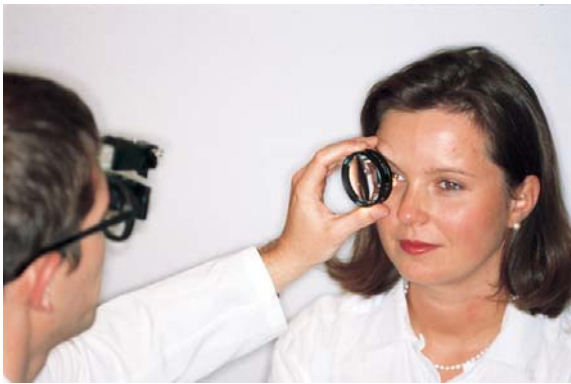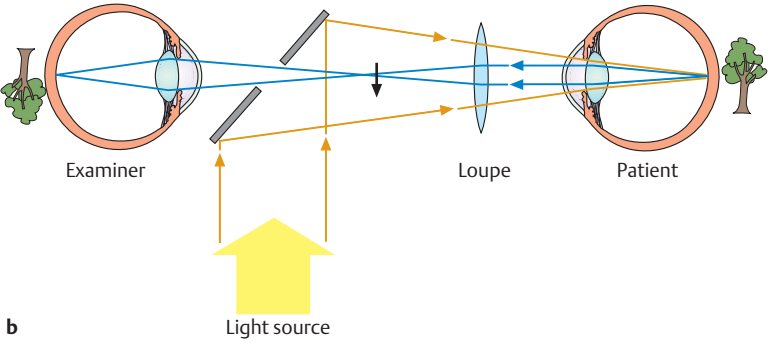
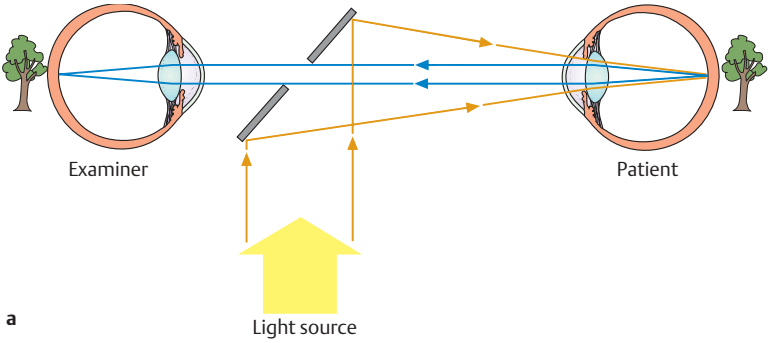


Fig. 12.4



and the examiner. They may also be used to measure the *prominence of retinal changes*, such as the prominence of the optic disk in papilledema or the prominence of a tumor. The base of the lesion is brought into focus first and then the peak of the lesion. A difference of 3 diopters from base to peak corresponds to a prominence of 1 mm. Direct ophthalmoscopy produces an erect image of the fundus, which is significantly easier to work with than an inverted image, and is therefore a suitable technique even for less experienced examiners.

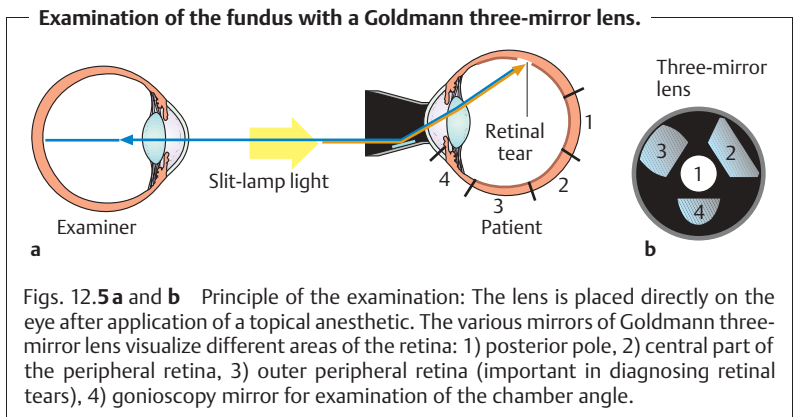
Disadvantages. The image of the fundus is highly magnified but shows *only a small portion of the fundus*. Rotating the ophthalmoscope can only partially compensate for this disadvantage. Direct ophthalmoscopy also produces only a two-dimensional image.

Indirect ophthalmoscopy (Figs. 12.4b and c): A condensing lens (+ 14 to + 30 diopters) is held approximately 13 cm from the patient's eye. The fundus appears in two to six-power magnification; the examiner sees a virtual inverted image of the fundus at the focal point of the loupe. Light sources are available for monocular or binocular examination.

Advantages. This technique provides a good stereoscopic, optimally illuminated overview of the entire fundus in binocular systems.

Disadvantages. Magnification is significantly less than in direct ophthalmoscopy. Indirect ophthalmoscopy requires practice and experience.

Contact lens examination: The fundus may also be examined with a slit lamp when an additional magnifying lens such as a three-mirror lens (see Fig. 12.5) or a 78 to 90 diopter lens is used.





Advantages. This technique produces a highly magnified three-dimensional image yet still provides the examiner with a good overview of the entire fundus. The three-mirror lens also visualizes “blind areas” of the eye such as the angle of the anterior chamber. Contact lens examination combines the advantages of direct ophthalmoscopy and indirect ophthalmoscopy and is therefore the *gold standard* for diagnosing retinal disorders.



Where significant opacification of the optic media (as in a mature cataract) prevents direct visualization of the retina with the techniques mentioned above, the examiner can evaluate the pattern of the retinal vasculature. The sclera is directly illuminated in all four quadrants by moving a light source back and forth directly over the sclera. Patients with intact retinas will be able to perceive the shadow of their own vasculature on the retina (entoptic phenomenon). They will see what looks like “veins of a leaf in autumn”. Patients who are able to perceive this phenomenon have potential retinal vision of at least 20/200.

Ultrasonography: Ultrasound studies are indicated where opacification of the optic media such as cataract or vitreous hemorrhage prevent direct inspection of the fundus or where retinal and choroidal findings are inconclusive. Intraocular tissues vary in how they reflect ultrasonic waves. The retina is highly reflective, whereas the vitreous body is normally nearly anechoic. Ultrasound studies can therefore demonstrate retinal detachment and distinguish it from a change in the vitreous body. Optic disk drusen are also highly reflective. Ultrasound is also helpful in diagnosing intraocular tumors with a prominence of at least 1.5 mm. The specific echogenicity of the tissue also helps to evaluate whether a tumor is malignant, for example in distinguishing a choroidal nevus from a malignant melanoma (Fig. 12.6).



Ultrasound studies can demonstrate retinal detachment where the optic media of the eye are opacified (due to causes such as cataract or vitreous hemorrhage). This is because the retina is highly reflective in contrast to the vitreous body. Ultrasound can also be used to confirm the presence of malignant choroidal processes.

Fundus photography: Abnormal changes can be recorded with a single-lens reflex camera. This permits precise documentation of follow-up findings. Photographs obtained with a fundus camera in green light provide high-contrast images of abnormal changes to the *innermost* layers of the retina such as changes in the layer of optic nerve fibers, bleeding, or microaneurysms.

Fluorescence angiography (with fluorescein or indocyanine green): In fluorescein angiography, 10 ml of 5% fluorescein sodium are injected into one of the patient’s cubital veins. Blue and yellow-green filters are then placed along the optical axis of a single-lens reflex camera. The blue filter ensures that only blue light from the light source reaches the retina. The yellow-green



Ultrasound examination of the fundus.

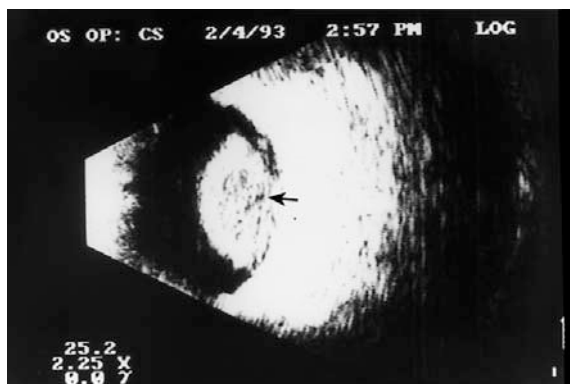

Fig. 12.6 Ultra-sound findings in malignant melanoma (arrow).

filter blocks the blue components of the reflected light so that the camera records only the image of the fluorescent dye (Fig. 12.7).



Fluorescein angiography is used to diagnose vascular retinal disorders such as proliferative diabetic retinopathy, venous occlusion, age-related macular degeneration, and inflammatory retinal processes. Where the blood-retina barrier formed by the zonulae occludentes is disturbed, fluorescein will leak from the retinal vessels. Disorders of the choroid such as choroiditis or tumors can also be diagnosed by this method; in these cases indocyanine is better than fluorescein.

12.2.2 Normal and Abnormal Fundus Findings in General

Normal fundus: The **retina** is normally completely transparent without any intrinsic color. It receives its uniform bright red coloration from the vasculature of the choroid (Fig. 12.8). The **vessels of the choroid** themselves are obscured by the retinal pigment epithelium. *Loss of transparency of the retina* is a sign of an abnormal process (for example in retinal edemas, the retina appears whitish yellow). The **optic disk** is normally a *sharply defined, yellowish orange* structure (in teenagers it is pale pink, and in young children significantly paler) that may exhibit a *central depression* known as the optic or physiologic cup. Light reflection on the inner limiting membrane will normally produce *multiple light reflexes* on the fundus. Teenagers will also exhibit a normal **foveal reflex** and **wall reflex** surrounding the macula, which is caused by the transition from the depression of the macular to the higher level of the retina (Fig. 12.9).



Fluorescein angiography of the fundus.

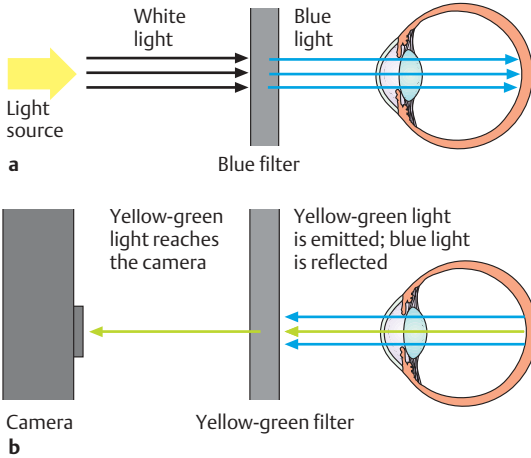


Fig. 12.7 Blue and yellow-green filters are placed along the optical axis of a single-lens reflex camera. **a** First the blue filter ensures that only blue light from the light source reaches the retina. This excites the previously injected fluorescein dye in the vessels of the fundus. **b** The excited fluorescein emits yellow-green light, and the blue light is reflected. The yellow-green filter blocks the blue components of the reflected light so that the camera records only the image of the fluorescent dye.

Normal fundus.

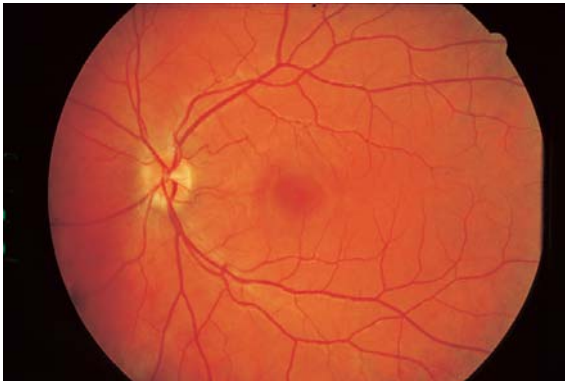

Fig. 12.8 The macula lutea lies about 3–4 mm temporal to and slightly below the optic disk. The fundus receives its uniform bright red coloration from the vessels of the choroid. Venous diameter is normally 1.5 times greater than arterial diameter.

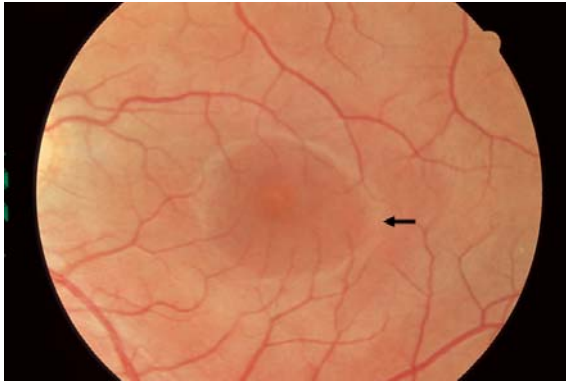
**Wall reflex surrounding the macula.**

Fig. 12.9 Typical highly reflective fundus in a teenager (see wall reflex).

Age-related changes: The **optic** disk turns pale yellow with age, and often the optic cup will become shallow and will be surrounded by a region of choroidal atrophy. The **fundus** will become dull and nonreflective. *Drusen* will be visible in the retinal pigment epithelium and middle peripheral *reticular proliferations of pigment epithelium* will be present. The *arterioles will be elongated* due to loss of elasticity with *irregular filling* due to thickening of the vascular walls. *Meandering of the venules* will be present with *crossing signs*, i.e., the sclerotic artery will be seen to compress the vein at the arteriovenous crossing, reducing the diameter of the column of venous blood. In extreme cases venous blood flow will be cut off completely.

Abnormal changes in the fundus: As a rule, *loss of transparency of the retina* is a sign of an abnormal process. For example in a retinal edema, the retina appears whitish yellow (see Fig. 12.19). A distinctive feature of abnormal retinal and choroidal changes is that the type and appearance of these changes permit precise *topographic localization* of the respective abnormal process when the diagnosis is made. The ophthalmoscopic image will usually allow one to determine in which of the layers shown in Fig. 12.2 the process is occurring. For example, in Fig. 12.27 (nonexudative age-related macular degeneration) one may see that the drusen and atrophy are located in the retinal pigment epithelium; the structures above it are not affected, as is apparent from the intact vascular structures.



12.2.3 Color Vision

Color vision defects may be congenital (especially in men as they are inherited and X-linked recessive) or acquired, for example in macular disorders such as Stargardt's disease. **Qualitative red-green vision defects** are evaluated with pseudoisochromatic plates such as the Ishihara or Stilling-Velhagen plates. They contain numerals or letters composed of small color dots surrounded by confusion colors (Fig. 12.10) that patients with color vision defects cannot read. The Farnsworth-Munsell tests (Fig. 12.11) can detect **blue-yellow color vision defects**.



Pseudoisochromatic plates contain numerals that patients with color vision defects cannot read. In the Farnsworth-Munsell test, patients with a color vision defect cannot sort markers with different hues (according to the colors of the rainbow) in the right order.

The Nagel anomaloscope permits **quantitative evaluation of color vision defects**. The test plate consists of a lower yellow half whose brightness can be adjusted, and an upper half that the patient tries to match to the lower yellow color by mixing red and green. The anomaly ratio is calculated from the final adjustment. Green-blind patients will use too much green, and red-blind patients too much red when mixing the colors.

Perimetry

Ishihara plates for diagnosing red-green vision defects.




Fig. 12.10 Patients with normal color vision will recognize the number 26 on the left and 42 on the right.


**Farnsworth-Munsell test of red-green and blue-yellow color vision defects.**

Fig. 12.11 The patient must sort markers of various hues in the right order according to the colors of the rainbow.

12.2.4 Electrophysiologic Examination Methods

(electroretinogram, electro-oculogram, and visual evoked potentials; see Fig. 12.2a)

Electroretinogram (ERG): This examination method uses electrodes to record the electrical response of the retina to flashes of light (Fig. 12.12a). Photopic (light-adapted) and scotopic (dark-adapted) electroretinograms are obtained. The electroretinogram (ERG) consists of a negative A wave indicating the response of the photoreceptors and a positive B wave primarily indicating the response of the bipolar cells and the supporting cells of Müller (Fig. 12.12b). A flicker ERG (repeated flashes) isolates pure cone response; a pattern ERG (such as a checkerboard) and oscillating potentials can be used to evaluate the inner layers of the retina. The ERG represents a summation response of the retina. A focal ERG can record the response of isolated areas of the retina.



The classic indication for an electroretinogram is retinitis pigmentosa with early loss of scotopic and photopic potentials.

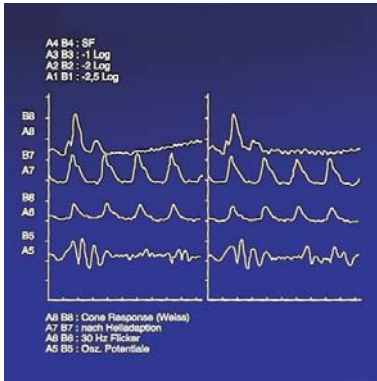
Electro-oculogram (EOG): The electro-oculogram detects abnormal changes in the retinal pigment epithelium such as macular vitelliform dystrophy. This examination method utilizes the dipole of the eye in which the cornea forms the positive pole and the retinal pigment epithelium the negative pole. The standing potential across cornea and retina in comparison to the cornea is measured indirectly with two temporal electrodes (Fig. 12.13). During the measuring process, the patient performs regular eye movements by alternately focusing on two lights. The standing potential is normally higher in the light-adapted eye than in the dark-adapted eye. The ratio of light-adapted



Electroretinogram (ERG).



Fig. 12.12
a Retinal potentials are recorded with a corneal contact lens electrode and skin electrode.



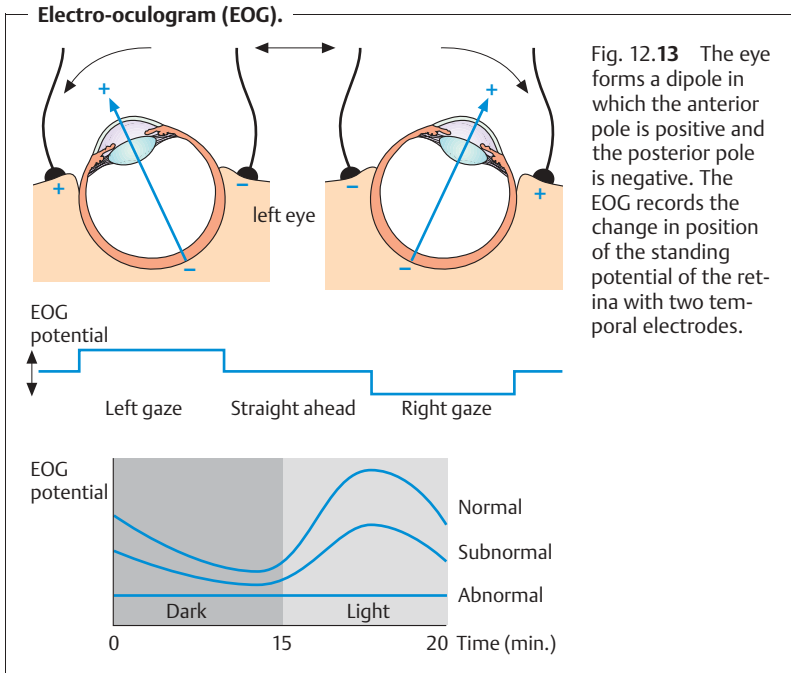
b Normal electroretinogram.

potential to dark-adapted potential (*Arden ratio*) is obtained to evaluate the eye; this ratio is normally greater than 1.8. The ratio will be decreased in the presence of abnormal changes.



The typical indication for an electro-oculogram is macular vitelliform dystrophy (Best's vitelliform dystrophy) with a significantly decreased Arden ratio.

Visual evoked potential (VEP): This examination is used to diagnose damage along the visual pathway. The VEP is not a specific examination of the retina such as an electroretinogram or electro-oculogram. This method is briefly discussed in Chapter 13, Optic Nerve.



12.3 Vascular Disorders

12.3.1 Diabetic Retinopathy

Definition

Diabetic retinopathy is an ocular microangiopathy.

Epidemiology: Diabetic retinopathy is one of the main causes of acquired blindness in the industrialized countries. Approximately 90% of all diabetic patients have retinopathy after twenty years.

Pathogenesis and individual stages of diabetic retinopathy: Diabetes mellitus can lead to changes in almost every ocular tissue. These include symptoms of keratoconjunctivitis sicca, xanthelasma, mycotic orbital infections, transitory refractory changes, cataract, glaucoma, neuropathy of the optic nerve, oculomotor palsy. However, *90% of all visual impairments* in diabetic patients are caused by diabetic retinopathy. The most common international nomenclature used to describe the various changes in diabetic retinopathy



(Table 12.1) is based on the classification of the Diabetic Retinopathy Study. A distinction is made between nonproliferative stages (1. mild, 2. moderate, 3. severe; Fig. 12.14) and proliferative stages (1. non-high-risk 2. high-risk; Fig. 12.15 – 12.17).

Table 12.1 Changes in diabetic retinopathy

Stage of retinopathy	Retinal changes
Nonproliferative diabetic retinopathy	<ul style="list-style-type: none"> ❖ Microaneurysms. ❖ Intraretinal hemorrhages ❖ Lipid deposits in the retina (hard exudates) ❖ Retinal edema ❖ Venous beading ❖ Excessive hemorrhages ❖ Cotton-wool spots (nerve fiber infarctions with soft exudates) ❖ Intraretinal microvascular anomalies
Proliferative diabetic retinopathy	<ul style="list-style-type: none"> ❖ Preretinal neovascularization ❖ Vitreous hemorrhage ❖ Tractional retinal detachment (due to traction of vitreous scarring) ❖ Rubeosis iridis (neovascularization of the iris that can occlude the angle of the anterior chamber; this entails the risk of acute secondary angle closure glaucoma)

Moderate nonproliferative diabetic retinopathy.

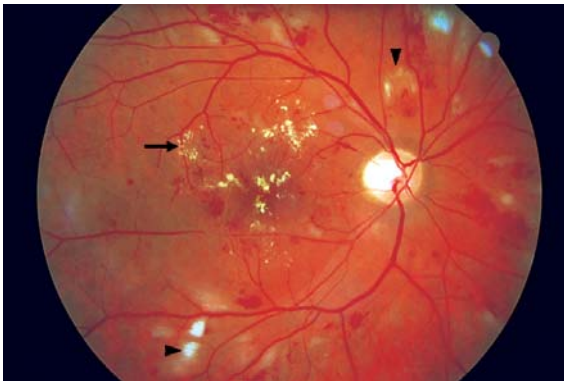


Fig. 12.14 Microaneurysms, intraretinal hemorrhages, hard exudates (arrow), and cotton-wool spots (arrowheads).



Proliferative diabetic retinopathy.

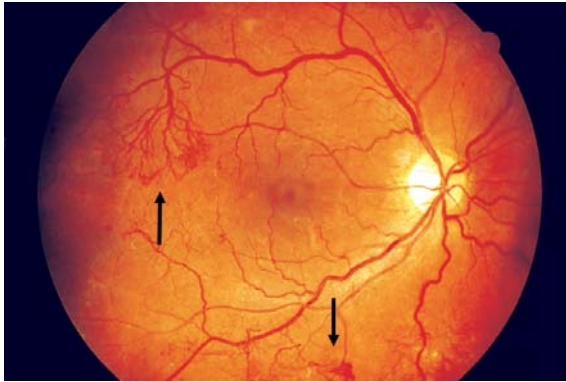
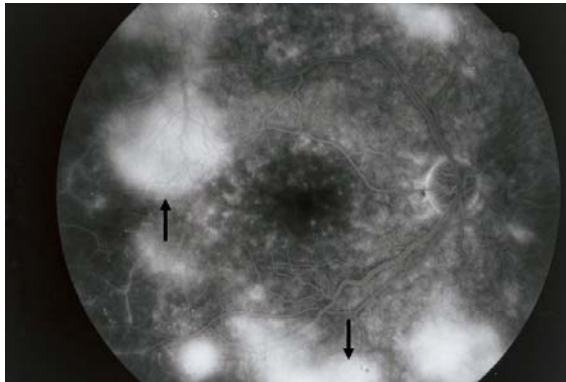


Fig. 12.15
a Preretinal neovascularization (arrows) is a typical sign.



b Corresponding angiographic image. Fluorescein dye leakage is seen in the neovascularized area (arrows).

Symptoms: Diabetic retinopathy remains asymptomatic for a long time. Only in the late stages with macular involvement or vitreous hemorrhage will the patient notice visual impairment or suddenly go blind.

Diagnostic considerations: Diabetic retinopathy and its various stages (see Table 12.1) are diagnosed by stereoscopic examination of the fundus with the pupil dilated. Ophthalmoscopy and evaluation of stereoscopic fundus photographs represent the gold standard. Fluorescein angiography is used to determine if laser treatment is indicated. The presence of rubeosis iridis is confirmed or excluded in slit-lamp examination with a mobile pupil, i.e., without the use of a mydriatic, and by gonioscopy of the angle of the anterior chamber.



High-risk proliferative diabetic retinopathy.

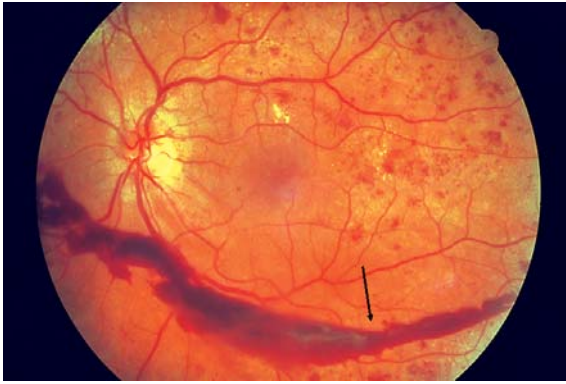

Fig. 12.16 The clearly visible vitreous hemorrhage seen here (arrow) is a typical sign of this stage of diabetic retinopathy. The patient will only notice deterioration of vision in this later stage.

Differential diagnosis: A differential diagnosis must exclude other vascular retinal diseases, primarily hypertensive changes of the fundus (this is done by excluding the underlying disorder).

Treatment: Clinically significant macular edema, i.e., macular edema that threatens vision, is managed with focal laser treatment at the posterior pole. Proliferative diabetic retinopathy is treated with scatter photocoagulation performed in three to five sessions.

Prophylaxis: Failure to perform regular ophthalmologic screening examinations in patients with diabetes mellitus is a negligent omission that exposes patients to the risk of blindness. Therefore, all type II diabetics should undergo ophthalmologic examination upon diagnosis of the disorder, and type I diabetics should undergo ophthalmologic examination within five years of the diagnosis. Thereafter, diabetic patients should undergo ophthalmologic examination once a year, or more often if diabetic retinopathy is present. Pregnant patients should be examined once every trimester.

Clinical course and prognosis: Optimum control of blood glucose can prevent or delay retinopathy. However, diabetic retinopathy can occur despite optimum therapy. Rubeosis iridis (neovascularization in the iris) in proliferative diabetic retinopathy is tantamount to loss of the eye as rubeosis iridis is a relentless and irreversible process.



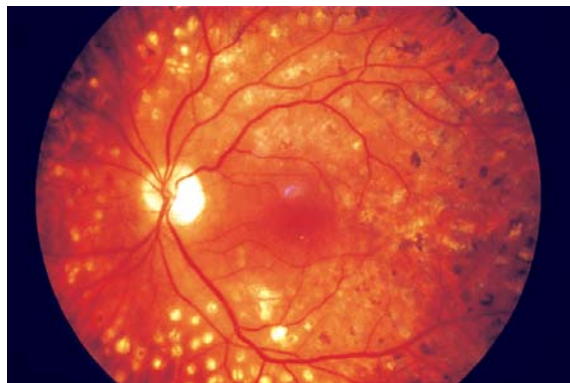
The risk of blindness due to diabetic retinopathy can be reduced by optimum control of blood glucose, regular ophthalmologic examination, and timely therapy, but it cannot be completely eliminated.



Proliferative diabetic retinopathy before and after laser treatment.

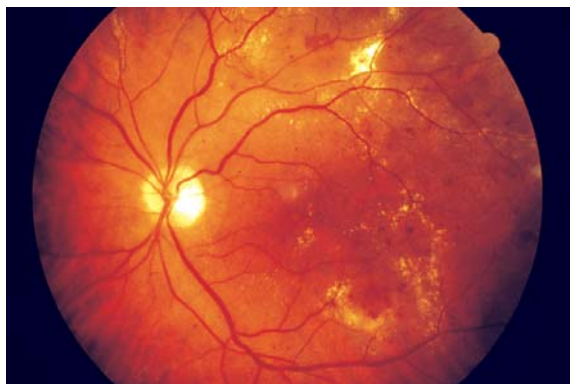

Fig. 12.17
a Proliferative diabetic retinopathy with clinically significant macular edema before laser therapy.



b Findings after successful laser treatment (laser burns appear whitish brown).

12.3.2 Retinal Vein Occlusion

Definition

Vein occlusion occurs as a result of circulatory dysfunction in the central vein or one of its branches.

Epidemiology: Retinal vein occlusion is the second most frequent *vascular* retinal disorder after diabetic retinopathy. The most frequent underlying systemic disorders are arterial hypertension and diabetes mellitus; the most frequent underlying ocular disorder is glaucoma.



Frequent underlying systemic disorders of retinal vein occlusion include arterial hypertension and diabetes mellitus. Frequent underlying ocular disorders include glaucoma and retinal vasculitis.

Etiology: Occlusion of the central vein of the retina or its branches is frequently due to local thrombosis at sites where sclerotic arteries compress the veins. In **central retinal vein occlusion**, the thrombus lies at the level of the lamina cribrosa; in **branch retinal vein occlusion**, it is frequently at an arteriovenous crossing.

Symptoms: Patients only notice a loss of visual acuity if the macula or optic disk are involved.

Diagnostic considerations and findings: Central retinal vein occlusion can be diagnosed where linear or punctiform hemorrhages are seen to occur in all four quadrants of the retina (Fig. 12.18a). Often one will find distended and increasingly meandering veins. In **branch retinal vein occlusion**, intraretinal hemorrhages will occur in the area of vascular supply; this bleeding may occur in only one quadrant (Fig. 12.18b) or in two quadrants (hemispheric vein occlusion). Cotton-wool spots and retinal or optic-disk edema may also be present (simultaneous retinal and optic-disk edema is also possible). Chronic occlusions may also be accompanied by lipid deposits. One differentiates between **non-ischemic** and **ischemic** occlusion depending on the extent of capillary occlusion. Ischemic occlusion is diagnosed with the aid of fluorescein angiography.

Differential diagnosis: Other forms of vascular retinal disease must be excluded, especially diabetic retinopathy. An internist should be consulted to verify or exclude the possible presence of an underlying disorder.

Treatment: In the **acute stage of vein occlusion**, hematocrit should be reduced to 35–38% by hemodilution. Laser treatment is performed in ischemic occlusion that progresses to neovascularization or rubeosis iridis. Focal laser treatment is performed in **branch retinal vein occlusion with macular edema** when visual acuity is reduced to 20/40 or less within three months of occlusion.

Prophylaxis: Early diagnosis and prompt treatment of underlying systemic and ocular disorders is important.

Clinical course and prognosis: Visual acuity improves in approximately one-third of all patients, remains unchanged in one-third, and worsens in one-third despite therapy. Complications include preretinal neovascularization, retinal detachment, and rubeosis iridis with angle closure glaucoma.



Retinal vein occlusion.

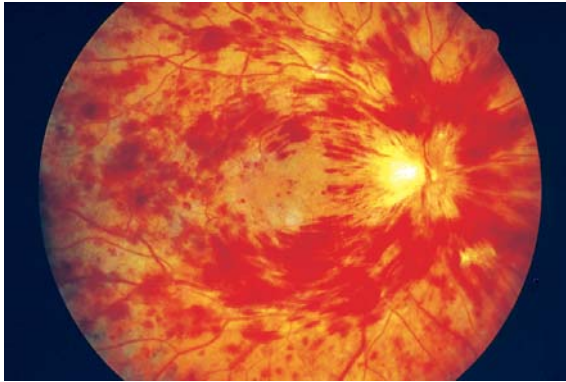
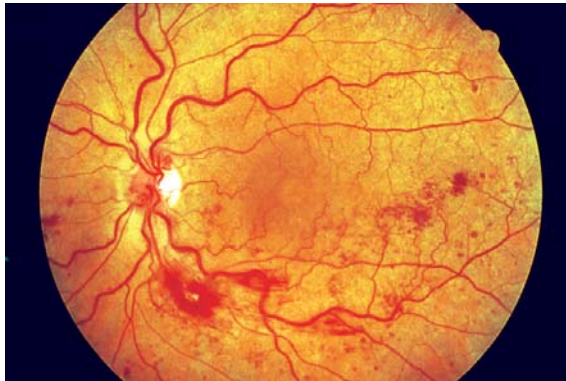

Fig. 12.18
a Central retinal vein occlusion: intraretinal hemorrhages are visible in every retinal quadrant.



b Occlusion of the two main inferior branches. Bleeding occurs only in the affected areas of the retina in branch retinal vein occlusion.

12.3.3 Retinal Arterial Occlusion

Definition

Retinal infarction due to **occlusion of an artery** in the lamina cribrosa or a **branch retinal artery occlusion**.

Epidemiology: Retinal artery occlusions occur significantly less often than vein occlusions.

Etiology: Emboli (Table 12.2) are *frequently* the cause of retinal artery and branch retinal artery occlusions. *Less frequent* causes include inflammatory processes such as temporal arteritis (Horton's arteritis).



Table 12.2 Causes of embolus in retinal artery occlusion

Type of embolus	Source of embolus
Calcium emboli	Atheromatous plaques from the carotid artery or heart valves
Cholesterol emboli	Atheromatous plaques from the carotid artery
Thrombocyte-fibrin emboli (gray)	In atrial fibrillation, myocardial infarction, or due to heart surgery
Myxoma emboli	In atrial myxoma (young patients)
Bacterial or mycotic emboli (Roth spots)	In endocarditis and septicemia

! Horton's arteritis should be excluded where retinal artery occlusion is accompanied by headache.

Symptoms: In **central retinal artery occlusion**, the patient generally complains of *sudden, painless unilateral blindness*. In **branch retinal artery occlusion**, the patient will notice a loss of visual acuity or visual field defects.

Diagnostic considerations: The diagnosis is made by ophthalmoscopy. In the **acute stage of central retinal artery occlusion**, the *retina* appears *grayish white* due to edema of the layer of optic nerve fibers and is *no longer transparent*. Only the *fovea centralis*, which contains no nerve fibers, remains visible as a "*cherry red spot*" because the red of the choroid shows through at this site (Fig. 12.19a). The column of blood will be seen to be interrupted. Rarely one will observe an embolus. Patients with a cilioretinal artery (artery originating from the ciliary arteries instead of the central retinal artery) will exhibit normal perfusion in the area of vascular supply, and their loss of visual acuity will be less. *Atrophy of the optic nerve* will develop in the **chronic stage of central retinal artery occlusion**.

! In the acute stage of central retinal artery occlusion, the fovea centralis appears as cherry red spot on ophthalmoscopy. There is not edema of the layer of optic nerve fibers in this area because the fovea contains no nerve fibers.

In **branch retinal artery occlusion**, a retinal edema will be found in the affected area of vascular supply (Fig. 12.19b). **Perimetry** (visual field testing) will reveal a total visual field defect in central retinal artery occlusion and a partial defect in branch occlusion.

Differential diagnosis: Lipid-storage diseases that can also create a cherry red spot such as Tay-Sachs disease, Niemann-Pick disease, or Gaucher's disease should be excluded. These diseases can be clearly identified on the basis



Retinal artery occlusion.

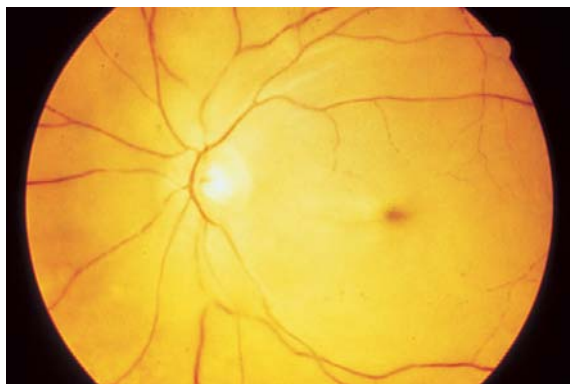
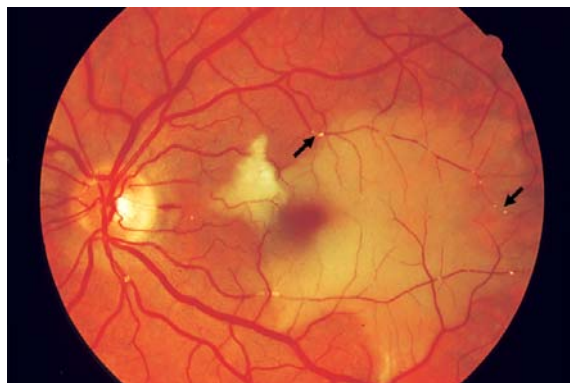
Fig. 12.19
a Central retinal artery occlusion. The paper-thin vessels and extensive retinal edema in which the retina loses its transparency are typical signs. Only the fovea is spared, which appears as a cherry red spot.



b Branch retinal artery occlusion. Multiple emboli are visible in the affected arterial branches (arrows).

of their numerous additional symptoms and the fact that they afflict younger patients.

Treatment: Emergency treatment is often unsuccessful even when initiated immediately. Ocular massage, medications that reduce intraocular pressure, or paracentesis are applied in an attempt to drain the embolus in a peripheral retinal vessel. Calcium antagonists or hemodilution are applied in an attempt to improve vascular supply. Lysis therapy is no longer performed due to the poor prognosis (it is not able to prevent blindness) and the risk to vital tissue involved.

Prophylaxis: Excluding or initiating prompt therapy of predisposing underlying systemic disorders is crucial (see Table 12.2).



Clinical course and prognosis: The prognosis is poor because *irreparable damage* to the inner layers of the retina occurs *within one hour*. Blindness usually cannot be prevented in central retinal artery occlusion. The prognosis is better where only a branch of the artery is occluded unless a macular branch is affected.

12.3.4 Hypertensive Retinopathy and Sclerotic Changes

Definition

Arterial changes in hypertension are primarily caused by vasospasm; in arteriosclerosis they are the result of thickening of the wall of the arteriole.

Epidemiology: Arterial hypertension in particular figures prominently in clinical settings.



Vascular changes due to arterial hypertension are the most frequent cause of retinal vein occlusion.

Pathogenesis: High blood pressure can cause breakdown of the blood-retina barrier or obliteration of capillaries. This results in intraretinal bleeding, cotton-wool spots, retinal edema, or swelling of the optic disk.

Symptoms: Patients with high blood pressure frequently suffer from headache or eye pain. Impaired vision or loss of visual acuity only occurs in stage III or IV hypertensive vascular changes. Arteriosclerosis does not exhibit any ocular symptoms.

Diagnostic considerations: Hypertensive and arteriosclerotic changes in the fundus are diagnosed by ophthalmoscopy, preferably with the pupil dilated (Tables 12.3 and 12.4). Changes in the retinal vasculature are frequent findings; choroidal infarctions are rare in acute hypertension (Elschnig's spots: circumscribed atrophy and proliferation of pigment epithelium in the infarcted area).

Differential diagnosis: Ophthalmoscopy should be performed to exclude other vascular retinal disorders such as diabetic retinopathy. Diabetic retinopathy is primarily characterized by parenchymal and vascular changes; a differential diagnosis is made by confirming or excluding the systemic underlying disorder.

Treatment: Treating the underlying disorder is crucial where fundus changes due to arterial retinopathy are present. Blood pressure should be reduced to below 140/90 mm Hg. Fundus changes due to arteriosclerosis are untreatable.

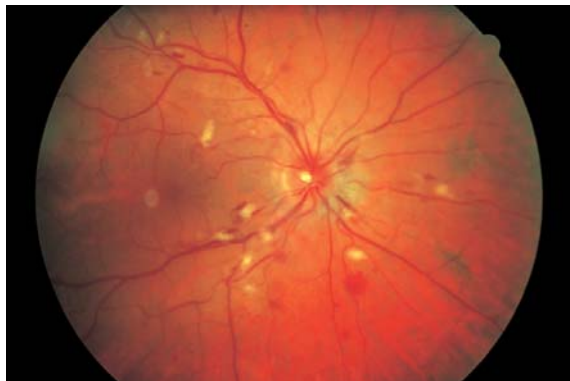
**Table 12.3** Stages of hypertensive vascular changes (as described by Keith, Wagener, and Barker)

Stage	Characteristics
Stage I:	Constricted, tortuous arterioles.
Stage II:	Severe vascular constriction and Gunn's crossing sign. The column of venous blood is constricted by the sclerotic artery at an arteriovenous crossing.
Stage III:	Retinal hemorrhages, hard exudates, cotton-wool spots, retinal edema (Fig. 12.20)
Stage IV:	Papilledema

The WHO distinguishes between hypertensive retinopathy (stages I and II) and malignant hypertensive retinopathy (stages III and IV)

Table 12.4 Stages of arteriosclerotic vascular changes (as described by Scheie)

Stage	Characteristics
Stage I:	Widening of arteriole reflexes
Stage II:	Arteriovenous crossing sign
Stage III:	Copper-wire arteries (copper colored arterial reflex)
Stage IV:	Silver-wire arteries (silver colored arterial reflex)

Hypertensive retinopathy (Stage III).**Fig. 12.20** Typical findings in this stage include hemorrhages (here readily visible) and cotton-wool spots.



Prophylaxis: Regular blood pressure monitoring and ophthalmoscopic examination of the fundus are required to minimize the risk of complications (see below).

Clinical course and complications: Sequelae of arteriosclerotic and hypertensive vascular changes include retinal artery and vein occlusion and the formation of macroaneurysms that can lead to vitreous hemorrhage. In the presence of papilledema, the subsequent atrophy of the optic nerve can produce lasting and occasionally severe loss of visual acuity.

Prognosis: In some cases, the complications described above are unavoidable despite well controlled blood pressure.

12.3.5 Coats' Disease

Definition

Congenital retinal telangiectasia with vascular anomalies that nearly always presents *unilaterally* and can lead to exudation and eventually to exudative retinal detachment.

Epidemiology: This rare disorder manifests itself in young children and teenagers. Boys are usually affected (in about 90% of all cases).



Coats' disease usually occurs in young and teenage boys. It is nearly always unilateral.

Pathogenesis: Telangiectasia and aneurysms lead to exudation and eventually to retinal detachment.

Symptoms: The early stages are characterized by loss of visual acuity, the later stages by leukocoria (white pupil; see Fig. 12.36) or unilateral strabismus, although the combination of leukocoria *and* strabismus is also possible.

Diagnostic considerations and findings: Ophthalmoscopy will reveal telangiectasia, subretinal whitish exudate with exudative retinal detachment and hemorrhages (Fig. 12.21).

Differential diagnosis: In the advanced stages of the disorder, retinoblastoma should be excluded by ophthalmoscopy and retinopathy of prematurity on the basis of the patient's history. Both disorders may also cause leukocoria.

Treatment: The treatment of choice is laser photocoagulation or cryotherapy to destroy anomalous vasculature.



Coats' disease.

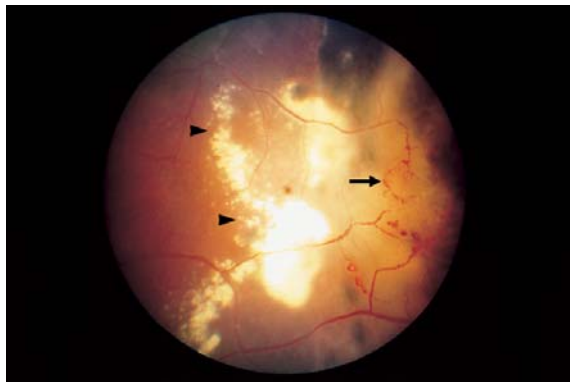


Fig. 12.21 Typical vascular changes of telangiectasia (arrow) accompanied by exudative retinal detachment with numerous lipid deposits (arrowheads).

Prognosis: Left untreated, the disease will eventually cause blindness due to total retinal detachment. Treatment is effective in preventing blindness in about 50% of all patients.

12.3.6 Retinopathy of Prematurity

Definition

A retinal disorder attributable to disruption of normal development of the retinal vasculature in preterm infants with birth weight less than 2500 g.

Epidemiology: The disorder is rare. Infants with birth weight below 1000 g are at increased risk of developing the disorder. Retinopathy of prematurity is not always preventable despite optimum care and strict monitoring of partial pressure of oxygen.

Etiology: Preterm birth and exposure to oxygen disturbs the normal development of the retinal vasculature. Vessel obliteration occurs, followed by proliferative neovascularization. This results in vitreous hemorrhage, retinal detachment, and, in the late scarring stage, retrolenticular fibroplasia as vessels and connective tissue fuse with the detached retina.

Findings and symptoms: After an initially asymptomatic clinical course, vitreous hemorrhage or retinal detachment will be accompanied by secondary strabismus. Leukocoria can occur in the retrolenticular fibroplasia stage. Table 12.5 shows the classification of the various stages.



Table 12.5 Classification of retinopathy of prematurity

Stage	Characteristics
Stage I:	Demarcation (border between vascularized and nonvascularized retina)
Stage II:	Formation of a ridge (development of intraretinal proliferative tissue)
Stage III:	Ridge with extraretinal proliferation
Stage IV:	Subtotal retinal detachment
Stage V:	Total retinal detachment

As is customary in ophthalmology, the extent of the respective abnormal change is specified by analogy to a clock face. For example a demarcation line may be said to extend from one to six o'clock. A plus stage includes dilated and tortuous vasculature of the posterior pole in addition to the other changes.

Diagnostic considerations: The retina should be examined with the pupil dilated four weeks after birth at the latest. This may be done as part of the routine examination of the newborn. Follow-up examinations will depend on the degree of retinal vascularization.

Differential diagnosis: Other causes of leukocoria such as retinoblastoma or cataract (see Table 11.1) should be considered.

Treatment: Surgery is rarely successful in stages IV and V. In stage III, laser photocoagulation or cryotherapy is performed in the nonvascularized portion of the retina.

Prophylaxis: Partial pressure of oxygen should be kept as low as possible, and ophthalmologic screening examinations should be performed.



Early detection of retinopathy of prematurity is particularly important.

Clinical course and prognosis: Stage I and II retinopathy resolves spontaneously in 85% of all affected children.



12.4 Degenerative Retinal Disorders

12.4.1 Retinal Detachment

Definition

Retinal detachment refers to the separation of the neurosensory retina (see Fig. 12.2a) from the underlying retinal pigment epithelium, to which normally it is loosely attached. This can be classified into four types:

- ❖ **Rhegmatogenous** retinal detachment results from a tear, i.e., a break in the retina.
- ❖ **Tractional** retinal detachment results from traction, i.e., from vitreous strands that exert tensile forces on the retina (see proliferative vitreoretinopathy and complicated retinal detachment).
- ❖ **Exudative** retinal detachment is caused by fluid. Blood, lipids, or serous fluid accumulates between the neurosensory retina and the retinal pigment epithelium. Coats' disease is a typical example.
- ❖ **Tumor-related** retinal detachment.

Primary retinal detachment usually results from a tear. In rare cases, **secondary retinal detachment** may also result from a tear due to other disorders or injuries. Combinations of both are also possible but rare. Proliferative vitreoretinopathy frequently develops from a chronic retinal detachment (see Chapter 11, Vitreous Body).

Epidemiology: Although retinal detachments are relatively rarely encountered in ophthalmologic practice, they are clinically highly significant as they can lead to blindness if not treated immediately.

Rhegmatogenous retinal detachment (most frequent form): Approximately 7% of all adults have retinal breaks. The incidence of this finding increases with *advanced age*. The peak incidence is between the fifth and seventh decades of life. This indicates the significance of posterior vitreous detachment (separation of the vitreous body from inner surface of the retina; also age-related) as a cause of retinal detachment. The annual incidence of retinal detachment is one per 10 000 persons; the prevalence is about 0.4% in the elderly. There is a known familial disposition, and retinal detachment also occurs in conjunction with *myopia*. The prevalence of retinal detachment with emmetropia (normal vision) is 0.2% compared with 7% in the presence of severe myopia exceeding minus 10 diopters.

Exudative, tractional, and tumor-related retinal detachments are encountered far less frequently.

Etiology: Rhegmatogenous retinal detachment. This disorder develops from an *existing break in the retina*. Usually this break is in the peripheral retina, rarely in the macula (Fig. 12.22). Two types of breaks are distinguished:



Horseshoe tear (arrow) and retinal detachment (whitish retina).

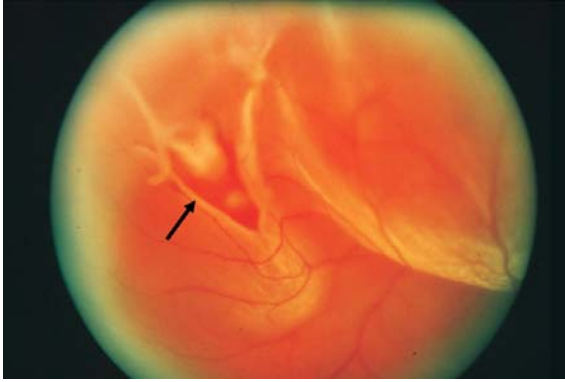


Fig. 12.22 The image shows a typical reddish horseshoe tear in the retina (arrow) with bullous retinal detachment.

- ❖ **Round breaks:** A portion of the retina has been completely torn out due to a posterior vitreous detachment.

- ❖ **Horseshoe tears:** The retina is only slightly torn.

Not every retinal break leads to retinal detachment. This will occur only where the liquified vitreous body separates, and vitreous humor penetrates beneath the retina through the tear. The retinal detachment occurs when the forces of adhesion can no longer withstand this process. Tractional forces (tensile forces) of the vitreous body (usually vitreous strands) can also cause retinal detachment with or without synchysis. In this and every other type of retinal detachment, there is a *dynamic interplay of tractional and adhesive forces*. Whether the retina will detach depends on which of these forces is stronger.

Tractional retinal detachment. This develops from the tensile forces exerted on the retina by preretinal fibrovascular strands (see proliferative vitreoretinopathy) especially in proliferative retinal diseases such as diabetic retinopathy.

Exudative retinal detachment. The primary cause of this type is the breakdown of the inner or outer blood – retina barrier, usually as a result of a vascular disorder such as Coats' disease. Subretinal fluid with or without hard exudate accumulates between the neurosensory retina and the retinal pigment epithelium.

Tumor-related retinal detachment. Either the transudate from the tumor vasculature or the mass of the tumor separates the retina from its underlying tissue.



Symptoms: Retinal detachment can remain asymptomatic for a long time. In the stage of acute posterior vitreous detachment, the patient will notice **flashes of light** (photopsia) and **floaters**, black points that move with the patient's gaze. A posterior vitreous detachment that causes a retinal tear may also cause avulsion of a retinal vessel. Blood from this vessel will then enter the vitreous body. The patient will perceive this as "**black rain**," numerous slowly falling small black dots. Another symptom is a **dark shadow in the visual field**. This occurs when the retina detaches. The patient will perceive a falling curtain or a rising wall, depending on whether the detachment is superior or inferior. A break in the center of the retina will result in a sudden and significant **loss of visual acuity**, which will include metamorphopsia (image distortion) if the macula is involved.

Diagnostic considerations: The lesion is diagnosed by stereoscopic examination of the fundus with the pupil dilated. The detached retina will be white and edematous and will lose its transparency. Ophthalmoscopy will reveal a bullous retinal detachment; in **rhegmatogenous retinal detachment**, a bright red retinal break will also be visible (see Fig. 12.22). The tears in rhegmatogenous retinal detachment usually occur in the superior half of the retina in a region of equatorial degeneration. In **tractional retinal detachment**, the bullous detachment will be accompanied by preretinal gray strands. In **exudative retinal detachment**, one will observe the typical picture of serous detachment; the exudative retinal detachment will generally be accompanied by massive fatty deposits and often by intraretinal bleeding.

The **tumor-related retinal detachment** (as can occur with a malignant melanoma) either leads to secondary retinal detachment over the tumor or at some distance from the tumor in the inferior peripheral retina. Ultrasound studies can help confirm the diagnosis where retinal findings are equivocal or a tumor is suspected.



An inferior retinal detachment at some distance from the tumor is a sign that the tumor is malignant.

Differential diagnosis: Degenerative **retinoschisis** is the primary disorder that should be excluded as it can also involve rhegmatogenous retinal detachments in rare cases. A retinal detachment may also be confused with a choroidal detachment. Fluid accumulation in the choroid, due to inflammatory choroidal disorders such as Vogt-Koyanagi-Harada syndrome, causes the retinal pigment epithelium and neurosensory retina to bulge outward. These forms of retinal detachment have a greenish dark brown color in contrast to the other forms of retinal detachment discussed here.

Treatment: Retinal breaks with minimal circular retinal detachment can be treated with **argon laser coagulation** (Fig. 12.23). The retina surrounding the break is fused to the underlying tissue whereas the break itself is left open. The scars resulting from argon laser therapy are sufficient to prevent any

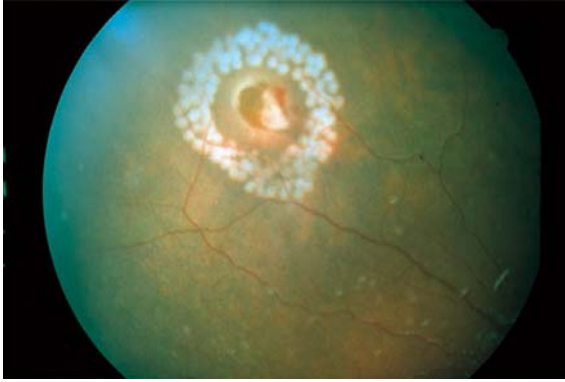

Retinal break immediately after argon laser photocoagulation.


Fig. 12.23
Circular white laser burns are visible around the break.

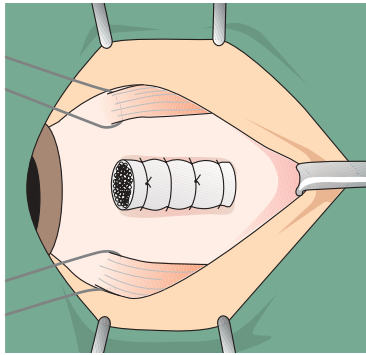
further retinal detachment. More extensive retinal detachments are usually treated with a **retinal tamponade with an elastic silicone sponge** that is sutured to the outer surface of the sclera, a so-called budding procedure (Fig. 12.24a – c). It can be sutured either in a radial position (perpendicular to the limbus) or parallel to the limbus. This indents the wall of the globe at the retinal break and brings the portion of the retina in which the break is located back into contact with the retinal pigment epithelium. The indentation also reduces the traction of the vitreous body on the retina. An **artificial scar** is created to stabilize the restored contact between the neurosensory retina and retinal pigment epithelium. This is achieved with a cryoprobe. After a successful operation, this scar prevents recurring retinal detachment. Where there are several retinal breaks or the break cannot be located, a **silicone cerclage** is applied to the globe as a circumferential buckling procedure. The procedures described up until now apply to *uncomplicated retinal detachments*, i.e., without proliferative vitreoretinopathy. Suturing a retinal tamponade with silicone sponge may also be attempted initially in a *complicated retinal detachment* with proliferative vitreoretinopathy. If this treatment is unsuccessful, the vitreoretinal proliferations are excised, and a **vitrectomy is performed** in which the vitreous body is replaced with Ringer's solution, gas, or silicone oil. These fluids tamponade the eye from within.

Prophylaxis: High-risk patients above the age of 40 with a positive family history and severe myopia should be regularly examined by an ophthalmologist, preferably once a year.

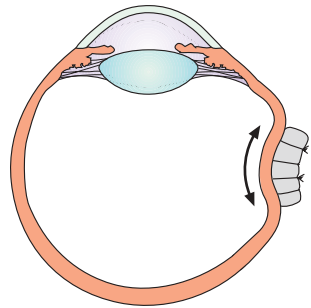
Clinical course and prognosis: About 95% of **rhegmatogenous retinal detachments** can be treated successfully with surgery. Where there has been



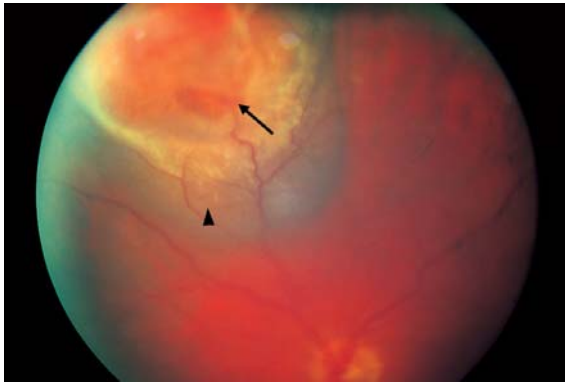
Reattaching a detached retina with a silicone sponge tamponade.



a



b



c

Fig. 12.24 a The ocular muscles are retracted and the eye is brought into the proper position for the operation. The tamponade is sutured to the outer surface of the sclera. b Cross section of the eye with the tamponade in place: The globe is indented at the site of the tamponade. c Wedged beneath the horseshoe tear (arrow) is a radial tamponade (arrowhead). The retina is again in contact with the underlying tissue.



macular involvement (i.e., the initial detachment included the macula), a loss of visual acuity will remain. The prognosis for the **other forms of retinal detachment** is usually poor, and they are often associated with significant loss of visual acuity.

12.4.2 Degenerative Retinoschisis

Definition

A frequently bilateral split in an inner and outer layer of the retina. The split is usually at the level of the outer plexiform layer (Fig. 12.25).

Epidemiology: About 25% of all people have retinoschisis. The tendency increases with age.

Pathogenesis: Idiopathic retinal splitting occurs, usually in the outer plexiform layer.

Symptoms: Retinoschisis is *primarily asymptomatic*. The patient will usually notice a reduction of visual acuity and see shadows only when the retinal split is severe and extends to the posterior pole.

Diagnostic considerations: Ophthalmoscopic examination will reveal bullous separation of the split inner layer of the retina. The inner surface has the appearance of hammered metal. Rarely breaks will occur in the inner and outer retinal layers.

Retinoschisis.

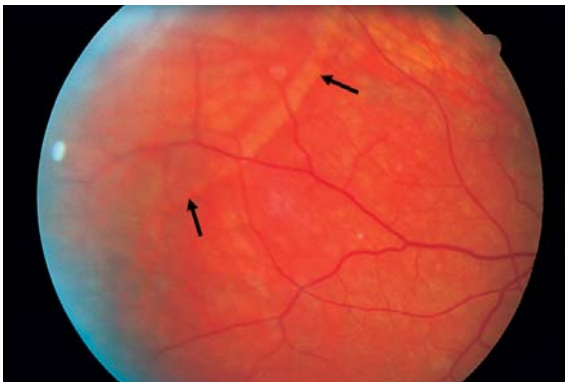


Fig. 12.25 Split in the retina with bullous separation of the inner layers of the retina (arrows).



Differential diagnosis: *Rhegmatogenous retinal detachment* should be excluded. Ophthalmoscopy will reveal a continuous break in the retina in a retinal detachment, and the retina will not appear as transparent as in retinoschisis. However, retinal breaks can also occur in retinoschisis. In the inner layer of the retina, these breaks will be very small and hardly discernible. In the outer layer, they will be very large. Complete rhegmatogenous retinal detachment can occur in retinoschisis only where there is a break in both layers.

Treatment: Usually no treatment is required. The rare cases in which retinal detachment occurs are treated surgically using the standard procedures for retinal detachment.



Degenerative retinoschisis differs from retinal detachment in that it usually requires no treatment.

Clinical course and prognosis: The prognosis for degenerative retinoschisis is very good. Progressive retinal splitting or retinal detachment with a subsequent reduction in visual acuity is rare.

12.4.3 Peripheral Retinal Degenerations

Definition

Peripheral retinal degenerations refer to degenerative changes that lie parallel to the ora serrata in the peripheral portions of the retina. These include two basic types:

- ❖ **Harmless retinal changes** such as pars plana cysts of the posterior ciliary body or peripheral chorioretinal atrophy (cobblestone degeneration).
- ❖ **Precursors of retinal detachment** such as local thinning of the retina referred to as snail track or lattice degeneration.

Epidemiology: The prevalence of the lesions is 6–10%.

Pathogenesis: Unknown.

Symptoms: Peripheral retinal degenerations are asymptomatic.

Diagnostic considerations: The diagnosis is made by ophthalmoscopic examination of the peripheral retina with the pupil dilated. The retina may be examined by indirect binocular ophthalmoscopy or using a three-mirror lens.

Cobblestone degenerations appear as whitish sharply defined localized areas of extensive atrophy of the retina, pigment epithelium, and choriocapillaris that lie between the ora serrata and the equator. **Snail track degeneration** presents with yellowish, whitish radiant dots consisting of microglia and astrocytes. **Lattice degeneration** presents with thinned retinal areas with whitish sclerotic vessels. This results in reactive focal atrophy and hypertro-



phy of the retinal pigment epithelium in the region of equatorial degeneration and liquefaction of the overlying vitreous body.

Differential diagnosis: The findings are highly characteristic and easily diagnosed clinically. Rarely, vascular processes or inflammatory changes and scars from other causes must be considered in a differential diagnosis.

Treatment: Treatment is either not required or not recommended as laser therapy does not reduce the risk of retinal detachment. Ophthalmoscopic follow-up examinations should be performed at regular intervals.

Prophylaxis: No prophylaxis is possible.

Clinical course and prognosis: The clinical course is usually benign. Round atrophic retinal breaks can develop in the areas of snail track and lattice degeneration. However, the long-term risk of retinal detachment is only 1%.

12.4.4 Central Serous Chorioretinopathy

Definition

Serous detachment of the retina and/or retinal pigment epithelium.

Etiology: Serous detachment occurs through a defect in the outer blood – retina barrier (“tight junctions” in the retinal pigment epithelium). Local factors that may be related to *physical or psychological stress* are presumably involved.

Epidemiology: The disorder primarily affects men in the third and fourth decade of life.

Symptoms: Patients present with a loss of visual acuity, a relative central scotoma (dark spot), image distortion (metamorphopsia), or perception of objects as larger or smaller than they are (macropsia or micropsia).

Diagnostic considerations: **Ophthalmoscopy** will reveal a serous retinal detachment, usually at the macula. In chronic cases, a fine brown and white pigment epithelial scar will develop at the site of the fluid effusion. Swelling in the central retina shortens the visual axis and produces hyperopia. The site of fluid effusion can be identified during the active phase with the aid of **fluorescein angiography** (Fig. 12.26 a and b).

Treatment: Usually no treatment is required for the **first occurrence** of the disorder. Retinal swelling resolves spontaneously within a few weeks. **Recurrences** may be treated with laser therapy provided the site of fluid effusion lies outside the fovea centralis. Corticosteroid therapy is contraindicated as the therapy itself can lead to development of central serous chorioretinopathy in rare cases.



Central serous chorioretinopathy.

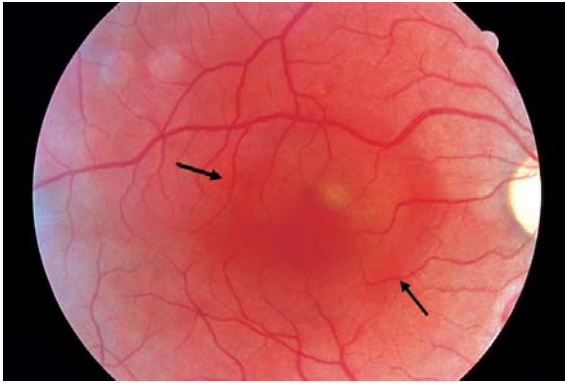
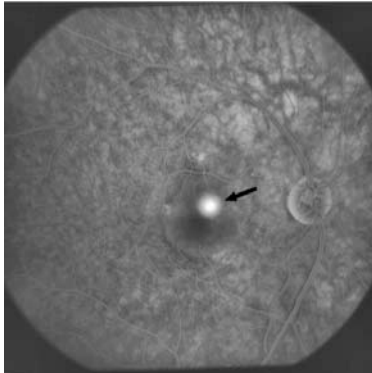


Fig. 12.26
a Bullous fluid accumulation beneath the retina (arrows).



b Angiogram of the same patient. The site of fluid effusion appears as a hyperfluorescent spot (arrow).

Clinical course and prognosis: The prognosis is usually good. However, recurrences or chronic forms can lead to a permanent loss of visual acuity.



Local stress-related factors and steroids can lead to macular edema in predisposed patients.



12.4.5 Age-Related Macular Degeneration

Definition

Progressive degeneration of the macula in elderly patients.

Epidemiology: Age-related macular degeneration is the most frequent cause of blindness beyond the age of 65 years.

Pathogenesis: Drusen develop in the retinal pigment epithelium due to accumulation of metabolic products.

Symptoms: Patients notice a *gradual* loss of visual acuity. Where macular edema is present, patients complain of image distortion (metamorphopsia), macropsia, or micropsia.

Findings and diagnostic considerations: Ophthalmoscopic examination can distinguish two separate stages that occur in chronological order (Table 12.6).

Differential diagnosis: Other vascular diseases of the retina such as branch retinal vein occlusion should be excluded by ophthalmoscopy. Malignant melanoma should be excluded by ultrasound studies.

Treatment: No reliably effective medical therapy is available. Laser therapy may be performed in the exudative stage in about 5–10% of all patients without neovascularization involving the fovea centralis. Use of progressively stronger near vision aids such as a hand magnifier or binocular magnifier should be tried.

Clinical course and prognosis: The course of the disorder is chronic and leads to progressive loss of visual acuity.



Laser therapy may be performed in the exudative stage of late age-related macular degeneration in 10% of all patients provided the disorder is diagnosed early.

Table 12.6 Stages of age-related macular degeneration (ARM)

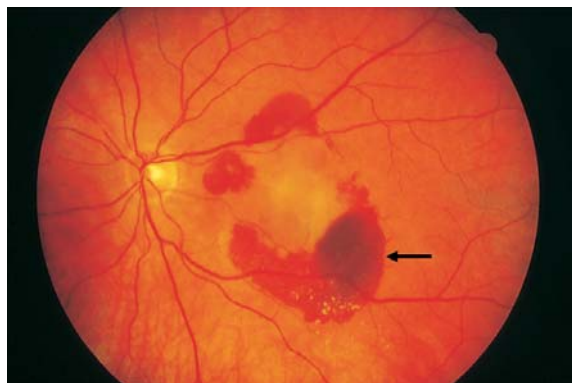
Stage	Characteristics
1. Early ARM:	Drusen, atrophy, and proliferation of retinal pigment epithelium (< 175 μm)
2. Late ARM:	Geographic atrophy (Fig. 12.27 a) of the retinal pigment epithelium. Serous detachment of the retina and/or retinal pigment epithelium; hemorrhages (Fig. 12.27 b). Fibrous scar (Fig. 12.27 c)



Stages of late age-related macular degeneration.

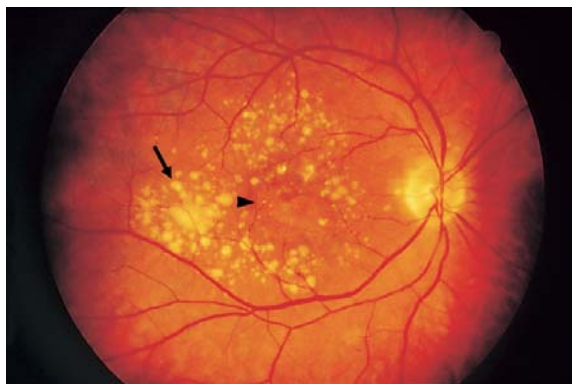

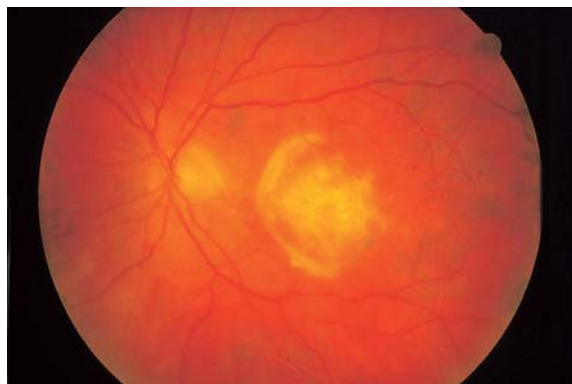Fig. 12.27
a Late age-related macular degeneration: Typical signs include drusen (arrow) and geographically central atrophy (arrowhead).



b Late age-related macular degeneration: Intraretinal bleeding (arrow) is a typical sign.



c Late age-related macular degeneration: The fibrous scar is a typical sign.



12.4.6 Degenerative Myopia

Definition

The fundus in degenerative myopia is characterized by abnormal chorioretinal atrophy.

Epidemiology: Chorioretinal atrophy due to myopia is rare.

Pathogenesis: The atrophy usually occurs in the presence of severe myopia exceeding minus 6 diopters. The causes include stretching changes in the retina, choroid, and Bruch's membrane due to the elongated globe in axial myopia.

Symptoms: Loss of visual acuity occurs where there is macular involvement.

Findings and diagnostic considerations: Typical signs include chorioretinal atrophy around the optic disk and at the posterior pole and defects in Bruch's membrane known as lacquer cracks (Fig. 12.28). These cracks can provide openings for vascular infiltration with resulting subretinal neovascularization that can lead to retinal edema and bleeding (Fuchs' black spot). The final stage of the disorder is characterized by a diskiform scar. The diagnosis is made by ophthalmoscopy. Fluorescein angiography is indicated where subretinal neovascularization is suspected.

Differential diagnosis: Choroidal scars and angioid streaks (breaks in Bruch's membrane) in pseudoxanthoma elasticum must be excluded by ophthalmoscopy. The diagnosis is unequivocal where myopia is present.

Degenerative myopia.

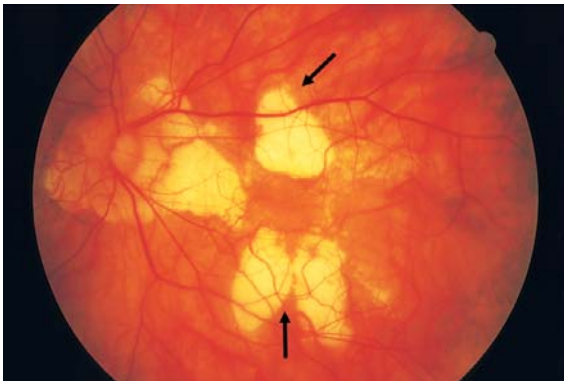


Fig. 12.28
Extensive areas of
chorioretinal
atrophy (arrows).



Treatment: The causes of the disorder cannot be treated. It is important to correct myopia optimally with eyeglasses or contact lenses to avoid fostering progression of the disorder. Subretinal neovascularization outside the fovea or close to its border can be treated by laser photocoagulation.

Clinical course and prognosis: Chronic progressive myopia will result in increasing loss of visual acuity. The prognosis for subretinal neovascularization is poor. The incidence of retinal detachment is higher in myopic eyes.

12.5 Retinal Dystrophies

12.5.1 Macular Dystrophies

Definition

Macular dystrophies are disorders of the macula that usually occur bilaterally and manifest themselves between the ages of 10 and 30.

12.5.1.1 Stargardt's Disease

Definition

This is a macular dystrophy that proceeds from the retinal pigment epithelium.

Inheritance: Autosomal recessive disorder.

Epidemiology: Stargardt's disease is rare.

Symptoms: Progressive loss of visual acuity occurs between the ages of 10 and 20 years.

Findings and diagnostic considerations: Initial findings are slight white "fleck" lesions in the macular region (Fig. 12.29), which may occur in combination with lesions in the entire fundus (*fundus flavimaculatus*). The electroretinogram and electro-oculogram will be normal or reduced. In the later stage, the white lesions significantly increase in size and number. This will not necessarily be reflected in the ERG or EOG.

Differential diagnosis: Other disorders involving white "fleck" lesions such as inherited autosomal dominant drusen must be excluded by ophthalmoscopy. The diagnosis is confirmed by fluorescein angiography. Blockage of the choroidal fluorescein is a characteristic feature of Stargardt's disease.

Treatment: No treatment is available. Edge-filtered eyeglasses and magnifying near vision aids can help make better use of the patient's remaining vision.



Stargardt's disease.

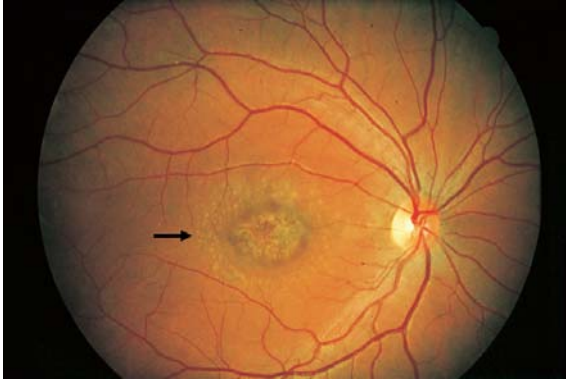


Fig. 12.29
Typical “fleck” lesions of the retina (arrow) and extensive atrophy of the pigment epithelium in the macular region.

Prophylaxis: No prophylaxis is possible. Examination of siblings and genetic counseling are indicated.

Clinical course and prognosis: The disorder is chronically progressive. Vision in the final stages is usually 0.1 (20/200) or less.

12.5.1.2 Best's Vitelliform Dystrophy

Epidemiology: The disorder is rare, with an incidence similar to Stargardt's disease.

Inheritance: The disorder is inherited as an autosomal dominant trait with variable penetrance and expressivity. The gene locus is on chromosome 11 (11q13).

Symptoms: Clinical manifestation occurs between the ages of 5 and 15 years. Initially there is a subjectively slight decrease in visual acuity. In the later stages of the disorder, vision is reduced to about 20/200.

Findings and diagnostic considerations: A typical feature of this form of macular dystrophy is that *visual acuity is negligibly diminished at the onset of the disorder*. However, the *morphologic findings are remarkable*. Ophthalmoscopy will reveal yellowish round vitelliform lesions in the macular region (Fig. 12.30) that look like the yolk of a fried egg. (The Latin word *vitellus* means egg yolk.) Usually these lesions are bilateral and symmetrical, although eccentric lesions may also occur. Table 12.7 lists the various manifestations.

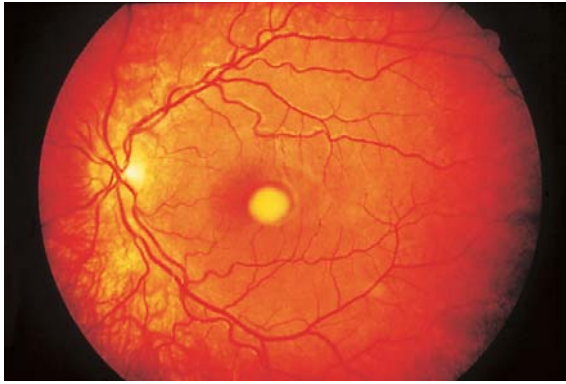
**Best's vitelliform dystrophy.**

Fig. 12.30
The yellow, sharply demarcated lesion appears like the yolk of a fried egg.

Table 12.7 Stages of Best's vitelliform dystrophy

Stage	Characteristics
Previtelliform stage	Yellowish central pigment changes
Vitelliform stage	Sharply demarcated yellow yolk-like lesion (see Fig. 12.30)
Pseudohypopyon stage	Settling of the yellow material
Vitelliruptive stage	"Scrambling" of the yolk-like lesions with irregular yellow deposits
Scar stage	Transition to scar



The macular change resembling an egg yolk gave rise to the name vitelliform dystrophy.

Differential diagnosis: An unequivocal diagnosis can usually be made on the basis of the clinical picture alone. Sharply reduced or absent light response in the EOG and ERG confirms the presence of Best's vitelliform dystrophy.

Treatment: The causes of the disorder cannot be treated.

Prophylaxis: Examination of siblings and genetic counseling are indicated.

Clinical course and prognosis: The prognosis is more favorable than for Stargardt's disease. The disorder is chronically progressive. Visual acuity in the better eye usually remains about 20/40. Secondary loss of visual acuity can result from subretinal neovascularization.



12.5.2 Retinitis Pigmentosa

Definition

This term is used to refer to a heterogeneous group of retinal disorders that lead to progressive loss of visual acuity, visual field defects, and night blindness. The name retinitis pigmentosa comes from the pigment deposits that characterize these disorders. In their classic form (see findings and diagnostic considerations) of such disorders, these deposits progress from the periphery to the center of the retina.

Epidemiology: The worldwide incidence of retinitis pigmentosa is estimated at between one per 35 000 and one per 70 000 persons. The estimated incidence of mutated alleles is one per 80 persons.

Forms of retinitis pigmentosa:

1. Rod-cone dystrophy (classic retinitis pigmentosa, by far the most frequent form).
2. Cone-rod dystrophy (inverse retinitis pigmentosa).
3. Sectoral retinitis pigmentosa.
4. Retinitis pigmentosa sine pigmento (form without pigment).
5. Unilateral retinitis pigmentosa.
6. Leber's amaurosis (form occurring in early childhood).
7. Retinopathy punctata albescens (punctate retinitis).
8. In combination with other disorders in syndromes and metabolic disorders such as mucopolysaccharidoses, Fanconi's syndrome, mucopolipidosis IV, peroxisomal disorders, Cockayne's syndrome, mitochondrial myopathies, Usher's syndrome, neuronal and ceroid lipofuscinoses, renal tubular defect syndromes, etc.

Retinitis pigmentosa occurs almost exclusively as rod-cone dystrophy. Therefore, the other extremely rare forms are not discussed here except for the inverse form of classic retinitis pigmentosa, which is presented for purposes of comparison.

Inheritance: Individual genetic forms may be identified from among the heterogeneous group of disorders comprising retinitis pigmentosa. This group of disorders can involve various genotypes as well as variable phenotypic expression or different stages of a disorder with one specific genotype. There are *over 15 purely ocular forms* of retinitis pigmentosa. The most common form of inheritance is autosomal recessive (60%), followed by autosomal dominant (up to 25%), and X-linked (15%). Rhodopsin gene mutations (chromosome 3) and "retinal degeneration slow" (RTS) gene mutations (chromosome 6) have also been described.



Symptoms: Initial symptoms of retinitis pigmentosa include glare, night blindness, progressive visual field defects, loss of visual acuity, and color vision defects. The age of manifestation depends on the type of inheritance.

Findings and diagnostic considerations: The diagnosis is made by ophthalmoscopy on the basis of a classic picture.

Rod-cone dystrophy (primarily the rods are affected first). “*Bone-spicule*” proliferation of retinal pigment epithelium is observed in the middle periphery of the retina. This will gradually spread toward the center and farther peripherally (Fig. 12.31). Early deficits include color vision defects and disturbed contrast perception. *Atrophy of the optic nerve*, discernible as a waxy yellow appearance of the optic disk, will occur in the advanced stages. The *arteries will appear narrowed*, and the *fundus reflex will be extremely muted*. The patient will typically have a “*gun-barrel*” visual field with good visual acuity for a surprisingly long time but with progressive loss of the peripheral visual field.

Cone-rod dystrophy (primarily the cones are affected first). Here, there is early loss of visual acuity with gradual progressive loss of visual field. In both forms of retinitis pigmentosa, the diagnosis is confirmed by electroretinography. Light response in the electroretinogram will be sharply reduced or absent early in the clinical course of the disease.

Differential diagnosis: Differential diagnosis should consider changes collectively referred to as pseudoretinitis pigmentosa because they simulate the clinical picture of retinitis pigmentosa. The most common causes that should be excluded in this context are:

Advanced retinitis pigmentosa.

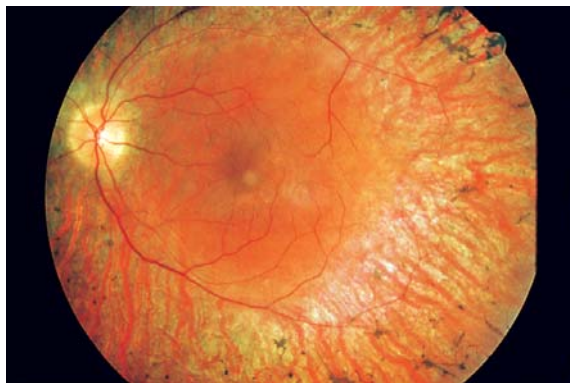

Fig. 12.31 Typical signs include narrowed retinal vessels, waxy yellow appearance of the optic disk due to atrophy of the optic nerve, and “bone-spicule” proliferation of retinal pigment epithelium.



- ❖ Posttraumatic changes.
- ❖ Postinflammatory or postinfectious changes. These may include degenerative retinal pigment epithelial disease secondary to rubella with “salt and pepper” fundus of punctate areas of atrophy and proliferation of retinal pigment epithelium. Other causes include syphilis, which may present with placoid lesions of pigment epithelial atrophy and proliferations.
- ❖ Tumors.
- ❖ Medications, such as chloroquine, Myambutol (ethambutol), and thioridazine.

Treatment: The causes of the disorder cannot be treated. Edge-filtered eyeglasses (eyeglasses with orange or blue colored lenses that filter out certain wavelengths) and magnifying near vision aids can help make better use of the patient’s remaining vision.

Prophylaxis: No prophylaxis is possible.

Clinical course and prognosis: Retinitis pigmentosa is chronically progressive. The clinical course depends on the specific form of the disorder; severe forms lead to blindness.

12.6 Toxic Retinopathy

Definition

Retinal changes resulting from use of medications.

Epidemiology: Toxic retinopathy is rare.

Pathogenesis: Toxic retinopathy can remain asymptomatic for a long time. Loss of visual acuity occurs if the macula is affected.

Chloroquine in doses exceeding 250 g causes retinal damage. Macular edema can occur initially. Later, punctate pigment epithelial changes develop, which may progress to bull’s eye maculopathy with concentric rings of hypopigmentation and hyperpigmentation in the macular region (Fig. 12.32). These findings are usually bilateral and symmetrical. Other toxic retinal changes are listed in the appendix.

Diagnostic considerations: The diagnosis is made by binocular ophthalmoscopy with the pupil dilated and confirmed by electrophysiologic studies that include an electroretinogram, electro-oculogram, and visual evoked potentials (see Fig. 12.2a).

Differential diagnosis: Retinal pigment epithelium or retinal bleeding can result from many other retinal disorders, and may also be associated with the underlying disease for which the medication was prescribed.



Chloroquine toxicity (bull's eye maculopathy).

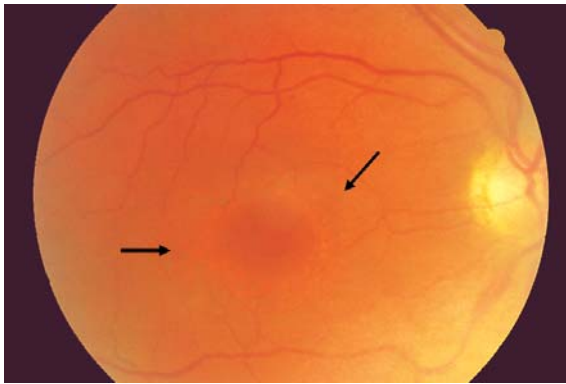


Fig. 12.32
Chronic use of this medication causes concentric rings of atrophy and proliferation of retinal pigment epithelium (arrows).

Treatment: The medication should be discontinued if possible.

Prophylaxis: Regular ophthalmologic follow-up examinations are indicated before and during treatment that involves medications with known ocular side effects.

Clinical course and prognosis: The clinical course depends on the specific medication and dose. Findings may improve after the medication is discontinued. However, with chloroquine in particular, findings may continue to worsen even years later.

12.7 Retinal Inflammatory Disease

12.7.1 Retinal Vasculitis

Definition

Retinal vasculitis is an inflammation of the retinal vasculature. Typical findings include cells in the vitreous body.

Epidemiology: Retinal vasculitis is one of the more frequent clinical syndromes.

Etiology: The cause of retinal vasculitis often remains obscure. It can be caused by a pathogen or occur in association with immunologic processes (Table 12.8).



Table 12.8 The most important causes of retinal vasculitis

❖ Idiopathic	❖ Sarcoidosis
❖ Eales' disease	❖ Tuberculosis
❖ Behçet's disease	❖ Borreliosis (Lyme disease)
❖ Multiple sclerosis	❖ Listeriosis
❖ Lupus erythematosus	❖ Brucellosis
❖ Wegener's granulomatosis	❖ Syphilis
❖ Polyarteritis nodosa	❖ Viruses
❖ Horton's arteritis	

Symptoms: Patients report loss of visual acuity or black dots in their visual field. These are due to the presence of cells in the vitreous body.

Diagnostic considerations: The ophthalmologic diagnostic work-up includes clinical examination, ophthalmoscopy, and slit-lamp examination. The slit-lamp examination will reveal *cells in the vitreous body*. Ophthalmoscopic findings will include whitish preretinal infiltrates (Fig. 12.33), vascular constriction (usually involving the veins), vascular occlusion, intraretinal bleeding, and retinal edema. Fluorescein angiography may be used to evaluate the presence and activity of neovascularization. Underlying systemic disease, immunologic processes, and infections (see Table 12.8) must be excluded.

Differential diagnosis: Other vascular diseases of the retina such as vein occlusion should be excluded. These vascular diseases may be distinguished from vascular retinitis by the *absence of cells in the vitreous body*.

Retinal vasculitis.

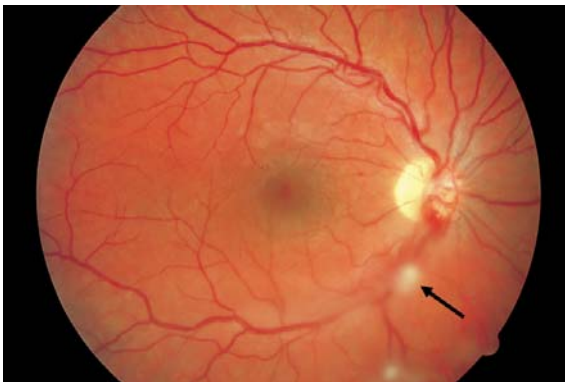


Fig. 12.33 Ophthalmoscopy reveals whitish preretinal vitreous infiltrates (arrow).



Treatment: The causes of known underlying disorders should be treated. Symptoms are treated with topical steroids and systemic steroids in the absence of contraindications. Neovascularization is treated with laser therapy.

Prophylaxis: No prophylaxis is possible except for possible treatment of an underlying disorder.

Clinical course and prognosis: Vascular occlusion can result in neovascularization that may lead to vitreous hemorrhage. Tractional retinal detachment is another possible complication.

12.7.2 Posterior Uveitis Due to Toxoplasmosis

Definition

Focal chorioretinal inflammation caused by infection.

Epidemiology: This clinical syndrome is encountered frequently.

Pathogenesis: The pathogen, *Toxoplasma gondii*, is transmitted by ingestion of tissue cysts in raw or undercooked meat or by oocysts from cat feces. In congenital toxoplasmosis, the child acquires the pathogen through transplacental transmission.

Symptoms and diagnostic considerations: As a general rule, a negative complement-fixation test does not exclude *Toxoplasma* infection where classic clinical symptoms are present. Both forms of the disorder present with characteristic *grayish white chorioretinal focal lesions surrounded by vitreous infiltration* and *associated vasculitis* (Fig. 12.34). In **congenital toxoplasmosis**, the affected children have a *macular scar* that *significantly impairs* visual acuity. This often leads to secondary strabismus. Intracerebral involvement can also result in hydrocephalus and intracranial calcifications. In the **acquired form**, visual acuity is impaired only where the macula is involved. This is rarely the case.



Congenital toxoplasmosis results in a macular scar that significantly impairs visual acuity.

Differential diagnosis: Chorioretinitis with tuberculosis, sarcoidosis, borreliosis (Lyme disease), or syphilis should be excluded by serologic studies.

Treatment: The treatment of choice consists of a combination of pyrimethamine, sulfonamide, folinic acid, and steroids in their respective standard doses.

Prophylaxis: Avoid raw meat and cat feces.



Recurrent toxoplasmosis.

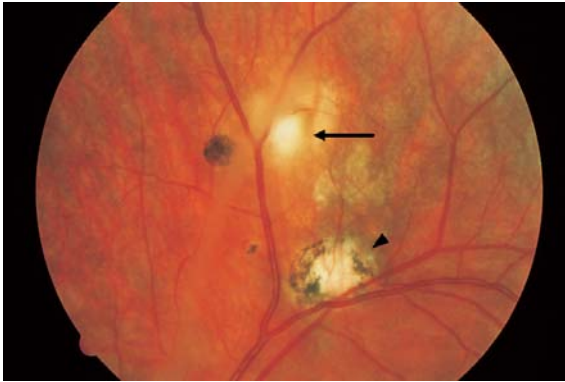


Fig. 12.34
Acute grayish white chorioretinal focal lesion (arrow) and brownish white chorioretinal scars (arrow-head). Lesions usually recur at the margin of the original scar, the "mother spot".

Clinical course and prognosis: Posterior uveitis due to toxoplasmosis usually heals without severe loss of visual acuity where the macula is not involved. However, it can recur at any time. There is no cure for the congenital form.

12.7.3 AIDS-Related Retinal Disorders

Definition

Retinal disorders in AIDS involve either AIDS-associated microangiopathy or infection.

Epidemiology: Up to 80% of all AIDS patients have retinal disorders as a result of the disease. Other ocular involvement is rare.

Pathogenesis: The pathogenesis of microangiopathy is still unclear. Opportunistic infections are frequently caused by viruses.

Symptoms: Microangiopathy is usually asymptomatic. Patients with infectious retinal disorders report loss of visual acuity and visual field defects.

Diagnostic considerations: Ophthalmoscopic findings in **AIDS-associated microangiopathy** include hemorrhages, microaneurysms, telangiectasia, and cotton-wool spots. Direct involvement of vascular endothelial cells in HIV infection or immune-complex-mediated damage to endothelial cells and vascular structures is thought to play a role.



Cytomegalovirus retinitis.

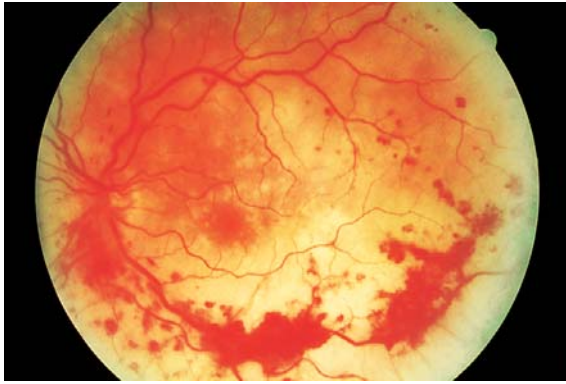

Fig. 12.35
Typical signs include extensive white areas of retinal necrosis and hemorrhages.

Cytomegalovirus retinitis occurs in 20–40% of older patients. Peripheral retinal necrosis and intraretinal bleeding (Fig. 12.35) are frequently observed. Vascular occlusion is rare. Secondary rhegmatogenous retinal detachment may develop. These lesions heal to produce fine granular pigment epithelial scars.

Less frequently, AIDS may involve **retinal infection** caused by **herpes simplex** and **varicella-zoster viruses**, **Toxoplasma gondii**, or **Pneumocystis carinii**. The diagnosis of a viral retinal infection in AIDS is confirmed by attempting to obtain positive serum cultures and by resistance testing.

Differential diagnosis: Inflammatory retinal changes due to other causes should be excluded by serologic studies.

Treatment: Microangiopathy does not require treatment. Viral retinitis is treated with ganciclovir or foscarnet. Herpes simplex and varicella-zoster viruses are treated with acyclovir.

Prophylaxis: Ophthalmologic screening examinations are indicated in the presence of known viral infection.

Clinical course and prognosis: The prognosis for microangiopathy is very good. Infectious retinitis will lead to blindness if left untreated. Visual acuity can often be preserved if a prompt diagnosis is made.



12.7.4 Viral Retinitis

Definition

Retinal disorder caused by viral infection.

Epidemiology: Viral retinitis is a rare disorder

Pathogenesis: Infection of the retina and retinal vasculature caused by cytomegalovirus, herpes simplex, varicella-zoster, or rubella viruses. Viral retinitis frequently occurs in immunocompromised patients.

Symptoms: Patients report loss of visual acuity and visual field defects.

Diagnostic considerations: Slit-lamp examination will reveal cells in the vitreous body. Ophthalmoscopic findings will include retinal necrosis with intraretinal bleeding (see Fig. 12.35). Necrosis can occur as acute lesions and spread over the entire retina like a grassfire within a few days. When the retinitis heals, it leaves behind wide-area scarring.

During pregnancy, rubella virus can cause embryopathy in the child. Ophthalmic examination will reveal typical fine granular pigment epithelial scars on the fundus that are often associated with a congenital cataract. The diagnosis is confirmed by measuring the serum virus titer. The possibility of compromised immunocompetence should be verified or excluded.

Differential diagnosis: Posterior uveitis and vasculitis should be excluded. These disorders may be distinguished from viral retinitis by the absence of necrosis.

Treatment: The disorder is treated with high doses of an antiviral agent (acyclovir, ganciclovir, or foscarnet) according to the specific pathogen.

Prophylaxis: Ophthalmologic screening examinations are indicated in immunocompromised persons with suspected viral infection.

Clinical course and prognosis: Viral retinitis can be arrested if diagnosed early. However, recurrences are frequent in immunocompromised patients. Blindness usually cannot be prevented in retinal necrosis syndrome.

12.7.5 Retinitis in Lyme Disease

Definition

Inflammation of the retina usually caused by *Borrelia burgdorferi*.

Epidemiology: The incidence of this retinal disorder has increased in recent years.



Etiology: The inflammation is caused by spirochetes usually transmitted by bites from infected ticks.

Findings and symptoms: Lyme disease can lead to many inflammatory ocular changes with their respective symptoms. These include conjunctivitis, keratitis, and iridocyclitis. Retinal vasculitis, retinal artery occlusion, neuroretinitis, optic neuritis, and choroiditis have also been described.



Lyme disease should be excluded as a possible cause of posterior uveitis of uncertain etiology.

Diagnostic considerations: The diagnosis is made by ophthalmoscopy and serologic studies to identify the pathogen.

Differential diagnosis: Inflammatory ocular changes due to other causes (such as toxoplasmosis or tuberculosis) should be excluded.

Treatment: Antibiotic treatment with tetracycline, penicillin G, or third-generation cephalosporins is indicated.

Clinical course and prognosis: Retinal changes due to Lyme disease tend to recur.

12.7.6 Parasitic Retinal Disorders

Definition

Inflammation of the retina caused by infection with parasites such as *Onchocerca volvulus* (the pathogen that causes onchocerciasis), *Toxocara canis* or *Toxocara cati* (nematode larvae that are normally intestinal parasites of dogs and cats), *Taenia solium*, (pork tapeworm), and other parasites.

Epidemiology: Onchocerciasis, like trachoma and leprosy, is one of the most frequent causes of blindness worldwide. However, like the other parasitic diseases discussed here, it is rare in Europe and North America.

Etiology: *Onchocerca volvulus* is transmitted by the bite of black flies. This allows the larvae (microfilaria) to penetrate the skin, where they form fibrous subcutaneous nodules. There they reach maturity and produce other microfilaria, which migrate into surrounding tissue. The danger of ocular infiltration is particularly great where there are fibrous nodules close to the eye.

Toxocara canis or *Toxocara cati* (eggs of nematodes infesting dogs and cats) are transmitted to humans by ingestion of substances contaminated with the feces of these animals. The eggs hatch in the gastrointestinal tract, where they gain access to the circulatory system and may be spread throughout the entire body. The choroid can become infested in this manner.



Taenia solium: The pork tapeworm infestation can occur from eating pork contaminated with larvae or other substances contaminated with tapeworm eggs. Mature tapeworms can also release eggs into the intestine. The larvae travel through the bloodstream to various organs and can also infest the eye.

Diagnostic considerations and findings: Ophthalmoscopy will reveal intraocular inflammation. Onchocerciasis has been known to be associated with posterior uveitis as well as keratitis and iritis. Histologic examination will demonstrate microfilaria in the retina. Visceral larva migrans, *Toxocara canis*, or *Toxocara cati* can cause complications involving endophthalmitis and retinal detachment. Subretinal granulomas and larval inflammation of the retina have been known to occur. The larvae of different species of worms can produce diffuse unilateral subacute neuroretinitis with the typical clinical picture of grayish white intraretinal and subretinal focal lesions. Fly larvae can also invade the subretinal space in ophthalmomyiasis.

Differential diagnosis: Other causes of retinal inflammation and subretinal granulomas should be excluded.

Treatment: Laser photocoagulation or surgical removal of the worm larvae may be indicated.

Clinical course and prognosis: It is not uncommon for these disorders to lead to blindness.

12.8 Retinal Tumors and Hamartomas

12.8.1 Retinoblastoma

Definition

A retinoblastoma is a malignant tumor of early childhood that develops from immature retinal cells.

Epidemiology: Retinoblastoma is the most common malignant ocular tumor in children, occurring in approximately one of 20000 births. In 30% of all cases, it is bilateral.

Pathogenesis: A somatic mutation is detected in about 95% of all patients. In the other patients, it is inherited as an autosomal dominant trait. Changes on chromosome 13q have been observed in germ-cell mutations. Retinoblastomas may then occur at several locations in the retina or bilaterally.



Where retinoblastoma is inherited as an autosomal dominant trait, the siblings of the affected child should be regularly examined by an ophthalmologist.



Symptoms: Retinoblastoma manifests itself before the age of three in 90% of affected children. Parents observe leukocoria (a whitish yellow pupil; Fig. 12.36) in 60% of these children, strabismus in 20%, and a reddened eye in 10%.

! Every child presenting with strabismus should undergo examination of the fundus with the pupil dilated to exclude a retinoblastoma.

Findings and diagnostic considerations: A grayish white, vascularized retinal tumor will be observed on ophthalmoscopy. In its advanced stages, this tumor was formerly referred to as an *amaurotic cat's eye*. Infiltration of the vitreous body, anterior chamber (pseudohypopyon), and orbit may occur. A retinoblastoma that also involves the fellow eye and pineal body is referred to as a *trilateral retinoblastoma*.

! A trilateral retinoblastoma is defined as additional manifestation of the tumor in the pineal body.

Calcifications frequently occur in these tumors. Radiographs or CT images that show calcifications can therefore help to confirm the diagnosis in uncertain cases.

Differential diagnosis: Several other disorders should be excluded by ophthalmoscopy. These include:

- ❖ Cataract (with leukocoria).
- ❖ Primary strabismus (with strabismus).
- ❖ Infection (with a reddened eye).

Leukocoria in the left eye due to a retinoblastoma.

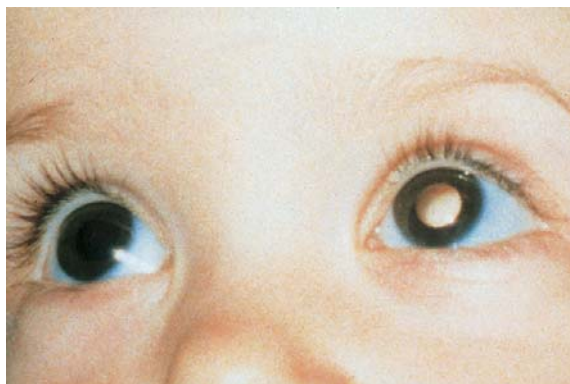

Fig. 12.36
The whitish gleam of the pupil of the left eye is a typical finding in retinoblastoma.



Retinal detachment, persistent hyperplastic primary vitreous (PHPV), and Coats' disease should also be excluded.

Treatment: Tumors less than four pupil diameters may be managed with radiation therapy delivered by plaques of radioactive ruthenium or iodine (brachytherapy) and cryotherapy. Larger tumors require enucleation of the eye.

Prophylaxis: Following the diagnosis, the fellow eye should be examined with the pupil dilated every three months for five years. After that, follow-up examinations may be performed at greater intervals.

Clinical course and prognosis: Left untreated, a retinoblastoma will eventually metastasize to the brain and cause death. Patients frequently develop a second malignant tumor such as an osteosarcoma.

12.8.2 Astrocytoma

Definition

An astrocytoma or astrocytic hamartoma is a *benign* tumor that develops from the astrocytes of the neuroglial tissue.

Epidemiology: Astrocytomas are rare.

Etiology: Astrocytomas belong to the phakomatoses and are presumably congenital disorders that develop from the layer of optic nerve fibers. They may manifest themselves as purely ocular disorders or in association with tuberous sclerosis (Bourneville's disease).

Symptoms: Patients usually have *no ocular symptoms*. Calcifying astrocytic hamartomas in the region of the basal ganglia or ventricles can cause epilepsy and mental deficiency. An astrocytoma in Bourneville's disease will be associated typically with an adenoma sebaceum in the facial skin.

Findings and diagnostic considerations: Astrocytomas are either incidental findings in ophthalmic examinations performed for other reasons, or they are diagnosed in patients presenting with reduced visual acuity. Ophthalmoscopy will reveal *single or multiple "mulberry" tumors* one to two pupil diameters in size. These will appear white and are often calcified. The tumors are inherently fluorescent when observed in blue light in fluorescein angiography with a blue filter.

Differential diagnosis: A retinoblastoma should be excluded in children. That is usually larger than an astrocytoma on ophthalmoscopy. A possible *Toxocara canis* granuloma should be confirmed or excluded by serologic studies.



Treatment: No ophthalmologic treatment is required. The patient should be referred to a neurologist to exclude cerebral involvement.

Clinical course and prognosis: These tumors rarely increase in size.

12.8.3 Hemangiomas

Definition

Capillary hemangiomas or hemangioblastomas occur in angiomatosis retinae (von Hippel-Lindau disease).

Von Hippel-Lindau disease.

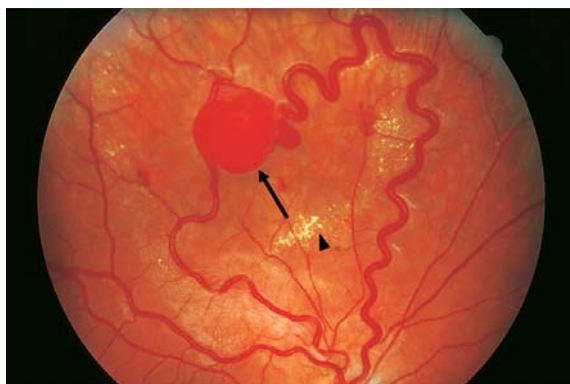
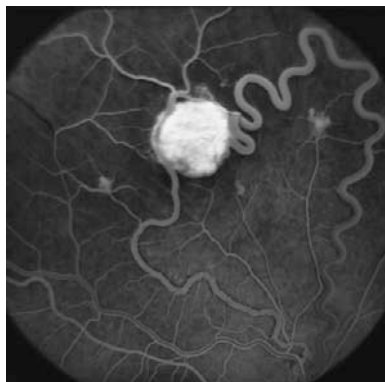

Fig. 12.37
a A hemangioblastoma (arrow) in von Hippel-Lindau disease with enlarged retinal arteries and veins and retinal detachment with hard exudate (arrowhead).



b Corresponding fluorescein angiogram.



Epidemiology: Hemangiomas are rare.

Etiology: These are *benign* congenital changes. There may be an autosomal dominant inheritance.

Symptoms: Loss of visual acuity will result where exudative retinal detachment develops.

Findings and diagnostic considerations: Retinal hemangiomas are characterized by thickened tortuous arteries and veins (Figs. 12.37 a and b). Bilateral changes are present in 50% of all patients.

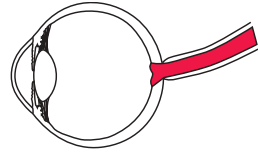
Differential diagnosis: Coats' disease, branching retinal hemangiomas in Wyburn-Mason syndrome, and cavernous hemangiomas should be considered. Cerebral hemangiomas, renal cysts, hypernephromas, and pheochromocytomas should also be excluded.

Treatment: Retinal hemangiomas may be treated by laser or cryocautery therapy. However, exudative retinal detachment will develop as the treatment increases this risk.

Clinical course and prognosis: The disorder is gradually progressive. The prognosis for visual acuity is poor in the disorder where retinal detachment develops.

13 Optic Nerve

Oskar Gareis and Gerhard K. Lang



13.1 Basic Knowledge

The optic nerve extends from the posterior pole of the eye to the *optic chiasm* (Fig. 13.1). After this characteristic crossing, the fibers of the optic nerve travel as the *optic tract* to the *lateral geniculate body*. Depending on the shape of the skull, the optic nerve has a total length of 35 – 55 mm. The nerve consists of:

- ❖ An intraocular portion.
- ❖ An intraorbital portion.
- ❖ An intracranial portion.

Path of the optic nerve.

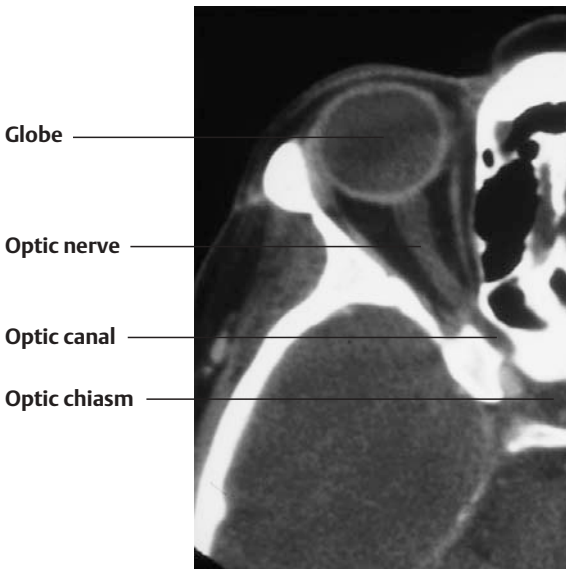


Fig. 13.1 CT image showing the intraorbital and intracranial portions of the optic nerve.



13.1.1 Intraocular Portion of the Optic Nerve

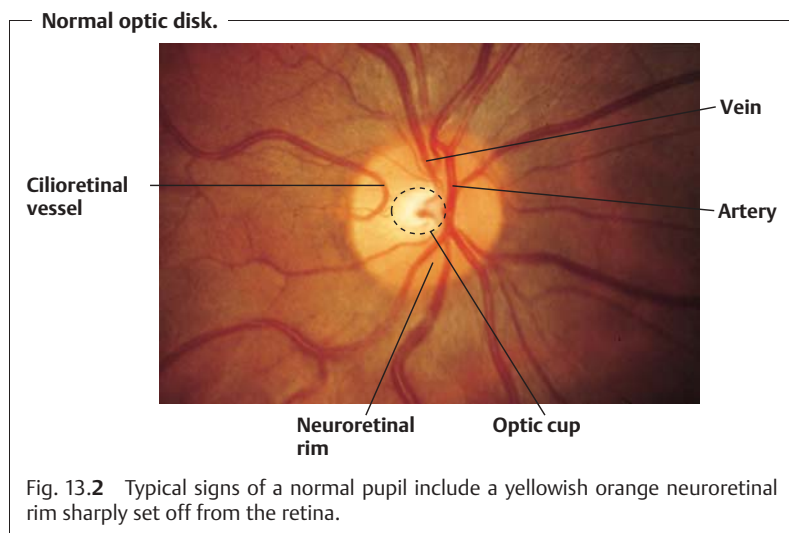
The intraocular portion of the optic nerve is visible on ophthalmoscopy as the **optic disk**. All the retinal nerve fibers merge into the optic nerve here, and the central retinal vessels enter and leave the eye here. The complete absence of photoreceptors at this site creates a gap in the visual field known as the *blind spot*.

Shape and size: The optic disk (Fig. 13.2) is normally *slightly vertically oval* with an average area of approximately 2.7 mm² and a horizontal diameter of approximately 1.8 mm. There is a *wide range of physiologic variability in the size of the optic disk*; its area may vary by a factor of seven, and its horizontal diameter by a factor of two and one-half.

Color: The normal physiologic color is *yellowish orange*. The temporal half of the optic disk is usually slightly paler.

Margin: The margin of the optic disk is *sharply defined* and readily distinguished from the surrounding retinal tissue. On the nasal side, the greater density of the nerve fibers makes the margin slightly less distinct than on the temporal side. A common clinical observation is a crescent of pigment or irregular pigmentation close to the optic disk on the temporal side; sometimes the sclera will be visible through this crescent.

Prominence of the optic disk: The normal optic disk is not prominent. The nerve fibers are practically flush with the retina.





Neuroretinal rim (Fig. 13.2): This consists of the bundles of all the optic nerve fibers as they exit through the scleral canal. The rim has a *characteristic configuration*: The narrowest portion is in the temporal horizontal region followed by the nasal horizontal area; the widest areas are the vertical inferior and superior areas.

Optic cup: This is the *slightly eccentric cavitation* of the optic nerve that has a slightly flattened oval shape corresponding to that of the neuroretinal rim. It is the brightest part of the optic disk. No nerve fibers exit from it (Fig. 13.2). The **size of the optic cup** correlates with the size of the optic disk; the larger the optic disk, the larger the optic cup. Because enlargement of the optic cup means a loss of nerve fibers in the rim, *it is particularly important to document the size of the optic cup*. This is specified as the horizontal and vertical *ratios of cup to disk diameter* (cup/disk ratio). Due to the wide range of variability in optic disk size, it is not possible to specify absolute cup/disk ratios that indicate the presence of abnormal processes.

Central retinal artery and vein: These structures usually enter the eye slightly nasal to the center of the optic disk. Visible pulsation in the vein is normal. However, *arterial pulsation is always abnormal* and occurs with disorders such as increased intraocular pressure and aortic stenosis.

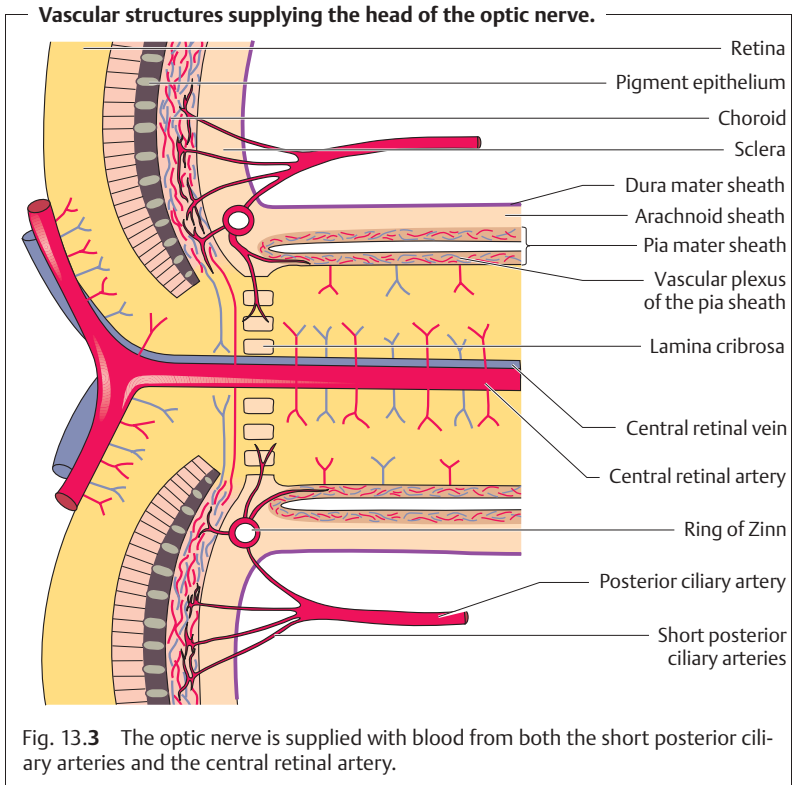
Cilioretinal vessels are aberrant vessels originating directly from the choroid (short posterior ciliary arteries). Resembling a cane, they usually course along the temporal margin of the optic disk and supply the inner layers of the retina (Fig. 13.2).

Blood supply to the optic disk (Fig. 13.3): The optic disk receives its blood supply from the ring of Zinn, an anastomotic ring of small branches of the short posterior ciliary arteries and the central retinal artery. Both groups of vessels originate from the ophthalmic artery, which branches off of the internal carotid artery and enters the eye through the optic canal. The central retinal artery and vein branch into the optic nerve approximately 8 mm before the point at which the optic nerve exits the globe. Approximately 10 short posterior ciliary arteries penetrate the sclera around the optic nerve.

13.1.2 The Intraorbital and Intracranial Portion of the Optic Nerve

The **intraorbital portion** begins after the nerve passes through a sieve-like plate of scleral connective tissue, the lamina cribrosa. Inside the orbit, the optic nerve describes an S-shaped course that allows extreme eye movements.

After the optic nerve passes through the optic canal, the short **intracranial portion** begins and extends as far as the optic chiasm. Like the brain, the intraorbital and intracranial portions of the optic nerve are surrounded by sheaths of dura mater, pia, and arachnoid (see Fig. 13.3). The nerve receives its blood supply through the vascular pia sheath.



13.2 Examination Methods

These include:

- ❖ Ophthalmoscopy (see Chapter 1).
- ❖ Visual acuity testing (see Chapter 1).
- ❖ Perimetry test (see Chapter 14).
- ❖ Pupillary light reflex (see Chapter 9).
- ❖ Testing color vision (for example with the panel D 15 test).
- ❖ Visual evoked potential (VEP).

Panel D 15 test of color vision: This is a color marker sorting test. The patient is presented with 15 small color markers that he or she must select and sort according to a fixed blue color marker. Patients with color vision defects will typically confuse certain markers within the color series. The specific color vision defect can be diagnosed from these mistakes.



Visual Evoked Potential (VEP): The VEP may be regarded as an *isolated occipital EEG*. The electrical responses in the brain to optical stimuli are transmitted by electrodes placed over the occipital lobe. Measurements include the *speed of conduction* (i.e., latency; normal values range between 90 and 110 ms) and the *voltage differential* between the occipital lobe and skin electrodes (i.e., amplitude; normal values depend on the laboratory setting). The *most important indication* for VEP testing is retrobulbar optic neuritis to demonstrate an extended latency period in demyelination, such as in diffuse encephalitis.

13.3 Disorders that Obscure the Margin of the Optic Disk

13.3.1 Congenital Disorders that Obscure the Margin of the Optic Disk

There are *normal* variants of the optic disk in which the margin appears fully or partially blurred. Care should be taken to distinguish them from abnormal findings.

13.3.1.1 Oblique Entry of the Optic Nerve

Where the **optic nerve exits the eye in an oblique and nasal direction** (Fig. 13.4), the nerve fibers on the nasal circumference will be elevated. The *tightly compressed nasal nerve fibers* will obscure the margin of the optic disk. Accordingly, *temporal nerve fibers are stretched*, and the neuroretinal rim cannot be clearly distinguished. Often an adjacent crescentic whitish area,

Oblique entry of the optic nerve.

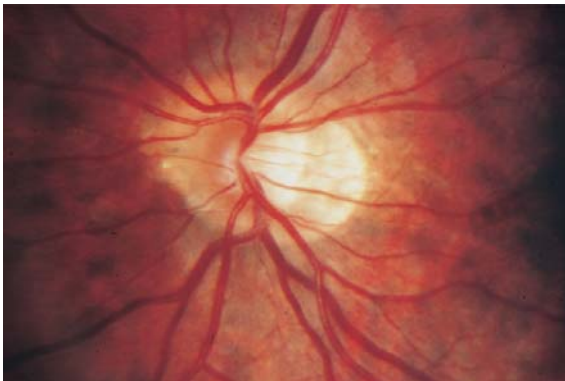


Fig. 13.4 Tightly compressed nasal nerve fibers cause slight elevation of the optic disk, and the margin of the disk is obscured.



known as a temporal crescent, will be observed on the temporal side. This crescent is frequently seen in myopia and is referred to as a myopic crescent. It can also be circular.

13.3.1.2 Tilted Disk

An **optic nerve that exits the eye superiorly** (Fig. 13.5) is referred to as a tilted disk. The *superior circumference of the margin of the optic disk will be obscured* in a manner similar to oblique entry of the optic nerve. A number of other changes may also be observed, including an inferior crescent, situs inversus of the retinal vessels, ectasia of the fundus, myopia, and visual field defects. These findings may occur in various combinations and are referred to collectively as **tilted-disk syndrome**. This is *clinically highly significant* as nasal inferior ectasia of the fundus can produce temporal superior visual field defects. Where these findings are bilateral, care should be taken to distinguish them from pituitary tumors. This clinical picture is regarded as a form of *rudimentary coloboma*.

13.3.1.3 Pseudopapilledema

Pseudopapilledema (Fig. 13.6) is due to a *narrow scleral canal*. Because of the constriction, the nerve fibers are tightly compressed. The optic disk is **elevated and the full circle of the margin obscured**. The optic cup is absent, and the retinal vessels appear tortuous. There are no abnormal morphologic changes such as bleeding, nerve fiber edema, and hyperemia; visual acuity and visual field are normal. Pseudopapilledema *can* occur with hyperopia,

Tilted disk.

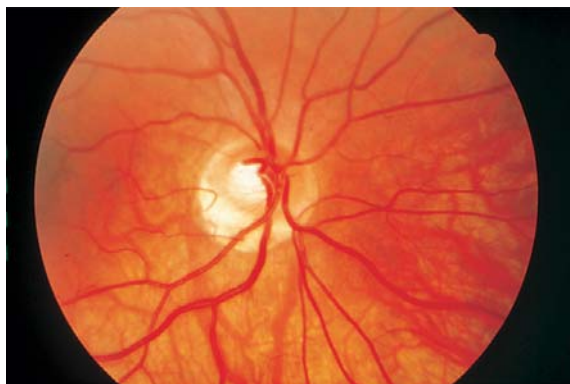

Fig. 13.5
Oblique entry of the optic nerve superiorly with an inferior crescent and inferior segmental ectasia of the fundus.

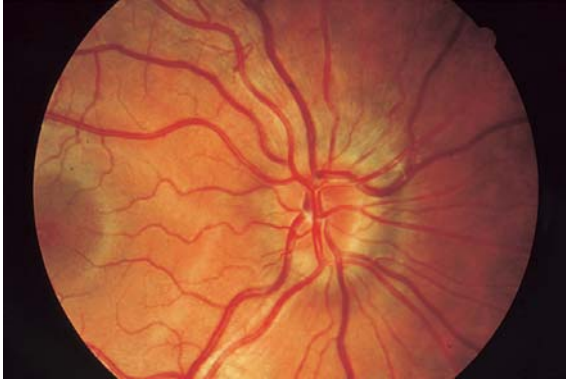**Pseudopapilledema.**

Fig. 13.6 Circular blurring of the margin of the optic disk with absence of the optic cup.

although it is encountered equally frequently in emmetropic or slightly myopic eyes.

Differential diagnosis: optic disk edema, optic disk drusen (see Table 13.1).

13.3.1.4 Myelinated Nerve Fibers

Normally retinal nerve fibers are not myelinated. However, **myelinated areas** occasionally occur in the retina (Fig. 13.7). They occur most frequently **at the**

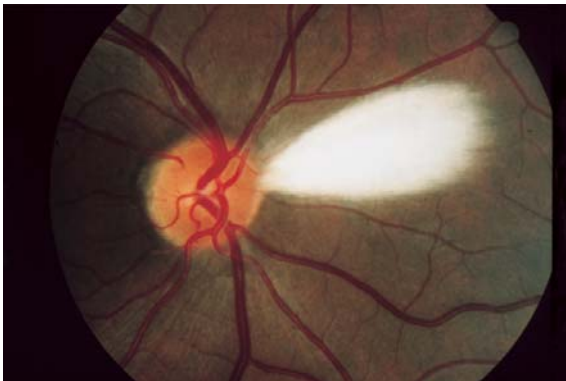Myelinated nerve fibers.

Fig. 13.7 Because they are myelinated, the nerve fibers appear whitish and striated and can simulate segmental blurring of the margin.



margin of the optic disk. Whitish and striated, they simulate segmental or circular blurring of the margin. Myelinated nerve fibers can *also occur on the periphery of the retina*. Because of their location in the innermost layer of the retina, they tend to obscure the retinal vessels. Myelinated nerve fibers normally cause no loss of function. Only extensive findings can lead to small scotomas.

13.3.1.5 Bergmeister's Papilla

The fetal hyaloid artery emerges from the optic disk to supply the vitreous body and lens. Glial and fibrous tissue may persist if the structure is not fully absorbed. This vestigial tissue, usually on the nasal side of the optic disk, is known as **Bergmeister's papilla**. When this tissue takes the form of veil-like membrane overlying the surface of the optic disk, it is also referred to as an **epipapillary membrane** (Fig. 13.8). Usually this condition is *asymptomatic*.

13.3.1.6 Optic Disk Drusen

Drusen are **yellowish lobular bodies in the tissue of the optic disk that are usually bilateral (in 70% of all cases)**. Ophthalmoscopy can reveal superficial drusen but not drusen located deep in the scleral canal. In the presence of optic disk drusen, the disk appears *slightly elevated with blurred margins and without an optic cup* (Fig. 13.9). Abnormal morphologic signs such as hyperemia and nerve fiber edema will not be present. However, bleeding in lines along the disk margin or subretinal peripapillary bleeding may occur in rare cases.

Bergmeister's Papilla.

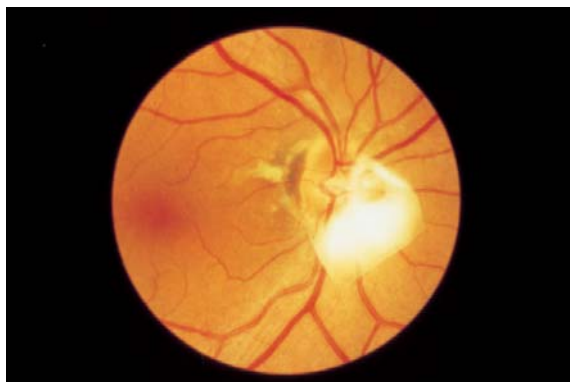

Fig. 13.8 Remnants of the hyaloid artery forming a veil-like epipapillary membrane overlying the surface of the optic disk are seen on nasal side.



Optic disk drusen.

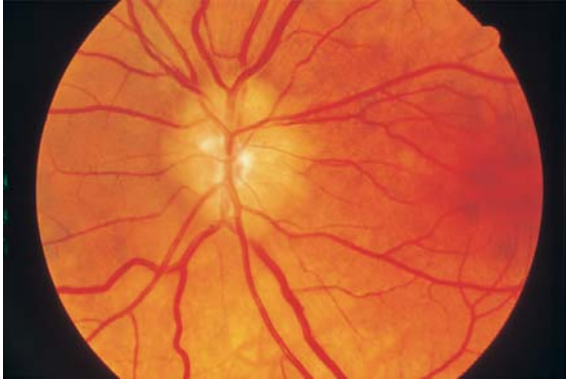

Fig. 13.9 The yellowish lobular deposits (drusen) make the optic disk appear elevated with blurred margins and without an optic cup.

A small lamina cribrosa appears to be a factor in the *etiology* of the disorder. This impedes axonal plasma flow, which predisposes the patient to axonal degeneration. This in turn produces calcifications exterior to the axons (drusen). Retinal drusen are hyaline deposits in Bruch's membrane and are a completely unrelated process.

Drusen usually **do not cause any loss of function**. Deep drusen can cause compressive atrophy of nerve fibers with resulting subsequent visual field defects.

Optic disk drusen may be diagnosed on the basis of characteristic ultrasound findings of highly reflective papillary deposits. Fluorescein angiography findings of autofluorescence prior to dye injection are also characteristic.

See Table 13.1 for *differential diagnosis*.

13.3.2 Acquired Disorders that Obscure the Margin of the Optic Disk

The normal variants and congenital changes discussed in the previous section must be distinguished from *abnormal changes to the optic disk due to nerve fiber edema*. The term optic disk edema is used in a generic sense to describe any such change. However, this term should be further specified whenever possible:

- ❖ **Optic disk edema without primary axonal damage:**
 - Papilledema.
 - Hypotension papilledema.
- ❖ **Optic disk edema with direct axonal damage:**
 - Inflammation: papillitis or retrobulbar optic neuritis.
 - Infarction with ischemic optic neuropathy (arteriosclerotic or arteritic).



❖ **Optic disk edema due to infiltration:**

- For example due to an underlying hematologic disorder.

13.3.2.1 Papilledema

Definition

Bilateral optic disk edema secondary to increased intracranial pressure.

Epidemiology: Epidemiologic data from the 1950s describe papilledema in as many as 60% of patients with brain tumors. Since then, advances in neuroradiology have significantly reduced the incidence of papilledema. The diagnostic importance of the disorder has decreased accordingly.

Etiology: An adequate theory to fully explain the pathogenesis of papilledema is lacking. Current thinking centers around a mechanical model in which increased intracranial pressure and impeded axonal plasma flow through the narrowed lamina cribrosa cause nerve fiber edema. However, there is no definite correlation between intracranial pressure and prominence of the papilledema. Nor is there a definite correlation between the times at which the two processes occur. However, severe papilledema can occur within a few hours of increased intracranial pressure, such as in acute intracranial hemorrhage. Therefore, papilledema is a *conditional, unspecific sign of increased intracranial pressure* that does not provide conclusive evidence of the cause or location of a process.

In approximately 60% of all cases, the increased intracranial pressure with papilledema is caused by an *intracranial tumor*; 40% of all cases are due to other causes, such as hydrocephalus, meningitis, brain abscess, encephalitis, malignant hypertension, or intracranial hemorrhages. The patient should be referred to a neurologist, neurosurgeon, or internist for diagnosis of the underlying causes.



Every incidence of papilledema requires immediate diagnosis of the underlying causes as increased intracranial pressure is a life-threatening situation.

The incidence of papilledema in the presence of a brain tumor decreases with increasing age; in the first decade of life it is 80%, whereas in the seventh decade it is only 40%. Papilledema cannot occur where there is atrophy of the optic nerve, as papilledema requires intact nerve fibers to develop.

Special forms:

- ❖ **Foster Kennedy syndrome:** This refers to isolated atrophy of the optic nerve due to direct tumor pressure on one side and papilledema due to increased intracranial pressure on the other side. Possible causes may include a meningioma of the wing of the sphenoid or frontal lobe tumor.



- ❖ **Hypotension papilledema:** This refers to a nerve fiber edema due to ocular hypotension. Possible causes may include penetrating trauma or fistula secondary to intraocular surgery.

Symptoms and diagnostic considerations: Visual function remains unimpaired for long time. This significant discrepancy between morphologic and functional findings is an *important characteristic in differential diagnosis*. **Early functional impairments** can include reversible obscurations. *Perimetry testing* may reveal an increase in the size of the blind spot (Fig. 13.10c). Central visual field defects and concentric narrowing of the visual field are **late functional impairments** that occur with existing complex atrophy of the optic nerve.



Papilledema is characterized by significant morphologic findings and only slight visual impairment.

The following **phases** may be distinguished by *ophthalmoscopy*:

Early phase (Fig. 13.10a): First the nasal margin and then the superior and inferior margins of the optic disk are obscured because of the difference in the relative densities of the nerve fibers (see optic disk). The optic cup *is initially preserved*. This is important in a differential diagnosis to exclude pseudopapilledema and optic disk drusen. The optic disk is hyperemic due to dilatation of the capillaries, and there is no pulsation in the central retinal vein. Edema can produce concentric peripapillary retinal folds known as Paton's folds.

Acute phase (Fig. 13.10b): This is characterized by increasing elevation of the optic disk, radial hemorrhages around the margin of the optic disk and grayish white exudates. *The optic cup is often no longer discernible*. The color of the optic disk will be red to grayish red.

Chronic phase. Significant optic disk edema is present. *The optic cup is obliterated*, and the hyperemia will be seen to subside.

Atrophic phase. Proliferation of astrocytes results in complex or secondary atrophy of the optic nerve.

Differential diagnosis: This includes pseudopapilledema, optic disk drusen (Table 13.1), abnormalities of the optic disk without functional impairment, optic disk edema with hypertension, and optic neuritis.

Treatment: Intracranial pressure should be reduced by treating the underlying disorder (see Etiology). Once intracranial pressure has been normalized, the papilledema will resolve within a few weeks. Usually complex atrophy of the optic nerve will remain. The severity will vary according to the duration of the papilledema.

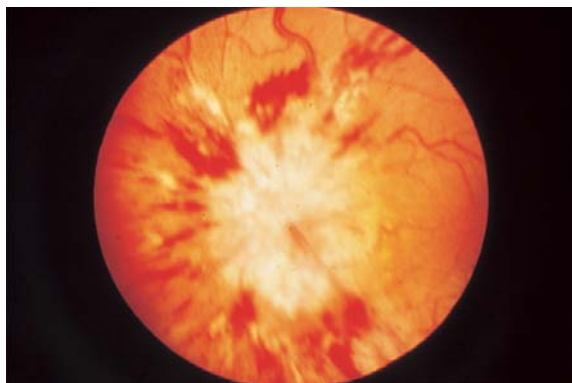


Papilledema.

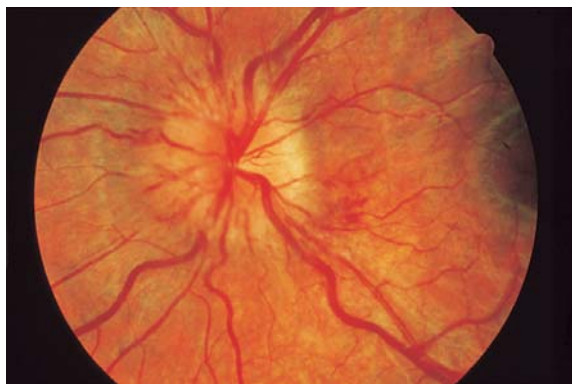

Fig. 13.10

a Early phase of papilledema: The nasal margin of the optic disk is partially obscured. The optic disk is hyperemic due to dilatation of the capillaries, and the optic cup is still visible.



b Acute stage: The optic disk is increasing elevated and has a gray to grayish red color. Radial hemorrhages around the margin of the optic disk and grayish white exudates are observed. The optic disk can no longer be clearly distinguished.

Continued →

13.3.2.2 Optic Neuritis

Definition

Optic neuritis is an inflammation of the optic nerve that may occur within the globe (**papillitis**) or posterior to it (**retrobulbar optic neuritis**).

Epidemiology: Optic neuritis occurs most frequently in adults between the ages of 20 and 45. Women are more frequently affected than men. Twenty to forty per cent of all patients with optic neuritis develop diffuse encephalitis (multiple sclerosis).



Papilledema (continued).

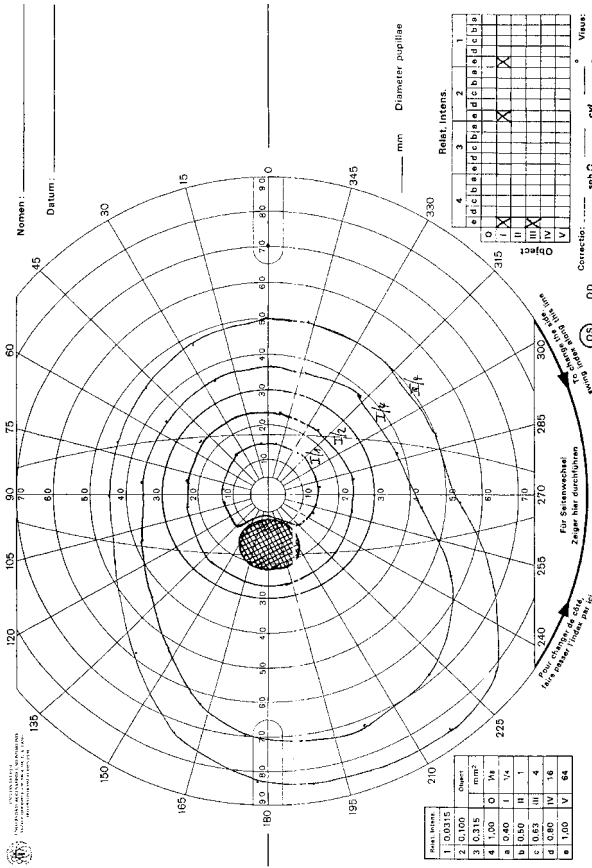


Fig. 13.10 c Functional findings. The enlarged blind spot (indicated by hatching) is an early functional correlate to ophthalmoscopic findings. The blind spot is an absolute scotoma (indicated by cross-hatching), meaning that the patient cannot discern marker V/4. The enlargement of the blind spot (indicated by hatching) is a relative scotoma, meaning that the patient cannot discern marker 1/4. The markers used in the test are light markers of varying size (indicated by Roman numerals) and varying light intensity (indicated by Arabic numerals and letters). The larger the number, the larger the size and greater the light intensity of the respective marker. The table at the lower right shows which markers were used in the test. The table at the lower left shows the values corresponding to the numerals and letters.



Table 13.1 Differential diagnosis of pseudopapilledema, optic disk drusen, and papilledema

Differential criterion	Pseudopapill- edema	Optic disk drusen	Papilledema
❖ Size of optic disk	Small	Small	Unaffected
❖ Optic cup	Absent	Absent	Initially present
❖ Spontaneous venous pulse	Possibly present	Possibly present	Absent
❖ Veins and papillary capillaries	Normal	Normal	Obstructed
❖ Color of optic disk	Normal	Pale	Hyperemic
❖ Peripapillary bleed- ing	Absent	Absent	Present
❖ Peripapillary nerve fibers	Normal	Normal	Edematous
❖ Angiography	Normal	Intrinsic fluores- cence	Early leakage
❖ Ultrasound	Atypical	Highly reflective deposits	Atypical

Etiology: Papillitis.

- ❖ *Inflammatory processes:* These include infectious diseases such as Lyme disease, malaria, and syphilis, and manifestations in the optic nerve of inflammation of the orbit, paranasal sinuses, or base of the skull.
- ❖ *Autoimmune disorders:* These include lupus erythematosus, polychondritis, regional enteritis (Crohn's disease), ulcerative colitis, nodular panarteritis, and Wegener's granulomatosis.
- ❖ *Toxic damage* due to agents such as methanol, lead, Myambutol (ethambutol hydrochloride), and chloramphenicol. In 70% of these cases, the *cause is not determined*.

Retrobulbar optic neuritis. The primary causes of this disorder are *demyelinating diseases of the central nervous system* such as diffuse encephalitis. In 20% of all cases, retrobulbar optic neuritis is an isolated early symptom of diffuse encephalitis. However, a differential diagnosis should always also consider the *other causes of papillitis mentioned above*.

Symptoms: The **cardinal symptom** is *sudden loss of vision*, which may occasionally be accompanied by fever (*Uhthoff symptom*). The field of vision is typically impaired by a central scotoma (Fig. 13.11b), paracentral scotomas, a



centrocecal scotoma involving the macula and blind spot, and wedge-shaped visual field defects up to and including complete blindness.

Other symptoms include pain that increases in extreme positions of gaze and when pressure is applied to the globe, and reduced perception of color intensity.

Diagnostic considerations: Ophthalmoscopic findings in **papillitis** (Fig. 13.11 a) include edema and hyperemia of the head of the optic nerve. This flattens the optic cup and obscures the margin of the optic disk. Bleeding at the margin of the optic disk may or may not be present. The elevation of the optic disk is considerably less than in papilledema.

The optic disk will appear normal in **retrobulbar optic neuritis**.



In retrobulbar optic neuritis, the patient sees nothing (due to a central scotoma), and the physician sees nothing (the fundus appears normal).

Other findings upon examination include an afferent pupillary defect (this is regularly encountered; see Chapter 9), red-green color vision defect, and delayed latency in the visual evoked potential.

Differential diagnosis:

Papilledema: Initially there is no loss of function.

Ischemic optic neuropathy: The central scotoma is lacking, and patients are usually over the age of 60.

Treatment: This depends on the underlying disorder. Retrobulbar optic neuritis with severe loss of vision (less than 0.1) may be treated with high doses of steroids, i.e., 1000 mg of oral prednisolone daily for three days and 1 mg of oral prednisolone per kilogram of body weight on days four through fourteen. However, this treatment only leads to more rapid restoration of vision. Final visual acuity after one year is identical with or without high-dose steroid therapy.

Prognosis: This depends on the underlying disorder. Severe permanent losses of visual acuity are possible, as are significant spontaneous improvements. **Retrobulbar optic neuritis in diffuse encephalitis** usually exhibits a strong tendency toward spontaneous improvement within four weeks without any treatment. However, *discrete functional defects* such as reduced visual contrast and reduced perception of color intensity will *always* remain. Morphologic findings *always* include a *pale optic* disk as a result of complex atrophy of the optic nerve following papillitis or partial isolated atrophy of the optic nerve following retrobulbar optic neuritis.



Papillitis.

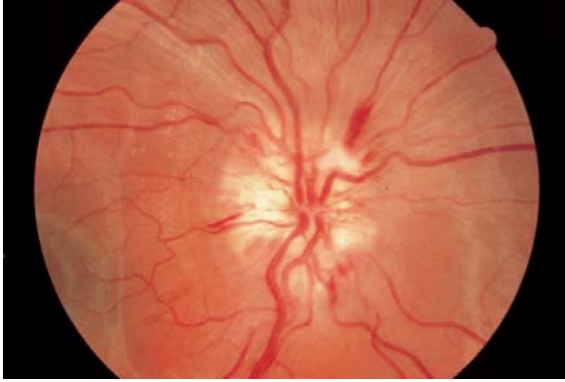

Fig. 13.11
a Papillitis in Lyme disease: The margin of the optic disk is slightly obscured by edema and hyperemia of the head of the optic nerve. The optic cup is obscured.

Continued →

13.3.2.3 Anterior Ischemic Optic Neuropathy (AION)

The following forms of anterior ischemic optic neuropathy (AION) are distinguished according to the cause of the disorder:

- ❖ **Arteriosclerotic** anterior ischemic optic neuropathy.
- ❖ **Arteritic** anterior ischemic optic neuropathy.

Arteriosclerotic Anterior Ischemic Optic Neuropathy

Definition

An acute disruption of the blood supply to the optic disk, i.e., optic disk infarction, resulting from vascular changes in arteriosclerosis.

Epidemiology: Arteriosclerotic AION is a common cause of sudden loss of visual acuity. The greatest incidence of this disorder is between the ages of 60 and 70. In contrast to arteritic AION, it can also occur in adults below the age of 60.

Etiology: The causes of the disorder lie in acute disruption of the blood flow through the lateral branches of the short posterior ciliary arteries and the ring of Zinn in the setting of severe arteriosclerosis. A narrow scleral canal, i.e., a small optic disk, is a predisposing factor. The disorder known as *diabetic papillopathy* also belongs to this group of disorders, although it has a better prognosis in terms of vision.



Papillitis (continued).

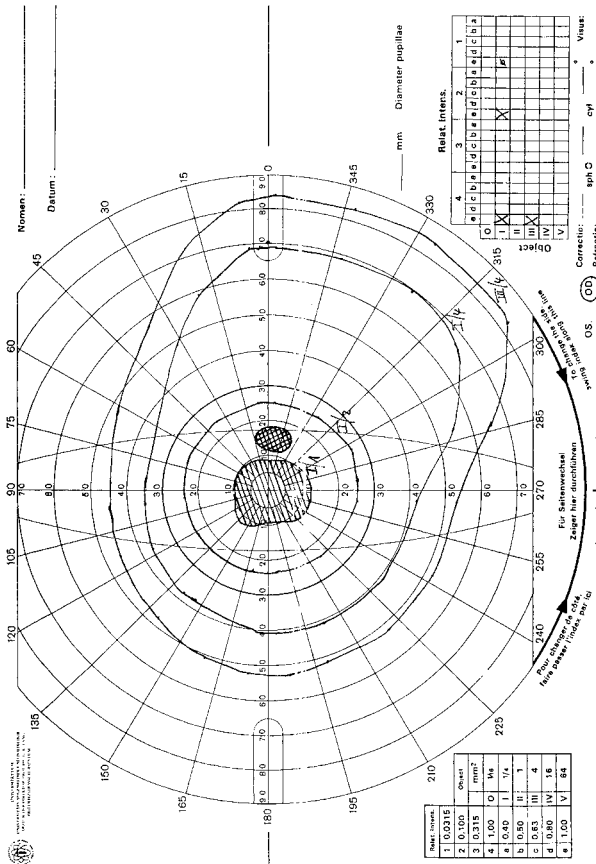


Fig. 13.11 b Central scotoma in papillitis: A central scotoma is a typical functional finding in retrobulbar optic neuritis but on that may also be observed in papillitis. In this case, a relative scotoma is present (indicated by single hatching), i.e., the patient is only unable to discern markers I/1 and weaker in central area whereas larger markers are visible (see also Fig. 13.10). The blind spot is also located next to this area.



Symptoms: Patients report a *sudden unilateral loss of visual acuity*. This is due to segmental or complete infarction of the anterior portion of the optic nerve. Severity is variable. The patient may present with wedge-shaped visual field defects (Fig. 13.12b) or horizontal visual field defects that correlate with segmental nerve fiber edemas. However, severe concentric defects progressing to total blindness can also occur. Vision may or not be impaired. An afferent pupillary defect is always present.

Diagnostic considerations: The patient will frequently have a history of hypertension, diabetes mellitus, or hyperlipidemia.

Ophthalmoscopy will reveal edema of the optic disk, whose margin will be accordingly obscured. The margin is often obscured in a segmental pattern, which is an important criterion in differential diagnosis (Fig. 13.12a). The head of the optic nerve is also hyperemic with marginal bleeding.

! Obscured segments of the margin of the optic disk that correlate with visual field defects are a sign of AION.

Treatment: Anterior ischemic optic neuropathy is nearly impossible to treat. Attempted methods include hemodilution (pentoxifylline infusions, acetylsalicylic acid, and bloodletting depending on hematocrit levels) and systemic administration of steroids to control the edema. Diagnosis of the underlying cause is important; examination by an internist and Doppler ultrasound studies of the carotid artery may be helpful. Underlying disorders such as diabetes mellitus or arterial hypertension should be treated.

Anterior ischemic optic neuropathy (AION).

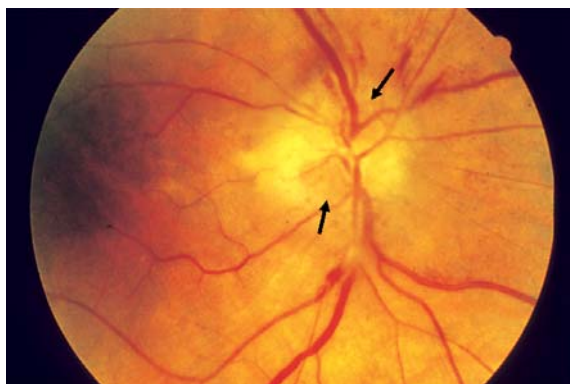

Fig. 13.12
a Superior and inferior segments of the margin of the optic disk are obscured (arrows) due to edema. This is a typical morphologic sign of AION.

Continued →



Anterior ischemic optic neuropathy (continued).

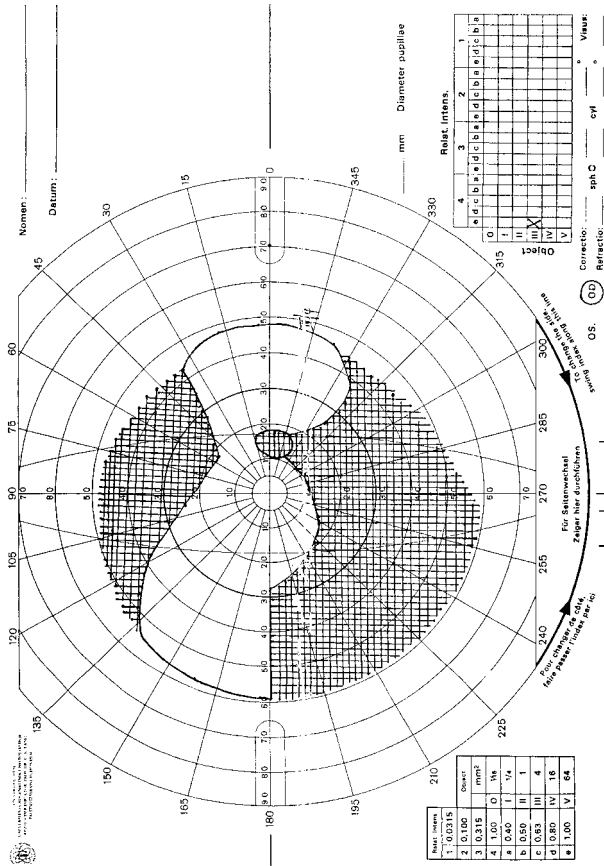


Fig. 13.12 b Superior and inferior wedge-shaped visual field defects correlate with obscured segments of the margin of the optic disk. As these are absolute scotomas they are indicated by crosshatching.



Prognosis: The prognosis is usually poor even where therapy is initiated early. Isolated atrophy of the optic nerve will appear within three weeks, complex atrophy of the optic nerve is less frequent but may also be observed.

Arteritic Anterior Ischemic Optic Neuropathy

Definition

An acute disruption of the blood supply to the optic disk due to inflammation of medium-sized and small arterial branches.

Epidemiology: The annual incidence is approximately three cases per 100 000. The disorder occurs almost exclusively after the age of 60. Women are affected slightly more often than men, accounting for 55% of all cases. Fifty per cent of all patients suffer from ocular involvement within a few days up to approximately three months of the onset of the disorder.

Etiology: Giant cell arteritis is a frequently bilateral granulomatous vasculitis that primarily affects the medium-sized and small arteries. Common sites include the temporal arteries, ophthalmic artery, short posterior ciliary arteries, central retinal artery, and the proximal portion of the vertebral arteries, which may be affected in varying combinations.

Symptoms: Patients report *sudden unilateral blindness or severe visual impairment*. Other symptoms include headaches, painful scalp in the region of the temporal arteries, tenderness to palpation in the region of the temporal arteries, pain while chewing (a characteristic sign), weight loss, reduced general health and exercise tolerance. Patients may have a history of amaurosis fugax or polymyalgia rheumatica.

Diagnostic considerations: The **ophthalmoscopic findings** are the same as in arteriosclerotic AION (see Fig. 13.12a). **Other findings** include a significantly increased erythrocyte sedimentation rate (precipitous sedimentation is the most important hematologic finding), an increased level of C-reactive protein, leukocytosis, and iron-deficiency anemia.



Erythrocyte sedimentation rate should be measured in every patient presenting with anterior ischemic optic neuropathy.

The temporal arteries are prominent (Fig. 13.13), painful to palpation, and have no pulse. The diagnosis is confirmed by a biopsy of the temporal artery. Because of the segmental pattern of vascular involvement, negative histologic findings cannot exclude giant cell arteritis.



Giant cell arteritis should be considered in every patient presenting with anterior ischemic optic neuropathy.



Prominent temporal arteries in temporal arteritis.

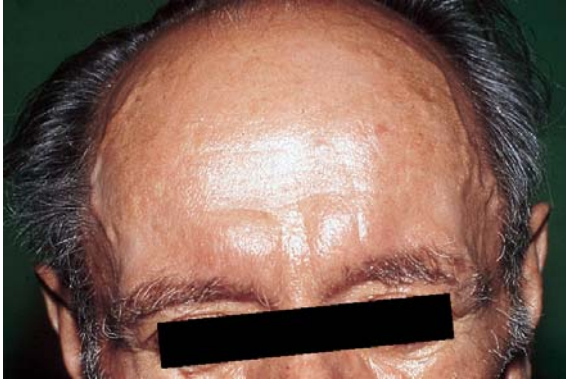

Fig. 13.13 The prominent temporal arteries are painful to palpation and have no pulse.

Differential diagnosis: Arteriosclerotic AION should be considered.

Treatment: *Immediate* high-dosage systemic steroid therapy (initial doses up to 1000 mg of intravenous prednisone) is indicated. Steroids are reduced as the erythrocyte sedimentation rate decreases, C-reactive protein levels drop, and clinical symptoms abate. However, a maintenance dose will be required for several months. Vascular treatment such as pentoxifylline infusions may be attempted.

! High-dosage systemic steroid therapy (for example 250 mg of intravenous prednisone) is indicated to protect the fellow eye even if a giant cell arteritis is only suspected.

Prognosis: The prognosis for the affected eye is *poor* even where therapy is initiated early. Immediate steroid therapy is absolutely indicated because in approximately 75% of all cases the fellow eye is affected within a few hours and cerebral arteries may also be at risk.

13.3.2.4 Infiltrative Optic Disk Edema

Infiltration of the optic disk occurs in about one in three cases of leukosis or other blood dyscrasias. This infiltration results in optic disk edema that is usually associated with infiltration of the meninges. The optic disk edema can therefore occur from both direct leukemic infiltration and secondary to increased pressure in the meninges of the optic nerve. The prognosis for both vision and survival is poor.



13.4 Disorders in which the Margin of the Optic Disk is Well Defined

13.4.1 Atrophy of the Optic Nerve

Definition

Irreversible loss of axons in the region of the third neuron (from the retinal layer of ganglion cells to the lateral geniculate body).

Morphology and pathologic classification: Atrophy of the optic nerve is classified according to its morphology and pathogenesis. The following forms are distinguished **on the basis of ophthalmoscopic findings:**

- ❖ Primary atrophy of the optic nerve.
- ❖ Secondary atrophy of the optic nerve.
- ❖ Glaucomatous atrophy of the optic nerve.

Forms of primary atrophy of the optic nerve may be further classified according to their **pathogenesis:**

- ❖ *Ascending* atrophy in which the lesion is located anterior to the lamina cribrosa in the ocular portion of the optic nerve or retina.
- ❖ *Descending* atrophy in which the lesion is located posterior to the lamina cribrosa in a retrobulbar or cranial location.

Etiology:

Etiology of primary atrophy of the optic nerve.

The most important causes are as follows:

- ❖ *Ascending atrophy (after two to four weeks):*
 - Usually vascular, such as central retinal artery occlusion or anterior ischemic optic neuropathy.
- ❖ *Descending atrophy (after four to six weeks):*
 - Compressive, such as from an orbital or intracranial mass or hydrocephalus.
 - Traumatic, such as avulsion, compression of the optic nerve in a fracture, or hematoma in the optic nerve sheath.
 - Inflammatory, such as retrobulbar optic neuritis, arachnoiditis of the optic chiasm, or syphilis.
- ❖ *Toxic:*
 - Chronic abuse of low-grade tobacco and alcohol in tobacco and alcohol amblyopia.
 - Lead, arsenic, or thallium.
 - Methyl alcohol.
 - Medications, such as ethambutol, chloramphenicol, gentamicin, isoniazid, vincristine, penicillamine, etc.



❖ **Congenital or hereditary:**

- Infantile hereditary optic atrophy (an autosomal dominant disorder with slow progressive loss of visual acuity, color vision defects, and visual field defects).
- Juvenile hereditary optic atrophy (similar to the infantile form only the onset is usually later, in the second decade of life).
- Leber's optic atrophy.
- Behr's infantile recessive optic atrophy.

❖ **Systemic disorders:**

- Hemorrhagic anemia or pernicious anemia.
- Leukosis.

Etiology of secondary atrophy of the optic nerve.

The most important causes are as follows:

- ❖ Papilledema.
- ❖ Anterior ischemic optic neuropathy.
- ❖ Papillitis.



The etiology of any atrophy of the optic nerve should be determined to exclude possible life-threatening intracerebral causes such as a tumor.

Symptoms: The spectrum of functional defects in optic atrophy is broad. These range from small peripheral visual field defects in partial optic atrophy to severe concentric visual field defects or blindness in total optic atrophy.

Diagnostic considerations: The most important examinations are a detailed history, ophthalmoscopy, and perimetry testing. Color vision testing and visual evoked potential may be useful as follow-up examinations in beginning optic atrophy.

Primary atrophy of the optic nerve. Ophthalmoscopy will reveal a well defined, pale optic disk (Fig. 13.14). The pallor can cover the entire optic disk (it will appear chalk white in total optic atrophy), or it may be partial or segmental. The neuroretinal rim is atrophied, which causes the optic disk to flatten out. The diameter of the retinal vessels will be decreased.

Secondary atrophy of the optic nerve. Ophthalmoscopy will reveal a pale optic disk. The disk is slightly elevated due to proliferation of astrocytes, and the margin is blurred (Fig. 13.15). The optic cup will be partially or completely obscured. The retinal vessels will be constricted.

Treatment: The disorder involves *irreversible* damage to the nerve fibers. As a result, no effective treatment is available.

Prognosis: Early identification and timely management of a treatable cause such as a tumor or pernicious anemia can arrest the progression of the disorder. Where this is not the case, the prognosis for vision is poor.



Primary atrophy of the optic nerve.

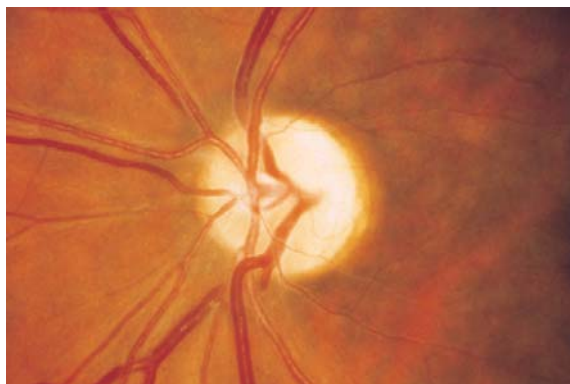


Fig. 13.14 The optic disk is well defined and pale. The neuroretinal rim is atrophied resulting in a flattened optic disk.

Secondary atrophy of the optic nerve.

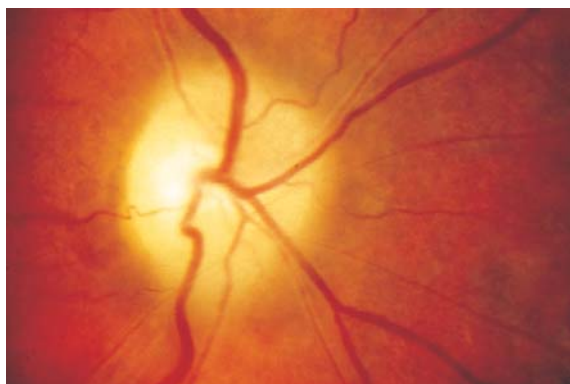

Fig. 13.15 The optic disk is elevated and pale due to proliferation of astrocytes.

Special Forms of Atrophy of the Optic Nerve

Leber's atrophy. Here there is involvement of both optic nerves *without additional neurologic symptoms*. In 85% of all cases, men between the ages of 20 and 30 are affected. The disorder is due to mutations in the mitochondrial DNA.

Ophthalmoscopy will reveal optic disk edema as in papillitis followed by primary optic nerve atrophy. Initial retrobulbar optic neuritis is also possible.



Functional symptoms include a large central scotoma with a peripherally limited visual field. This will lead to significant loss of vision within a few months, although the remaining vision will not decrease any further.

There is no *treatment*.

Behr's disease (infantile recessive optic atrophy). This is also a disorder involving both optic nerves. However, in contrast to Leber's atrophy there are *additional neurologic symptoms*. These may include ataxia and mental retardation. The disease is an inherited autosomal recessive disorder and manifests itself in early childhood.

Ophthalmoscopy will reveal progressive optic atrophy with severe loss of visual acuity but without complete blindness.

There is no *treatment*.

Waxy pallor optic atrophy. This disorder (Fig. 13.16) is associated with tapetoretinal degeneration, such as retinitis pigmentosa.

Ophthalmoscopy will reveal an *optic disk with a wax-like pallor* that is shallow with a well defined margin. There will be severe thinning of the central retinal vessels. The *cause of the wax-like yellow color is not known*.

There is no *treatment*.

13.4.2 Optic Nerve Pits

An optic nerve pit (Fig. 13.17) is characterized by a **round or oval grayish depression in the papillary tissue that does not compromise the margin of the optic disk**. These pits are usually found in an inferior temporal location, although they do occur elsewhere. In 85% of all cases, one eye is affected.

Waxy pallor optic atrophy.

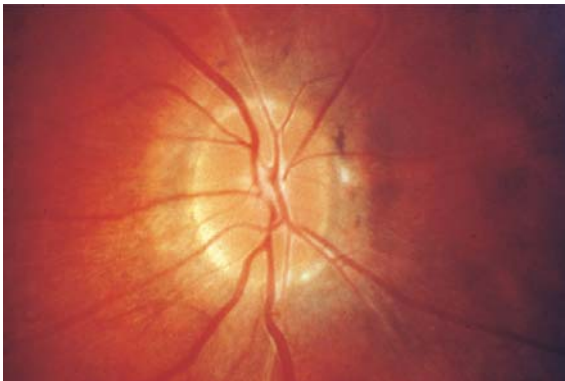

Fig. 13.16 Waxy pallor optic atrophy is associated with tapetoretinal degeneration.



Optic nerve pits.

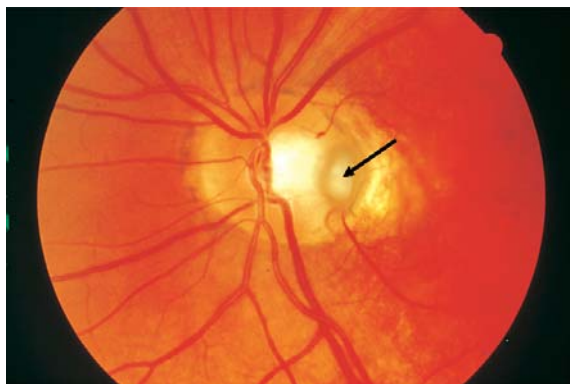


Fig. 13.17 These are oval grayish temporal depressions in the papillary tissue (arrow).

Several pits in one optic disk have been described. Serous retinal detachment occurs in 25% of all cases, depending on the location of the pit. Where the detachment affects the macula, a significant loss of visual acuity will result that will prove very difficult to manage with laser surgery. Otherwise optic nerve pits are an *incidental finding without any functional deficit*. They are considered to be rudimentary colobomas.

Optic disk coloboma.

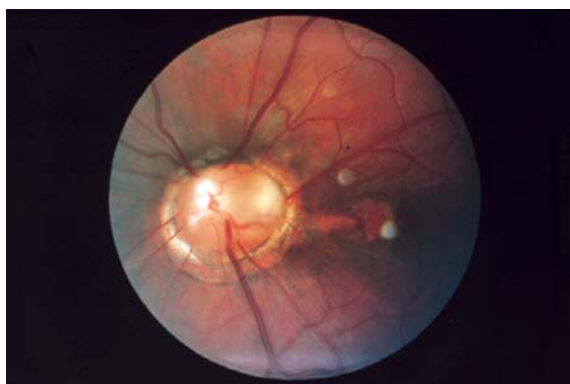


Fig. 13.18 The optic disk is enlarged with a funnel-shaped depression with whitish tissue and a peripapillary pigment ring. The retinal vessels do not branch from a central venous or arterial trunk.



13.4.3 Optic Disk Coloboma (Morning Glory Disk)

An optic disk coloboma (Fig. 13.18) is the result of incomplete closure of the embryonic optic cup. The optic disk is enlarged with a funnel-shaped depression with whitish tissue and a peripapillary pigment ring. The retinal vessels extend outward across the margin of the disk in a radial pattern without a central trunk vessel. Patients with optic disk coloboma often have *decreased visual acuity and visual field defects*.

13.5 Tumors

Optic nerve tumors are classified as **intraocular** or **retrobulbar tumors**. Intraocular tumors are rare.

13.5.1 Intraocular Optic Nerve Tumors

Melanocytoma (Fig. 13.19): These are benign pigmented tumors that primarily occur in blacks. The color of the tumor varies from gray to pitch black. It is often eccentric and extends beyond the margin of the optic disk. In 50% of all cases, one will also observe a peripapillary choroidal nevus. Visual acuity is usually normal, although discrete changes in the visual field may be present.

Astrocytoma (Fig. 13.20): Astrocytomas appear as white reflecting “mulberry” masses that can calcify. Their size can range up to several disk diameters. The tumor is highly vascularized. Visual field defects can result where the tumor is sufficiently large to compress the optic nerve. Astrocytomas

Melanocytoma.

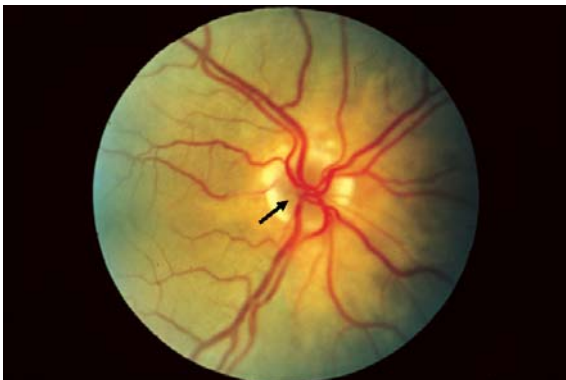

Fig. 13.19 Benign tumor of the optic disk that represents a special form of nevus (arrow).



Astrocytoma in tuberous sclerosis (Bourneville's disease).

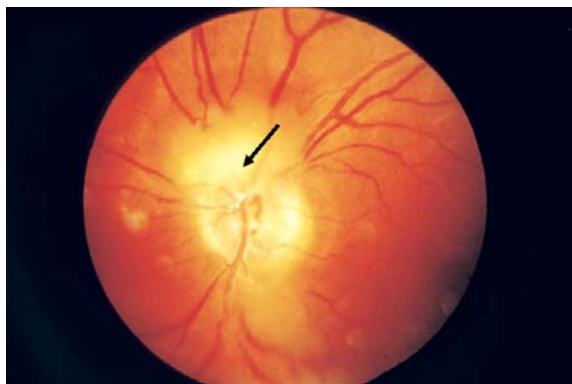

Fig. 13.20
Whitish, "mulberry" tumor on the superior margin of the optic disk (arrow).

occur in tuberous sclerosis (Bourneville's disease) and neurofibromatosis (Recklinghausen's disease).

Hemangioma (Fig. 13.21): Capillary hemangiomas are eccentric, round orange-colored vascular deformities on the optic disk (von Hippel disease). They may occur in association with other angiomas, for example in the cerebellum (in von Hippel-Lindau disease).

Capillary hemangioma in von Hippel disease.

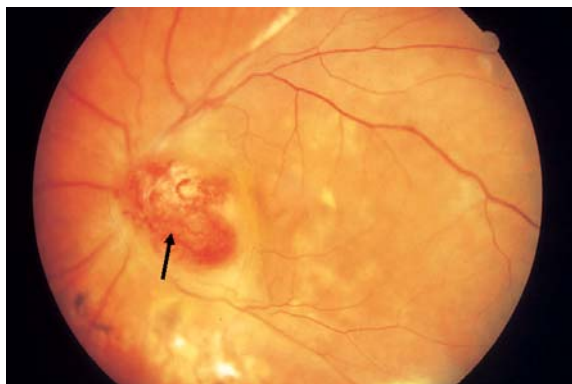

Fig. 13.21
Eccentric capillary vascular deformity on the optic disk (arrow).

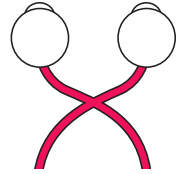


13.5.2 Retrobulbar Optic Nerve Tumors

The most common retrobulbar optic nerve tumors are **gliomas** and **meningiomas**. *Symptoms* include a usually slow loss of visual acuity with exophthalmos. *Ophthalmoscopy* will reveal descending primary atrophy of the optic nerve. *Meningioma of the sheath of the optic nerve* is typically accompanied by the formation of opticociliary shunt vessels with compression of the central retinal vessels.

14 Visual Pathway

Oskar Gareis and Gerhard K. Lang



14.1 Basic Knowledge

The anatomy of the visual pathway may be divided into six separate parts (Fig. 14.1):

- 1. Optic nerve:** This includes all of the optic nerve fiber bundles of the eye.
 - 2. Optic chiasm:** This is where the characteristic crossover of the nerve fibers of both optic nerves occurs. The *central and peripheral fibers* from the temporal halves of the retinas *do not cross* the midline but continue into the optic tract of the *ipsilateral side*. The *fibers of the nasal halves cross the midline* and there enter the *contralateral* optic tract. Along the way, the inferior nasal fibers travel in a small arc through the proximal end of the contralateral optic nerve (the anterior arc of Wilbrand). The superior nasal fibers travel in a small arc through the ipsilateral optic tract (the posterior arc of Wilbrand).
 - 3. Optic tract:** This includes all of the *ipsilateral optic nerve fibers and those that cross the midline*.
 - 4. Lateral geniculate body:** The optic tract ends here. The third neuron connects to the fourth here, which is why atrophy of the optic nerve does not occur in lesions beyond the lateral geniculate body.
 - 5. Optic radiations** (geniculocalcarine tracts): The fibers of the *inferior retinal quadrants* pass through the temporal lobes; those of the *superior quadrants* pass through the parietal lobes to the occipital lobe and from there to the visual cortex.
 - 6. Primary visual area** (striate cortex or Brodmann's area 17 of the visual cortex): The *nerve fibers diverge* within the primary visual area; the macula lutea accounts for most of these fibers. The macula is represented on the most posterior portion of the occipital lobe. The central and intermediate peripheral regions of the visual field are represented anteriorly. The temporal crescent of the visual field, only present unilaterally, is represented farthest anteriorly.
- Other connections extend from the visual cortex to associated centers and oculomotor areas (**parastriate** and **peristriate areas**). Aside from the optic tract there is also another tract known as the **retinohypothalamic tract**. This



Anatomy of the visual pathway.

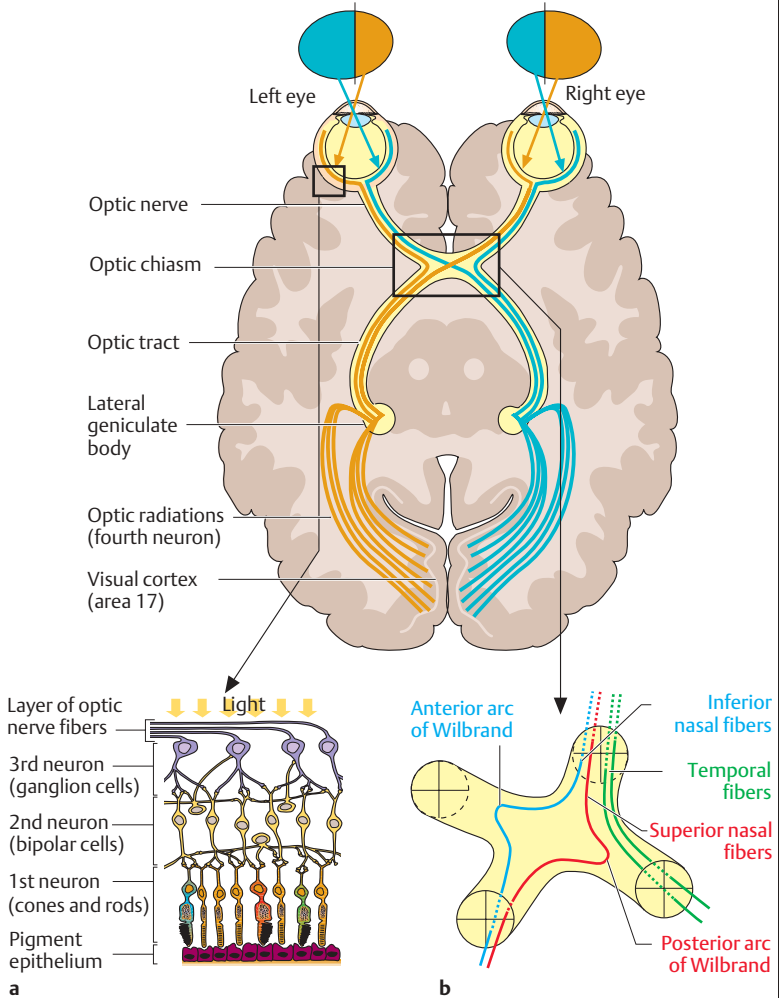


Fig. 14.1 a Overview of the course of the visual pathway. b Structure of the retina. c Course of the nerve fibers in the optic chiasm.



tract is older in evolutionary terms and diverges from the optic chiasm. It transmits light impulses for metabolic and hormonal stimulation to the diencephalon and pituitary gland system and influences the circadian rhythm.

14.2 Examination Methods

Visual field testing (perimetry): This is the most important test for visual pathway lesions. Because it permits one to diagnose the location of the lesion, it is also of interest from a neurologic standpoint. The “**visual field**” is defined as the *field of perception of the eye at rest with the gaze directed straight ahead*. It includes all points (objects and surfaces) in space that are simultaneously visible when the eye focuses on *one point*.

The examination is performed on *one eye at a time*. The **principle** of the test is to have the patient focus on a central point in the device while the eye is in a defined state of adaptation with controlled ambient lighting (see below). Light markers appear in the hemisphere of the device. The patient signals that he or she perceives the markers by pressing a button that triggers an acoustic signal.

There are two types of perimetry.

1. Kinetic perimetry. *Hemispheric Goldmann* or *Rodenstock* perimeters are used for this test (Fig. 14.2). Kinetic perimetry involves *moving* points of light that travel into the hemisphere from the periphery. Light markers of identical size and intensity produce concentric rings of identical perception referred to as *isopters*. The points of light decrease in size and light intensity as they move toward the center of the visual field, and the isopters become correspondingly smaller (Fig. 14.2b). This corresponds with the sensitivity of the retina, which increases from the periphery to the center.

The advantage of kinetic perimetry is the personal interaction between physician and patient. This method is especially suitable for older patients who may have difficulties with a stereotyped interaction required by a computer program. *Specific indications* for kinetic perimetry include visual field defects due to neurologic causes and examinations to establish a disability (such as hemianopsia or quadrantic anopsia).

2. Static perimetry. This is usually performed with computerized equipment such as the *Humphrey field analyzer* (Fig. 14.3) or *Octopus 2000*, although a Goldmann or Rodenstock hemispheric perimeter can also be used for static testing of the visual field. In static perimetry, the light intensity of *immobile* light markers is increased until they are perceived. The intensity threshold continuously increases from the macula, with the highest sensitivity, to the periphery. A variety of different computer programs can be selected depending on the specific clinical setting. These include the outer margins or the 30 degree visual field in glaucoma (Fig. 14.3b).



Goldmann hemispheric perimeter and visual field findings.

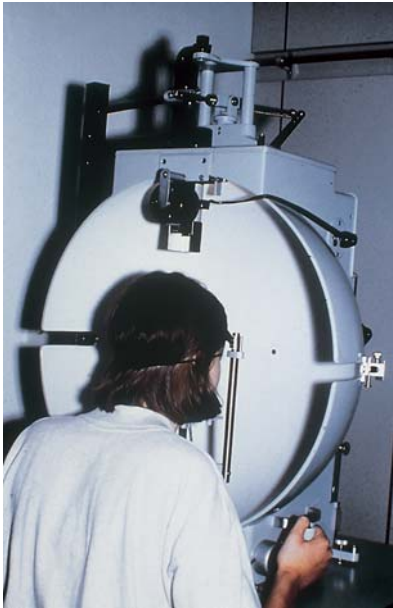

Fig. 14.2 a The patient focuses with one eye on a black dot in the middle of the hemisphere. As soon as the patient notices the light marker moving in from the periphery, he or she presses a button that triggers an acoustic signal. The examiner sits behind the hemisphere. From there, the examiner controls the light marker and records which points the patient recognizes.

Continued →

Other examination methods:

- ❖ Pupillary findings.
- ❖ Pupillary light reflex.
- ❖ Visual evoked potential.
- ❖ CT or MRI to diagnose causes.



Goldmann hemispheric perimeter and visual field findings.

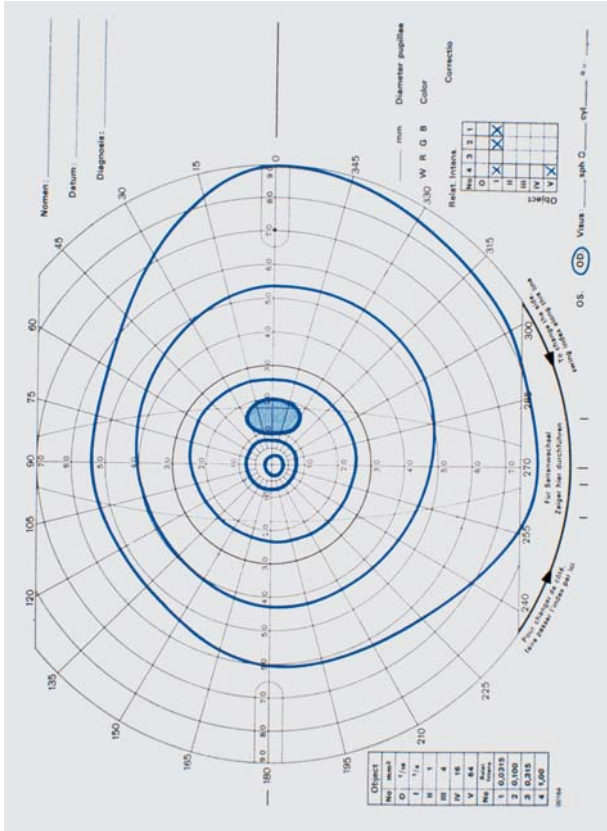


Fig. 14.2 b Normal visual field. Due to the anatomy of the bridge of the nose and roof of the orbit, the visual field is physiologically limited in the nasal and superior regions. The blind spot (optic disk) normally lies 10 to 20 degrees off center in the horizontal plane, on the right in the right eye and on the left in the left eye.



Humphrey field analyzer and visual field findings.



Fig. 14.3 a In static perimetry, the patient also focuses on a black dot in the middle of the hemisphere. As soon as the patient perceives a light marker, he or she presses a button that triggers an acoustic signal. The result is shown on the monitor on the right.

Continued →

14.3 Disorders of the Visual Pathway

Lesions of the visual pathway may be classified according to three main locations.

1. Prechiasmal lesions (lesions of the optic nerve) involve visual field defects on the same side.
2. Chiasmal lesions (disorders of the optic chiasm) typically cause bilateral temporal hemianopsia but can also cause unilateral or bilateral visual field defects (see below).
3. Retrochiasmal lesions (disorders of visual pathway posterior to the optic chiasm, i.e., from the optic tract to the visual cortex) cause homonymous visual field defects.

14.3.1 Prechiasmal Lesions

Disorders of the optic nerve lead to an ipsilateral decrease in visual acuity and/or visual fields defects (see Chapter 13).



Humphrey field analyzer and visual field findings.

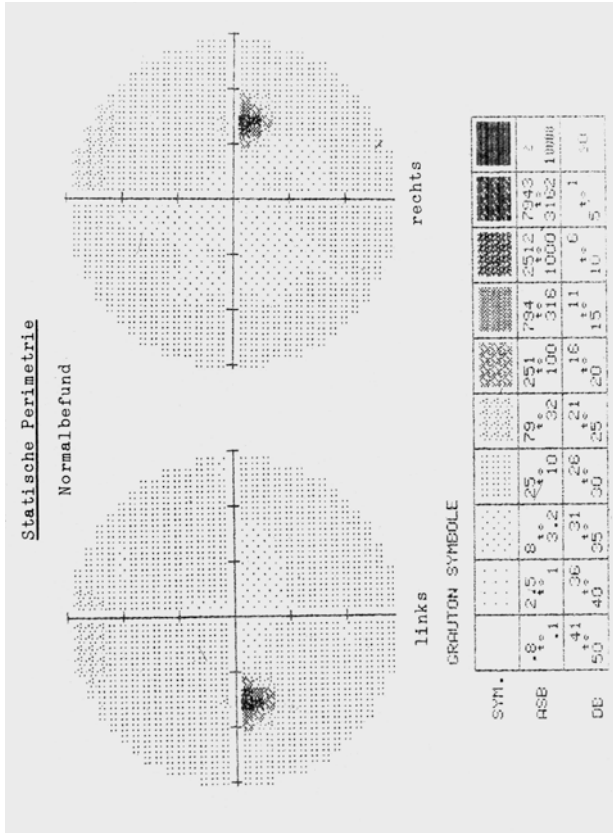


Fig. 14.3 **b** Normal visual field in the left and right eyes in the 30 degree range. The severity of the visual field defect is depicted with increasing gray scales. These correspond to specific light intensities (ASB stands for apostilb) and are graphed as logarithmic values (DB stands for decibel) to better visualize the retinal sensitivity. The dark area in both graphs represents the blind spot.



14.3.2 Chiasmatal Lesions

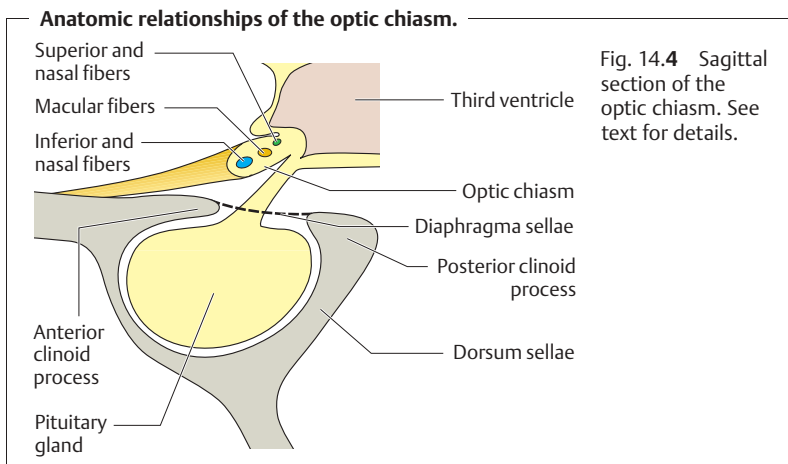
Anatomy: The optic chiasm and the optic nerves (Fig. 14.4) lie on the diaphragma sellae, a dural fold that forms the roof of the sella turcica.

The pituitary gland in the sella turcica lies **inferior to the chiasm**. The internal carotid artery defines the **lateral border of the chiasm**. The hypothalamus and anterior lobe of the cerebrum are located **superior to the chiasm**. **Within the chiasm**, the inferior nasal fibers cross inferiorly and anteriorly, and are therefore most likely to be affected by *pituitary tumors*. The superior nasal fibers cross posteriorly and superiorly within the chiasm and are therefore most likely to be affected by *craniopharyngiomas*. The macular fibers cross in various locations throughout the chiasm, including posteriorly and superiorly.

Etiology and corresponding visual field defects:

Pituitary adenomas: These are tumors that proceed from the hormone-secreting cells of the anterior lobe of the pituitary gland. As they increase in size superiorly, they reach the anterior margin of the chiasm where they compress the inferior and nasal fibers that cross there (Fig. 14.5). This leads to an *initial visual field defect* in the superior temporal quadrant that may later progress to complete bilateral temporal hemianopsia. The visual field defect usually spreads in an asymmetrical pattern. The eye with the more severe visual field defect often exhibits the lesser central visual acuity.

Craniopharyngiomas. These slow-growing tumors develop from tissue of the pouch of Rathke (the pituitary diverticulum) along the stem of the pituitary gland. Craniopharyngiomas compress the optic chiasm posteriorly and supe-





Inferior compression of the optic chiasm by a pituitary adenoma.

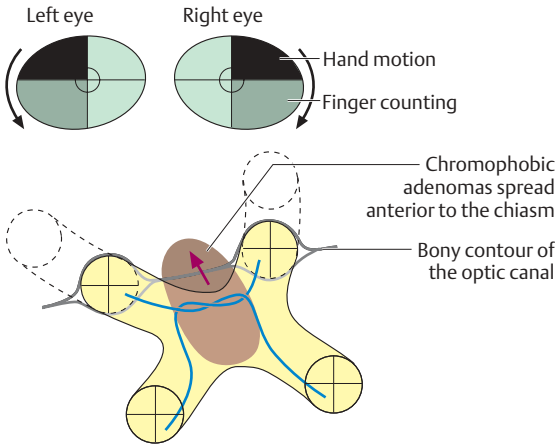


Fig. 14.5 The visual field defect begins as a bilateral superior temporal defect and may progress to complete bilateral temporal hemianopsia. The terms “finger counting” and “hand motion” describe the patient’s visual perception.

Superior compression of the optic chiasm by a craniopharyngioma.

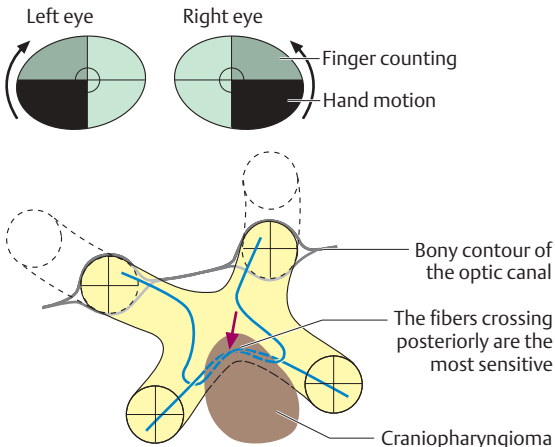


Fig. 14.6 The visual field defect begins bilaterally in the inferior temporal quadrants and can progress to complete bilateral temporal hemianopsia.

riorly and therefore primarily affect the superior nasal fibers that cross there (Fig. 14.6). The corresponding *visual field defect* begins in the inferior temporal quadrants and then spreads into the superior temporal quadrants.



Meningiomas. These are tumors that proceed from the arachnoid. They may affect various different parts of the chiasm depending on the site of their origin (Fig. 14.7). When they occur on the tuberculum sellae, they can compress either the optic nerve or the chiasm. Tumors that compress the junction of the optic nerve and chiasm simultaneously compress the fibers in the arc of Wilbrand. In addition to the ipsilateral central scotoma, this produces a contralateral *visual field defect* in the superior temporal quadrants. Meningiomas can also proceed from the margin of the sphenoid and compress the optic nerve. Those that originate along the olfactory tract can lead to a loss of sense of smell and to compression of the optic nerve.

Aneurysms. Dilation of the internal carotid artery due to an aneurysm can result in lateral compression of optic chiasm (Fig. 14.8). The resulting *visual field defect* begins unilaterally but can become bilateral if the chiasm is pressed against the contralateral internal carotid artery. Initially there is ipsilateral hemianopsia extending nasally. This is followed by compression of the contralateral side with contralateral hemianopsia that also extends nasally.

Other changes in the chiasm. Aside from the external effects on the chiasm, changes can occur within the chiasm itself. These include gliomas, demyelination, and trauma. The chiasm can also be involved in infiltrative or inflammatory changes of the basal leptomeninges (arachnoiditis of the optic chiasm). The resulting *visual field defects are highly variable*.

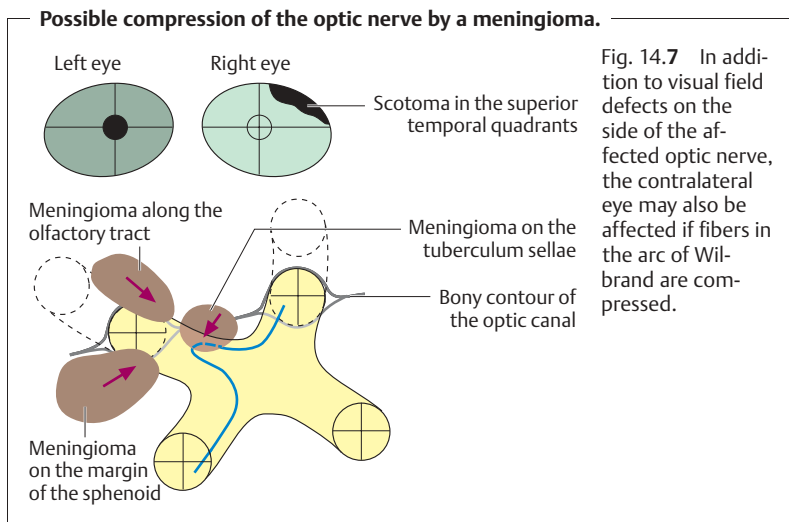


Fig. 14.7 In addition to visual field defects on the side of the affected optic nerve, the contralateral eye may also be affected if fibers in the arc of Wilbrand are compressed.



Lateral compression of the optic chiasm by an aneurysm in the internal carotid artery.

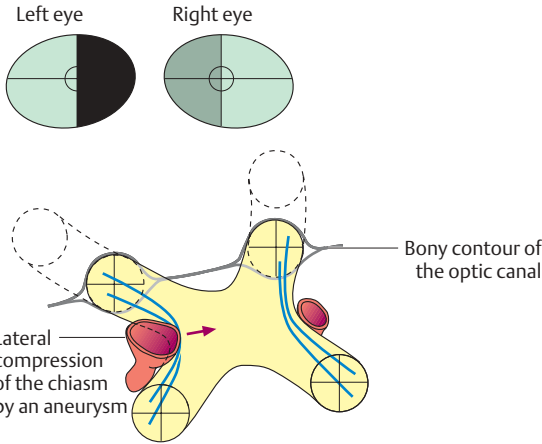


Fig. 14.8 The visual field defect begins on the same side as hemianopsia extending nasally and can progress to bilateral nasal hemianopsia.

Symptoms, diagnostic considerations, and clinical picture: The compression of the optic nerve produces **primary descending atrophy of the optic nerve**. This is associated with a more or less severe **decrease in visual acuity and visual field defects** (see Etiology). A visual field defect consisting of heteronymous bilateral temporal hemianopsia is referred to as **chiasm syndrome**. The visual field defects in these cases are frequently incongruent. Chiasm syndrome develops *slowly* and usually represents the late stage of a pituitary adenoma or craniopharyngioma.

❗ Heteronymous bilateral temporal hemianopsia with decreased visual acuity and unilateral or bilateral optic nerve atrophy is referred to as chiasm syndrome.

Bilateral temporal visual field defects are typical for chiasmal processes. However, the many possible locations of lesions in the region of the chiasm produce widely varying visual field defects depending on the specific etiology.

❗ Bilateral temporal visual field defects are due to chiasmal lesions. A chiasmal lesion should always be considered in the presence of any uncertain visual field defect.

Further diagnostic studies may be performed after visual acuity testing, pupillary light reaction testing, perimetry, and ophthalmoscopy of the fundus and optic disk. Such studies include radiographs of the sella turcica (to detect



enlargement or destruction of the sella turcica due to a pituitary adenoma), CT, MRI, carotid arteriography, and, in applicable cases, endocrinologic studies.

Treatment: This depends on the underlying cause. Neurosurgery may be indicated or medication, such as bromocriptine for a pituitary tumor.

Prognosis: This also depends on the underlying disorder. Ocular functional deficits may subside when the disorder is promptly diagnosed and treated.

14.3.3 Retrochiasmal Lesions

Etiology: Retrochiasmal lesions may result from a wide variety of **neurologic disorders** such as tumors, vascular insults, basal meningitis, aneurysms of the posterior communicating artery, abscesses, injuries (such as a contrecoup injury to the occipital lobe), and vasospasms (in an ocular migraine).

Symptoms, diagnostic considerations, and clinical picture: Visual field testing in particular will provide information on the location of the lesion. **Perimetry** is therefore a crucial diagnostic study. *Bilateral simultaneous visual field defects* are common to all retrochiasmal lesions of the visual pathway. Often these defects will be incongruent.



Homonymous visual field defects are the result of a retrochiasmal lesion.

Lesions of the optic tract and the lateral geniculate body. Because the nerve fibers are concentrated in a very small space, the visual field defect that occurs typically in these lesions is homonymous hemianopsia. Lesions on the right side produce visual field defects in the left half of the visual field and vice versa. Partial primary atrophy of the optic nerve may occur as the third neuron is affected, which extends from the retina to the lateral geniculate body. An *afferent pupillary defect on the side opposite the lesion* will be present. The cause of this defect is not known.

Lesions of the optic radiations. The *visual field defects* assume *many different forms* due to the wide spread of the optic radiations. Injuries to both the temporal and parietal lobes typically produce *homonymous hemianopsia*. Injuries primarily involving the temporal lobe produce homonymous *superior* quadrant anopsia; injuries primarily involving the parietal lobe produce homonymous *inferior* quadrant anopsia. Pupillary findings are normal because the lesion affects the fourth neuron. Approximately 30% of all cases involve an *afferent pupillary defect on the side opposite the lesion*. The cause of this defect is not known.

Lesions of the visual cortex. The visual field defects, like the lesions of the visual pathway, are *homonymous and hemianoptic*. The macula may or may not be affected depending on the extent of the lesion.

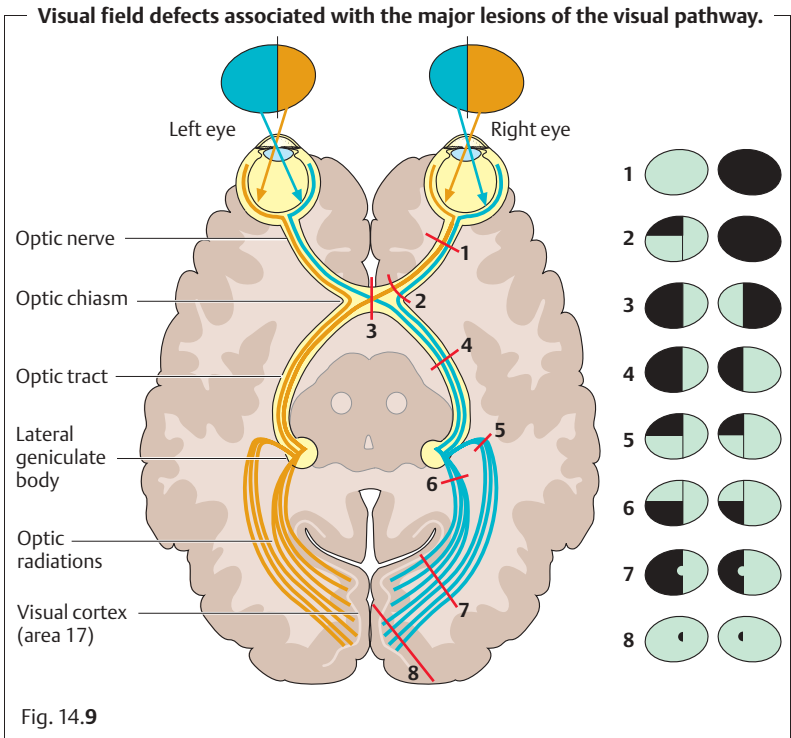


Special forms.

Cortical blindness. Bilateral lesions of the visual cortex, especially injuries, can produce both temporal and nasal visual field defects with *normal pupillary light reaction* and *normal optic disk findings*.

Visual agnosia. Where the association areas of the brain are damaged, as often occurs in lesions of the parietal lobe or marginal visual cortex, the patient can see but is unable to interpret or classify visual information. Examples of this include alexia (acquired inability to comprehend written words) and color agnosia (inability to distinguish colors).

Other symptoms and findings. Depending on the underlying disorder, these may include headache, nausea, vomiting, and papilledema. A differential diagnosis requires CT and MRI studies.





Treatment: Depending on the underlying disorder, the patient is referred to either a neurologist or neurosurgeon for treatment.

Prognosis: The prognosis is generally poor, and the visual field defects usually do not subside.

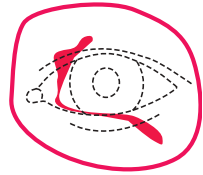
Ocular Migraine

This is due to a **transient vasospasm of the posterior cerebral artery** that supplies the visual cortex. **Symptoms** vary. Typically there will be a unilateral homonymous and initially paracentral scintillating scotoma, a series of flashes of bright light (fortification spectra), and perceptions of dazzling colors. Headache, nausea, and vertigo also occur. Paresis of the ocular muscles (*ophthalmoplegic migraine*) may also occur. **Treatment:** Patients should be referred to a neurologist.

Fig. 14.9 provides a **schematic overview** of all major lesions of the visual pathway with their associated visual field defects.

15 Orbital Cavity

Christoph W. Spraul and Gerhard K. Lang



15.1 Basic Knowledge

Importance of the orbital cavity for the eye: The orbital cavity is the *protective bony socket* for the globe together with the optic nerve, ocular muscles, nerves, blood vessels, and lacrimal gland. These structures are surrounded by orbital fatty tissue. The orbital cavity is shaped like a *funnel* that opens anteriorly and inferiorly. The six ocular muscles originate at the apex of the funnel around the optic nerve and insert into the globe. The globe moves within the orbital cavity as in a *joint socket*.

Bony socket: This consists of seven bones (Fig. 15.1):

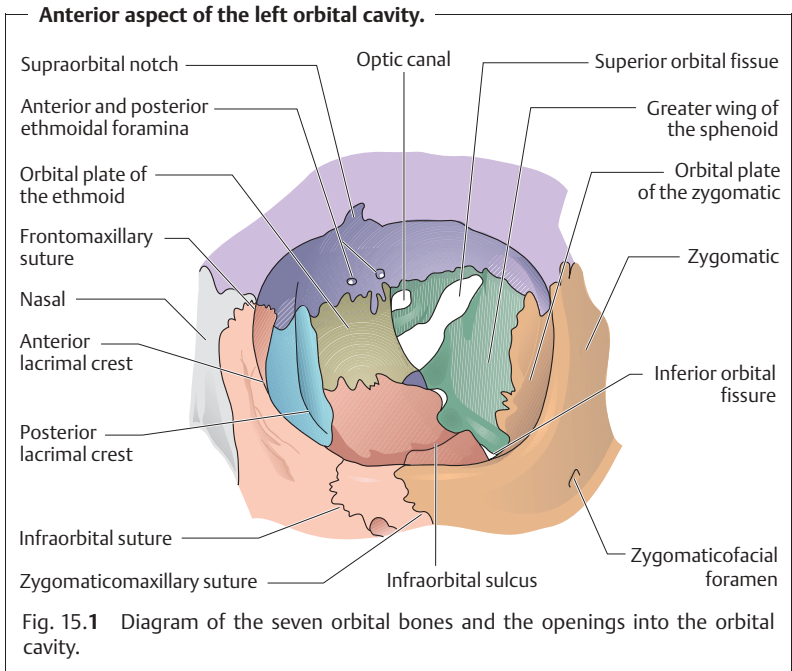
- ❖ Frontal.
- ❖ Ethmoid.
- ❖ Lacrimal.
- ❖ Sphenoid.
- ❖ Maxillary.
- ❖ Palatine.
- ❖ Zygomatic.

The bony rim of the orbital cavity forms a strong ring. Its other bony surfaces include very thin plates of bone (see adjacent structures).

Adjacent structures: The close proximity of the orbital cavity to adjacent structures is clinically significant. The **maxillary sinus** inferior to the orbital cavity is separated from it by a plate of bone 0.5 mm thick. The **ethmoidal air cells** located medial and posterior to the orbital cavity are separated from it by a plate of bone only 0.3 mm thick *or by periosteum alone*. The following other structures are also located *immediately adjacent to the orbital cavity*.

- ❖ **Sphenoidal sinus.**
- ❖ **Middle cranial fossa.**
- ❖ **Region of the optic chiasm.**
- ❖ **Pituitary gland.**
- ❖ **Cavernous sinus.**

Superior adjacent structures include the **anterior cranial fossa** and the **frontal sinus**. Table 15.1 lists the various bony openings into the orbital cavity and



the anatomic structures that pass through them. Because of this anatomic situation, the orbital cavity is frequently affected by disorders of adjacent structures. For example, inflammations of the paranasal sinuses can result in orbital cellulitis.

The walls of the orbital cavity are lined with periosteum, which is also referred to as periorbita. Its anterior boundary is formed by the orbital septa extending from the orbital rim to the superior and inferior tarsal plates, the lateral and medial palpebral ligaments, and the eyelids.

Arterial supply: The orbital cavity is supplied by the **ophthalmic artery**, a branch of the internal carotid artery. The ophthalmic artery communicates with the angular artery, a branch of the external carotid artery, via the supraorbital and supratrochlear arteries.



Stenosis of the internal carotid artery can result in reversed blood flow through the supraorbital and supratrochlear arteries. This can be demonstrated by Doppler ultrasound studies.



Table 15.1 Openings into the orbital cavity and the structures that pass through them

Orbital openings	Structures
Optic canal	<ul style="list-style-type: none"> ❖ Optic nerve ❖ Ophthalmic artery
Superior orbital fissure	<ul style="list-style-type: none"> ❖ Oculomotor nerve ❖ Trochlear nerve ❖ Abducent nerve ❖ Ophthalmic nerve: <ul style="list-style-type: none"> – Lacrimal nerve – Frontal nerve – Nasociliary nerve ❖ Superior ophthalmic veins
Inferior orbital fissure	<ul style="list-style-type: none"> ❖ Infraorbital nerve ❖ Zygomatic nerve ❖ Inferior ophthalmic vein
Infraorbital canal	<ul style="list-style-type: none"> ❖ Infraorbital nerve

Venous drainage from the orbital cavity: The orbital cavity drains through the **inferior ophthalmic vein** into the pterygoid plexus, through the **superior ophthalmic vein** into the cavernous sinus, and through the **angular vein** into the facial veins.

15.2 Examination Methods

Cardinal symptoms: Unilateral or bilateral **enophthalmos** (recession of the eyeball within the orbital cavity) or **exophthalmos** (protrusion of the eyeball) are characteristic of many orbital disorders (Table 15.2). These conditions should be distinguished from **pseudoexophthalmos** due to a long eyeball in severe myopia, and **pseudoenophthalmos** due to a small eyeball, such as in microphthalmos or phthisis bulbi.

The following list of examination techniques begins with the simple standard techniques and progresses to the difficult, more elaborate methods. As a general rule, orbital disorders require interdisciplinary cooperation between ENT specialists, neurologists, neurosurgeons, neuroradiologists, internists, nuclear medicine specialists, and oncologists.



Table 15.2 Causes for exophthalmos and enophthalmos listed according to clinical syndromes of similar etiology. Both the groups themselves and the disorders within each group are listed in descending order of incidence

Change in position	Causes
Exophthalmos (protrusion of the eyeball)	<ul style="list-style-type: none">❖ Graves' disease (most frequent cause) Inflammatory orbital disorders <ul style="list-style-type: none">❖ Orbital cellulitis (most frequent cause in children)❖ Orbital pseudotumor (autoimmune disorder)❖ Myositis of the ocular muscles (special form of pseudotumor)❖ Orbital abscess❖ Cavernous sinus thrombosis (serious clinical syndrome)❖ Severe tenonitis (inflammation of Tenon's capsule)❖ Mucocele❖ Mycosis (in immunocompromised patients)❖ Parasitic infestation of the orbital cavity (rare) Vascular orbital disorders <ul style="list-style-type: none">❖ Arteriovenous fistulas (pulsating)❖ Orbital hematomas (usually post-traumatic)❖ Orbital varices (intermittent exophthalmos) Orbital tumors (slowly progressive)
Enophthalmos	Developmental anomalies <ul style="list-style-type: none">❖ Craniosynostosis (premature fusion of cranial sutures)❖ Meningoencephalocele (very rare)❖ Osteopathy (rare) Orbital fractures (most frequent cause) <ul style="list-style-type: none">❖ Blowout fracture not associated with an orbital hematoma Neurogenic causes <ul style="list-style-type: none">❖ Horner's syndrome (sympathetic palsy)❖ Paresis of the oblique ocular muscles Atrophy of orbital tissue (symmetrical) <ul style="list-style-type: none">❖ Senile atrophy of the orbital fat❖ Dehydration

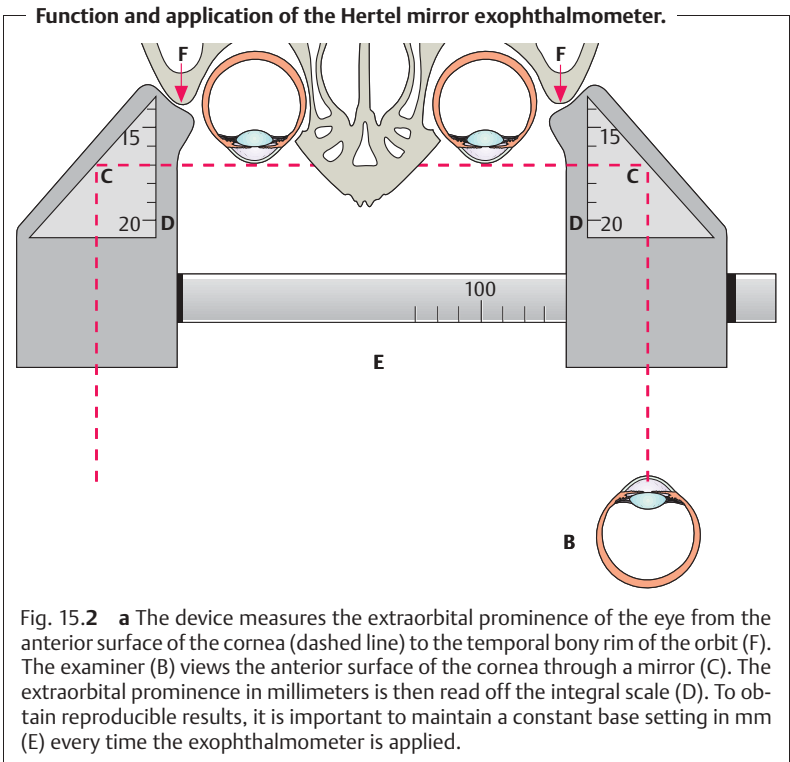


Visual acuity: See Chapter 1.

Ocular motility: The pattern of disturbed ocular motility can be a **sign of the cause of the disorder**. Causes may be neurogenic, myogenic, or mechanical (see Chapter 17).

Examination of the fundus: Retrobulbar processes can press the globe inward. This often produces **choroidal folds that are visible upon ophthalmoscopy**. Compression of the optic nerve by a tumor may result in **optic nerve atrophy or edema**. Meningiomas in the sheath of the optic nerve lead to the development of **shunt vessels on the optic disk**.

Exophthalmometry: The *Hertel mirror exophthalmometer* (Figs. 15.2a and b) measures the anterior projection of the globe beyond the orbital rim. A



Continued →



Function and application of the Hertel mirror exophthalmometer (continued).

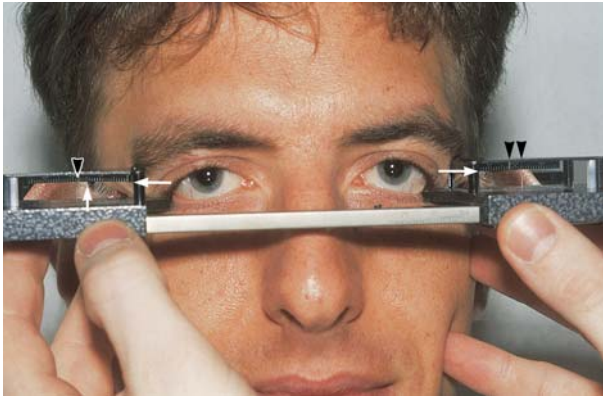

Fig. 15.2 **b** The exophthalmometer is placed on the lowest point of the temporal zygomatic. To avoid parallax measurement errors, the examiner moves his or her own eye horizontally until the two integral graduations (black arrowheads on the right) align in the projection (black left arrow). Once the graduations are aligned, the examiner reads the value of the extraorbital prominence of the anterior surface of the cornea (long white arrow) on the scale (short white arrows). The examiner reads the measurement with only one eye. The examiner uses his or her left eye to read the value for the patient's right eye and vice versa.

change in the position of the globe with respect to the orbital rim is a cardinal symptom of many orbital disorders (see Table 15.2).



The difference between the two sides is more important than the absolute value. A difference greater than 3 mm between the two eyes is abnormal. Unilateral exophthalmos is recognizable without an exophthalmometer. To do so, the examiner stands behind the patient, slightly lifts the patient's upper eyelids, and looks down over the patient's forehead toward the cheek.

Visual field testing: This is used to **document damage to the optic nerve** in orbital disorders.

Ultrasound studies: Two techniques are available for this noninvasive examination.

1. The **B-mode scan** (B stands for **b**rightness) provides a *two-dimensional image of orbital structures*. This examination is indicated in the presence of suspected orbital masses.



2. The **A-mode scan** (A stands for **amplitude**) permits *precise measurement of optic nerve and muscle thickness*. This examination is indicated as a follow-up study in the presence of Graves' disease (endocrine orbitopathy).

These studies may also be combined with **Doppler scans** to evaluate blood flow.

Conventional radiographic studies: These studies usually only provide information about the **nature of bone structures**, i.e., whether a fracture is present and where it is located. Smaller fractures often cannot be diagnosed by conventional radiography and require CT scans.

Computed tomography and magnetic resonance imaging: These modern examination modalities can precisely visualize orbital structures in various planes. They are **standard methods for diagnosing tumors**.



In the presence of orbital trauma, initial CT studies should be performed as this method can better visualize bony structures. Initial MRI scans should be performed where soft-tissue lesions are suspected.

Angiography: This is indicated in the presence of **suspected arteriovenous fistulas**.

15.3 Developmental Anomalies

Congenital developmental anomalies affecting the orbital cavity are very rare.

15.3.1 Craniofacial Dysplasia

15.3.1.1 Craniostenosis

This clinical picture involves **premature fusion of the cranial sutures**. Clinical signs often include *bilateral exophthalmos* associated with *ocular hypertelorism and exotropia* (divergent strabismus). The mechanical impairment of the optic nerve is evidenced by development of *papilledema* and requires surgical decompression to prevent atrophy of the optic nerve.

15.3.1.1.1 Oxycephaly

Premature fusion of the coronal suture causes the orbits to become elevated, flattened, and smaller than normal.



15.3.1.1.2 Craniofacial Dysostosis

Premature fusion of the coronal and sagittal sutures also results in a high skull and abnormally small orbits. This condition is also characterized by a wide root of the nose and a prominent chin.



Enucleation in early childhood can result in **orbital hypoplasia** as the globe provides a growth stimulus for the orbital cavity. Therefore the patient should promptly receive a prosthesis.

15.3.2 Mandibulofacial Dysplasia

15.3.2.1 Oculoauriculovertrebral Dysplasia

Epibulbar dermoids near the limbus are present in addition to outer ear anomalies and rudiments of a branchial passage in the cheek (see Fig. 4.19).

15.3.2.2 Mandibulofacial Dysostosis

Also known as Treacher Collins' syndrome (incomplete type) or Franceschetti's syndrome (complete type), this **anomaly of the first branchial arch** is characterized by orbital deformities with *antimongoloid palpebral fissures*, *coloboma of the lower eyelid*, low-set ears, and a hypoplastic mandible with dental deformities.

15.3.2.3 Oculomandibular Dysostosis

In addition to the typical bird-like face, this anomaly may be accompanied by bilateral microphthalmos associated with cataract, nystagmus, and strabismus.

15.3.2.4 Rubinstein–Taybi Syndrome

This craniomandibulofacial dysplasia is primarily characterized by antimongoloid palpebral fissures, ocular hypertelorism, epicanthal folds, and enophthalmos. Cataracts, iris colobomas, and infantile glaucoma have also been described.

15.3.3 Meningoencephalocele

Incomplete fusion of the cranial sutures in the orbital region can lead to evaginations of dural sac with brain tissue. Clinical findings occasionally include *pulsating exophthalmos* or, in extreme cases, a *tumorous protrusion*.



15.3.4 Osteopathies

Many of these disorders can produce orbital changes. The most common of these diseases include *Paget's disease of bone*, *dysostosis multiplex* (Hurler's syndrome), and *marble-bone disease of Albers-Schönberg* in which compressive optic neuropathy also occurs.

15.4 Orbital Involvement in Autoimmune Disorders: Graves' Disease

Definition

Autoimmune disorder with orbital involvement frequently associated with thyroid dysfunction. Histologic examination reveals inflammatory infiltration of the orbital cavity.

Epidemiology: Women are affected eight times as often as men. Sixty per cent of all patients have hyperthyroidism. Ten per cent of patients with thyroid disorders develop Graves' disease during the course of their life.



Graves' disease is the most frequent cause of both unilateral and bilateral exophthalmos.

Etiology: The precise etiology of this autoimmune disorder is not clear. Histologic examination reveals lymphocytic infiltration of the orbital cavity. The ocular muscles are particularly severely affected. Fibrosis develops after the acute phase.



An autonomous adenoma of the thyroid gland is not associated with Graves' disease. Some patients with Graves' disease never exhibit any thyroid dysfunction during their entire life.

Symptoms: The onset of this generally painless disorder is usually between the ages of 20 and 45. Patients complain of reddened dry eyes with a sensation of pressure (symptoms of keratoconjunctivitis sicca) and of cosmetic problems. Ocular motility is also limited, and patients may experience double vision.

Diagnostic considerations: Cardinal symptoms include *exophthalmos*, which is unilateral in only 10% of all cases, and eyelid changes that involve development of a *characteristic eyelid sign* (Table 15.3 and Fig. 15.3). Thickening of the muscles (primarily the rectus inferior and medialis) and subsequent fibrosis lead to limited motility and double vision. Elevation is impaired; this can lead to false high values when **measuring intraocular pressure** with the gaze elevated.



Table 15.3 Eyelid signs in Graves' disease

Eyelid sign	Explanation
❖ Dalrymple's sign	Upper eyelid is retracted with visible sclera superior to the limbus and widened palpebral fissure with developing exposure keratitis (overactive muscle of Müller).
❖ von Graefe's sign	Upper eyelid retracts when the eye depresses (overactive muscle of Müller).
❖ Gifford's sign	Upper eyelid is difficult to evert (due to eyelid edema).
❖ Stellwag's sign	Rare blinking.
❖ Kocher's sign	Fixed gaze.
❖ Eyelid flutters when closed	

Patient with Graves' disease, more severe in the left than in the right eye.

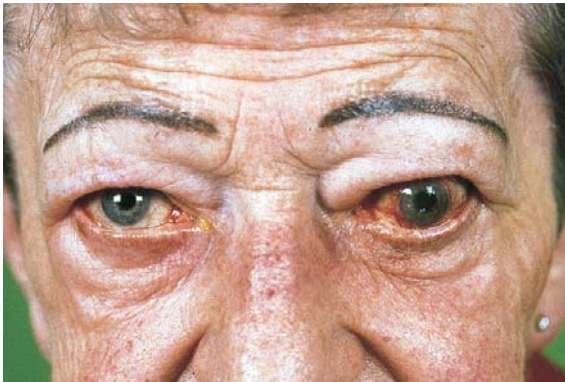

Fig. 15.3 Typical signs include exophthalmos, which here is readily apparent in the left eye, retraction of the upper eyelid with visible sclera superior to the limbus (Dalrymple's sign), conjunctival injection, and fixed gaze (Kocher's sign).

The tentative clinical diagnosis of Graves' disease is supported by **thickening of the extraocular muscles** identified in **ultrasound or CT studies** (Fig. 15.4). The further diagnostic work-up requires the cooperation of an internist, endocrinologist, and radiologist.



CT image of a patient with Graves' disease.

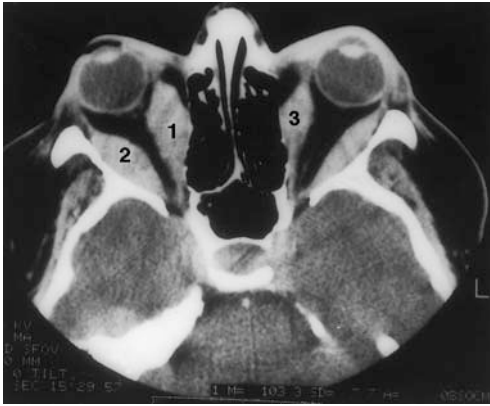


Fig. 15.4 The image shows obvious thickening of the extraocular muscles in the right orbit, primarily the rectus medialis (1) and rectus lateralis (2), and of the rectus medialis (3) in the left orbit.

Differential diagnosis: Rarer clinical syndromes such as orbital tumors and orbital pseudotumors must be excluded.

Treatment: The main principles in treating the disease in its **acute stage** include *management of the thyroid dysfunction*, *systemic cortisone* (initially 60–100 mg of prednisone) and *radiation therapy of the orbital cavity*. *Surgical decompression of the orbital cavity* is indicated in **recurrent cases that do not respond to treatment** to avoid compressive optic neuropathy. **Exposure keratitis** (keratitis due to inability to close the eye) should be treated with *artificial tears* or *tarsorrhaphy* (partial or complete suture closure of the upper and lower eyelid to shorten or close the palpebral fissure). In the **postinflammatory stage** of the disease, *eye muscle surgery* may be performed to correct strabismus.

Clinical course and prognosis: Visual acuity will remain good if treatment is initiated promptly. In the postinflammatory phase, exophthalmos often persists despite the fact that the underlying disorder is well controlled.

15.5 Orbital Inflammation

Because of the close proximity of the orbital cavity to the paranasal sinuses, which are particularly susceptible to inflammation, orbital inflammation represents the *second most frequent* group of orbital disorders after Graves' disease. Orbital cellulitis is the *most severe* of these.



15.5.1 Orbital Cellulitis

Definition

Acute inflammation of the contents of the orbital cavity with the cardinal symptoms of limited motility and general malaise.



Orbital cellulitis is the most frequent cause of exophthalmos in children.

Etiology: Acute orbital inflammation posterior to the orbital septum is *usually* an inflammation that has spread from surrounding tissue. Over 60% of all cases (as high as 84% in children) may be classified as originating in the **sinuses**, especially the ethmoidal air cells and the frontal sinus. In infants, **tooth germ inflammations** may be the cause. *Less frequently*, this clinical picture occurs in association with facial furuncles, erysipelas, hordeolum, panophthalmitis, orbital injuries, and sepsis.

Symptoms: Patients report severe malaise, occasionally accompanied by fever and pain exacerbated by eye movement.

Diagnostic considerations: Typical symptoms include **exophthalmos** with severe **chemosis** (conjunctival swelling), **eyelid swelling**, and significantly **limited ocular motility** (“cemented” globe; see Fig. 15.5). Patients may exhibit **leukocytosis** and an **increased erythrocyte sedimentation rate**. Where there is clinical evidence of suspected involvement of the paranasal sinuses, an ENT specialist should be consulted to evaluate the sinuses and initiate any necessary treatment.

Patient with orbital cellulitis.

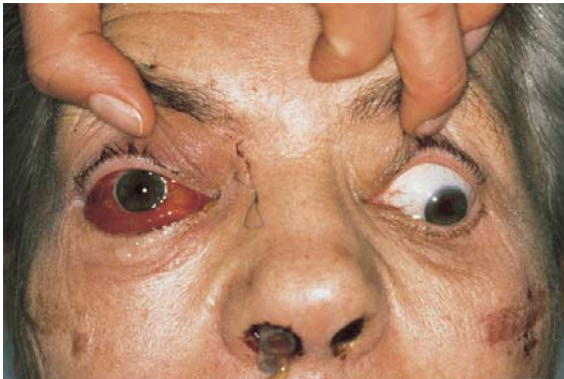

Fig. 15.5 Typical symptoms include chemosis (conjunctival swelling), exophthalmos, and significantly limited ocular motility (the right eye does not move with the left eye).



Differential diagnosis: *Preseptal cellulitis*, which is **more frequently encountered**, should be excluded. The inflammation in preseptal cellulitis is anterior to the orbital septum; *chemosis* and *limited motility* are absent. **Rarer clinical syndromes** that should also be considered in a differential diagnosis include an *orbital pseudotumor*, *orbital periostitis* which may be accompanied by a subperiosteal abscess, and an *orbital abscess*.

! The crucial characteristic feature of orbital cellulitis for differential diagnosis is the significantly limited ocular motility (“cemented” globe). A rhabdomyosarcoma should also be considered in children.

Treatment: This consists of **high-dose intravenous antibiotic therapy** with 1.5 g of oxacillin every four hours combined with one million units of penicillin G every four hours. Infants are treated with ceftriaxone and school-age children with oxacillin combined with cefuroxime in the appropriate doses. **Treatment of underlying sinusitis** is indicated in applicable cases.

Clinical course and complications: Orbital inflammation can lead to **optic neuritis** with subsequent atrophy and loss of vision. Purulent thrombophlebitis of the orbital veins can result in cavernous sinus thrombosis with meningitis, cerebral abscess, or sepsis.

! Orbital cellulitis can progress to a life-threatening situation (cavernous sinus thrombosis).

15.5.2 Cavernous Sinus Thrombosis

Definition

Rare but severe acute clinical syndrome in which the spaces of the cavernous sinus posterior to the orbital cavity become thrombosed, usually in the presence of adjacent purulent processes. This is not an orbital disorder in the strict sense.

Etiology: These are purulent inflammations that have spread from the middle ear, petrous bone, orbital cavities, or from the facial skin via the angular vein.

Symptoms: Patients present with an acute clinical picture with headache, stupor, fever, and vomiting.

Clinical findings: The ophthalmologist will usually diagnose *bilateral exophthalmos* and *episcleral and conjunctival venous stasis* in combination with multiple pareses of the cranial nerves. *Neurogenic paralysis of all ocular muscles* is referred to as **total ophthalmoplegia**. Where the *optic nerve is also involved*, the condition is referred to as **orbital apex syndrome**.



The limited motility of the globe is primarily neurogenic and due to damage to the nerves in the cavernous sinus as opposed to the mechanical limitation of motility due to the orbital inflammation in orbital cellulitis.

Diagnostic considerations and treatment: This lies primarily in the hands of ENT specialists, neurosurgeons, and internists. High-dose systemic antibiotic therapy and anticoagulation are indicated.

15.5.3 Orbital Pseudotumor

Definition

Lymphocytic orbital tumor of *unknown origin*.

Symptoms and findings: Painful, moderately severe inflammatory reaction with **eyelid swelling**, **chemosis**, and unilateral or bilateral **exophthalmos**. Involvement of the ocular muscles results in **limited motility with diplopia**.

Diagnostic considerations: The **CT and MR images** will show diffuse soft-tissue swelling. A **biopsy** is required to confirm the diagnosis.



Occasionally the CT image will simulate an infiltrative tumor.

Differential diagnosis: Various disorders should be excluded. These include **Graves' disease** and **orbital cellulitis**, which is usually bacterial. **Special forms of orbital pseudotumor** include myositis and Tolosa–Hunt syndrome (painful total ophthalmoplegia produced by an idiopathic granuloma at the apex of the orbit).

Treatment: High-dose **systemic cortisone** (initially 100 mg of prednisone) usually leads to remission. Orbital radiation therapy or surgical intervention may be indicated in cases that fail to respond to treatment.

15.5.4 Myositis

This a **special form of orbital pseudotumor** in which the lymphatic infiltration *primarily involves one or more ocular muscles*. Aside from significant *pain during motion*, symptoms include *limited ocular motility with double vision* (diplopia). Depending on the extent of the myositic changes, *exophthalmos with chemosis and eyelid swelling* may also be present. *Ultrasound studies* (Fig. 15.6) will reveal thickening of the ocular muscles with *tenonitis* (inflammation of Tenon's capsule).



In Graves' disease, only the muscle belly is thickened. In myositis, the entire muscle is thickened.



Diagnosis of myositis.

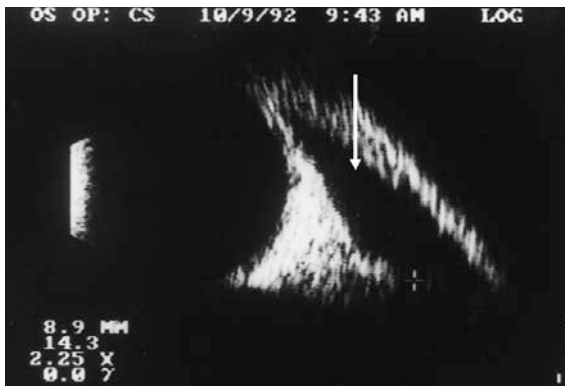

Fig. 15.6 The ultrasound image (B-mode scan) shows thickening of the entire hypoechoic rectus medialis (arrow).

15.5.5 Orbital Periostitis

This is an **inflammation of the periosteum lining the orbital cavity**, usually due to bacterial infection such as actinomycosis, tuberculosis, or syphilis. Less frequently, the disorder is due to osteomyelitis or, in infants, tooth germ inflammations. The clinical symptoms are similar to orbital cellulitis although significantly less severe and without limitation of ocular motility. Liquefaction of the process creates an orbital abscess; large abscesses may progress to orbital cellulitis.

15.5.6 Mucocele

These **mucus-filled cysts** may invade the orbital cavity in chronic sinusitis. They displace orbital tissue and cause exophthalmos.

Treatment is required in the following cases:

- ❖ Displacement of the globe causes cosmetic or functional problems, such as lagophthalmos or limited motility.
- ❖ Compression neuropathy of the optic nerve results.
- ❖ The mucocele becomes infected (pyocele).

15.5.7 Mycoses (Mucormycosis and Aspergillomycosis)

These rare disorders occur primarily in immunocompromised patients, such as those with diabetes mellitus or AIDS. The disorder often spreads from infected paranasal sinuses. The clinical picture is similar to those of inflammatory orbital disorders.



15.6 Vascular Disorders

These changes are *rare*. The most important and most frequently encountered disorder in this group is pulsating exophthalmos.

15.6.1 Pulsating Exophthalmos

Definition

Acute exophthalmos with palpable and audible pulsations synchronous with the pulse in the presence of a *cavernous sinus fistula* or *arteriovenous aneurysm*.

Etiology: An abnormal communication between the *cavernous sinus* and the *internal carotid artery* (a direct shunt) or *its branches* (indirect shunt) results in distention of the orbital venous network. Eighty per cent of all cases are attributable to trauma; less frequently the disorder is due to syphilis or arteriosclerosis.

Symptoms: Patients report an unpleasant sound in the head that is reminiscent of a machine and synchronous with their pulse.

Diagnostic considerations: The increased venous pressure leads to **dilation of the episcleral and conjunctival vessels** (Fig. 15.7), retinal signs of venous stasis with bleeding, exudation, and papilledema. **Intraocular pressure** is also **increased**. The increased pressure in the cavernous sinus can also result in oculomotor and abducent nerve palsy.



Sounds near the direct fistula are clearly audible with a stethoscope.

Fistula between the carotid artery and cavernous sinus.

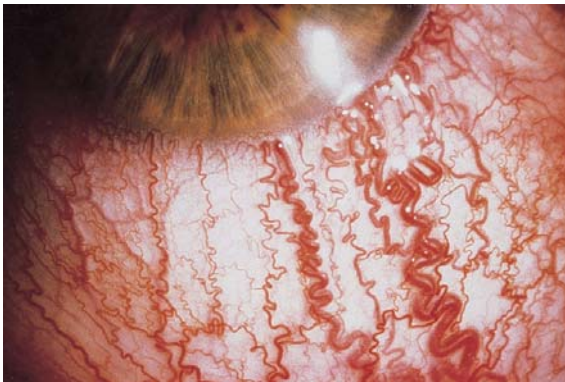

Fig. 15.7 The episcleral and conjunctival vessels are significantly dilated and describe tortuous corkscrew courses.



Doppler ultrasound studies can confirm a clinical suspicion. However, only **angiography** can determine the exact location of the shunt.

Treatment: Selective embolization may be performed in cooperation with a neuroradiologist once the shunt has been located.



Small shunts may close spontaneously in response to pressure fluctuations such as can occur in air travel.

15.6.2 Intermittent Exophthalmos

This *rare* clinical picture characterized by **intermittent unilateral or bilateral exophthalmos** is caused by *varicose dilation of the orbital veins*, such as can occur following trauma or in Osler's disease (polycythemia vera). Patients report protrusion of the eyeball of varying severity. Exophthalmos is usually unilateral and is especially prone to occur when the resistance to venous drainage is increased, as can occur when the patient presses, bends over, screams, or compresses the vessels of the neck. Occasionally the exophthalmos will be associated with increased filling of the episcleral and/or conjunctival vessels. The disorder can be diagnosed in *ultrasound studies using the Valsalva maneuver*. A differential diagnosis should exclude a fistula between the carotid artery and cavernous sinus or an arteriovenous aneurysm, which is usually accompanied by a dramatic clinical picture with pulsation and increased intraocular pressure. In these clinical pictures, the ultrasound examination will reveal *generalized* dilation of the orbital veins. Surgical removal of orbital varices entails a high risk of damaging crucial delicate neurovascular structures in the orbital cavity. However, it may be indicated in rare cases such as cosmetically unacceptable exophthalmos or where symptoms of keratoconjunctivitis sicca occur due to exposure that fails to respond to treatment.

15.6.3 Orbital Hematoma

Orbital bleeding is **usually post-traumatic** but may occur **less frequently due to coagulopathy** resulting from vitamin C deficiency, anticoagulants, or leukemia. Retrobulbar injections prior to eye surgery and acute venous stasis such as may occur in coughing fits, asphyxia, or childbirth can also cause orbital hematomas. Exophthalmos may be accompanied by *monocle or eyeglass hematoma, eyelid swelling, and subconjunctival hemorrhage*; *limited motility* is rare. Surgical decompression of the orbital cavity (transforix orbital decompression or orbitotomy) is indicated where damage to the optic nerve or blockage of the central retinal artery is imminent.



15.7 Tumors

15.7.1 Orbital Tumors

All orbital tumors displace the globe and cause exophthalmos that is frequently associated with limited ocular motility. Some tumors also cause specific additional symptoms and findings. These are discussed separately for each of the tumors presented in the following section.

Tumors of the lacrimal gland are discussed in Chapter 3, Lacrimal System.

15.7.1.1 Hemangioma

Hemangiomas are the *most common benign orbital tumors* in both children and adults. They usually occur in a *nasal superior* location. *Capillary* hemangiomas are more common in **children** (they swell when the child screams), and *cavernous* hemangiomas are more common in **adults**. *Treatment* is only indicated where the tumor threatens to occlude the visual axis with resulting amblyopia or where there is a risk of compressive optic neuropathy. Capillary hemangiomas in children may be treated with cortisone or low-dose radiation therapy.

15.7.1.2 Dermoid and Epidermoid Cyst

These lesions are the *most common orbital tumors in children*. Etiologically, they are choristomas, i.e., dermal or epidermal structures that have been displaced into deeper layers. However, they *usually are located anterior to the orbital septum* (and therefore are not in the actual orbit itself). Lesions located posterior to the orbital septum usually become clinically significant only in adults. *Treatment* consists of complete removal.

15.7.1.3 Neurinoma and Neurofibroma

These tumors are often associated with *Recklinghausen's disease (neurofibromatosis)*. If they occur in the optic canal, they must be removed before they cause compressive optic neuropathy.

15.7.1.4 Meningioma

A meningioma can proceed from the optic nerve (**meningioma of the optic nerve sheath**) or from within the cranium (**sphenoid meningioma**). Symptoms vary depending on the location of the tumor. Exophthalmos, limited motility, and compressive optic neuropathy can result. *Hyperostoses* are frequent findings in radiographic studies. Treatment consists of neurosurgical removal of the tumor. Like neurinomas, 16% of all meningiomas are



associated with *neurofibromatosis* (Recklinghausen's disease). *Meningiomas of the optic nerve sheath* are usually histologically benign but can recur if not completely removed. Interestingly, the average age of patients is 32; 20% are younger than 20.

15.7.1.5 Histiocytosis X

This is a generic term for the **proliferation of Langerhans' cells** of undetermined etiology; all three of the following types can cause exophthalmos where there is orbital involvement:

- ❖ Letterer-Siwe disease (malignant).
- ❖ Hand-Schüller-Christian disease (benign).
- ❖ Eosinophilic granuloma (rare and benign).

15.7.1.6 Leukemic Infiltrations

Leukemic infiltrations occur especially in acute lymphoblastic leukemia and in a special form of myeloid leukemia (granulocytic sarcoma or chloroma). Inflammation is present in addition to exophthalmos.

15.7.1.7 Lymphoma

Lymphomas can occur in isolation or in systemic disease. Cooperation with an oncologist is required. The disorder may be treated by radiation therapy or chemotherapy. Usually these tumors are *only slightly malignant*. **The highly malignant Burkitt's lymphoma**, which has a high affinity for the orbital cavity, is a notable exception.

15.7.1.8 Rhabdomyosarcoma

This is the *commonest primary malignant tumor in children*. The tumor often grows very rapidly. Because of the accompanying inflammation, a differential diagnosis should exclude orbital cellulitis. Other indicated diagnostic studies include a CT scan and possibly a biopsy. With modern therapeutic regimes such as chemotherapy and radiation therapy, curative treatment is possible in many cases.

15.7.2 Metastases

In **children**, the incidence of metastasis is higher in the orbital cavity than in the choroid. In **adults**, it is exactly the opposite. The most common orbital metastases in children originate from *neuroblastomas*. Malignant tumors from adjacent tissue can also invade the orbital cavity.



15.7.3 Optic Nerve Glioma

In children, this is the *second most common potentially malignant orbital tumor*. In 25% of all patients, the optic nerve glioma is associated with *neurofibromatosis* (Recklinghausen's disease). Fifteen percent of all patients with neurofibromatosis develop optic nerve gliomas. The prognosis is good only where the tumor is completely resected.

Injuries

See Chapter 18.

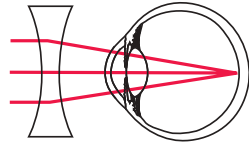
15.8 Orbital Surgery

Access to the orbital cavity is gained primarily through an **anterior** approach (transconjunctival or transpalpebral approaches yield good cosmetic results) or through a **lateral** approach. The lateral Krönlein approach provides better intraoperative exposure. *Transantral*, *transfrontal*, *transcranial*, and *transnasal* orbitotomies are used less frequently.

Orbital exenteration is indicated with advanced malignant tumors. This involves removal of the entire contents of the orbital cavity including the eyelids.

16 Optics and Refractive Errors

Christoph W. Spraul and Gerhard K. Lang



16.1 Basic Knowledge

16.1.1 Uncorrected and Corrected Visual Acuity

Uncorrected visual acuity: This refers to the resolving power of the eye without corrective lenses.

Corrected visual acuity: This refers to the resolving power of the eye with an optimal correction provided by corrective lenses (determined by visual acuity testing).

Both uncorrected visual acuity and corrected visual acuity provide information on how far apart two objects must be for the eye to perceive them as distinct objects (**minimum threshold resolution**). For the eye to perceive two objects as distinct, at least one unstimulated cone must lie between two stimulated cones on the retina. The cone density is greatest in the center of the retina and **central visual acuity** is highest. There the cones are spaced only 2.5 μm apart. This interval increases toward the periphery of the retina, and both uncorrected visual acuity and corrected visual acuity decrease accordingly. Cone spacing and physical effects such as diffraction and optical aberrations limit the average minimum threshold resolution, the **minimum visual angle** to one minute of arc (the individual maximum value is approximately 30 seconds of arc). One minute of arc is 1/60 of a degree or approximately 0.004 mm, which is somewhat more than the width of a cone. This corresponds to the maximum resolving power of the retina (Fig. 16.1).

16.1.2 Refraction: Emmetropia and Ametropia

Refraction is defined as the ratio of the refractive power of the lens and cornea (the refractive media) to the axial length of the globe. Emmetropia is distinguished from ametropia.

Emmetropia (normal sight): The ratio of the axial length of the eye to the refractive power of the cornea and lens is balanced. Parallel light rays that enter the eye therefore meet at a focal point *on* the retina (Figs. 16.2 and 16.6a) and not *anterior* or *posterior* to it, as is the case in ametropia.



Resolution of the eye (minimum threshold resolution).

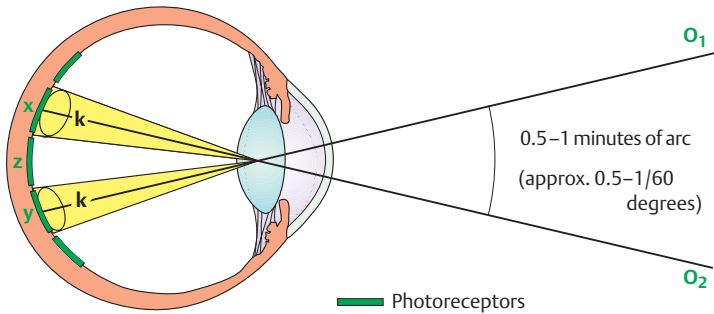


Fig. 16.1 Two points (O_1 and O_2) can only be perceived as distinct if at least one unstimulated cone (z) lies between two stimulated cones (x and y) on the retina. Due to optical aberrations and diffraction, a punctiform object is reproduced as a circle (k). This results in a maximum resolution of the eye of 0.5–1 minutes of arc or 0.5/60–1/60 of a degree. The drawing is not to scale.

Focal point in emmetropia and ametropia.

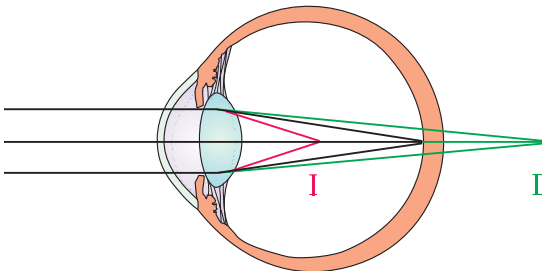
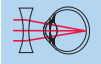


Fig. 16.2 Parallel rays of light entering the eye from an optically infinite distance meet at a focal point on the retina in emmetropia (black lines). In hyperopia, this focal point (II) lies posterior to the retina (green lines). In myopia (I), it lies anterior to the retina (red lines).

Ametropia (refractive error): There is a mismatch between the axial length of the eye and the refractive power of the lens and cornea. The ametropia is either **axial**, which is common, or **refractive**, which is less frequently encountered. The most common disorders are nearsightedness, farsightedness, and astigmatism.



Very few people have refraction of exactly ± 0.0 diopters. Approximately 55% of persons between the ages of 20 and 30 have refraction between +1 and -1 diopters.



Emmetropia is not necessarily identical to good visual acuity. The eye may have other disorders that reduce visual acuity, such as atrophy of the optic nerve or amblyopia.

The refractive power of an optical lens system is specified in *diopters*, which are the international units of measure. Refractive power is calculated according to the laws of geometric optics. According to **Snell's law**, the refraction of the incident light ray is determined by the angle of incidence and difference in the refractive indices n of the two media (Table 16.1).

The maximum **total refractive power of an emmetropic eye** is 63 diopters with an axial length of the globe measuring 23.5 mm. The cornea accounts for 43 diopters and the lens for 10–20 diopters, depending on accommodation. However, the refractive power of the eye is not simply the sum of these two values. The optic media that surround the eye's lens system and the distance between the lens and cornea render the total system more complex.



The refractive power D (specified in diopters) of an optical system is the reciprocal of the focal length of a lens f (specified in meters). This yields the equation: $D = 1/f$.

Example: Where a lens focuses parallel incident light rays 0.5 m *behind* the lens, the refractive power is $1/0.5 \text{ m} = +2$ diopters. This is a converging lens. Where the virtual focal point is *in front of* the lens, the refractive power is $1/-0.5 \text{ m} = -2$ diopters. This is a diverging lens (Fig. 16.3).

16.1.3 Accommodation

The refractive power of the eye described in the previous section is not a constant value. The eye's refractive power must alter to allow visualization of

Table 16.1 Important refractive indices n of the various tissues of the eye (from Krause, K. *Methoden der Refraktionsbestimmung*. Biermann, Münster, Germany, 1985)

Eye tissue	Refractive index n
Cornea	1.376
Aqueous humor	1.336
Lens at the poles	1.385
Lens at the core	1.406
Vitreous body	1.336

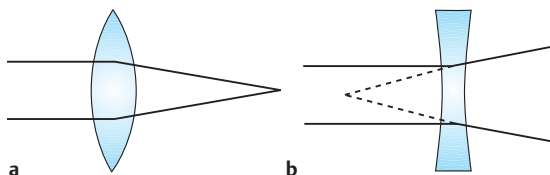
**Refraction of light rays traveling through converging and diverging lenses.**

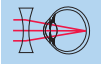
Fig. 16.3 **a** The converging lens (biconvex) concentrates incident light rays at a focal point behind the lens. **b** A diverging lens (biconcave) ensures that the light rays do not meet at all. The light rays appear to originate at a virtual focal point in front of the lens.

both near and distant objects with sharp contours. This accommodation is made possible by the *elasticity of the lens*.

Accommodation mechanisms: Accommodation involves the lens, zonule fibers, and ciliary muscle.

- ❖ **Lens:** The soluble proteins of the lens are surrounded by a thin elastic capsule. The curvature of the posterior capsule of the lens is greater than its anterior curvature, with a posterior radius of 6.0 mm as opposed to an anterior radius of 10.0 mm. The *intrinsic elasticity of the lens capsule* tends to make the lens assume a spherical shape. However, in the unaccommodated state this is prevented by the pull of the zonule fibers. The elasticity of the inner tissue of the lens progressively decreases with age due to deposits of insoluble proteins.
- ❖ **Zonule fibers:** The radiating zonule fibers insert into the equator of the lens and connect it to the ciliary body. They hold the lens securely in position and transmit the pull of the ciliary muscle to the lens.
- ❖ **Ciliary muscle:** *Contraction of the ring-shaped ciliary muscle* decreases the tension in the zonule fibers. The lens can then approach the spherical shape (with a radius of curvature of 5.3 mm) that its physical configuration and chemical composition would otherwise dictate. This change in the curvature of the lens is especially pronounced in its anterior surface. The deformation *increases the refractive power*; the focus of the eye shifts to the near field (Fig. 16.4), and close objects take on sharp contours. *As the ciliary muscle relaxes*, the tension on the lens increases and the lens flattens. The resulting *decrease in refractive power* shifts the focus of the eye into the distance (Fig. 16.4), and distant objects take on sharp contours.

The ciliary muscle is innervated by the short ciliary nerves, postganglionic parasympathetic fibers of the oculomotor nerve. Parasympatholytics such as atropine, scopolamine, and cyclopentolate inhibit the function of the ciliary muscle and therefore prevent accommodation. Referred to as *cycloplegics*,



Morphologic changes in accommodation.

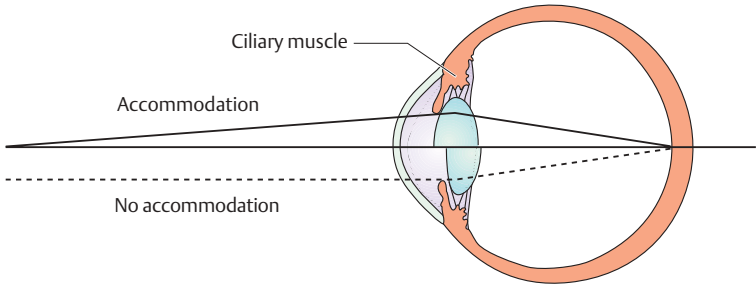


Fig. 16.4 Upper half of figure: In accommodation, the lens becomes increasingly globular. The curvature of the anterior surface in particular increases. The ciliary muscle is shifted slightly anteriorly, and the anterior chamber becomes shallower. Objects in the near field (continuous line) are represented on the retina with sharp contours.

Lower half of figure: With the ciliary body relaxed, parallel incident light rays (dotted line) are focused on the retina. Distant objects are represented on the retina with sharp contours.

these medications also cause *mydriasis* by inhibiting the sphincter pupillae. *Parasympathomimetics* such as pilocarpine cause the ciliary muscle and sphincter pupillae to contract, producing *miosis*.



When the ciliary muscle is *at rest*, the zonule fibers are under tension and the eye focuses on distant objects.

Accommodation is regulated by a *control loop*. The control variable is the sharpness of the retinal image. The system presumably uses the color dispersion of the retinal image to determine the direction in which accommodation should be corrected.

Range of accommodation: This specifies the *maximum increase in refractive power that is possible* by accommodation in diopters (Fig. 16.5). In mathematical terms, the range of accommodation is obtained by subtracting near-point refractive power from far-point refractive power. The **near point** is shortest distance that allows focused vision; the **far point** describes the farthest point that is still discernible in focus. The near and far points define the range of accommodation; its specific location in space is a function of the refractive power of the eye.

Example: In one patient, the near point lies at 0.1 m and the far point at 1 m. This patient's range of accommodation is then 10 diopters -1 diopter = 9 diopters.



In an emmetropic eye, the far point is at optical infinity. However, accommodation can also bring near-field objects into focus (Fig. 16.6b). The elasticity of the lens decreases with increasing age, and the range of accommodation decreases accordingly (Fig. 16.5). **Presbyopia** (physiologic loss of accommodation in advancing age) begins when the *range of accommodation falls below 3 diopters*. The gradual loss of accommodation causes the near point to recede; that patient's arms become “too short for reading”. Depending on age and limitation of accommodation, presbyopia can be compensated for with converging lenses of 0.5–3 diopters (see Fig. 16.6c and d).

16.1.4 Adaptation to Differences in Light Intensity

Like a camera, the eye's aperture and lens system also automatically adapts to differences in light intensity to avoid “overexposure”. This adjustment is effected by two mechanisms.

1. **The iris acts as an aperture to control the amount of light entering the eye.** This regulation takes about one second and can change the light intensity on the retina over a range of about a power of ten.
2. **The sensitivity of the retina changes** to adapt to differences in light intensity. The sensitivity of the retina to light is a function of the *concentration of photopigment in the photoreceptors* and of the *neuronal activity of the retinal cells*. The change in neuronal activity is a rapid process that takes only a few milliseconds and can alter the light sensitivity of the retina over a range of three powers of ten. The change in the concentration of photopigment takes several minutes but can cover a wide range of retinal light sensitivity, as much as eight powers of ten.

Range of accommodation in diopters as a function of age.

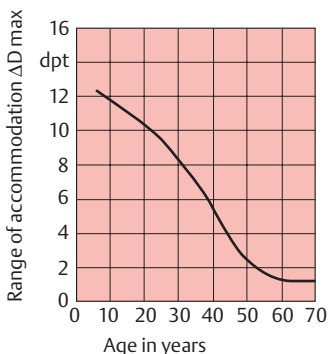


Fig. 16.5 When the range of accommodation falls below 3 diopters, a previous emmetropic patient will require eyeglasses for reading (adapted from Goersch 1987).



Refraction in the emmetropic eye.

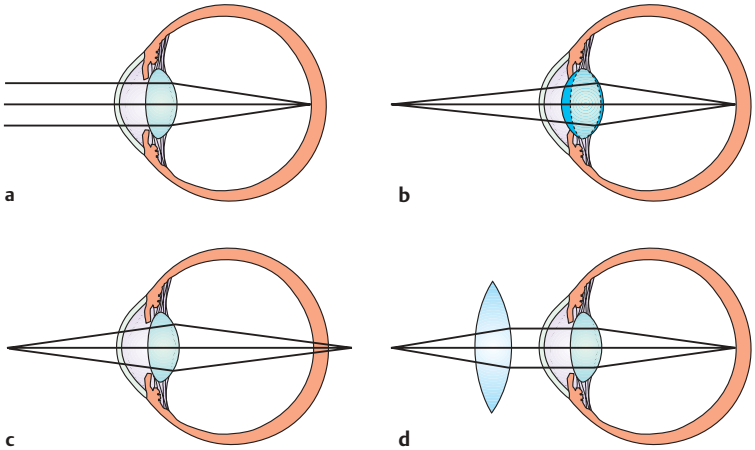


Fig. 16.6 **a** Parallel light rays entering the eye from optical infinity are focused on the retina in an *unaccommodated eye*. **b** Accommodation focuses the light rays from a close object on the retina, and the object is visualized with sharp contours. **c** Where accommodation is insufficient, as in advanced age, close objects appear blurred. **d** A converging lens is required to correct insufficient accommodation for near vision in advancing age.

16.2 Examination Methods

Visual acuity: see Chapter 1.

16.2.1 Refraction Testing

Refraction testing means measuring the *additional* refractive power required to produce a sharp image on the retina. Subjective and objective methods are used. Subjective methods require information from the patient.

Subjective refraction testing: This consists of successively placing various combinations of lenses before the patient's eye until the maximum visual acuity is reached (see Correction of Refractive Errors).

Objective refraction testing: Objective testing is unavoidable when the patient is unable to provide subjective information (for example with infants) or when this information is unreliable. This method also greatly accelerates subjective refractive testing.



Retinoscopy (shadow testing): The retina is illuminated through the pupil. The examiner observes the optical phenomena in the patient's pupil while moving the light source (Fig. 16.7).

Objective determination of refractive power with a retinoscope.

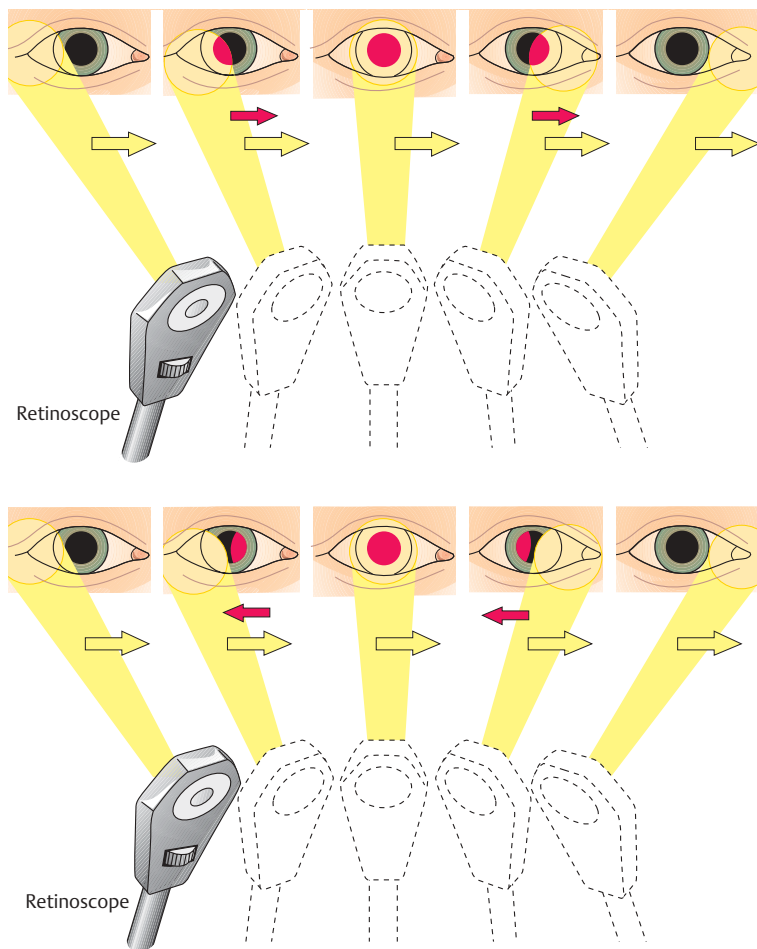
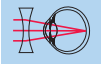


Fig. 16.7



Refractometry. The measuring principle is based on ophthalmoscopic observation of a test image projected on to the patient's retina. The distance between the test figure and the eye is changed until the image appears in focus on the retina. Refraction can then be calculated from the measured values. An alternative to changing of the distance is to place various lenses in the path of the light beam.

Automated refractometry. The method measures refraction automatically with the aid of light-sensitive detectors and a computer until a focused image appears on the retina. These systems operate with infrared light.



Any objective measurements of refraction should be verified by subjective testing whenever possible.

16.2.2. Testing the Potential Resolving Power of the Retina in the Presence of Opacified Ocular Media

Special examination methods are indicated in the presence of opacification of the ocular media of the eye (such as a cataract) to determine the potential visual acuity of the retina. This permits the ophthalmologist to estimate whether optimizing the refractive media with techniques such as cataract surgery or corneal transplantation would achieve the desired improvement.

Laser interference visual acuity testing: Lasers are used to project inference strips of varying widths on to the retina. The patient must specify the direction in which these increasing narrower strips are aligned. This examination can no longer be performed where there is severe opacification of the optic media such as in a mature cataract. The preliminary examination then consists of **evaluating the pattern of the transilluminated retinal vasculature.**

◀ Fig. 16.7 With the retinoscope, the examiner moves a light source (a beam of yellow light) across the pupil (dark spot) at a distance of about 50 cm from the patient. This produces a light reflex (red spot) in the patient's eye. It is important to note how this light reflex (red spot) behaves as the light source of the retinoscope is moved. There are two possibilities:

a "With" motion: the light reflex in the pupil (red spot) moves in the same direction (red arrows) as the light source of the retinoscope (yellow arrows). This means that the far point of the eye is *behind* the light source. **b "Against" motion.** The light reflex in the pupil moves in the *opposite* direction (red arrows) to the light source of the retinoscope (yellow arrows). This means that the far point of the eye lies *between* the eye and the light source. The examiner places appropriate lenses in front of the patient's eyes (plus lenses for "with" motion and minus lenses for "against" motion) until no further motion of the light reflex is observed. The motion of the retinoscope will then only elicit an infinitely fast reflex (**neutral point**). This method is used to determine the proper lens for correcting the refractive error.



16.3 Refractive Anomalies (Table 16.2)

16.3.1 Myopia (Shortsightedness)

Definition

A discrepancy between the refractive power and axial length of the eye such that parallel incident light rays converge at a *focal point anterior to the retina* (Fig. 16.8 a).

Epidemiology: Approximately 25% of persons between the ages of 20 and 30 have refraction less than -1 diopters.

Refraction in myopia.

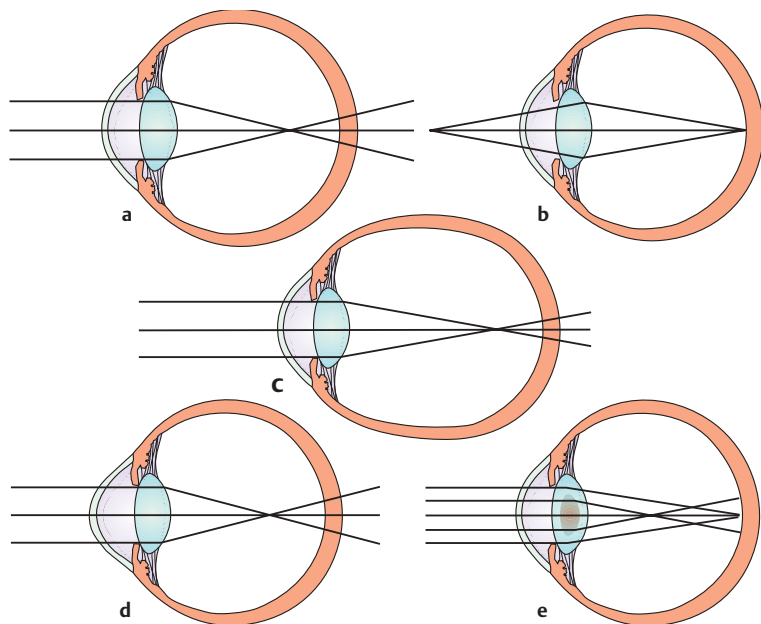


Fig. 16.8 a The focal point of parallel light rays entering the eye lies anterior to the retina. b Only close objects from which the light rays diverge until they enter the eye are focused on the retina and appear sharply defined. The far point is a finite distance from the eye. c Axial myopia: normal refractive power in an excessively long globe. d Refractive myopia: excessive refractive power in a normal-length globe. e Nuclear cataract with a secondary focal point (patient sees double).



Table 16.2 Overview of the most important refractive anomalies

Refractive anomaly	Focal point of parallel incident light rays	Causes	Vision	Possible complications	Optical correction
Myopia (nearsightedness)	Anterior to the retina	<ul style="list-style-type: none"> ❖ Eyeball too long (axial myopia). ❖ Excessive refractive power (refractive myopia). 	<ul style="list-style-type: none"> ❖ Very good near vision. ❖ Poor distance vision. 	<ul style="list-style-type: none"> ❖ Increased risk of retinal detachment. ❖ See p. 434 for complications specific to pathologic myopia. 	Diverging lenses (minus or concave lenses).
Hyperopia (farsightedness)	Posterior to the retina	<ul style="list-style-type: none"> ❖ Eyeball too short (axial hyperopia). ❖ Insufficient refractive power (refractive hyperopia). 	<ul style="list-style-type: none"> ❖ Poor near vision. ❖ Accommodation usually permits normal distance vision (in young patients and in slight to moderate hyperopia). 	<ul style="list-style-type: none"> ❖ Disposition to acute angle closure glaucoma (shallow anterior chamber). Caution is advised with diagnostic and therapeutic mydriasis. ❖ Esotropia 	Converging lenses (plus or convex lenses).
Astigmatism	Lack of a focal point	Anomalies in the curvature of the normally spherical surfaces of the refractive media (cornea and lens).	Patients see everything distorted.	Risk of refractive amblyopia.	Cylindrical lenses; eyeglass correction is only possible where astigmatism is regular.



Etiology: The etiology of myopia is not clear. Familial patterns of increased incidence suggest the influence of genetic factors.

Pathophysiology: Whereas parallel incident light rays converge at a focal point on the retina in emmetropic eyes, they converge at a focal point *anterior* to the retina in myopic eyes (Fig. 16.8a). This means that *no sharply defined images* appear on the retina when the patient gazes into the distance (Fig. 16.8a). The myopic eye can only produce *sharply defined images* of close objects from which the light rays diverge until they enter the eye (Fig. 16.8b). The far point moves closer; in myopia of -1 diopter it lies at a distance of 1 m.

! In myopia, the far point (distance from the eye = A) can be calculated using the formula: $A \text{ (m)} = 1/D$, where D is myopia in diopters.

Possible causes include an *excessively long globe* with normal refractive power (**axial myopia**; Fig. 16.8c) and, less frequently, *excessive refractive power* in a normal-length globe (**refractive myopia**; Fig. 16.8d).

! A difference in globe length of 1 mm with respect to a normal eye corresponds to a difference of about 3 diopters in refractive power.

Special forms of refractive myopia:

- ❖ Myopic sclerosis of the nucleus of the lens (*cataract*) in advanced age (see p. ■). This causes a secondary focal point to develop, which can lead to monocular diplopia (double vision).
- ❖ Keratoconus (increase in the refractive power of the cornea).
- ❖ Spherophakia (spherically shaped lens).

Forms: These include:

- ❖ **Simple myopia** (school-age myopia): Onset is at the age of 10–12 years. Usually the myopia does not progress after the age of 20. Refraction rarely exceeds 6 diopters. However, a *benign progressive myopia* also exists, which stabilizes only after the age of 30.
- ❖ **Pathologic myopia:** This disorder is largely hereditary and progresses continuously independently of external influences.

Symptoms and diagnostic considerations: The diagnosis is made on the basis of a typical clinical picture and refraction testing. Myopic patients have very good near vision. When gazing into the distance, they squint in an attempt to improve their uncorrected visual acuity by further narrowing the optic aperture of the pupil. The term “myopia” comes from this squinting; the Greek word “myein” means to squint or close the eyes. *Older* myopic patients can read without corrective lenses by holding the reading material at about the distance of the far point.

The typical **morphologic changes** occurring in myopia are referred to as **myopia syndrome**. Progressive myopia in particular is characterized by *thinning of the sclera*. The *elongation of the globe* causes a *shift in the axes of the eye*.



This often simulates esotropia. The *anterior chamber* is deep. *Atrophy of the ciliary muscle* is present as it is hardly used. The volume of the vitreous body is too small for the large eye, and it may collapse prematurely. This results in *vitreous opacifications* that the patient perceives as floaters.

Morphologic fundus changes in myopia, such as maculopathy and Fuchs' spot, are discussed in Section 12.4.6.

The **risk of retinal detachment** is increased in myopia. However, it *does not* increase in proportion to the severity of the myopia.



Because of the increased risk of retinal detachment, patients with myopia should be examined particularly thoroughly for prodromal signs of retinal detachment, such as equatorial degeneration or retinal tears. Therefore, examination of the fundus with the pupil dilated is indicated both when the first pair of eyeglasses is prescribed and at regular intervals thereafter.

Glaucoma is more difficult to diagnose in patients with myopia. Measurements of intraocular pressure obtained with a Schiøtz tonometer will be lower than normal due to the decreased rigidity of the sclera.



Applanation tonometry yields the most accurate values in patients with myopia because the rigidity of the sclera only slightly influences results.

The **optic cup** is also difficult to evaluate in patients with myopia because the optic nerve enters the eye obliquely. This also makes glaucoma more difficult to diagnose.

Treatment: The excessive refractive power of the refractive media must be reduced. This is achieved through the use of **diverging lenses** (minus or concave lenses; Fig. 16.9a). These lenses cause parallel incident light rays to diverge behind the lens. The divergent rays converge at a virtual focal point in front of the lens. The refractive power (D) is negative (hence the term "minus

Correction of myopia.

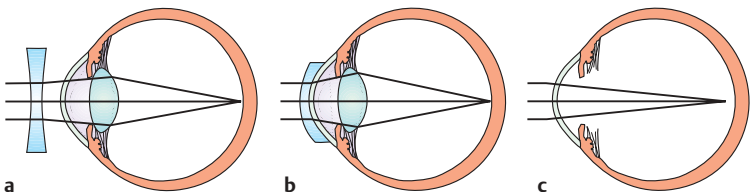


Fig. 16.9 a Correction with diverging lenses (minus lenses). b Correction with contact lens. c Correction by removing the lens to reduce refractive power of the eye.



lens”) and is equal to $1/f$, where f is the focal length in meters. Previously, *biconcave* or *planoconcave* lens blanks were used in the manufacture of corrective lenses. However, these entailed a number of optical disadvantages. Today lenses are manufactured in a *positive meniscus shape* to reduce lens aberrations.

Correction with contact lenses (Fig. 16.9b) offers optical advantages. The reduction in the size of the image is less than with eyeglass correction. Aberrations are also reduced. These advantages are clinically relevant with myopia exceeding 3 diopters.

! The closer the “minus” lens is to the eye, the weaker its refractive power must be to achieve the desired optic effect.

Minus lenses to be used to correct myopia should be no stronger than absolutely necessary. Although accommodation could compensate for an overcorrection, patients usually do not tolerate this well. Accommodative asthenopia (rapid ocular fatigue) results from the excessive stress caused by chronic contraction of the atrophic ciliary muscle.

! Myopic patients have “lazy” accommodation due to atrophy of the ciliary muscle. A very slight undercorrection is often better tolerated than a perfectly sharp image with minimal overcorrection.

In certain special cases, **removal of the crystalline lens** (Fig. 16.9c) may be performed to reduce the refractive power of the myopic eye. However, this operation is associated with a high risk of retinal detachment and is rarely performed. There is also the possibility of implanting an **anterior chamber intraocular lens** (diverging lens) anterior to the natural lens to reduce refractive power. See Chapter 5 for additional surgical options.

Popular health books describe exercises that can allegedly treat refractive errors such as nearsightedness without eyeglasses or contact lenses. Such exercises cannot influence the sharpness of the retinal image; they can only seemingly improve uncorrected visual acuity by training the patient to make better use of additional visual information. However, after puberty no late sequelae of chronically uncorrected vision are to be expected.

16.3.2 Hyperopia (Farsightedness)

Definition

In hyperopia, there is a discrepancy between the refractive power and axial length of the eye such that parallel incident light rays converge at a *focal point posterior to the retina* (Fig. 16.10a).

Epidemiology: Approximately 20% of persons between the ages of 20 and 30 have refraction exceeding +1 diopters. Most newborns exhibit slight hyper-



Refraction in hyperopia.

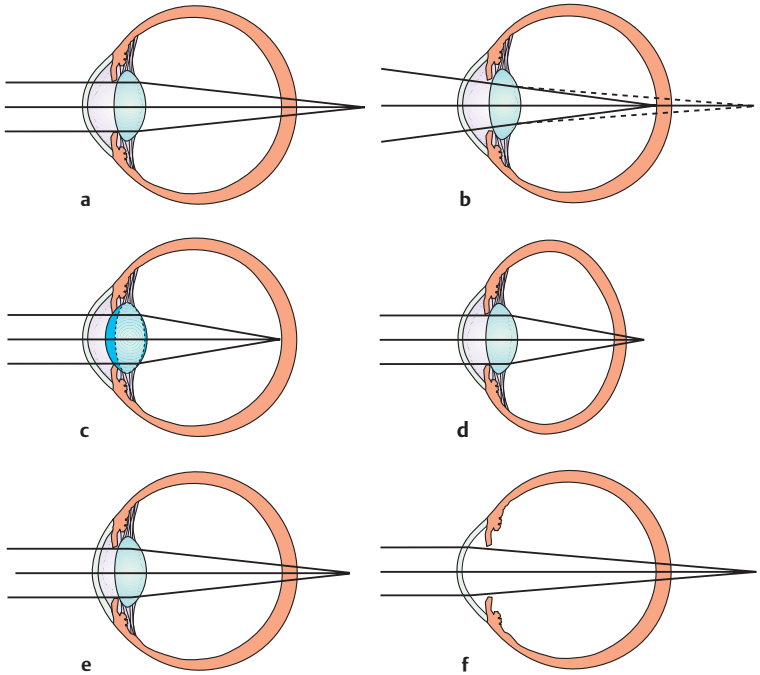


Fig. 16.10 **a** The focal point of parallel light rays entering the eye lies posterior to the retina. **b** Divergent light rays are focused on the retina. The virtual far point lies posterior to the eye (dotted line). **c** To bring the focal point on to the retina, a farsighted person must accommodate even when gazing into the distance. **d** Axial hyperopia: Refractive power is normal but the globe is too short (more common). **e** Refractive hyperopia: The globe is of normal length but refractive power is insufficient (less common). **f** A special form of refractive hyperopia is aphakia (absence of the lens).

opia (*newborn hyperopia*). This decreases during the first few years of life. In advanced age, refraction tends to shift toward the myopic side due to sclerosing of the nucleus of the lens.

Etiology: The mechanisms that coordinate the development of the eyeball so as to produce optic media of a given refractive power are not yet fully understood.



Pathophysiology: In farsighted patients, the virtual *far point* of the eye lies *posterior to the retina* (Fig. 16.10b). Only convergent incident light rays can be focused on the retina (Fig. 16.10b). This is due either to an *excessively short globe* with normal refractive power (**axial hyperopia**; Fig. 16.10d) or, less frequently, to *insufficient refractive power* in a normal-length globe (**refractive hyperopia**; Fig. 16.10e). Axial hyperopia is usually congenital and is characterized by a shallow anterior chamber with a thick sclera and well developed ciliary muscle.

! Hyperopic eyes are predisposed to acute angle closure glaucoma because of their shallow anterior chamber. This can be provoked by diagnostic and therapeutic mydriasis.

Special forms of refractive hyperopia:

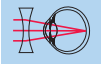
- ❖ Absence of the lens (aphakia) due to dislocation.
- ❖ Postoperative aphakia following cataract surgery without placement of an intraocular lens (see Fig. 16.10).

To bring the focal point on to the retina, a farsighted person *must accommodate even when gazing into the distance* (Fig. 16.10c). *Close objects remain blurred* because the eye is unable to accommodate any further in near vision. As accommodation is linked to convergence, this process can result in *esotropia* (accommodative esotropia or accommodative convergent strabismus).

Symptoms: In young patients, accommodation can compensate for slight to moderate hyperopia. However, this leads to chronic overuse of the ciliary muscle. Reading in particular can cause **asthenopic symptoms** such as eye pain or headache, burning sensation in the eyes, blepharoconjunctivitis, blurred vision, and rapid fatigue. **Esotropia** can also occur, as was mentioned above. As accommodation decreases with advancing age, near vision becomes increasingly difficult. For this reason, hyperopic persons tend to become presbyopic early.

Diagnostic considerations: Ophthalmoscopic examination of the fundus may reveal a slightly blurred **optic disk** that may be **elevated** (hyperopic pseudoneuritis). However, this is not associated with any functional impairments such as visual field defects, loss of visual acuity, or color vision defects. The retina is too large for the small eye, which leads to **tortuous retinal vascular structures**. Transitions to abnormal forms of axial shortening, such as in microphthalmos, are not well defined.

The ciliary muscle is chronically under tension in slight or moderate hyperopia to compensate for the hyperopia. This overuse of the ciliary muscle leads to a condition of residual accommodation in which the muscle is unable to relax even after the hyperopia has been corrected with plus lenses. This residual or **latent hyperopia** may be overlooked if refraction testing is performed without first completely paralyzing the ciliary body with cycloplegic



agents such as cyclopentolate or atropine. The full extent of hyperopia includes both this residual hyperopia and clinically manifest hyperopia.

! In the presence of asthenopic symptoms of uncertain origin, refraction testing under cycloplegia is indicated to rule out latent hyperopia.

Treatment: The insufficient refractive power must be augmented with **converging lenses** (plus or convex lenses; Fig. 16.11 a). A watch-and-wait approach is indicated with asymptomatic young patients with slight hyperopia. Spherical plus lenses converge parallel incident light rays at a focal point behind the lens. The refractive power (D) in plus lenses is positive. It is equal to $1/f$, where f is the focal length in meters. Previously, *biconvex* or *planoconvex* lens blanks were used in the manufacture of corrective lenses. However, these entailed a number of optical disadvantages. The optical aberrations of the *positive meniscus* lenses used today are comparatively slight.

The clinician should determine the *total degree of hyperopia present* (see Diagnostic considerations) prior to prescribing corrective lenses. The second step is to prescribe the **strongest plus lens** that the patient can tolerate without compromising visual acuity. Care should be taken to avoid overcorrection. This will compensate for the manifest component of the hyperopia. If the patient wears these corrective lenses permanently, then with time it will also become possible to correct the latent component (see Diagnostic con-

Correction of hyperopia.

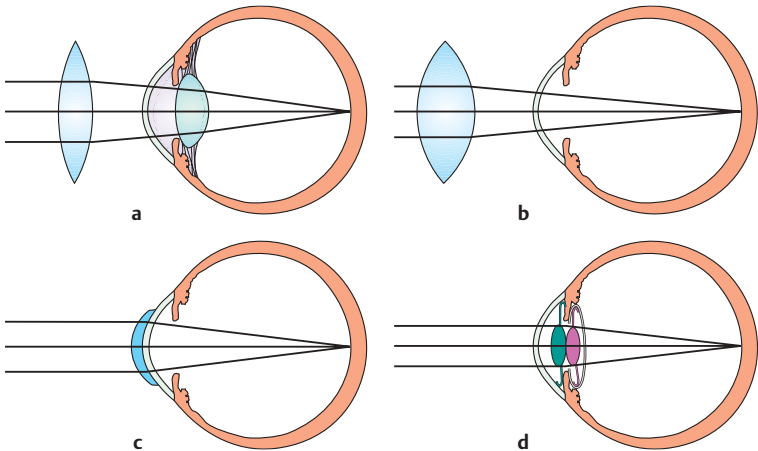


Fig. 16.11 a Correction with converging lenses (plus lenses). b–d Correction of aphakia with cataract lens (b), contact lens (c), anterior chamber intraocular lens (d, blue) or posterior chamber intraocular lens (d, red).



siderations). This is because the permanent tension in ciliary body is no longer necessary.

! Prior to any correction of hyperopia, refraction testing should be performed after administering cycloplegics to the patient. The correction is then made with the strongest plus lens that the patient can subjectively tolerate without compromising visual acuity.

In contrast, refraction testing to **correct aphakia does not require cycloplegia**. Here, too, *plus lenses* are required to correct the hyperopia. The closer the plus lens is to the retina, the stronger its refractive power must be to converge incident lights at a point on the retina. For this reason, a cataract lens (Fig. 16.11 b) has a refractive power of about 12 diopters, a contact lens (Fig. 16.11 c) about 14 diopters, an anterior-chamber intraocular lens about 20 diopters (Fig. 16.11 d), and a posterior-chamber lens about 23 diopters.

16.3.3 Astigmatism

Definition

Astigmatism is derived from the Greek word stigma (point) and literally means lack of a focal point. The disorder is characterized by a curvature anomaly of the refractive media such that parallel incident light rays do not converge at a point but are drawn apart to form a line.

Epidemiology: Forty-two per cent of all humans have astigmatism greater than or equal to 0.5 diopters. In approximately 20%, this astigmatism is greater than 1 diopter and requires optical correction.

Pathophysiology: The refractive media of the astigmatic eye are not spherical but *refract differently along one meridian than along the meridian perpendicular to it* (Fig. 16.12). This produces two focal points. Therefore, a *punctiform object* is represented as a sharply defined *line segment* at the focal point of the first meridian but also appears as a sharply defined line segment rotated 90 degrees at the focal point of the second meridian. Midway between these two focal points is what is known as the “*circle of least confusion*.” This refers to the location at which the image is equally distorted in every direction, i.e., the location with the least loss of image definition.

The aggregate system *lacks a focal point*.

The combined astigmatic components of all of the refractive media comprise the **total astigmatism** of the eye. These media include:

- ❖ Anterior surface of the cornea.
- ❖ Posterior surface of the cornea.
- ❖ Anterior surface of the lens.
- ❖ Posterior surface of the lens.

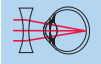


Image formation with an astigmatic cornea.

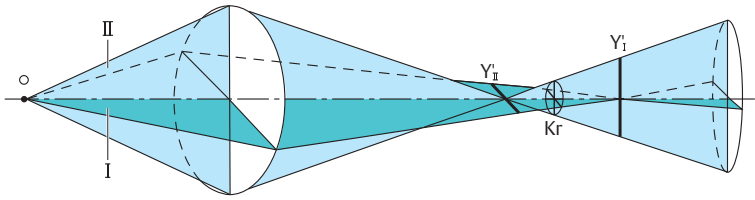


Fig. 16.12 The two main meridians (I and II) are perpendicular to each other. A punctiform object (o) is represented as a line segment Y'_{II} and Y'_I at the focal points of the two meridians. Midway between these two focal points is the “circle of least confusion” (Kr), the location with the least loss of image definition.

Rarely, nonspherical curvature of the retina may also contribute to astigmatism.

Classification and causes: Astigmatism can be classified as follows:

- ❖ **External astigmatism:** astigmatism of the anterior surface of the cornea.
- ❖ **Internal astigmatism:** the sum of the astigmatic components of the other media.

Astigmatism can also be classified *according to the location of the meridian of greater refraction*:

- ❖ **With-the-rule astigmatism** (most common form): The meridian with the greater refractive power is vertical, i.e., between 70 and 110 degrees.
- ❖ **Against-the-rule astigmatism:** The meridian with the greater refractive power is horizontal, i.e., between 160 and 20 degrees.
- ❖ **Oblique astigmatism:** The meridian with the greater refractive power is oblique, i.e., between 20 and 70 degrees or between 110 and 160 degrees.

The discussion up to this point has proceeded from the assumption that the anomaly is a **regular astigmatism** involving only two meridians approximately perpendicular to each other (Fig. 16.12). This is presumably caused by excessive eyelid tension that leads to astigmatic changes in the surface of the cornea.

The condition above should be distinguished from **irregular astigmatism**. Here, the curvature and the refractive power of the refractive media are *completely irregular* (Fig. 16.13a). There are multiple focal points, which produces a completely blurred image on the retina. This condition may be caused by the following diseases:

- ❖ Corneal ulcerations with resulting scarring of the cornea.
- ❖ Penetrating corneal trauma.

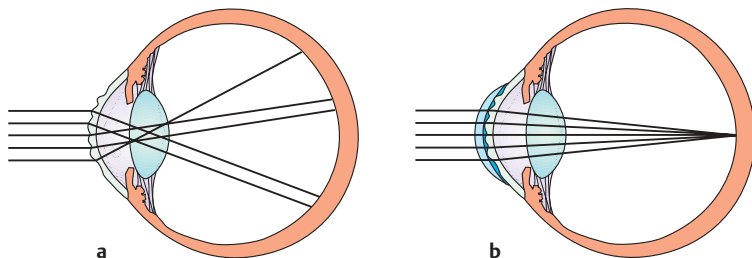
**Irregular corneal astigmatism.**

Fig. 16.13 **a** Curvature and refractive power of the refractive media are totally irregular, resulting in multiple focal points. **b** Correction of irregular corneal astigmatism with a rigid contact lens.

- ❖ Advanced keratoconus.
- ❖ Cataract.
- ❖ Lenticonus.

Symptoms: Patients with astigmatism see everything distorted. Attempts to compensate for the refractive error by accommodation can lead to asthenopic symptoms such as a burning sensation in the eyes or headache.

Diagnostic considerations: The **keratoscope** (Placido disk) permits *gross estimation* of astigmatism. The examiner evaluates the mirror images of the rings on the patient's cornea. In *regular astigmatism*, the rings are *oval*; in *irregular astigmatism*, they are *irregularly distorted*. Computerized corneal topography (**videokeratography**) can be used to obtain an image of the distribution of refractive values over the entire cornea (see Fig. 5.3). A **Helmholtz or Javal ophthalmometer** can be used to *measure the central corneal curvature*, which determines the refractive power of the cornea (Fig. 16.14).

Treatment: Early correction is crucial. Untreated astigmatism in children will eventually lead to uncorrectable refractive amblyopia because a sharp image is not projected on the retina.

Treatment of regular astigmatism: The purpose of the correction is to bring the “focal lines” of two main meridians together at one focal point. This requires a lens that *refracts in only one plane*. **Cylinder lenses** are required for this application (Fig. 16.15 a). Once the two “focal lines” have been converged into a focal point, **additional spherical lenses** can be used to shift this focal point on to the retina if necessary.



Diagnosis of corneal astigmatism with an ophthalmometer.

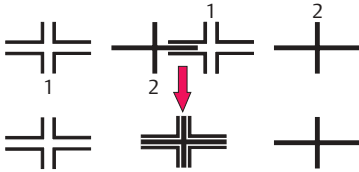


Fig. 16.14 The diagram shows the corneal reflex images (outline cross [1] and solid cross [2]) of the Zeiss ophthalmometer. These images are projected on to the cornea; the distance between them will vary depending on the curvature of the cornea. The examiner must align the images by changing their angle of projection. After aligning them, the examiner reads the axis of the main meridian, the corneal curvature in millimeters, and the appropriate refractive power in diopters on a scale in the device. This measurement is performed in both main meridians. The difference yields the astigmatism. In irregular astigmatism, the images are distorted, and often a measurement cannot be obtained.

Correction of regular astigmatism with cylinder lenses.

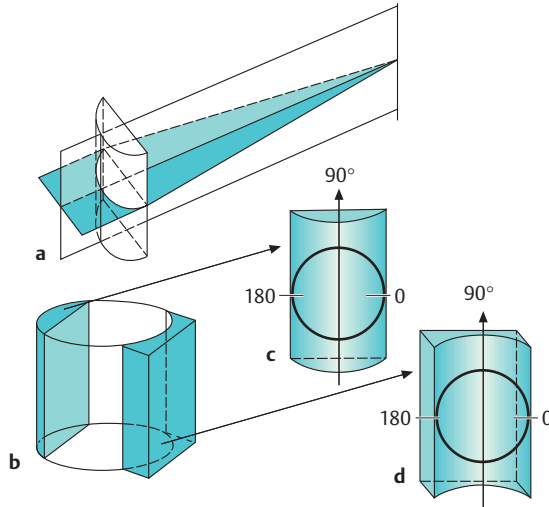


Fig. 16.15 **a** Cylinder lenses refract light only in the plane perpendicular to the axis of the cylinder. The axis of the cylinder defines the nonrefracting plane. **b–d** Cylinder lenses can be manufactured as plus cylinders (**c**) or minus cylinders (**d**).



Treatment of irregular astigmatism: This form *cannot* be corrected with eyeglasses. *External astigmatism* may be managed with a rigid contact lens (Fig. 16.13 b), keratoplasty, or surgical correction of the refractive error. Irregular *internal astigmatism* is usually lens-related. In this case, removal of the lens with implantation of an intraocular lens is indicated.



Only regular astigmatism can be corrected with eyeglasses.

16.3.4 Anisometropia

Definition

In anisometropia, there is a difference in refractive power between the two eyes.

Epidemiology: Anisometropia of at least 4 diopters is present in less than 1% of the population.

Etiology: The reason for the varying development of the two eyes is not clear. This primarily congenital disease is known to exhibit a familial pattern of increased incidence.

Pathophysiology: In anisometropia, there is a difference in refractive power between the two eyes. This refractive difference can be corrected separately for each eye with different lenses as long as it *lies below 4 diopters*. Where the difference in refraction is greater than or equal to 4 diopters, the size difference of the two retinal images becomes too great for the brain to fuse the two images into one. Known as **aniseikonia**, this condition jeopardizes binocular vision because it can lead to development of amblyopia (*anisometropic amblyopia*). The aniseikonia, or differing size of the retinal images, depends not only on the degree of refractive anomaly but also depends significantly on the **type of correction**. The closer to the site of the refraction deficit the correction is made, the less the retinal image changes in size. Correction with *intraocular lenses* results in almost no difference in image size. Contact lenses produce a slight and *usually irrelevant difference in image size*. However, *eyeglass correction* resulting in a difference of *more than 4 diopters* leads to *intolerable aniseikonia* (see Table 7.4).

Symptoms: Anisometropia is usually congenital and *often asymptomatic*. Children are not aware that their vision is abnormal. However, there is a tendency toward strabismus as binocular functions may remain underdeveloped. Where the correction of the anisometropia results in unacceptable aniseikonia, patients will report unpleasant visual sensations of *double vision*.



Diagnostic considerations: Anisometropia is usually diagnosed during routine examinations. The diagnosis is made on the basis of refraction testing.

Treatment: The refractive error should be corrected. Anisometropia exceeding 4 diopters cannot be corrected with **eyeglasses** because of the clinically relevant aniseikonia. **Contact lenses** and, in rare cases, surgical treatment are indicated. Patients with unilateral aphakia or who do not tolerate contact lenses will require implantation of an **intraocular lens**.



Correction of unilateral aphakia with unilateral glasses is usually contraindicated because it results in aniseikonia of approximately 25%.

16.4 Impaired Accommodation

16.4.1 Accommodation Spasm

Definition

An accommodation spasm is defined as inadequate protracted contraction of the ciliary muscle.

Etiology: Accommodation spasms are *rare*. They may occur as *functional impairment* or they may occur *iatrogenically* when treating young patients with parasympathomimetic agents (miotic agents). The functional impairments are frequently attributable to heightened sensitivity of the accommodation center, which especially in children (often girls) can be psychogenic. *Rarely* the spasm is due to *organic* causes. In these cases, it is most often attributable to irritation in the region of the oculomotor nuclei (from cerebral pressure or cerebral disorders) or to change in the ciliary muscle such as in an ocular contusion.

Symptoms: Patients complain of deep eye pain and blurred distance vision (lenticular myopia).

Diagnostic considerations and differential diagnosis: The diagnosis is made on the basis of presenting symptoms and refraction testing, including measurement of the range of accommodation. This is done with an accommodometer, which determines the difference in refractive power between the near point and far point. A *differential diagnosis* should exclude latent hyperopia. In children, this will frequently be associated with accommodative esotropia and accommodative pupil narrowing.

Treatment: This depends on the underlying disorder. Cycloplegic therapy with agents such as tropicamide or cyclopentolate may be attempted in the presence of recurrent accommodation spasms.



Prognosis: Iatrogenic spasms are completely reversible by discontinuing the parasympathomimetic agents. The prognosis is also good for patients with functional causes. Spasms due to organic causes require treatment of the underlying disorder but once treatment is initiated the prognosis is usually good.

16.4.2 Accommodation Palsy

Definition

Failure of accommodation due to palsy of the ciliary muscle.

Etiology: This rare disorder is primarily to one of the following causes:

- ❖ **Iatrogenic drug-induced palsy** due to parasympatholytic agents such as atropine, cyclopentolate, scopolamine, homatropine, and tropicamide.
- ❖ **Peripheral causes:** Oculomotor palsy, lesions of the ciliary ganglion, or the ciliary muscle.
- ❖ **Systemic causes:** Damage to the accommodation center in diphtheria, diabetes mellitus, chronic alcoholism, meningitis, cerebral stroke, multiple sclerosis, syphilis, lead or ergotamine poisoning, medications such as isoniazid or piperazine, and tumors.

Symptoms: The failure of accommodation leads to blurred near vision and may be associated with mydriasis where the sphincter pupillae muscle is also involved. The clinical syndromes listed below exhibit a specific constellation of clinical symptoms and therefore warrant further discussion.

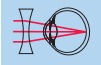
- ❖ **Post-diphtheria accommodation palsy:** This transitory palsy is a toxic reaction and occurs *without* pupillary dysfunction approximately four weeks after infection. Sometimes it is associated with palsy of the soft palate and/or impaired motor function in the lower extremities.
- ❖ **Accommodation palsy in botulism:** This is also a toxic palsy. It *does* involve the pupil, producing *mydriasis*, and can be the first symptom of botulism. It is associated with speech, swallowing, and ocular muscle dysfunction accompanied by double vision.
- ❖ **Tonic pupillary contraction** is associated with tonic accommodation.
- ❖ **Sympathetic ophthalmia** is characterized by a decrease in the range of accommodation, even in the unaffected eye.



Measurement of the range of accommodation is indicated whenever sympathetic ophthalmia is suspected.

Diagnostic considerations: In addition to measuring the range of accommodation with an accommodometer, the examiner should inquire about other ocular and general symptoms.

Treatment: This depends on the underlying disorder.



Prognosis: The clinical course of **tonic pupillary contraction** is chronic and results in irreversible loss of accommodation. The **toxic accommodation palsies** are reversible once the underlying disorder is controlled.

16.5 Correction of Refractive Errors

16.5.1 Eyeglass Lenses

Monofocal Lenses

There are two basic types.

- ❖ **Spherical lenses** refract light equally along every axis.
- ❖ **Toric lenses** (known as cylindrical lenses) refract light only along one axis. Spherical and toric lenses can be combined where indicated.

The **refractive power of the lenses** is measured manually or automatically with an optical interferometer. The measured refraction is specified as *spherocylindrical combination*. By convention, the specified axis of the cylindrical lens is perpendicular to its axis of refraction (Fig. 16.15c and d). The orientation of this axis with respect to the eye is specified on a standardized form (Fig. 16.16).

Example: +4.00 diopters -2.00 diopters/90 degrees means that the lens represents a combination of converging lens (+4 diopters) and cylindrical lens (-2 diopters) with its axis at 90 degrees.



Eyeglass lenses exhibit typical characteristics when moved back and forth a few inches in front of one's eye. Objects viewed through minus lenses appear to move in the same direction as the lens; objects viewed through plus lenses move in the opposite direction. A cylindrical lens produces image distortions when turned.

Multifocal Lenses

Multifocal lenses differ from the monofocal lenses of uniform refractive power discussed in the previous section in that different areas of the lens have different refractive powers. These lenses are best understood as *combinations of two or more lenses in a single lens*.

Bifocals: The *upper and middle portion of the lens* is ground for the *distance correction*; the lower portion is ground for the *near-field correction* (Fig. 16.17a and b). Patients are able to view distant objects in focus and read using *one pair* of eyeglasses, eliminating the need to constantly change glasses. The gaze is lowered and converged to read. This portion of the lens contains the near-field correction. This near-field correction can be placed in a different part of the lens for special applications.

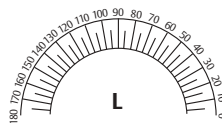
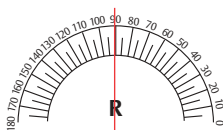


Eyeglass prescription.

Eyeglass prescription

for Mr./Mrs./M. _____

		Spherical	Cylindrical	Axis	Prism.	Base	Vertex distance
F	R	+ 4.0	- 2.0	90°	4	down	14
	L			°			
N	R			°			
	L			°			



Typ of spectacles: _____

Comments: _____

Date _____

Signature _____

Fig. 16.16 The refraction values for the right eye have been filled in. The cylindrical axis has also been entered (red line). The diagram specifies the position of the cylindrical axis with respect to the eye. A perpendicular cylindrical axis (red line) corresponds to 90 degrees on the standard form.

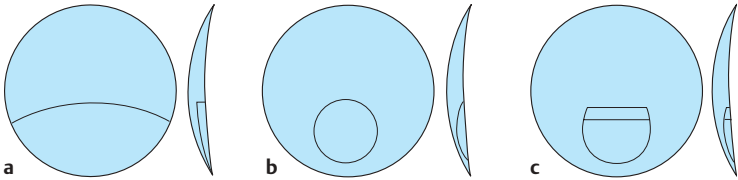
**Multifocal lenses.**

Fig. 16.17 **a** and **b** Bifocals. **c** Trifocals.

Trifocals: These lenses include a *third refractive correction* between the distance and near-field portions. This intermediate portion *sharply images the intermediate field between distance vision and reading range* without any need for accommodation (Fig. 16.17 **c**).

Progressive addition lenses: These lenses were developed to *minimize abrupt image changes* when the gaze moves through the different correction zones of the lens while *maintaining a sharp focus at every distance* (Fig. 16.18).

These eyeglasses also offer cosmetic advantages. They produce *well focused images in the central region* but have a *high degree of peripheral astigmatism*. However, many patients learn to tolerate this peripheral distortion.



Presbyopic patients tolerate progressive addition lenses better when they still have only slight presbyopia and have not previously worn bifocals.

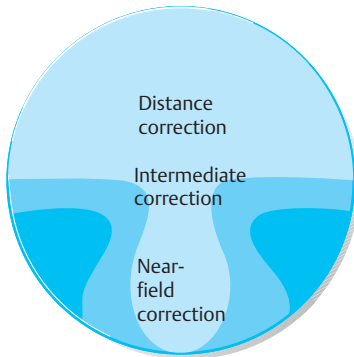
Progressive addition lenses.

Fig. 16.18 These lenses provide a smooth transition between the distance correction (upper portion), intermediate correction (middle portion), and near-field correction (lower portion), with continuously increasing refractive power. Clear vision is limited to only the light blue area. The stronger the Add in the near field, the narrower this light blue corridor becomes. At the same time, this increases the peripheral optical distortion (dark blue) outside the corridor.



Special Lenses

The following types of lenses have been developed for special applications:

Plastic lenses: These lenses reduce the weight of eyeglasses where severe ametropia must be corrected. Another advantage is that these lenses are largely shatterproof, which is why they are preferred for children. However, they are easily scratched.

Absorption lenses: These lenses are indicated in patients with *increased sensitivity to glare*.

! Operating motor vehicles in twilight or at night with eyeglasses that absorb more than 20% of incident light is dangerous because of the resulting reduction in visual acuity.

Photochromatic lenses: These lenses darken in response to the intensity of ultraviolet light. The lenses become darker at low temperatures than at high temperatures; they lighten more slowly at low temperatures and more rapidly at high temperatures. Light attenuation ranges between 15 and 50% in some lenses and between 30 and 65% in others.

! Photochromatic lenses pose problems for patients operating motor vehicles. The lenses darken only slightly in a warm car with the windows closed due to the lack of ultraviolet light. Dark lenses lighten too slowly when the car enters a tunnel.

Coated lenses: Extremely thin coatings of magnesium fluoride can be applied to lenses to reduce surface reflection on the front and back of the lens.

Subjective Refraction Testing for Eyeglasses

While the patient looks at vision charts, the examiner places various combinations of lenses in front of the patient's eye. The patient reports which of two lenses produces the sharper image. The better of the two is then compared with the next lens. This incremental method identifies the optimal correction. It is expedient to use the patient's objective refraction as the starting point for subjective testing. Refraction testing is performed either with a series of **test lenses** from a case or with a **Phoropter**, which contains many lenses that can be automatically or manually placed before the patient's eye.

The examination proceeds in three stages:

❖ **Monocular testing:** The optimal refraction for achieving best visual acuity is determined *separately for each eye*. The weakest possible minus lens is used in *myopic patients*, and the strongest possible plus lens in *hyperopic patients*. The red-green chromatic aberration test can be used for fine refraction. In this test, the patient compares optotypes on green and red backgrounds. Fine adjustment of refraction permits precise shifting of the



focal point of the light on the retina. Optotypes on both red and green backgrounds then appear equally sharply defined.

- ❖ **Binocular testing:** The objective of this stage is to achieve a *balance* between both eyes.
- ❖ **Near point testing:** The final stage of the examination determines the patient's *near visual acuity*, and, if necessary, the *presbyopic addition* ("Add"). Allowance is made for the patient's preferred reading and working position.

The values determined by this examination are entered in the eyeglass prescription (see Fig. 16.16). The **vertex distance** at which refraction was performed is an important additional parameter for the optician. This is the *distance between the back surface of the test lens and the anterior surface of the cornea*. If the manufactured eyeglasses have a different vertex distance, then the strength of the lenses should be altered accordingly. This is because the optical effect of eyeglass lenses varies according to the distance from the eye.

Before the lenses are fitted into the frame, the **distance between the pupils** must be measured to ensure that the lenses are properly centered. The *center of the lens* should be *in front of the pupil*. The prismatic effects of eccentric lenses might otherwise cause asthenopic symptoms such as headache or a burning sensation in the eyes.



To facilitate early detection of glaucoma, intraocular pressure should be measured in any patient over the age of 40 presenting for refraction testing for eyeglasses.

16.5.2 Contact Lenses

16.5.2.1 Advantages and Characteristics of Contact Lenses

Contact lenses are in immediate contact with the cornea. Although they are foreign bodies, most patients adapt to properly fitted contact lenses. Contact lenses differ from eyeglasses in that they correct the refractive error closer to the location of its origin. For this reason, the *quality of the optical image viewed through contact lenses is higher than that viewed through eyeglasses*. Contact lenses have significantly less influence on the size of the retinal image than does correction with eyeglasses. Lenses do not cloud up in rainy weather or steam, and peripheral distortion is minimized. The cosmetic disadvantage of thick eyeglasses in *severe ametropia* is also eliminated. *Severe anisometropia* requires correction with contact lenses for optical reasons, i.e., to minimize aniseikonia.

Contact lenses are defined by the following **characteristics**:

- ❖ Diameter of the contact lens.
- ❖ Radius of curvature of the posterior surface.



- ❖ Geometry of the posterior surface, i.e., spherical, aspherical, complex curvature, or toric.
- ❖ Refractive power.
- ❖ Material.
- ❖ Oxygen permeability of the material (Dk value).

The cornea requires oxygen from the precorneal tear film. To ensure this supply, *contact lens materials must be oxygen-permeable*. This becomes all the more important the less the contact lens moves and permits circulation of tear fluid. Contact lenses may be manufactured from *rigid* or *flexible* materials.

Rigid Contact Lenses

These contact lenses have a stable, nearly unchanging shape. Patients *take some time to become used to them* and should therefore wear them often. The goal is to achieve the best possible intimacy of fit between the posterior surface of the lens and the anterior surface of the cornea (Fig. 16.19). This allows the contact lens to float on the precorneal tear film. Every time the patient blinks, the lens is displaced superiorly and then returns to its central position. This permits circulation of the tear film.

Previously, polymethyl methacrylate (PMMA) was used as a material. However, this is practically impermeable to oxygen. The lenses were fitted in small diameters with a very shallow curvature; the central area maintained contact with the cornea while the periphery projected. This allowed excellent tear film circulation, and patients were able to wear the lenses for surprisingly long periods. *Today*, highly oxygen-permeable materials such as silicone

Fit of a rigid contact lens.

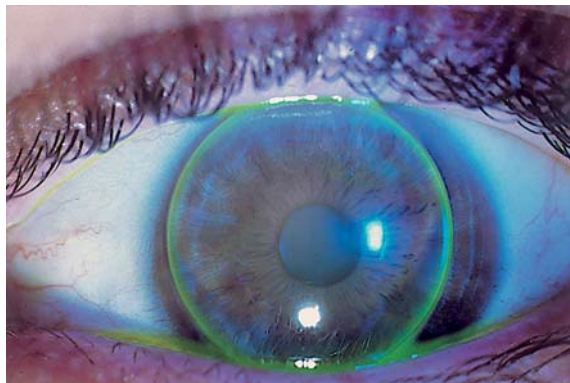


Fig. 16.19 A tear film lies between the anterior surface of the cornea and the posterior surface of the lens (visualized by fluorescein dye).



copolymers are available. This eliminates the time limit for *daily wearing*. These lenses may also remain in the eye overnight in special cases, such as aphakic patients with poor coordination (*prolonged wearing*).

Rigid contact lenses can be manufactured as *spherical lenses* and *toric lenses*. **Spherical** contact lenses can almost completely compensate for **corneal astigmatism of less than 2.5 diopters**. This is possible because the space between the posterior surface of the spherical contact lens and the anterior surface of the astigmatic cornea is filled with tear fluid that forms a “*tear lens*.” Tear fluid has nearly the same refractive index as the cornea. **More severe corneal astigmatism** or **internal astigmatism** requires correction with **toric** contact lenses. Rigid contact lenses can even correct severe **keratoconus**.

Soft Contact Lenses

The material of the contact lens, such as hydrogel, is soft and pliable. Patients find these lenses *significantly more comfortable*. The *oxygen permeability* of the material depends on its water content, which may range from 36% to 85%. The higher the water content, the better the oxygen permeability. However, it is typically *lower* than that of *rigid lenses*. The material is more permeable to foreign substances, which can accumulate in it. At 12.5–16 mm, flexible lenses are larger in diameter than rigid lenses. Flexible lenses are often supported by the limbus. The lens is often displaced only a few tenths of a millimeter when the patient blinks. This *greatly reduces the circulation of tear film under the lenses*. This limits the *maximum daily period* that patients are able to wear them and requires that they be removed at night to allow regeneration of the cornea. Deviation from this principle is only possible in exceptional cases under the strict supervision of a physician.

As the lenses are almost completely in contact with the surface of the cornea, *corneal astigmatism cannot be corrected with spherical soft lenses*. This requires toric soft lenses.

Special Lenses

The following types of special lenses are available for specific situations:

Therapeutic contact lenses: In the presence of **corneal erosion**, soft ultrathin (0.05 mm) contact lenses act as a bandage and thereby accelerate re-epithelialization of the cornea. They also reduce pain. Soft contact lenses may also be used in patients receiving topical medication as they store medication and only release it very slowly.

Corneal shields: These are collagen devices that resemble contact lenses. These shields are gradually broken down by the collagenase in the tear film. They are used as **bandages** and **substrates for topical medication** in the treatment of anterior disorders, such as erosion or ulcer.



Iris print lenses: These colored contact lenses with a clear central pupil are used in patients with **aniridia** and **albinism**.

They produce good cosmetic results, reduce glare, and can correct a refractive error where indicated.

Bifocal contact lenses: These lenses were developed to allow the use of contact lenses in **presbyopic patients**. As in eyeglasses, a *near-field correction* is ground into the lens. This near-field portion is always located at the bottom of the lens because the lens is heavier there. When the patient gazes downward to read, the immobile lower eyelid pushes this near-field portion superiorly where it aligns with the pupil and becomes optically effective. Another possibility is *diffraction* (bending of light rays as opposed to refraction) through concentric rings on the posterior surface of the contact lens. This produces two images, a distant refractive image and a near-field diffractive image. The patient chooses the image that is important at the moment. It is also possible to correct one eye for distance vision and the fellow eye for near vision (*monocular vision*).

Disadvantages of Contact Lenses

Contact lenses exert mechanical and metabolic influences on the cornea. Therefore, they require the *constant supervision of an ophthalmologist*.

Mechanical influences on the cornea can lead to *transient changes in refraction*. “Spectacle blur” can result when eyeglasses suddenly no longer provide the proper correction after removing the lens. Contact lenses require careful *daily cleaning* and disinfection. This is more difficult, time-consuming, and more expensive than eyeglass care and is particularly important with soft lenses.

Metabolic influences on the cornea: The macromolecular mesh of material absorbs proteins, protein breakdown products, low-molecular-weight substances such as medications and disinfectants, and bacteria and fungi. Serious complications can occur where daily care of the contact lenses is inadequate. With their threshold oxygen permeability, soft contact lenses interfere with corneal metabolism. Contact lenses are less suitable for patients with symptoms of keratoconjunctivitis sicca.

Contact Lens Complications

Complications have been observed primarily in patients wearing *soft* contact lenses. These include:

Infectious keratitis (corneal infiltrations and ulcers) caused by bacteria, fungi, and protozoans.



! *Acanthamoeba* keratitis is a serious complication affecting wearers of soft contact lenses and often requires penetrating keratoplasty.

Giant papillary conjunctivitis: This is an allergic reaction of the palpebral conjunctiva of the upper eyelid to denatured proteins. It results in proliferative “cobblestone” conjunctival lesions.

Corneal vascularization may be interpreted as the result of insufficient supply of oxygen to the cornea.

Severe chronic conjunctivitis: This usually makes it impossible to continue wearing contact lenses.

16.5.3 Prisms

Prisms can change the direction of parallel light rays. The optical strength of a prism is specified in *prism diopters*. Prism lenses can be combined with spherical and toric lenses. When prescribing eyeglasses, the ophthalmologist specifies the strength and the position of the base of the prism. Prism lenses are used to correct heterophoria (latent strabismus) and ocular muscle palsies, and in preparation for surgery to correct strabismus.

! A 1 diopter prism deflects a ray of light 1 cm at a distance of 1 m from the base of the prism.

16.5.4 Magnifying Vision Aids

The **reduction in central corrected visual acuity** as a result of destruction of the fovea with a central scotoma requires magnifying vision aids. However, magnification is always associated with a *reduction in the size of the visual field*. As a result, these vision aids require patience, adaptation, motivation, and dexterity. Cooperation between ophthalmologist and optician is often helpful. The following **systems** are available in order of magnification.

Increased near-field corrections: The stronger the near-field correction, the shorter the reading distance. Magnification (V) is a function of the refractive power of the near-field correction (D) and is determined by the equation $V = D/4$.

Example: Eyeglasses with a 10 diopter near-field correction magnify the image two and one-half powers. However, the object must be brought to within 10 cm of the eye.

Magnifying glasses are available in various strengths, with or without illumination.



Monocular and binocular loupes, telescopes, and prism loupes: An optical magnifying system is mounted on one or both eyeglass lenses. The optical system functions on the principle of Galilean or Keplerian optics.

Closed-circuit TV magnifier: This device displays text at up to 45 power magnification.

16.5.5 Aberrations of Lenses and Eyeglasses

Optical lens systems (eyeglasses or lenses) always have minor aberrations. These aberrations are not material flaws, rather they are due to the laws of physics. Expensive optical systems can reduce these aberrations by using many different lenses in a specific order.

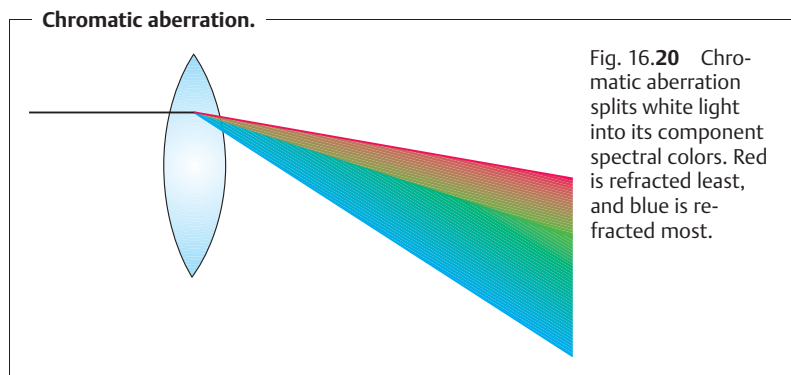
Chromatic Aberration (Dispersion)

This means that **the refractive power of the lens varies according to the wavelength of the light.**

Light consists of a blend of various wavelengths. Light with a *short wavelength* such as blue is refracted more than light with a *long wavelength* such as red (Fig. 16.20). This is why monochromatic light (light of a single wavelength) produces a sharper image on the retina.

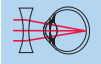


Chromatic aberration is the basis of the red-green test used for fine refraction testing.



Spherical Aberration

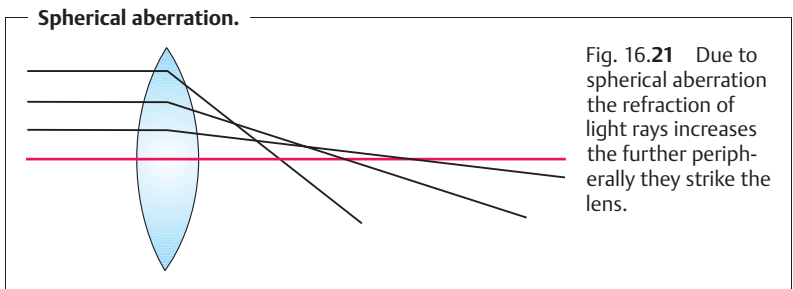
This means that **the refractive power of the lens varies according to the location at which the light ray strikes the lens.**



- ! Patients may report being able to see better when looking through a disk with a pinhole (a stenopeic aperture) than without it. This usually is a sign of an uncompensated refractive error in the eye.

The further peripherally the light ray strikes the lens, the more it will be refracted (Fig. 16.21). The iris intercepts a large share of these peripheral light rays. A narrow pupil will intercept a particularly large share of peripheral light rays, which improves the *depth of field*. Conversely, *depth of field is significantly poorer* when the pupil is dilated.

- ! Patients who have received mydriatic agents should refrain from driving.



Astigmatic Aberration

A punctiform object **viewed through a spherical lens** appears as a line.

If one looks through a lens obliquely to its optical axis, it will act as a *prism* (Fig. 16.22 a). A prism refracts a light ray toward its base (Fig. 16.22 b). In addition to this, the light is split into its component spectral colors. Light with a *short wavelength* (blue) is refracted more than light with a *long wavelength* (red). Astigmatic aberration is an undesired side effect that is present whenever one looks through a lens at an oblique angle.

This phenomenon should be distinguished from *astigmatic or toric lenses*, which correct for astigmatism of the eye when the patients looks through them *along the optical axis*.

Curvature of Field

This means that the **magnification of the image changes as one approaches the periphery**. The result is a sharp image with peripheral curvature. Convex or plus lenses produce *pincushion distortion*; concave or minus lenses produce *barrel distortion* (Fig. 16.23).



Astigmatic aberration.

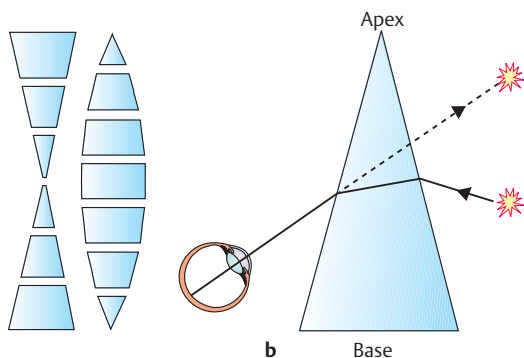


Fig. 16.22 **a** Lenses may be regarded as composed of many prisms, which explains many of the optical phenomena of lenses such as dispersion. **b** A prism refracts a light ray toward its base twice (solid line). However, it appears to the observer that the object is shifted toward the apex of the prism (dotted line).

Curvature of field.

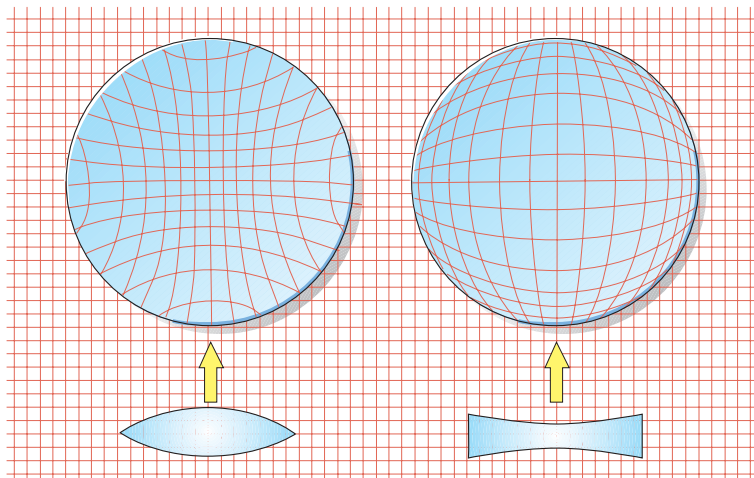
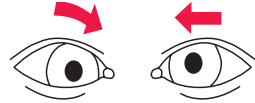


Fig. 16.23 Viewing an object through plus lenses produces pincushion distortion of the image, whereas minus lenses produce barrel distortion.

17 Ocular Motility and Strabismus

Doris Recker, Josef Amann, and Gerhard K. Lang



Definition

Strabismus is defined as deviation of an eye's visual axis from its normal position.

There are **two major types of manifest strabismus or heterotropia**:

1. **Concomitant strabismus** (from the Latin "comitare", accompany). The deviating eye *accompanies* the leading eye in every direction of movement. The angle of deviation remains the same in all directions of gaze. This form of strabismus may occur as monocular strabismus, in which only one eye deviates, or as alternating strabismus, in which both eyes deviate alternately.
2. **Paralytic strabismus** results from paralysis of one or more eye muscles. This form differs from concomitant strabismus in that the angle of deviation does not remain constant in every direction of gaze. For this reason, this form is also referred to as **incomitant strabismus**.

Epidemiology: The incidence of strabismus is about 5–7%. **Esotropia (convergent strabismus)** occurs far more frequently than **exotropia (divergent strabismus)** in Europe and North America. **Concomitant strabismus** usually occurs in children, whereas **paralytic strabismus** primarily affects adults. This is because concomitant strabismus is generally congenital or acquired within the first few years of life, whereas paralytic strabismus is usually acquired, for example as a post-traumatic condition.

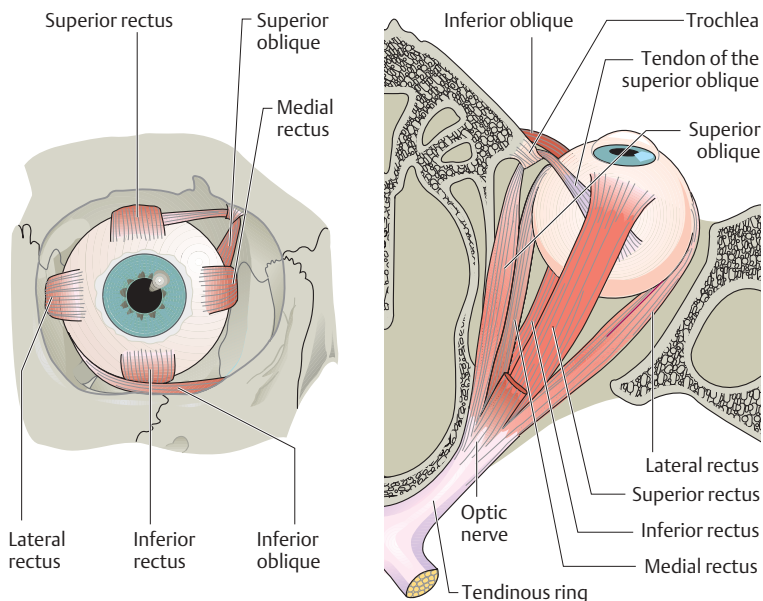
17.1 Basic Knowledge

Ocular motility: The movements of the eyeballs are produced by the following extraocular muscles (Fig. 17.1):

- ❖ The **four rectus muscles**: the superior, inferior, medial, and lateral rectus muscles.
 - ❖ The **two oblique muscles**: the superior and inferior oblique muscles.
- All of these muscles originate at the tendinous ring except for the inferior oblique muscle, which has its origin near the nasolacrimal canal. The *rectus muscles* envelope the globe posteriorly, and their respective tendons insert



Extraocular muscles of the right eye.



Figs. 17.1 **a** and **b** The two oblique ocular muscles insert on the temporal aspect posterior to the equator. The four rectus muscles insert on the superior, inferior, nasal, and temporal sclera.

into the superior, inferior, nasal, and temporal sclera. The *oblique muscles* insert into the temporal globe posterior to the equator. The insertion of the muscles determines the direction of their pull (see Table 17.1).

The connective tissue between the individual ocular muscles is incorporated into the **fascial sheath of the eyeball (Tenon's capsule)**. Other important anatomic structures include the **lateral and medial check ligaments** comprising the lateral connections of the orbital connective tissue and the **ligament of Lockwood**. This is comprised of the ligamentous structures between the inferior rectus and inferior oblique that spread out like a hammock to the medial and lateral rectus muscles.

These anatomic structures and the uniform nerve supply to the extraocular muscles (like acting muscles have like nerve supply) ensure ocular balance. Changes that disturb this balance, such as ocular muscle paralysis that limits or destroys the affected muscle's ability to contract, cause strabismus. The angle of deviation is a sign of abnormal imbalance.



Direction of pull of the extraocular muscles: The **horizontal ocular muscles** pull the eye in only *one* direction: The lateral rectus pulls the eye outward (*abduction*); the medial rectus pulls it inward (*adduction*). **All other extraocular muscles** have a *secondary direction of pull* in addition to the primary one. Depending on the path of the muscle, where it inserts on the globe, and the direction of gaze (Fig. 17.1), these muscles may elevate or depress the eye, adduct or abduct it, or rotate it medially (intorsion) or laterally (extorsion). The primary action of the superior rectus and superior oblique is *elevation*; the primary action of the inferior rectus and inferior oblique is *depression*. Table 17.1 shows the primary and secondary actions of the six extraocular muscles. A knowledge of these actions is important to understanding paralytic strabismus.

Nerve supply to the extraocular muscles: The oculomotor nerve (third cranial nerve) supplies all of the extraocular muscles except the superior oblique, which is supplied by the trochlear or fourth cranial nerve, and the lateral rectus, which is supplied by the abducent or sixth cranial nerve (see Table 17.1). The **extraocular muscle nuclei** are located in the brain stem on the floor of the fourth ventricle and are interconnected via the medial longitudinal fasciculus, a nerve fiber bundle connecting the extraocular muscles, neck muscles, and vestibular nuclei for coordinated movements of the head and globe (Fig. 17.2). Various **visual areas** in the brain control eye and gaze movements. The location of the muscle nuclei and knowledge of the visual areas are important primarily in gaze paralysis and paralytic strabismus and of particular interest to the neurologist. For example, the type of gaze paralysis will allow one to deduce the approximate location of the lesion in the brain.



All extraocular muscles except for the superior oblique and lateral rectus are supplied by the oculomotor nerve.

Physiology of binocular vision: Strictly speaking, we “see” with our brain. The eyes are merely the organs of sensory reception. Their images are stored by coding the stimuli received by the retina. The optic nerve and visual pathway transmit this information in coded form to the visual cortex.

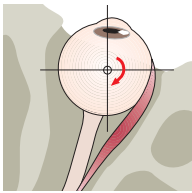
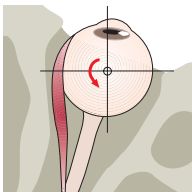
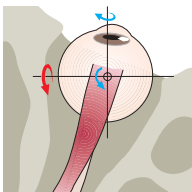
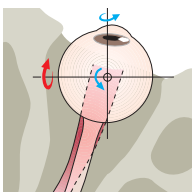
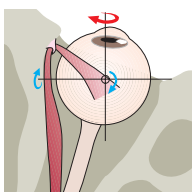
The **sensory system** produces a retinal image and transmits this image to the higher-order centers. The **motor system** aids in this process by directing both eyes at the object so that the same image is produced on each retina. The brain can then process this information into **binocular visual impression**. A person has no subjective awareness of this interplay between sensory and motor systems.

There are **three distinct levels of quality of binocular vision:**

1. **Simultaneous vision:** The retinas of the two eyes perceive two images *simultaneously*. In normal binocular vision, both eyes have the *same point* of fixation, which lands on the fovea centralis in each eye. The image of an



Table 17.1 Function of the extraocular muscles with the gaze directed straight ahead

Muscle	Primary action	Secondary action	Example (right eye)	Nerve supply
Lateral rectus	Abduction	None		Abducent nerve
Medial rectus	Adduction	None		Oculomotor nerve
Superior rectus	Elevation	Intorsion and adduction		Oculomotor nerve
Inferior rectus	Depression	Extorsion and adduction		Oculomotor nerve
Superior oblique	Intorsion	Depression and abduction		Trochlear nerve

Continued →



Table 17.1 (Continued)

Muscle	Primary action	Secondary action	Example (right eye)	Nerve supply
Inferior oblique	Extorsion	Elevation and abduction		Oculomotor nerve

Location of the extraocular muscle nuclei and gaze centers.

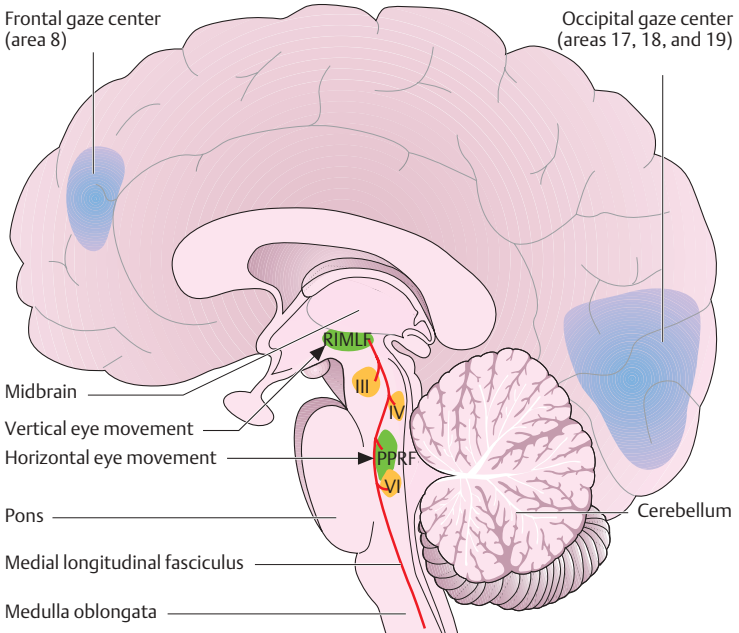


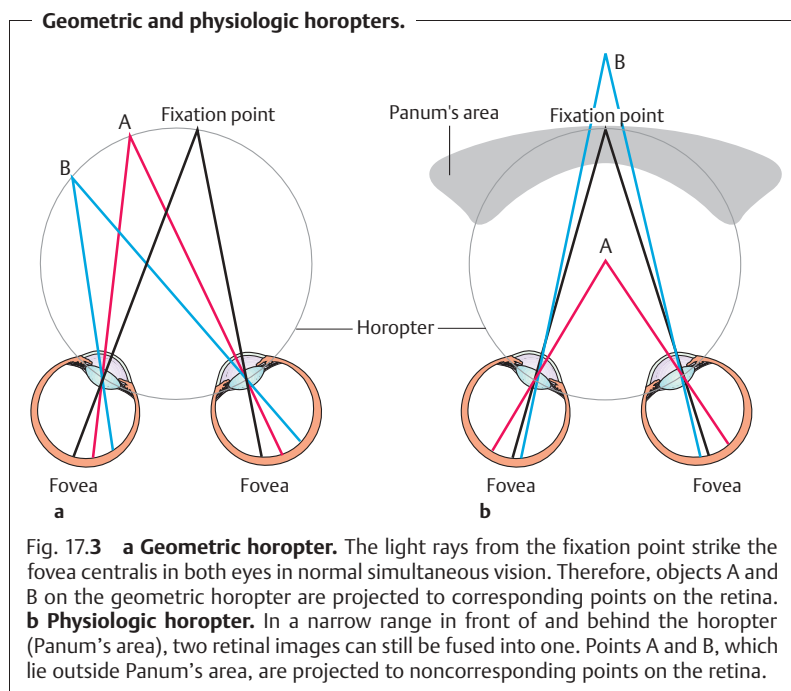
Fig. 17.2 The oculomotor or third cranial nerve supplies all of the extraocular muscles except the superior oblique (supplied by the trochlear or fourth cranial nerve) and the lateral rectus (supplied by the abducent or sixth cranial nerve). The rostral interstitial nucleus of the medial longitudinal fasciculus (RIMLF) is responsible for vertical eye movement and phases of rapid nystagmus. The paramedian pontine reticular formation (PPRF) is responsible for horizontal eye movement.



object always lands on *identical* areas of the retina, referred to as *corresponding points on the retina*. Objects lying on an imaginary circle known as the *geometric horopter* (Fig. 17.3a) are projected to these points on the retina. A different horopter will apply for any given fixation distance. The images of both retinas are therefore identical in normal binocular vision. This phenomenon may be examined by presenting different images to each retina; normally both images will be perceived. This is known as *physiologic diplopia*.

! Physiologic diplopia can be demonstrated by placing two vertical pencils in a line along the subject's visual axis, with the second pencil approximately twice as far from the subject as the first. When the subject focuses on one pencil, the other will appear double.

2. **Fusion:** Only where both retinas convey the same visual impression, i.e., transmit identical images to the brain, will the two retinal images blend into a *single perception*. Impaired fusion can result in double vision (horror fusionis or diplopia).





3. **Stereoscopic vision (perception of depth):** This is the highest level of quality of binocular vision and is possible only where several conditions are met. For objects to be projected to corresponding or identical points on the retina, they must lie on the *same* geometric horopter. Objects lying in front of or behind this circle will not be projected to corresponding points but to *noncorresponding or disparate points* on the retina. The result is that these objects are perceived as double images (diplopia). However, objects within a narrow range in front of and behind the horopter are fused into a *single image*. This area is referred to as *Panum's area*. The brain processes noncorresponding retinal images within Panum's area into a single three-dimensional visual perception and does not interpret them as double images (Fig. 17.3b). On the contrary, the brain uses the double images to distinguish differences in depth.

17.2 Concomitant Strabismus

Definition

Concomitant strabismus differs from paralytic strabismus in that the angle of deviation remains the same in every direction of gaze. The deviating eye follows the normal fellow eye at a constant angle.

Epidemiology: Concomitant strabismus occurs almost exclusively in children. Approximately 5.3–7.4% of all children are affected. In 60–70% of all cases, the disorder initially manifests itself within the first two years of life.

Etiology: Vision at birth is neither focused nor binocular, and both sensorimotor coordination and binocular vision are very unstable during the first few years of life. *Impairments of the sensory or motor systems or central processing of visual perceptions* that occur during this time can disturb the coordination between the eyes and lead to strabismus. However, the causes of concomitant strabismus are often unclear. The following causes have been identified to date:

- ❖ **Genetic factors:** Approximately 60% of children with strabismus have a family history of increased incidence.
- ❖ **Uncorrected refractive errors** are partially responsible for the occurrence of strabismus. Children with *hyperopia* (farsightedness) tend to have *esotropia*. This is because convergence and accommodation are coupled. Children with hyperopia have to accommodate *without converging* when gazing into the distance to compensate for their refractive error. However, accommodation always triggers a convergence impulse that can cause esotropia.
- ❖ **Insufficient fusion:** This can occur in conjunction with *anisometropia* (unequal refractive power in the two eyes) and *aniseikonia* (unequal reti-



nal image size). It can also occur in *heterophoria* (latent strabismus) after one eye has been covered with a bandage for a prolonged period.

- ❖ **Unilateral visual impairment:** Severe nearsightedness, corneal scarring, lens opacities (cataract), macular changes, and retinal disorders can cause secondary strabismus. *Retinal causes* include retinoblastoma, Coats' disease, retinopathy of prematurity, retinal detachment, or central retinal scarring in congenital toxoplasmosis.



Any initial examination of a patient with strabismus must invariably include examination of the fundus of both eyes under mydriasis in addition to examination of the anterior segments of the eye

- ❖ **Other possible causes** of concomitant strabismus include:
 - Perinatal lesions such as preterm birth and asphyxia.
 - Cerebral trauma and encephalitis.

Pathophysiology: Deviation of the visual axis of the deviating eye causes objects to be projected to noncorresponding points on the retina. One would expect these patients suffer from constant double vision because the left and right eyes supply different information to the brain. However, the central nervous system utilizes two mechanisms to help avoid double vision in concomitant strabismus:

1. **Suppression:** A central inhibiting mechanism suppresses the visual stimuli from the deviating eye. There are two different types of suppression:

Central scotoma: This visual field defect occurs when the perceived object is projected to the same location on the fovea in both eyes but strabismus causes the eyes to perceive it as separate objects. As this would cause confusion, the object projected on the fovea of the deviating eye is suppressed.

Fixation point scotoma: This visual field defect occurs when the image perceived by the leading eye is projected to a point *next to the fovea* in the deviating eye. This results in diplopia as the fixation point does not lie within the fovea as it would in physiologic sight. The scotoma occurs at this noncorresponding point next to the fovea to suppress the diplopia.

2. **Sensory adaptation:** In *binocular* vision with the gaze directed straight ahead, the fixation point of the *deviating eye* can fall *beyond* the fovea. This produces *anomalous retinal correspondence* as the fixation point in the nondeviating eye always falls *on* the fovea. This means that the image created in the deviating eye is *not as sharply focused* as the image in the leading eye and is suppressed.

Amblyopia secondary to suppression. Constant suppression in strabismus in the form of a central and fixation scotomas can lead to severe amblyopia, especially in children below the age of six. The prospects for successful treatment decrease with age, and amblyopia becomes irreversible beyond the age



Table 17.2 Forms of amblyopia

Forms of amblyopia	Cause	Treatment
Amblyopia with strabismus	Suppression of the deviating eye	Occlusion therapy
Deprivation amblyopia	Organic disease, such as ptosis or cataract	Early surgery and occlusion therapy in applicable cases
Refractive amblyopia	Different refractive errors	Correction with eyeglasses or contact lenses and occlusion therapy in applicable cases
Bilateral amblyopia	Nystagmus, astigmatism, late correction of refractive errors	None

of six to eight. Amblyopia only occurs in unilateral strabismus. In alternating strabismus, fixation or deviation alternates between both eyes so that both eyes learn to see. A differential diagnosis must distinguish amblyopia in strabismus from other forms of amblyopia. These are listed in Table 17.2.

! Strabismus occurring before the age of six will frequently lead to amblyopia. Early examination and treatment by an ophthalmologist are crucial.

17.2.1 Forms of Concomitant Strabismus

These essentially include the following forms:

- ❖ **Esotropia:** Inward deviation of the visual axis.
- ❖ **Exotropia:** Outward deviation of the visual axis.
- ❖ **Hypertropia and hypotropia:** Ocular deviation with one eye higher or lower than the other.
- ❖ **Cyclotropia:** This refers to the rotation of one eye around its visual axis. An isolated form of strabismus (i.e., one that does not occur in combination with paralytic strabismus), this disorder is extremely rare and therefore will not be discussed in greater detail.

17.2.1.1 Esotropia

Epidemiology: Esotropia is one of the most commonly encountered forms of strabismus.



Symptoms and diagnostic considerations: There are three forms of esotropia:

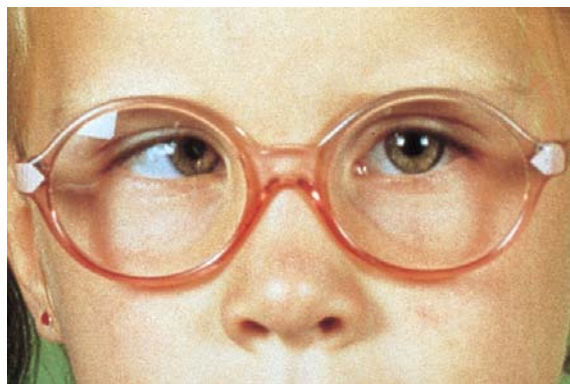1. **Congenital or infantile esotropia:** Strabismus is *present at birth* or develops *within the first six months of life*.

This form is characterized by a large alternating angle of deviation (Fig. 17.4a and b), lack of binocular vision, latent nystagmus (involuntary oscillation of the eyeballs that only occurs or becomes more pronounced when one eye is covered), intermittent inclination of the head in the direction of the leading eye, and additional hypertropia (primary oblique muscle dysfunction and dissociated vertical deviation).

Alternating esotropia.



Fig. 17.4 In this form of strabismus, the eyes take the lead alternately. **a** Eye position when fixating an object on the right.



b Eye position when fixating an object on the left.



Another motility disorder that always occurs in infantile strabismus syndrome is the A or V pattern deviation. This is the result of *anomalous central control*, i.e., anomalies in the pattern of nerve supply to the rectus and oblique muscles.

- ❖ “A pattern deviation” refers to an inward angle of deviation that increases in upgaze and decreases in downgaze.
- ❖ “V pattern deviation” refers to an inward angle of deviation that decreases in upgaze and increases in downgaze.

2. **Acquired strabismus:** Two forms are distinguished:

- ❖ 1. Strabismus begins at *the age of incomplete sensory development*, i.e., between the ages of one and three. Usually the disorder manifests itself at the age of two and leads to sensory adaptation syndromes in the form of *unilateral strabismus*. Amblyopia is usually already present, and correspondence is primarily anomalous.
- ❖ 2. Strabismus *manifests itself between the ages of three and seven*. This form of *acute late strabismus with normal sensory development* is encountered far less frequently than other forms. As binocular vision is already well developed, affected children cannot immediately suppress the visual images of the deviating eye. As a result, they suffer from *sudden* double vision at the onset of strabismus, which they attempt to suppress by closing one eye. *Immediate* treatment is indicated to preserve binocular vision. This consists of the following steps:
 - Objective examination of refraction with the pupils dilated with atropine or cyclopentolate is performed to determine whether a refractive error is present. Clinical experience has shown that moderate and severe hyperopia will be detected more frequently than in the congenital form.
 - The angle of deviation is precisely determined and corrected with prism eyeglasses.
 - Surgery is indicated if eyeglass correction fails to improve the angle of deviation within a few weeks or the eyes are emmetropic.



Binocular vision is well developed in late strabismus with normal sensory development. Surgery within three to six months will allow the patient to maintain or regain stereoscopic vision.

3. **Microstrabismus:** This is defined as unilateral esotropia with a *minimal cosmetic effect*, i.e., an angle of deviation of 5 degrees or less. As a result, microstrabismus is often diagnosed too late, i.e., only at the age of four to six. By that time the resulting amblyopia in the deviating eye may be severe. Another sequela of microstrabismus is anomalous retinal correspondence. Binocular vision is partially preserved despite anomalous retinal correspondence and amblyopia. However, it can no longer be improved by treatment. For this reason, treatment is limited to occlusion therapy to correct the amblyopia.



17.2.1.2 Abnormal Accommodative Convergence/Accommodation Ratio

When the accommodative convergence/accommodation ratio is abnormal, the angle of deviation may fluctuate depending on whether the fixated object is far or near. For example in *accommodative esotropia*, the angle of deviation is larger with close objects than with distant objects. The disorder is corrected with bifocal eyeglasses, which in the case of accommodative esotropia have a strong near-field correction (Fig. 17.5a and b). A residual angle of deviation may remain despite the eyeglass correction. However, the angle of deviation may also improve to the point that the visual axes are parallel with good binocular vision.

Accommodative esotropia in the right eye.



Fig. 17.5 a Gaze is directed through the distance portion of bifocals.



b Gaze is directed through the near-field portion of the bifocals. The arrow indicates the dividing line between the distance and near-field portions.



An abnormal accommodative convergence/accommodation ratio will cause fluctuations in ocular deviation in near and distance fixation.

17.2.1.3 Exotropia

Exotropia (divergent strabismus) is less common than esotropia. As it is usually acquired, the disorder is encountered more often in adults than in children, who more frequently exhibit esotropia. Exotropia less frequently leads to amblyopia because the strabismus is often alternating. Occasionally what is known as “*panorama vision*” will occur, in which case the patient has an expanded binocular field of vision. The following forms are distinguished:

- ❖ **Intermittent exotropia.** This is the *most common form* of divergent strabismus. In intermittent exotropia, an angle of deviation is present only when the patient gazes into the distance; the patient has normal binocular vision in near fixation (Figs. 17.6a and b). The image from the deviating eye is suppressed in the deviation phase. This form of strabismus can occur as a *latent disorder* in mild cases, meaning that the intermittent exotropia only becomes manifest under certain conditions, such as fatigue.
- ❖ **Secondary exotropia** occurs with reduced visual acuity in one eye resulting from disease or trauma.
- ❖ **Consecutive exotropia** occurs after esotropia surgery. Often the disorder is overcorrected.

17.2.1.4 Vertical Deviations (Hypertropia and Hypotropia)

Like A pattern and V pattern deviations, vertical deviations are also typically caused by anomalies in the pattern of nerve supply to the rectus and oblique muscles. Vertical deviations are usually associated with esotropia or exotropia, for example in infantile strabismus. Primary oblique muscle dysfunction and dissociated vertical deviation are common in this setting.

Primary oblique muscle dysfunction is characterized by *upward vertical* deviation of the adducting eye during *horizontal* eye movements.

Dissociated vertical deviation is *alternating upward deviation of the eyes*. The respective non-fixating eye or the eye occluded in the cover test will be elevated.

17.2.2 Diagnosis of Concomitant Strabismus

17.2.2.1 Evaluating Ocular Alignment with a Focused Light

This is a fundamental examination and is usually the first one performed by the ophthalmologist in patients with suspected concomitant strabismus. The examiner holds the light beneath and close to his or her own eyes and observes the light reflexes on the patient's corneas (*Hirschberg's method*) in



Intermittent exotropia in the right eye.

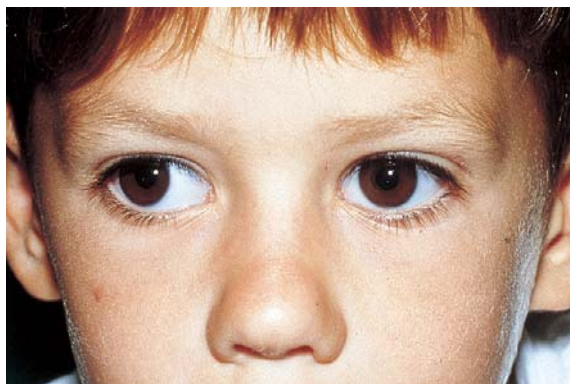
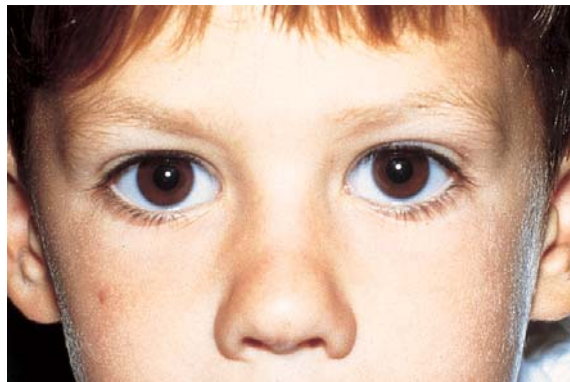
Fig. 17.6 a The right eye deviates in distance fixation.



b No deviation is present in near fixation.

near fixation at a distance of 30 cm. Normally, these reflexes are symmetrical. Strabismus is present if the corneal reflex deviates in one eye. The corneal reflexes are symmetrical in normal binocular vision or pseudostrabismus; in esotropia, exotropia, and vertical deviation, they are asymmetrical.

17.2.2.2 Diagnosis of Infantile Strabismic Amblyopia (Preferential Looking Test)

Strabismus occurs most frequently in the newborn and infants and must also be treated at this age to minimize the risk of visual impairment. As the examiner cannot rely on patient cooperation at this age, examination techniques requiring minimal patient cooperation are necessary. The preferential



looking test can be used for early evaluation of vision beginning at the age of four to six months. This test cannot reliably detect strabismic amblyopia. However, Teller acuity cards (Fig. 17.7) are sufficiently sensitive for early detection of deficits in the presence of *defects of the entire visual system*.

Procedure: The infant is shown a card (Teller acuity card) with the same background brightness. The examiner is hidden behind a viewing case that covers him or her from the front and side. An observation pinhole in the middle of the card permits the examiner to observe only the infant's eyes and determine upon which side of the card the infant is fixating. Infants who prefer the striped side have good fixation.

17.2.2.3 Diagnosis of Unilateral and Alternating Strabismus (Unilateral Cover Test)

A unilateral cover test can distinguish between manifest unilateral strabismus and alternating strabismus. The patient is requested to fixate on a point. The examiner then covers one eye and observes the uncovered eye (Fig. 17.8a – c).

- ❖ In **unilateral strabismus**, the *same eye always deviates*. When the deviating eye is covered, the uncovered eye (the leading, nondeviating eye) remains focused on the point of fixation. When the nondeviating eye is covered, the uncovered deviating eye has to take the lead. To do so, it will first make a visible adjustment. In esotropia, this adjustment is from medial to lateral; in exotropia, it is from lateral to medial.
- ❖ In **bilateral alternating strabismus**, *both eyes will alternately fixate and deviate*.

Diagnosis of strabismus in children with the Teller acuity card.

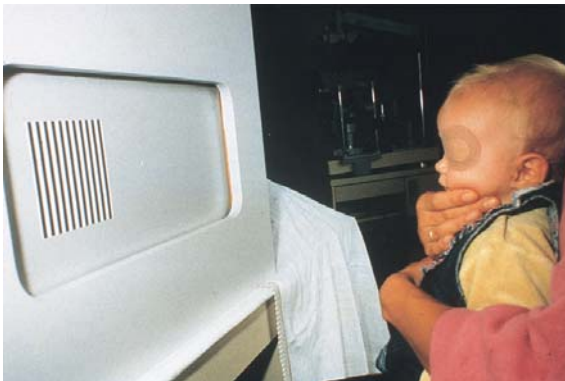

Fig. 17.7 The Teller acuity card is located in a viewing case behind which the examiner sits. This permits the examiner to see upon which half of the card the infant fixates. Infants who prefer the striped side have good fixation.

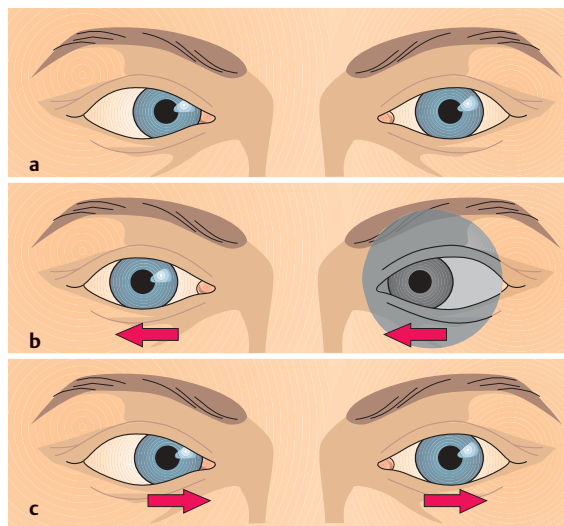
**Response of the deviating eye to a unilateral cover test.**

Fig. 17.8 **a** Unilateral esotropia of the right eye. **b** Unilateral cover test: When the leading left eye is covered, the deviating right eye adjusts with a movement from medial to lateral and then takes the lead. The covered left eye deviates. **c** When the leading left eye is uncovered again, the right eye reverts to its deviation. The leading left eye is realigned with the fixation point.

17.2.2.4 Measuring the Angle of Deviation

Exact measurement of the angle of deviation is crucial to prescribing the proper prism correction to compensate for the angle of deviation and to the corrective surgery that usually follows. A measurement error may lead to undercorrection or overcorrection of the angle of deviation during the operation. *Example:* Esotropia of + 15 degrees is corrected by shifting the medial rectus 4.0 mm posteriorly and shortening the lateral rectus 5.0 mm.

The angle of deviation is measured with a **cover test in combination with the use of prism lens of various refractive powers**. The patient fixates on a certain point with the *leading eye* at a distance of 5 m or 30 cm, depending on which angle of deviation is to be measured. The examiner place prism lenses of different refractive power before the patient's deviant eye until the eye no longer makes any adjustment. This is the case when the angle of deviation corresponds to the strength of the respective prism and is fully compensated for by that prism. The tip of the prism must always point in the direction of deviation during the examination.



Prism bars simplify the examination. These bars contain a series of prisms of progressively increasing strength arranged one above the other.

Maddox's cross (Fig. 17.9) is a device often used to measure the angle of deviation. A light source mounted in the center of the cross serves as a fixation point. The patient fixates the light source with his or her *leading eye*. The *objective angle of deviation is measured* with prisms as described above. In children, often only the objective angle of deviation is measured as this measurement does not require any action on the part of the patient except for fixating a certain point, in this case the light source at center of the cross. In adults, the examiner can ask the patient to describe the *location of the area of double vision* (double vision may be a sequela of paralytic strabismus, which is the most common form encountered in adults). This uses the graduations on the Maddox's cross. The cross has two scales, a large numbered scale for testing at five meters and a fine scale for testing at one meter (see Fig. 17.9). The patient describes the location of the area of double vision according to a certain number on this scale. The examiner selects the appropriate prism correction according to the patient's description to correct the angle of deviation of the paralyzed eye. This superimposes the images seen by the deviating eye and the nondeviating eye to eliminate the double vision.

Maddox's cross.




Fig. 17.9 A Maddox cross is frequently used only as a fixation object when examining children. The patient fixates on the light source in the center. The two scales (a large numbered scale for testing at five meters and a fine scale for testing at one meter) are only relevant for verbal patients asked to describe the location of the area of double vision, for example in paralytic strabismus. (See text for examination procedure.)



- !** The angle of deviation can be measured in prism diopters or degrees. One prism diopter refracts light rays approximately half a degree so that two prism diopters correspond to one degree.

17.2.2.5 Determining the Type of Fixation

This examination is used to ascertain *which part of the retina of the deviating eye* the image of the fixated point falls on. The patient looks through a special ophthalmoscope and fixates on a small star that is imaged on the fundus of the eye. The examiner observes the fundus.

- ❖ In **central fixation**, the image of the star falls on the fovea centralis.
- ❖ In **eccentric fixation**, the image of the star falls on an area of the retina outside the fovea (Fig. 17.10). Usually this point lies between the fovea and the optic disk.

Aside from the type of fixation, one can also estimate potential *visual acuity*. The greater the distance between where the point of fixation lies and the fovea, the lower the resolving power of the retina and the poorer visual acuity will be. Initial treatment consists of occlusion therapy to shift an eccentric point of fixation on to the fovea centralis.

17.2.2.6 Testing Binocular Vision

Bagolini test: This test uses flat lenses with fine parallel striations. The striations spread light from a point source into a strip. The lenses are mounted in the examination eyeglasses in such a manner that the strips of light form a diagonal cross in patients with intact binocular vision. The patient is asked to

Ophthalmoscopic examination of fixation.

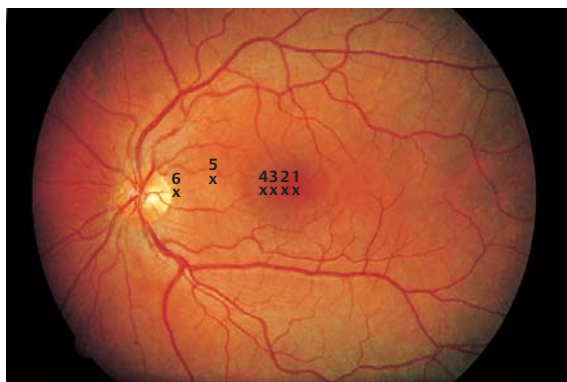

Fig. 17.10

1 = foveal fixation; 2 = parafoveal fixation; 3 = macular fixation; 4 = paramacular fixation; 5 and 6 = eccentric fixation.



describe the pattern of the strips of light while looking at the point source. Patients who describe a cross have normal simultaneous vision. Patient who see only one diagonal strip of light are suppressing the image received by the respective fellow eye.

Lang's test: This test may be used to determine depth perception in infants. A card depicts various objects that the child only sees if it can perceive depth.

17.2.3 Therapy of Concomitant Strabismus

Therapy of concomitant strabismus in children: Treatment is generally long-term. The duration of treatment may extend from the first months of life to about the age of twelve. Specific treatments and therapeutic success are determined not only by the clinical course but also by the child's overall personality and the parents' ability to cooperate. The entire course of treatment may be divided into **three phases with corresponding interim goals**.

1. The ophthalmologist determines whether the cause of the strabismus may be treated with **eyeglasses** (such as hyperopia).
2. If the strabismus cannot be fully corrected with eyeglasses, the next step in treatment (parallel to prescribing eyeglasses) is to minimize the risk of amblyopia by **occlusion therapy**.
3. Once the occlusion therapy has produced sufficient visual acuity in both eyes, the alignment of one or both eyes is corrected by **surgery**. Late strabismus with normal sensory development is an exception to this rule (for further information, see Surgery). The alignment correction is required for normal binocular vision and has the added benefit of cosmetic improvement.

Therapy of concomitant strabismus in adults: The only purpose of surgery is cosmetic improvement. A functional improvement in binocular vision can no longer be achieved.

17.2.3.1 Eyeglass Prescription

Where the strabismus is due to a cause that can be treated with eyeglasses, then eyeglasses can eliminate at least the accommodative component of the disorder. Often residual strabismus requiring further treatment will remain despite eyeglass correction.

17.2.3.2 Treatment and Avoidance of Strabismic Amblyopia

Strict occlusion therapy by eye patching or eyeglass occlusion is the most effective method of avoiding or treating strabismic amblyopia. *Primarily the leading eye is patched.*

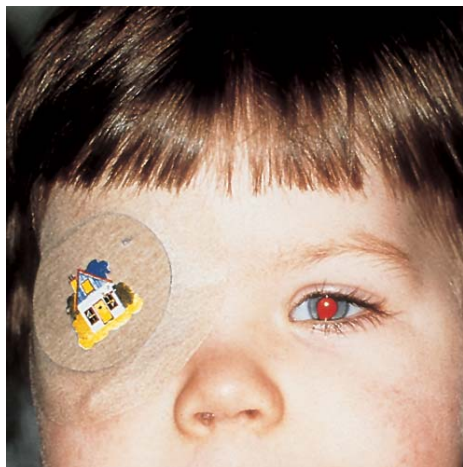
**Occlusion therapy of amblyopia.**

Fig. 17.11 The leading eye is patched for several hours or days at a time to improve visual acuity in the deviating amblyopic eye.

Eye patching: Severe amblyopia with eccentric fixation requires an eye patch (Fig. 17.11). Eyeglass occlusion (see next section) entails the risk that the child might attempt to circumvent the occlusion of the good eye by looking over the rim of the eyeglasses with the leading eye. This would compromise the effectiveness of occlusion therapy, whose purpose is to train the amblyopic eye.

Eyeglass occlusion: Mild cases of amblyopia usually may be treated successfully by covering the eyeglass lens of the leading eye with an opaque material. In such cases, the child usually does not attempt to look over the rim of the eyeglasses because the deviating eye has sufficient visual acuity.

Procedure: The duration of occlusion therapy must be balanced so as to avoid a loss of visual acuity in the leading eye. The leading eye is occluded for several hours at a time in **mild amblyopia**, and for several days at a time in **severe amblyopia** depending to the patient's age. For example, the nondeviating eye in a *four-year-old patient* is patched for *four days* while the deviating eye is left uncovered. Both eyes are then left uncovered for one day. This treatment cycle is repeated beginning on the following day.



Amblyopia must be treated in early childhood. The younger the child is, the more favorable and rapid the response to treatment will be. The upper age limit for occlusion therapy is approximately the age of nine. The earlier therapy is initiated, the sooner amblyopia can be eliminated.



The goal of treatment in infantile strabismus is to achieve *alternating strabismus* with *full visual acuity* and *central fixation* in both eyes. Binocular vision is less important in this setting. It is not normally developed anyway in patients who develop strabismus at an early age and cannot be further improved.

17.2.3.3 Surgery

Surgery in infantile strabismus syndrome: Surgery should be postponed until after amblyopia has been successfully treated (see previous section). It is also advisable to wait until the patient has reached a certain age. Adequate follow-up includes precise measurement of visual acuity at regular intervals in tests that require the patient's cooperation, and such cooperation is difficult to ensure in young patients below the age of four. Surgical correction in a very young patient prior to successful treatment of amblyopia involves a risk that a decrease in visual acuity in one eye may go unnoticed after the strabismus has been corrected. However, the child should undergo surgery prior to entering school so as to avoid the social stigma of strabismus. In such a case, surgery achieves only a *cosmetic correction of strabismus*.

Surgery in late strabismus with normal sensory development: In this case, surgery should be performed as early as possible because the primary goal is to preserve binocular vision, which is necessarily absent in infantile strabismus syndrome.

Procedure: The effect of surgery is less to alter the pull of the extraocular muscles than to alter the position of the eyes at rest. **Esotropia** is corrected by a combined procedure involving a medial rectus recession and a lateral rectus resection. The medial rectus is released because its pull is "too strong" (see Fig. 17.1), whereas the lateral rectus is shorted to increase its pull. The degree of correction depends on the angle of deviation. **Primary oblique muscle dysfunction** is corrected by inferior oblique recession and if necessary by doubling the superior oblique to reinforce it. **Exotropia** is corrected by posteriorly a lateral rectus recession in combination with a medial rectus resection.



17.3 Heterophoria

Definition

Heterophoria refers to a muscular imbalance between the two eyes that leads to misalignment of the visual axes only under certain conditions (see below). This is in contrast to orthophoria, muscular balance with parallel visual axes. Heterophoria is typified by *initially parallel visual axes* and *full binocular vision*. The following forms are distinguished analogously to manifest strabismus:

- ❖ **Esophoria:** latent inward deviation of the visual axis.
- ❖ **Exophoria:** latent outward deviation of the visual axis.
- ❖ **Hyperphoria:** latent upward deviation of one eye.
- ❖ **Hypophoria:** latent downward deviation of one eye.
- ❖ **Cyclophoria:** latent rotation of one eye around its visual axis.

Epidemiology: This disorder occurs in 70–80% of the population. The incidence increases with age.

Etiology and symptoms: Heterophoria does not manifest itself as long as image fusion is unimpaired. Where fusion is impaired as a result of alcohol consumption, stress, fatigue, concussion, or emotional distress, the muscular imbalance can cause intermittent or occasionally permanent strabismus. This is then typically associated with symptoms such as headache, blurred vision, diplopia, and easily fatigued eyes.

Diagnostic considerations: Heterophoria is diagnosed by the **uncover test**. This test simulates the special conditions under which heterophoria becomes manifest (decreased image fusion such as can occur due to extreme fatigue or consumption of alcohol) and eliminates the *impetus to fuse images*. In contrast to the cover test, the uncover test focuses on the *response of the previously covered eye immediately after being uncovered*. Once uncovered, the eye makes a visible adjustment to permit fusion and recover binocular vision.

Treatment: Heterophoria requires treatment only in symptomatic cases. Convergence deficiencies can be improved by **orthoptic exercises**. The patient fixates a small object at eye level, which is slowly moved to a point very close to the eyes. The object may not appear as a double image. **Prism eyeglasses** to compensate for a latent angle of deviation help only temporarily and are controversial because they occasionally result in an increase in heterophoria. **Strabismus surgery** is indicated only when heterophoria deteriorates into clinically manifest strabismus.



Pseudostrabismus.

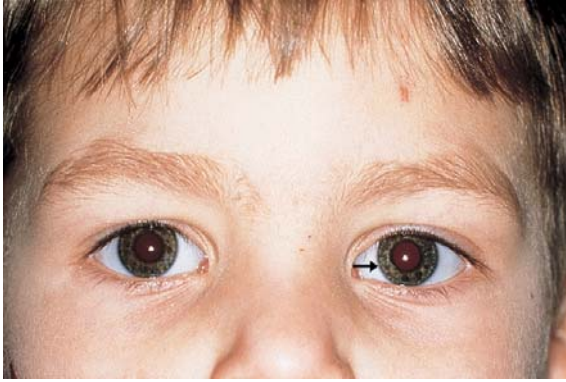

Fig. 17.12
Esotropia of the left eye (arrow) is only simulated by a broad dorsum of the nose. The corneal reflexes demonstrate parallel visual axes.

17.4 Pseudostrabismus

A broad dorsum of the nose with epicanthal folds through which the nasal aspect of the palpebral fissure appears shortened can often simulate strabismus in small children (Fig. 17.12). The child's eyes appear esotropic especially when gazing to the side. Testing with a focused light will reveal that the corneal reflexes are symmetrical, and there will be no eye adjustments in the cover test. Usually the epicanthal folds will spontaneously disappear during the first few years of life as the dorsum of the nose develops.

17.5 Ophthalmoplegia and Paralytic Strabismus

Definitions

Ophthalmoplegia can affect one or more ocular muscles at the same time. The condition may be partial (**paresis**, more common) or complete (**paralysis**, less common). The result is either gaze palsy or strabismus (paralytic strabismus), depending on the cause (see next section) and severity.

- ❖ **Gaze palsy:** Impairment or failure of coordinated eye movements. For example in cyclovertical muscular palsy, the upward and downward gaze movements are impaired or absent.
- ❖ **Paralytic strabismus:** Strabismus due to:
 - *Isolated* limited motility in *one* eye.
 - *Asymmetrical* limited motility in *both* eyes.

The angle of deviation does not remain constant in every direction of gaze (as in concomitant strabismus) but increases in the direction of pull of the paralyzed muscle. This is referred to as an *incomitant* angle of deviation.



Etiology and forms of ocular motility disturbances: Two forms are distinguished.

- ❖ **Congenital ocular motility disturbances** may be due to the following causes:
 - Prenatal encephalitis.
 - Aplasia of the ocular muscles.
 - Birth trauma.
- ❖ **Acquired ocular motility disturbances** may be due to the following causes:
 - Diabetes mellitus.
 - Multiple sclerosis.
 - Intracranial tumors.
 - Arteriosclerosis.
 - Central ischemia (apoplexy).
 - AIDS.
 - Trauma and other causes.

Ocular motility disturbances are either neurogenic, myogenic, or due to mechanical causes.

Neurogenic ocular motility disturbances (see also ophthalmoplegia secondary to cranial nerve lesions) are distinguished according to the location of the lesion (Table 17.3):

- ❖ *Lesions of the nerves supplying the ocular muscles.* This condition is referred to as an *infranuclear* ocular motility disturbance and is the most common cause of paralytic strabismus. The following nerves may be affected:
 - Oculomotor nerve lesions are rare and cause paralysis of several muscles.
 - Trochlear nerve lesions are common and cause paralysis of the superior oblique.
 - Abducent nerve lesions are common and cause paralysis of the lateral rectus.
- ❖ *Lesions of the ocular muscle nuclei.* This condition is referred to as a *nuclear* ocular motility disturbance (see Fig. 17.2).



The oculomotor nuclei supply both sides but the nerves are not close together. Therefore, bilateral palsy suggests a nuclear lesion, whereas unilateral palsy suggests a lesion of one nerve.

- ❖ *Lesions of the gaze centers.* This condition is referred to as a *supranuclear* ocular motility disturbance (see gaze centers, Fig. 17.2). It very often causes gaze palsy.
- ❖ Another possible but rare condition is a *lesion of the fibers connecting two nuclei*. This condition is referred to as an *internuclear* ocular motility disturbance and may occur as a result of a lesion of the medial longitudinal fasciculus (see Figs. 17.2 and 17.13, Internuclear ophthalmoplegia).



Table 17.3 Classification of neurogenic ophthalmoplegia according to the location of the lesion (see Fig. 17.2)

Ocular motility disturbance	Causes	Location of lesion	Effects	
Infranuclear ocular motility disturbance	<ul style="list-style-type: none"> ❖ In younger patients: <ul style="list-style-type: none"> – Trauma – Multiple sclerosis – Infectious disease – Brain tumors ❖ In older patients: <ul style="list-style-type: none"> – Vascular disease – Diabetes – Hypertension – Arteriosclerosis 	<ul style="list-style-type: none"> ❖ Lesion in one of the nerves supplying the ocular muscles: <ul style="list-style-type: none"> – Oculomotor nerve – Trochlear nerve – Abducent nerve 	<ul style="list-style-type: none"> ❖ Palsy of one or several extraocular muscles of one or both eyes resulting in strabismus or complete gaze palsy. 	
Nuclear ocular motility disturbance	<ul style="list-style-type: none"> ❖ Multiple sclerosis ❖ Myasthenia gravis ❖ Meningoencephalitis ❖ Syphilis ❖ AIDS 	<ul style="list-style-type: none"> ❖ Lesion of the ocular muscle nucleus 	<ul style="list-style-type: none"> ❖ Palsy of the extraocular muscles of both eyes in varying degrees of severity. 	
Supranuclear ocular motility disturbance	<ul style="list-style-type: none"> ❖ Horizontal gaze palsy 	<ul style="list-style-type: none"> ❖ Diabetes ❖ Apoplexy ❖ Tumor ❖ Encephalitis ❖ Vascular insult ❖ Multiple sclerosis 	<ul style="list-style-type: none"> ❖ Lesion in the paramedian pontine reticular formation (PPRF; see Fig. 17.2) 	<ul style="list-style-type: none"> ❖ All conjugate eye movements on the side of the lesion are impaired. ❖ Peripheral facial paresis is often also present. ❖ Both eyes are affected.

Continued →



Table 17.3 (Continued)

Ocular motility disturbance	Causes	Location of lesion	Effects
❖ Vertical gaze palsy (Parinaud's syndrome)	❖ Midbrain infarctions ❖ Tumors of the quadrigeminal region such as pineal gland tumors and germinomas.	Lesion in the medial longitudinal fasciculus (MLF; see Fig. 17.2)	❖ Isolated upward or downward gaze palsy (common). ❖ Combined upward and downward gaze palsy (rare). ❖ Moderately wide pupils. ❖ Impaired accommodation. ❖ Convergence nystagmus. ❖ Jerky upper eyelid retraction.
Internuclear ocular motility disturbance (INO)	❖ Younger patients with bilateral INO: multiple sclerosis ❖ Older patients with unilateral INO: brain stem infarction	Lesion in the medial longitudinal fasciculus (see Fig. 17.2)	❖ Medial nerve palsy or impaired adduction in one eye in side gaze with intact near reflex convergence (see Fig. 17.13). ❖ Jerk nystagmus in the abducted eye as long as the palsy persists. ❖ In <i>bilateral INO</i> , fine vertical nystagmus in the direction of gaze.

Myogenic ocular motility disturbances are rare. These include palsies due to the following causes:

- ❖ *Graves' disease* is the most common cause of myogenic ocular motility disturbances. Because it alters the contractility and ductility of the ocular muscles, it can result in significant motility disturbances (see Chapter 15).
- ❖ *Ocular myasthenia gravis* is a disorder of neuromuscular transmission characterized by the presence of acetylcholine receptor antibodies. Typical symptoms of ocular myasthenia gravis include fluctuating weakness



Right internuclear ophthalmoplegia.

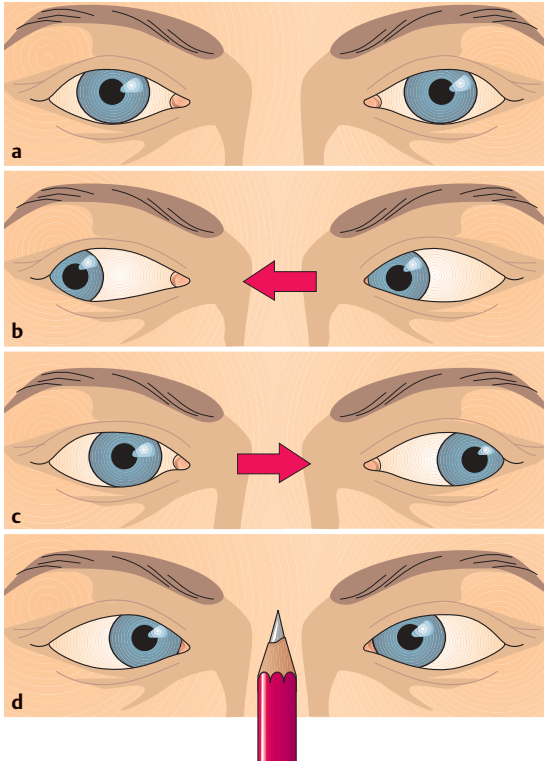


Fig. 17.13 **a** Parallel visual axes. **b** Normal right gaze. **c** In left gaze, the right eye cannot be adducted because the medial longitudinal fasciculus is interrupted. **d** Convergence is preserved in both eyes.

that is clearly attributable to any one cranial nerve. The weakness typically increases in severity during the course of the day with fatigue.

Important diagnostic aids include the following tests.

- Simpson test: The patient is asked to gaze upward for one minute. Gradual drooping of one of the patient's eyelids during the test due to fatigue of the levator palpebrae strongly suggests myasthenia gravis.
- Tensilon (edrophonium chloride) test: This test is used to confirm the diagnosis. The patient is given 1–5 mg of intravenous Tensilon (edrophonium chloride). Where myasthenia gravis is present, the paresis will disappear within a few seconds. (Refer to a textbook of neurology for a detailed description of this test.)



- ❖ *Chronic progressive external ophthalmoplegia (CPEO)* is a usually bilateral, gradually progressive paralysis of one or more extraocular muscles. In the final stages it results in complete paralysis of both eyes. Because the paralysis is symmetric the patient does not experience strabismus or double vision.
- ❖ *Ocular myositis* is inflammation of one or more extraocular muscles. The pathogenesis is uncertain. Ocular motility is often limited not so much in the direction of pull of the inflamed muscle as in the opposite direction. While there is paresis of the muscle, it is characterized primarily by insufficient ductility. Often additional symptoms are present, such as pain during eye movement.

Mechanical ocular motility disturbances include palsies due to the following causes:

- ❖ *Fractures*. In a blowout fracture for example, the fractured floor of the orbit can impinge the inferior rectus and occasionally the inferior oblique. This can interfere with upward gaze and occasionally produce strabismus.
- ❖ *Hematomas*.
- ❖ *Swelling* in the orbit or facial bones, such as can occur in an orbital abscess or tumor.

Symptoms: Strabismus: Paralysis of one or more ocular muscles can cause its respective antagonist to dominate. This results in a typical strabismus that allows which muscle is paralyzed to be determined (see Diagnostic considerations). This is readily done especially in abducent or trochlear nerve palsy as the abducent nerve and the trochlear nerve each supply only one extraocular muscle (see Fig. 17.1).

Example: abducent nerve palsy (Fig. 17.14). A lesion of the abducent nerve paralyzes the lateral rectus so that the eye can no longer be *abducted*. This paralysis also causes the muscle's antagonist, the medial rectus, to dominate. Because this muscle is responsible for *adduction*, the affected eye remains *medially rotated*.

Gaze palsy. Symmetrical paralysis of one or more muscles of both eyes limits ocular motility in a certain direction. For example, *vertical gaze palsy* or *Pari-naud's syndrome*, which primarily occurs in the presence of a pineal gland tumor, involves a lesion of the rostral interstitial nucleus of the medial longitudinal fasciculus (see Fig. 17.12). Paralysis of *all extraocular muscles* leads to complete gaze palsy. Gaze palsy suggests a supranuclear lesion, i.e., a lesion in the gaze centers. Examination by a neurologist is indicated in these cases.

Double vision. Loss of binocular coordination between the two eyes due to ophthalmoplegia leads to double vision. Normal vision may be expected in patients with only moderate paresis. As the onset of paresis is usually sudden, double vision is the typical symptom that induces patients to consult a phys-



Left abducent nerve palsy.

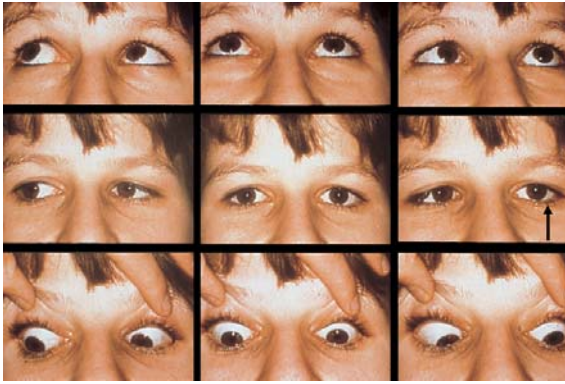

Fig. 17.14 The left eye remains immobile in left gaze (arrow).

ician. Some patients learn to suppress one of the two images within a few hours, days, or weeks. Other patients suffer from persistent double vision. Children usually learn to suppress the image quicker than adults.

Causes. Double vision occurs when the image of the fixated object only falls on the fovea in one eye while falling on a point on the peripheral retina in the fellow eye. As a result, the object is perceived in two different directions and therefore seen double (Fig. 17.15 **a** and **b**). The double image of the deviating eye is usually somewhat out of focus as the resolving power of the peripheral retina is limited. Despite this, the patient cannot tell which is real and which is a virtual image and has difficulty in reaching to grasp an object.

The *distance between the double images* is greatest in ophthalmoplegia in the original direction of pull of the affected muscle.

Example: trochlear nerve palsy (Fig. 17.16). The superior oblique supplied by the trochlear nerve is primarily an intorter and depressor in adduction (see Table 17.1); it is also an abductor when the gaze is directed straight ahead. Therefore, the limited motility and upward deviation of the affected eye is most apparent in depression and intorsion as when reading. The distance between the double images is greatest and the diplopia most irritating in this direction of gaze, which is the main direction of pull of the paralyzed superior oblique.

Compensatory head posture. The patient can avoid diplopia only by attempting to avoid using the paralyzed muscle. This is done by assuming a typical compensatory head posture in which the gaze lies within the binocular visual field; the patient tilts his or her head and turns it toward the shoulder opposite the paralyzed eye.

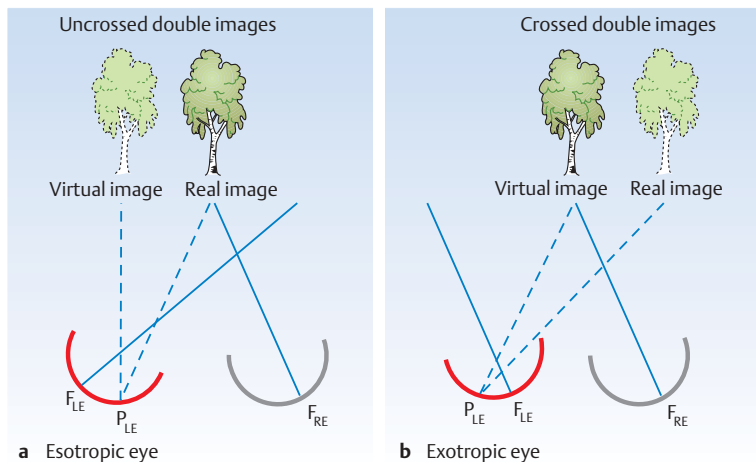
**Crossed and uncrossed diplopia.**

Fig. 17.15 **a** Esotropia in the left eye (LE) with uncrossed images. The right eye (RE) is the leading eye, and the left eye is esotropic. The visual image falling on the fovea in the leading eye falls on the nasal retina next to the fovea (P_{LE}) in the esotropic eye and is perceived in space in a temporal location. The object is seen as two uncrossed or homonymous images.

b Exotropia in the left eye (LE) with crossed images. The right eye (RE) is the leading eye, and the left eye is exotropic. The visual image falling on the fovea in the leading eye falls on the temporal retina next to the fovea (P_{LE}) in the exotropic eye and is perceived in space in a nasal location. The object is seen as two crossed or heteronymous images.

The *Bielschowsky head tilt test* uses this posture to confirm the diagnosis of trochlear or fourth cranial nerve palsy (Fig. 17.17). In this test, the examiner tilts the patient's head toward the side of the paralyzed eye. If the patient then fixates with the normal eye, the paralyzed eye will deviate. When the patient's head is tilted toward the normal side, there will be no vertical deviation (see Diagnostic considerations for further diagnostic procedures).

Ocular torticollis. The compensatory head posture in trochlear nerve palsy is the most pronounced and typical of all cranial nerve palsies. *Congenital* trochlear nerve palsy can lead to what is known as ocular torticollis.

Incomitant angle of deviation. The angle of deviation in paralytic strabismus also varies with the direction of gaze and is not constant as in concomitant strabismus. Like the distance between the double images, the angle of deviation is greatest when the gaze is directed in the direction of pull of the para-



Right trochlear nerve palsy.

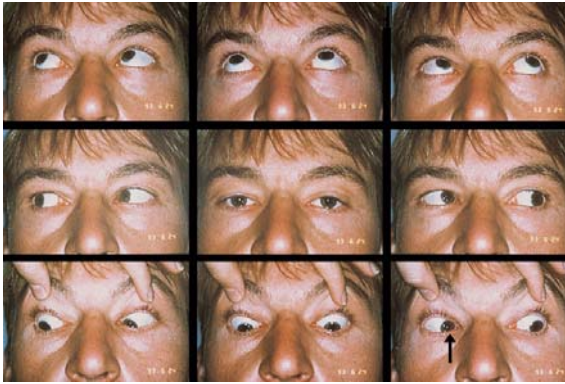


Fig. 17.16 Vertical deviation of the right eye in left downward gaze (arrow).

Bielschowsky head tilt test.



Fig. 17.17 **a** When the patient tilts her head to the left (toward the normal side), the right eye does not deviate upward when the normal left eye fixates.

b When the patient tilts her head to the right (toward the side of the paralyzed muscle), the right eye deviates upward when the normal left eye fixates.



lyzed muscle. The angle of deviation may be classified according to the which eye fixates.

- A *primary angle of deviation* is the angle of deviation when fixating with the normal eye. This angle is small.
- A *secondary angle of deviation* is the angle of deviation when fixating with the paralyzed eye. This angle is large.



The secondary angle of deviation is always larger than the primary angle. This is because both the paralyzed muscle and its synergist in the fellow eye receive increased impulses when the paralyzed eye fixates. For example when the right eye fixates in right abducent nerve palsy, the left medial rectus will receive increased impulses. This increases the angle of deviation.

Cranial nerve palsies: The commonest palsies are those resulting from cranial nerve lesions. Therefore, this section will be devoted to examining these palsies in greater detail than the other motility disturbances listed under Etiology. It becomes evident from the examples of causes listed here that a diagnosis of ophthalmoplegia will always require further diagnostic procedures (often by a neurologist) to confirm or exclude the presence of a tumor or a certain underlying disorder such as diabetes mellitus.

Abducent nerve palsy:

Causes: The main causes of this relatively common palsy include vascular disease (diabetes mellitus, hypertension, or arteriosclerosis) and intracerebral tumors. Often a tumor will cause increased cerebrospinal fluid pressure, which particularly affects the abducent nerve because of its long course along the base of the skull. In *children*, these transient isolated abducent nerve palsies can occur in infectious diseases, febrile disorders, or secondary to inoculations.

Effects: The lateral rectus is paralyzed, causing its antagonist, the medial rectus, to dominate. Abduction is impaired or absent altogether, and the affected eye remains medially rotated (see Fig. 17.14). Horizontal homonymous (uncrossed) diplopia is present (see Fig. 17.15). The images are farthest apart in abduction.

Example: right abducent nerve palsy.

- ❖ Compensatory head posture with right tilt.
- ❖ Esotropia when the gaze is directed straight ahead.
- ❖ Largest angle of deviation and distance between images in right gaze.
- ❖ No angle of deviation or diplopia in left gaze.

Retraction syndrome (special form of abducent nerve palsy):

Causes: Retraction syndrome is a congenital unilateral motility disturbance resulting from a lesion to the abducent nerve acquired during pregnancy.



Effects: The lateral rectus is no longer supplied by the abducent nerve but by fibers from the oculomotor nerve that belong to the medial rectus. This has several consequences. *As in* abducent nerve palsy, *abduction is limited* and slight esotropia is usually present. *In contrast to* abducent nerve palsy, the globe recedes into the orbital cavity when *adduction is attempted*. This narrows the palpebral fissure. This *retraction of the globe* in attempted adduction results from the simultaneous outward and inward pull of two antagonists on the globe because they are supplied by the same nerve (oculomotor nerve).

Trochlear nerve palsy:

Causes: The commonest cause is trauma; less common causes include vascular disease (diabetes mellitus, hypertension, and arteriosclerosis). Trochlear nerve palsy is a relatively common phenomenon.

Effects: The superior oblique is primarily an intorter and a depressor in adduction. This results in upward vertical deviation of the paralyzed eye in adduction and vertical strabismus (see Fig. 17.16). Patients experience vertical diplopia; the images are farthest apart in depression and intorsion. Compensatory head posture is discussed in the section on symptoms. Diplopia is absent in elevation.

Oculomotor nerve palsy:

Causes:

- ❖ Complete oculomotor nerve palsy: *Every intraocular and almost every extraocular muscle* is affected, with loss of both accommodation and pupillary light reaction. The failure of the parasympathetic fibers in the oculomotor nerve produces mydriasis. Ptosis is present because the levator palpebrae is also paralyzed. The paralyzed eye deviates in extorsion and depression as the function of the lateral rectus and superior oblique is preserved. Patients do not experience diplopia because the ptotic eyelid covers the pupil.
- ❖ Partial oculomotor nerve palsy:
 - External oculomotor nerve palsy (isolated paralysis of the *extraocular* muscles supplied by the oculomotor nerve; see Fig. 17.1) is characterized by deviation in extorsion and depression. If the ptotic eyelid does not cover the pupil, the patient will experience diplopia.
 - Internal oculomotor nerve palsy is isolated paralysis of the *intraocular* muscles supplied by the oculomotor nerve. This is characterized by loss of accommodation (due to paralysis of the ciliary muscle) and mydriasis (due to paralysis of the sphincter pupillae). Patients do not experience diplopia as there is no strabismic deviation (see also tonic pupil and Adie syndrome).

Combined cranial nerve palsies. The third, fourth, and sixth cranial nerves can be simultaneously affected, for example in a lesion at the apex of the orbi-



tal cavity or in the cavernous sinus. Clinical suspicion of combined lesion may be supported by a corneal sensitivity test as the ophthalmic division of the trigeminal nerve, which provides sensory supply to the cornea, courses through the cavernous sinus. Where there is loss of corneal sensitivity, whether the lesion is located in the cavernous sinus must be determined.

Diagnosis of ophthalmoplegia: Examination of the nine diagnostic positions of gaze (see Chapter 1). The patient is asked to follow the movements of the examiner's finger or a pencil with his or her eyes only. The six cardinal directions of gaze (right, upper right, lower right, left, upper left, lower left) provide the most information; upward and downward movements are performed with several muscles and therefore do not allow precise identification of the action of a specific muscle. Immobility of one eye when the patient attempts a certain movement suggests involvement of the muscle responsible for that movement.

The **Bielschowsky head tilt test** is performed only where trochlear nerve palsy is suspected (see symptoms).

Measuring the angle of deviation. Measuring this angle in the nine diagnostic directions of gaze provides information about the severity of the palsy, which is important for surgical correction. This is done using a Harms tangent

Measuring the angle of deviation with the Harms tangent table.



Fig. 17.18 The patient sits at a distance of 2.5 meters from the table and fixates on the light in the center. The examiner evaluates the nine diagnostic positions of gaze. The grid provides the coordinates for measuring the horizontal and vertical deviations, and the diagonals are used to measure the angle of deviation at a head tilt of 45 degrees (Bielschowsky head tilt test in trochlear nerve palsy). A small projector with positioning cross hairs mounted on the patient's forehead permits the examiner to determine the patient's head tilt with a relatively high degree of precision. The tilt of the image (paralytic strabismus often leads to image tilting) can also be measured with the Harms tangent table. To do so, the fixation light in the center of the table is spread into a band of light.



table (Fig. 17.18). In addition to the vertical and horizontal graduations of the Maddox's cross, the Harms table also has diagonals. These diagonals permit the examiner to measure the angle of deviation even in patients with a compensatory head tilt, such as can occur in trochlear nerve palsy.

Differential diagnosis: Table 17.4 shows the most important differences between paralytic strabismus and concomitant strabismus.

Treatment of ophthalmoplegia: Surgery for paralytic strabismus should be postponed for at least one year to allow for possible spontaneous remission. Preoperative diagnostic studies to determine the exact cause are indicated to permit treatment of a possible underlying disorder, such as diabetes mellitus. Severe diplopia may be temporarily managed by alternately patching the eyes until surgery. Alternatively, an eyeglass lens with a prism correction for the paralyzed eye may be used to compensate for the angle of deviation and eliminate diplopia. Eyeglasses with nonrefracting lenses may be used for patients who do not normally wear corrective lenses. Prism lenses may not always be able to correct extreme strabismus. If surgery is indicated, care

Table 17.4 Differential diagnosis between concomitant strabismus and paralytic strabismus

Differential criterion	Concomitant strabismus	Paralytic strabismus
Onset	At an early age, initially only periodically.	At any age, sudden onset.
Cause	Hereditary, uncorrected refractive error, perinatal injury.	Disease of or injury to ocular muscles, supplying nerves, or nuclei.
Diplopia	None; image suppressed (except in late strabismus with normal sensory development).	Diplopia is present.
Compensatory head posture	None.	Constant.
Depth perception	Not present.	Only present when patient assumes compensatory head posture (see symptoms).
Visual acuity	Usually unilaterally reduced visual acuity.	No change in visual acuity.
Angle of deviation	Constant in every direction of gaze.	Variable, increasing in the direction of pull of the paralyzed muscle.



must be taken to correctly *gauge the angle of deviation*. The goal of surgery is to eliminate diplopia in the normal visual field, i.e., with head erect, in both near and distance vision. It will not be possible to surgically eliminate diplopia in *every visual field*.

Procedure: The *antagonist of the respective paralyzed muscle* can be *weakened* by recession. Resecting or doubling the paralyzed muscle can additionally reduce the angle of deviation.

! Strabismus surgery for ophthalmoplegia is possible only after a one-year regeneration period.

17.6 Nystagmus

Definition

Nystagmus refers to bilateral involuntary rhythmic oscillation of the eyes, which can be jerky or pendular (jerk nystagmus and pendular nystagmus).

The various forms of nystagmus are listed in Table 17.5.

Etiology: The etiology and pathogenesis of nystagmus remain unclear. Nystagmus is also a *physiologic phenomenon* that may be elicited by gazing at rapidly moving objects. An example of this is optokinetic nystagmus, a jerk nystagmus that occurs in situations such as gazing out of a moving train.

Treatment: Where nystagmus can be reduced by convergence, prisms with an outward facing base may be prescribed. In special cases, such as when the patient assumes a compensatory head posture to control the nystagmus, Kestenbaum's operation may be indicated. This procedure involves parallel shifts in the horizontal extraocular muscles so as to weaken the muscles that are contracted in the compensatory posture and strengthen those that are relaxed in this posture.

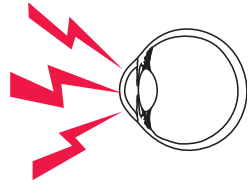


Table 17.5 Forms of nystagmus

Forms	Onset	Characteristics	Type of nystagmus
Ocular nystagmus	Congenital or acquired in early childhood	<ul style="list-style-type: none"> ❖ Occurs in organic disorders of both eyes, such as albinism, cataract, color blindness, vitreous opacification, or macular scarring. ❖ Significant visual impairment. ❖ Secondary strabismus may also be present. 	<ul style="list-style-type: none"> ❖ Pendular nystagmus.
Congenital nystagmus	Congenital or acquired in early childhood (at the age of three months)	<ul style="list-style-type: none"> ❖ Nystagmus is not curbed by fixation but exacerbated. ❖ Oscillation is usually horizontal. ❖ Intensity varies with the direction of gaze (usually less in near fixation than in distance fixation). 	<ul style="list-style-type: none"> ❖ Constant alternation between pendular and jerk nystagmus.
Latent nystagmus	Congenital or acquired in early childhood	<ul style="list-style-type: none"> ❖ Always associated with congenital strabismus. ❖ Manifested only by spontaneously uncovering one eye when fixation changes. ❖ Direction of oscillation changes when fixation changes (see right column). 	<ul style="list-style-type: none"> ❖ Right oscillating nystagmus in right fixation. ❖ Left oscillating nystagmus in left fixation. ❖ Nystagmus occurs as jerk nystagmus.
Fixation nystagmus	Acquired	<ul style="list-style-type: none"> ❖ Occurs in disorders of the brain stem or cerebellum due to vascular insults, multiple sclerosis, trauma, or tumors. 	<ul style="list-style-type: none"> ❖ Pendular or other abnormal form of oscillation.
Gaze palsy nystagmus	Acquired	See fixation nystagmus.	<ul style="list-style-type: none"> ❖ Jerky oscillation. This nystagmus is especially apparent at the onset of muscular paralysis when the patient attempts to use the muscle that is becoming paralyzed.

18 Ocular Trauma

Gerhard K. Lang



18.1 Examination Methods

The incidence of ocular injuries remains high despite the increase in safety regulations in recent years, such as mandatory seat belts and protective eye-wear for persons operating high-speed rotary machinery. Therefore it is important that every general practitioner and health care staff member is able to recognize an ocular injury and provide initial treatment. The patient should then be referred to an ophthalmologist, who should be solely responsible for evaluation of the injury and definitive treatment. The following diagnostic options are available to determine the nature of the injury more precisely.

Patient history: Obtaining a thorough history will provide important information about the cause of the injury.

- ❖ Work with a hammer and chisel nearly always suggests an intraocular foreign body.
- ❖ Cutting and grinding work suggests corneal foreign bodies.
- ❖ Welding and flame cutting work suggests ultraviolet keratoconjunctivitis.



The examiner should always ascertain whether the patient has adequate tetanus immunization.

Inspection (gross morphologic examination): Ocular injuries frequently cause pain, photophobia, and blepharospasm. A few drops of topical anesthetic are recommended to allow the injured eye to be examined at rest with minimal pain to the patient. The cornea and conjunctiva are then examined for signs of trauma using a focused light, preferably one combined with a magnifying loupe (see Fig. 1.11 for examination technique). The eyelids may be everted to inspect the tarsal surface and conjunctival fornix. A foreign body can then be removed immediately.

Ophthalmoscopy: Examination with a focused light or ophthalmoscope will permit gross evaluation of deeper intraocular structures, such as whether a vitreous or retinal hemorrhage is present. A vitreous hemorrhage may be identified by the lack of red reflex on retroillumination. Care should be taken to avoid unnecessary manipulation of the eye in an obviously severe open-



globe injury (characterized by a soft globe, pupil displaced toward the penetration site, prolapsed iris, and intraocular bleeding in the anterior chamber and vitreous body). Such manipulation might otherwise cause further damage, such as extrusion of intraocular contents.

! To properly estimate the urgency of treating palpebral and ocular trauma, it is particularly important to differentiate between open-globe injuries and closed-globe injuries. Open-globe injuries have highest priority due to the risk of losing the eye.

18.2 Classification of Ocular Injuries by Mechanism of Injury

❖ **Mechanical injuries:**

- Eyelid injuries.
- Injuries to the lacrimal system.
- Conjunctival laceration.
- Foreign body in the cornea and conjunctiva.
- Corneal erosion.
- Nonpenetrating injury (blunt trauma to the globe).
- Injury to the floor of the orbit (blowout fracture).
- Penetrating injury (open-globe injury).
- Impalement injury to the orbit.

❖ **Chemical injuries.**

❖ **Injuries due to physical agents:**

- Burns.
- Radiation injuries (ionizing radiation).
- Ultraviolet keratoconjunctivitis.

❖ **Indirect ocular trauma:** transient traumatic retinal angiopathy (Purtscher's retinopathy).

18.3 Mechanical Injuries

18.3.1 Eyelid Injury

Etiology: Eyelid injuries can occur in practically every facial injury. The following types warrant special mention:

- ❖ Eyelid lacerations with involvement of the eyelid margin.
- ❖ Avulsions of the eyelid in the medial canthus with avulsion of the lacrimal canaliculus.

Clinical picture: The highly vascularized and loosely textured tissue of the eyelids causes them to bleed profusely when injured. Hematoma and swelling will be severe (Fig. 18.1). *Abrasions* usually involve only the superficial layers of the skin, whereas *punctures, cuts*, and all *eyelid avulsions due to blunt*



trauma (such as a fist) frequently involve all layers. Bite wounds (such as dog bites) are often accompanied by injuries to the lacrimal system.

Treatment: Surgical repair of eyelid injuries, especially lacerations with involvement of the eyelid margin, should be performed with care. The wound should be closed in layers and the edges properly approximated to ensure a smooth margin without tension to avoid later complications, such as cicatricial ectropion (Fig. 18.2).

18.3.2 Injuries to the Lacrimal System

Etiology: Lacerations and tears in the medial canthus (such as dog bites or glass splinters) can divide the **lacrimal duct**. Obliteration of the **punctum** and **lacrimal canaliculus** is usually the result of a burn or chemical injury. Injury to the **lacrimal sac** or **lacrimal gland** usually occurs in conjunction with severe craniofacial trauma (such as a kick from a horse or a traffic accident). Dacryocystitis is a common sequela, which often can only be treated by surgery (dacryocystorhinostomy).

Clinical picture: See Chapter 3 for dacryocystitis. See Fig. 18.3 for avulsion of the lower lacrimal system (avulsions in the medial canthus).

Treatment: Lacrimal system injuries are repaired under an operating microscope. A ring-shaped silicone stent is advanced into the canaliculus using a special sound (Figs. 18.3b – f). The silicone stent remains *in situ* for three to four months and is then removed.



Surgical repair of eyelid and lacrimal system injuries must be performed by an ophthalmologist.

18.3.3 Conjunctival Laceration

Epidemiology: Due to its exposed position, thinness, and mobility, the conjunctiva is susceptible to lacerations, which are usually associated with subconjunctival hemorrhage.

Etiology: Conjunctival lacerations most commonly occur as a result of penetrating wounds (such as from bending over a spiked-leaf palm tree or from a branch that snaps back on to the eye).

Symptoms and diagnostic considerations: The patient experiences a foreign body sensation. Usually this will be rather mild. Examination will reveal circumscribed conjunctival reddening or subconjunctival hemorrhage in the injured area. Occasionally only application of fluorescein dye to the injury will reveal the size of the conjunctival gap.



Laceration of the upper and lower eyelids with avulsion of the lacrimal system.

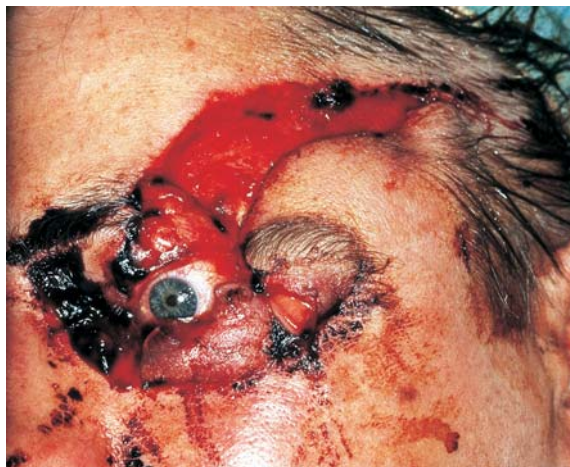
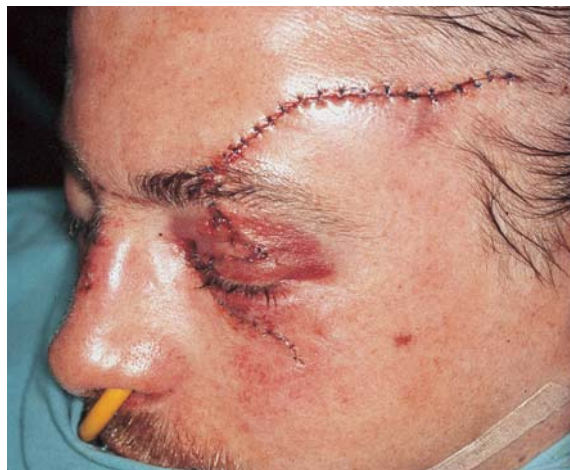
Fig. 18.1 a The injury has exposed the cornea. The patient is unable to close the eye, and the cornea and conjunctiva can no longer be moistened.



b Postoperative findings.

Continued →



Laceration of the upper and lower eyelids with avulsion of the lacrimal system (continued).

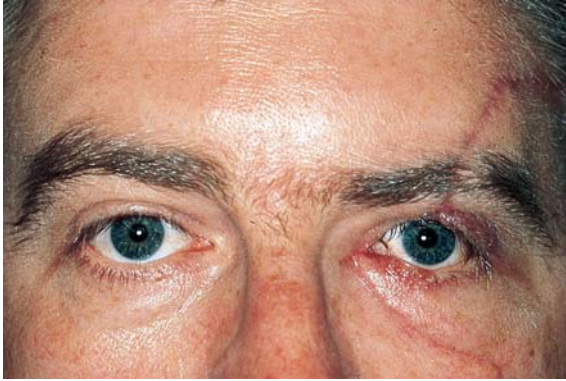

Fig. 18.1 c Findings two months postoperatively after treating the wound with placement of a plastic stent *in situ* (see also Fig. 18.3 for surgical technique).

Cicatricial ectropion in the left lower eyelid after improper repair.

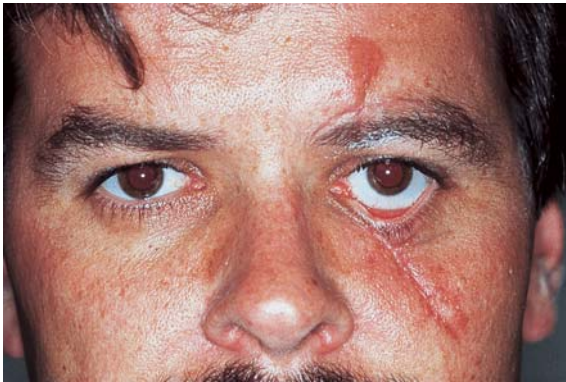

Fig. 18.2 Failure to close the wound in layers without creating tension in the wound results in a scar that “pulls” the lower eyelid downward.



Surgical treatment of avulsion of the eyelid with avulsion of the lacrimal system (bicanicular ring intubation).

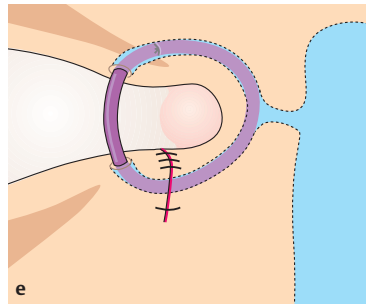
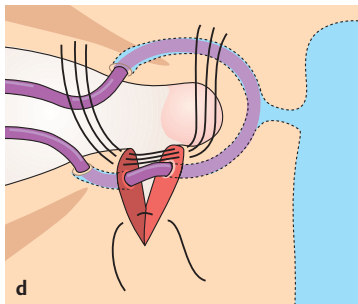
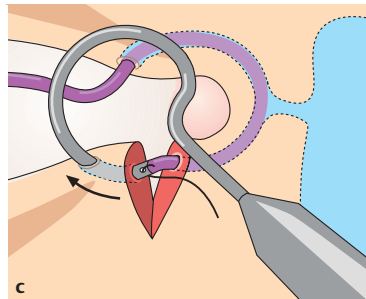
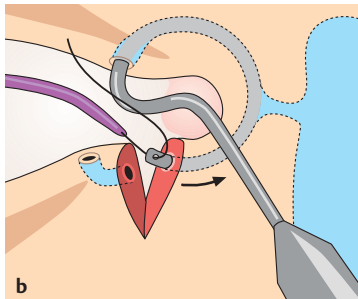
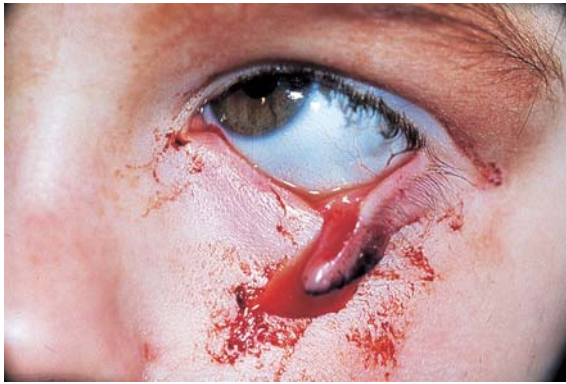

Fig. 18.3 a-e

Continued →



Surgical treatment of avulsion of the eyelid with avulsion of the lacrimal system (bicanicular ring intubation) (continued).

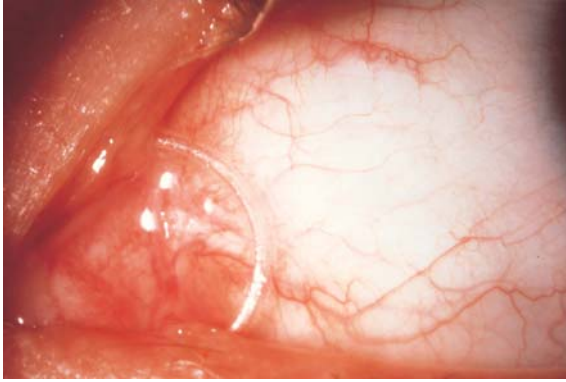

Fig. 18.3f

a Findings prior to treatment of the wound. **b** The pigtail sound is introduced through the uninjured superior lacrimal canaliculus. Now the silicone tube can be introduced at the medial margin of the wound and pulled through. **c** Next the sound is advanced into the punctum of the injured canaliculus to grasp the other end of the silicone tube. **d** Finally, the ends of the tube are joined to form a ring. **e** and **f** Surgical site after the repair.

Treatment: Minor conjunctival injuries do not require treatment as the conjunctiva heals quickly. Larger lacerations with mobile edges are approximated with absorbable sutures.



The possibility of a perforating injury should always be considered in conjunctival injuries. When the wound is treated, the physician should inspect the underlying sclera after application of topical anesthetic.

18.3.4 Corneal and Conjunctival Foreign Bodies

Epidemiology: Foreign bodies on the cornea and conjunctiva are the commonest ocular emergency encountered by general practitioners and ophthalmologists.

Etiology: Airborne foreign bodies and metal splinters from grinding or cutting disks in particular often become lodged in the conjunctiva or cornea or burn their way into the tissue.

Symptoms and diagnostic considerations: The patient experiences a foreign-body sensation with every blink of the eye. This is accompanied by epiphora (tearing) and blepharospasm. Depending on the time elapsed since the



injury, i.e., after a few hours or several days, conjunctival or ciliary injection will be present (Figs. 18.4a and b). The foreign bodies on the conjunctiva or cornea are themselves often so small that they are visible only under loupe magnification. There may be visible infiltration or a ring of rust. Where there is *no* visible foreign body but fluorescein dye reveals vertical corneal striations, the foreign body will be beneath the tarsus (see Fig. 5.11).

Corneal and conjunctival foreign bodies and the reamer used to remove them.

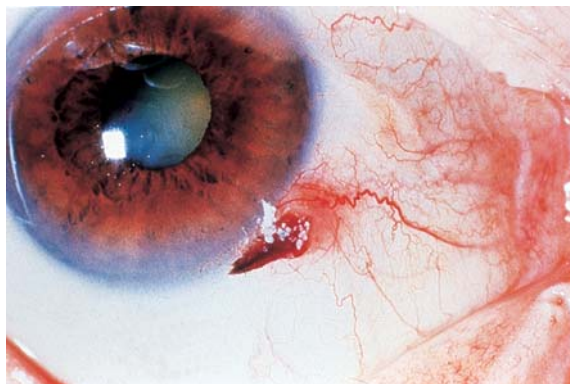
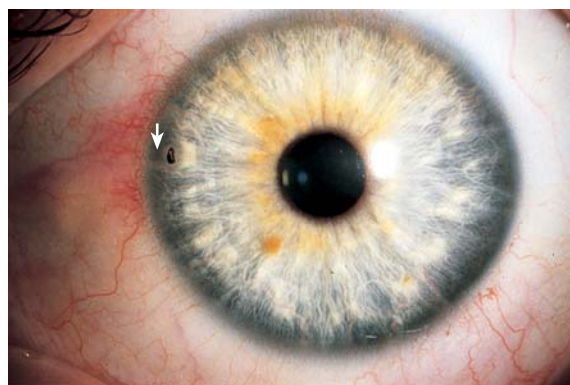
Fig. 18.4a Conjunctival foreign body (lodged grain kernel) on the limbus of the cornea with conjunctival injection.



b Foreign body that has burned its way into the cornea. While the patient was using a grinder without protective eye-wear the previous day, a splinter flew in the eye (arrow) that now exhibits a slight halo of visible infiltration. Note the conjunctival and ciliary injection at the site of the foreign body (see also Fig. 4.6).

Continued →



Corneal and conjunctival foreign bodies and the reamer used to remove them (continued).

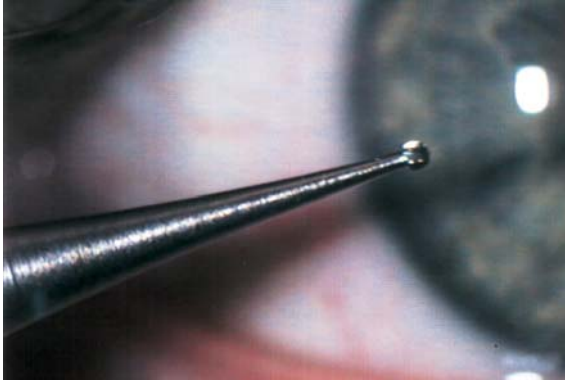


Fig. 18.4c
Reamer used to ream out the defect created by the foreign body.



A foreign-body sensation with every blink of the eye accompanied by epiphora, blepharospasm, and vertical striations on the surface of the cornea are typical signs of a subtarsal foreign body.

Treatment: Corneal and conjunctival foreign bodies. The foreign body is pried out of its bed with a fine needle or cannula. The defect created by the foreign body will often be contaminated with rust or infiltrated with leukocytes. This defect is carefully reamed out with a drill (Fig. 18.4c) and treated with an antibiotic eye ointment and bandaged if necessary.

Subtarsal foreign bodies. Everting the upper and lower eyelids will usually reveal the foreign body, which may then be removed with a moist cotton swab. An antibiotic eye bandage is placed until the patient is completely free of symptoms.

18.3.5 Corneal Erosion

Etiology: This disorder follows initial **trauma** to the surface cornea, such as the fingernail of a child carried in the parent's arms, a spiked-leaf palm tree, or a branch that snaps back on to the eye. Properly treated, this epithelial defect usually heals within a short time, i.e., 24 to 48 hours depending on the size of the defect. However, *occasionally* the epithelial cells do not properly adhere to Bowman's layer so that the epithelium repeatedly ruptures at the site of the initial injury. This characteristically occurs in the morning when the patient wakes up and suddenly opens his or her eyes. This **recurring erosion** often creates severe emotional stress for the patient.



Symptoms and diagnostic considerations: Immediately after the injury, the patient experiences a severe foreign-body sensation associated with tearing. Because there is actually a defect in the *surface* of the cornea, the patient has the subjective sensation of a foreign body *within* the eye. The epithelial defect causes severe pain, which immediately elicits a blepharospasm. Additional symptoms associated with corneal erosion include immediate eyelid swelling and conjunctival injection. Fluorescein sodium dye will readily reveal the corneal defect when the eye is examined through a blue light (Fig. 18.5).

Treatment: An antibiotic ointment eye bandage is used.



Treatment of recurrent corneal erosion often requires hospitalization. Bilateral bandages are placed to ensure that the eyes are completely immobilized.

18.3.6 Blunt Ocular Trauma (Ocular Contusion)

Epidemiology and etiology: Ocular contusions resulting from blunt trauma such as a fist, ball, champagne cork, stone, falling on the eye, or a cow's horn are very common. Significant deformation of the globe can result where the diameter of the blunt object is less than that of the bony structures of the orbit.

Clinical picture and diagnostic considerations: Deformation exerts significant traction on intraocular structures and can cause them to tear. Often there will be blood in the anterior chamber, which will initially prevent the examiner from evaluating the more posterior intraocular structures.

Corneal erosion.

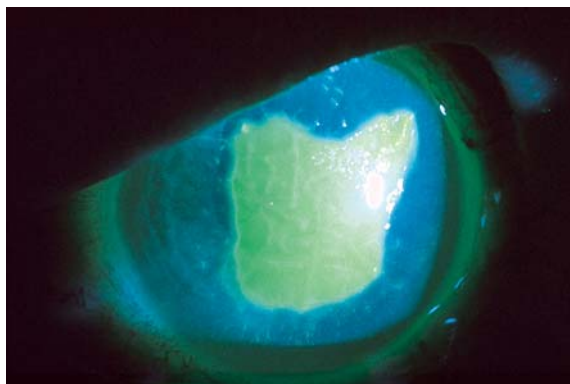


Fig. 18.5 The epithelial defect in the cornea is readily visible when the eye is examined through a blue light after administration of fluorescein sodium dye.



- !** Do not administer medications that act on the pupil as there is a risk of irreversible mydriasis from a sphincter tear, and pupillary movements increase the risk of subsequent bleeding. The posterior intraocular structures should only be thoroughly examined in mydriasis to determine the extent of injury after a week to ten days.

Common injuries are listed in Table 18.1 and Fig. 18.6.

Late sequelae of blunt ocular trauma include:

- ❖ Secondary glaucoma.
- ❖ Retinal detachment.
- ❖ Cataract.

- !** Late sequelae of blunt ocular trauma may occur years after the injury.

Treatment: This involves immobilizing the eye initially, to allow intraocular blood to settle. See Table 18.1 for details.

- !** Subsequent bleeding three or four days after the injury is common.

18.3.7 Blow-out Fracture

Etiology (see also blunt ocular trauma): Blow-out fractures of the orbit result from blunt trauma. Blunt objects of small diameter, such as a fist, tennis ball, or baseball, can compress the contents of the orbit so severely that orbital wall fractures. This fracture usually occurs where the bone is thinnest, *along the paper-thin floor of the orbit over the maxillary sinus*. The ring-shaped bony orbital rim usually remains intact. The fracture can result in protrusion and impingement of orbital fat and the inferior rectus and its sheaths in the fracture gap. Where the *medial ethmoid wall* fractures instead of the orbital floor, emphysema in the eyelids will result.

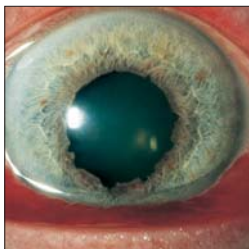
Symptoms and diagnostic considerations: The more severe the contusion, the more severe the intraocular injuries and resulting visual impairment will be. Impingement of the inferior rectus can result in **diplopia**, especially in upward gaze. Initially, the diplopia may go unnoticed when the eye is still swollen shut. A large bone defect may result in displacement of larger portions of the contents of the orbital cavity. The eye may recede into the orbit (**enophthalmos**) and the **palpebral fissure may narrow**. Injury to the infraorbital nerve, which courses along the floor of the orbit, may result. This can cause **hypesthesia of the facial skin**.

Crepitus upon palpation during examination of the eyelid swelling is a sign of emphysema due to collapse of the ethmoidal air cells. The crepitus is caused by air entering the orbit from the paranasal sinuses. The patient should refrain from blowing his or her nose for the next four or five days to avoid forcing air or germs into the orbit. Radiographs should be obtained and an ear, nose, and throat specialist consulted to help determine the **exact**

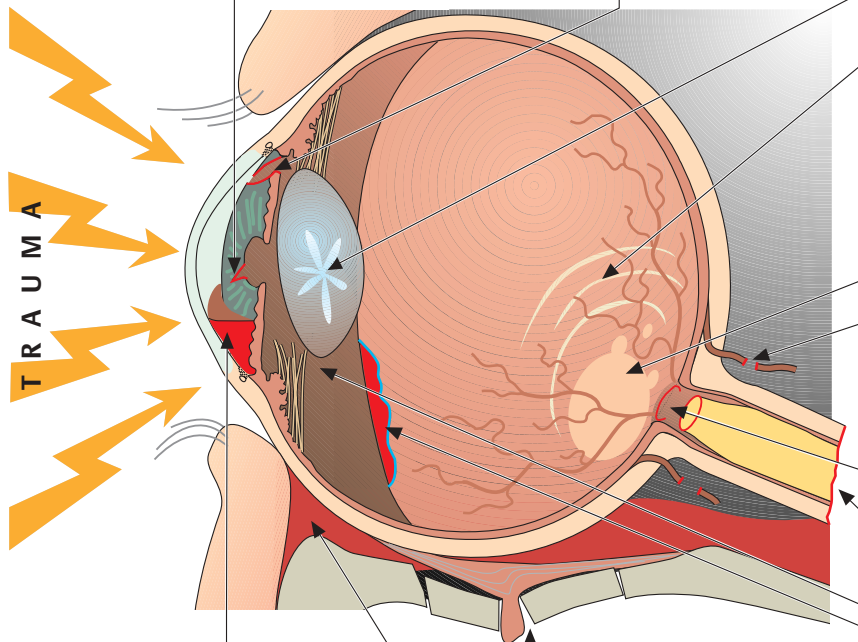
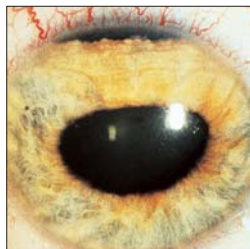

Possible ocular injuries resulting from blunt trauma.

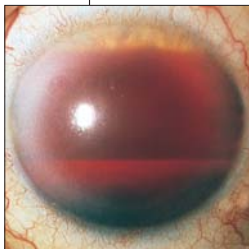Sphincter tear



Iridodialysis



Hyphema



Orbital floor fracture with impingement of the inferior rectus

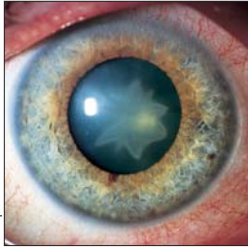
Retrolbulbar and eyelid hematoma

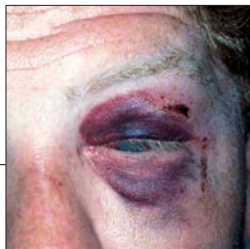

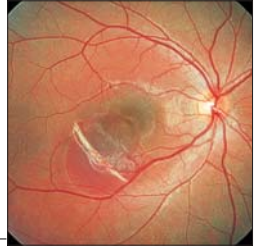
Fig. 18.6 See text and Table 18.1 for details.



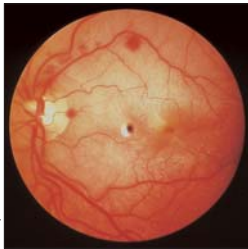Traumatic cataract (contusion rosette)



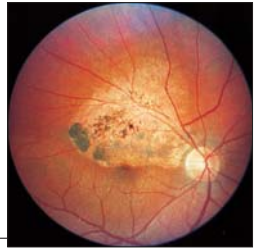Choroidal rupture



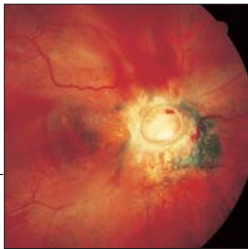Retinal contusion (Berlin's edema)



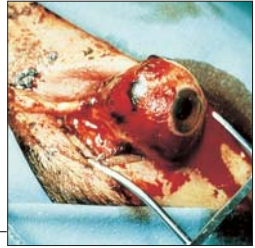
Traumatic retinochoroidopathy



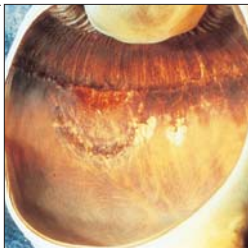
Avulsion of the optic nerve



Avulsion of the globe



Tear in the ora serrata



Subluxation of the lens

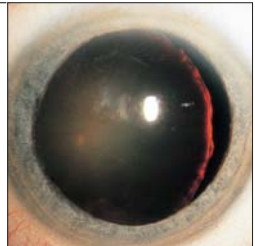



Table 18.1 Overview of possible injuries resulting from blunt trauma to the globe

Description of injury	Definition	Sequelae	Treatment
Iridodialysis	Avulsion of the root of the iris.	<ul style="list-style-type: none">❖ Loss of pupillary roundness.❖ Increased glare.❖ Optical impairment results if there is a large gap at the palpebral fissure leading to a 'double pupil'.	Suture of the base of the iris is indicated for severe injuries (patient has two pupils due to severe avulsion; see Fig. 18.6). Other cases do not require treatment.
Traumatic aniridia	Total avulsion of the iris.	Patient suffers from increased glare.	<ul style="list-style-type: none">❖ Sun glasses.❖ Where a simultaneous cataract is present, a black prosthetic lens with an optical aperture the size of the pupil is inserted during cataract surgery.
Recession of the angle	Widening of the angle of the anterior chamber.	Late sequela: secondary glaucoma.	See Chapter 10.
Cyclodialysis	Avulsion of the ciliary body from the sclera.	<ul style="list-style-type: none">❖ Intraocular hypotonia with choroidal folds and optic disk edema.❖ Visual impairment.	The ciliary body must be reattached with sutures to prevent phthisis bulbi (shrinkage of the eyeball).
Subluxation of the lens	Avulsion of the zonule fibers.	<ul style="list-style-type: none">❖ Dislocation of the lens and iridodonesis.❖ Decreased visual acuity.	Removal of the lens and implantation of a prosthetic lens; see Chapter 7.
Vitreous detachment	Separation of the base of the vitreous body.	Patient sees floaters (see Chapter 11).	See Chapter 11.

Continued →



Table 18.1 (Continued)

Description of injury	Definition	Sequelae	Treatment
Avulsion of the ora serrata	Avulsion of the peripheral retina (ora serrata).	Retinal detachment resulting in flashes of light, shadows, and blindness.	Retinal surgery; see Chapter 12.
Sphincter tear	Tear in the sphincter pupillae with elongation of the iris.	Traumatic mydriasis or impaired pupillary function may be present.	Sun glasses are indicated. Otherwise no treatment is possible.
Contusion rosette	Traumatic lens opacity (traumatic cataract).	<ul style="list-style-type: none"> ❖ Rosette-shaped sub-capsular opacity on the anterior surface of the lens, which with time migrates into the deeper cortex due to the apposition of lens fibers yet otherwise remains unchanged. ❖ Patient suffers from gradually increasing loss of visual acuity. 	Opacity in the optical center is routinely an indication for surgery (see Chapter 7, for details of surgery).
Berlin's edema	Retinal and macular edema at the posterior pole of the globe (contrecoup location) possibly associated with bleeding.	Loss of visual acuity.	Watch-and-wait approach is advised until swelling recedes.
Choroidal ruptures	Crescentic concentric choroidal tears around the pupil.	Tears that extend through the macula can result in decreased visual acuity.	No treatment is possible. Watch-and-wait approach is advised until scarring develops.

Continued →



Table 18.1 (Continued)

Description of injury	Definition	Sequelae	Treatment
Traumatic retinochoroidopathy	Choroidal and retinal atrophy due to avulsion or impingement of the short posterior ciliary arteries.	Loss of visual acuity.	No treatment is possible.
Avulsion of the globe	Traumatic avulsion of the globe out of the orbit, frequently associated with avulsion of the optic nerve (see next row).	Immediate blindness.	Enucleation.
Avulsion of the optic nerve	Avulsion of the entire optic nerve at its point of entry into the globe.	Immediate blindness.	The separation of the nerve fibers is irreversible.
Injury to the optic nerve	Possible injuries include: <ul style="list-style-type: none">❖ Hematoma of the optic nerve sheath.❖ Optic nerve contusion.❖ Fracture of the optic nerve canal.	Atrophy of the optic nerve with loss of visual acuity and visual field defects.	No treatment is possible.
Retrobulbar hematoma	Injury to retrobulbar vascular structures.	<ul style="list-style-type: none">❖ Orbital bleeding.❖ Eyelid hematoma.❖ Exophthalmos.	<ul style="list-style-type: none">❖ Wait for blood to be absorbed.❖ Surgery is indicated only when the central retinal artery is occluded by pressure.

Continued →



Table 18.1 (Continued)

Description of injury	Definition	Sequelae	Treatment
Hyphema	Bleeding in the anterior chamber.	Patient has blurred vision.	<ul style="list-style-type: none"> ❖ Patient should assume an upright posture to allow blood to settle. This will restore vision. ❖ Hyphema will resolve spontaneously.
Vitreous hemorrhage	Bleeding into the vitreous chamber.	<ul style="list-style-type: none"> ❖ Identified by the lack of red reflex on retroillumination during ophthalmoscopy. ❖ Loss of visual acuity. 	Wait for spontaneous recession.
Orbital fracture (blow-out fracture)	Fracture of the floor of the orbit with displacement into the maxillary sinus.	<ul style="list-style-type: none"> ❖ Diplopia in the affected eye. ❖ Elevation or depression deficit. 	<ul style="list-style-type: none"> ❖ Patient should refrain from blowing his or her nose if paranasal sinuses are involved (crepitus upon palpation). ❖ Surgical repair of the orbital floor and release of impinged orbital contents.

location of the fracture. CT studies are more precise and may be indicated to evaluate difficult cases.



Tissue displaced into the maxillary sinus will resemble a hanging drop of water in the CT image.

Treatment: Surgery to restore normal anatomy and the integrity of the orbit should be performed within ten days. This minimizes the risk of irreversible damage from scarring of the impinged inferior rectus. Where treatment is prompt, the prognosis is good (see Section 15.8 for orbital surgery).



Tetanus prophylaxis and treatment with antibiotics are crucial.



18.3.8 Open-Globe Injuries

Etiology: Together with severe chemical injuries, open-globe injuries are the most devastating forms of ocular trauma. They are caused by sharp objects that penetrate the cornea and sclera. A distinction is made between penetration with and without an intraocular foreign body. However, even blunt trauma can cause an open-globe injury in an eye weakened by previous surgery or injury where extremely high-energy forces are involved (such as falling on a cane or a blow from a cow's horn).

Clinical picture and diagnostic considerations: Penetrating injuries cover the entire spectrum of clinical syndromes. Symptoms can range from massive penetration of the cornea and sclera (Fig. 18.7) with loss of the anterior chamber to tiny, nearly invisible injuries that close spontaneously. The latter may include a fine penetrating wound or the entry wound of a foreign body. Depending on the severity of the injury, the patient's visual acuity may be severely compromised or not influenced at all.

One of the most common sequelae is a **traumatic cataract**. The rupture in the lens capsule allows aqueous humor to penetrate, causing the lens to swell. This results in lens opacification of varying severity. Large defects will lead to total opacification of the lens within hours or a few days. Smaller defects that close spontaneously often cause a circumscribed opacity. Typically, penetration results in a rosette-shaped anterior or posterior subcapsular opacity.

Depending on the severity of the injury, the following **diagnostic signs** will be present in an open-globe injury:

- ❖ The anterior chamber will be shallow or absent.
- ❖ The pupil will be displaced toward the penetration site.

Penetrating injury.

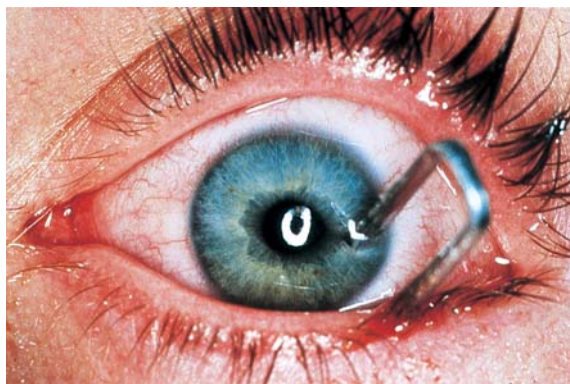


Fig. 18.7 Open-globe injury from a staple involving the cornea, iris, lens, sclera, and retina.



- ❖ Swelling of the lens will be present (traumatic cataract).
- ❖ There will be bleeding in the anterior chamber and vitreous body.
- ❖ Hypotonia of the globe will be present.

The rupture of the lens capsule and vitreous hemorrhage often render examination difficult as they prevent direct inspection. These cases, and any patient whose history suggests an intraocular foreign body, require one or both of the following diagnostic imaging studies:

- ❖ Radiographs in two planes to determine whether there is a foreign body in the eye.
- ❖ CT studies, that permit precise localization of the foreign body and can also image radiolucent foreign bodies such as plexiglas.



An injury sustained while working with a hammer and chisel suggests an intraocular foreign body. The diagnosis may be confirmed by examining the fundus in mydriasis and obtaining radiographic studies.

Treatment: First aid. Where penetrating trauma is suspected, a sterile bandage should be applied and the patient referred to an eye clinic for treatment. Tetanus immunization or prophylaxis and prophylactic antibiotic treatment are indicated as a matter of course.

Surgery. Surgical treatment of penetrating injuries must include suturing the globe and reconstructing the anterior chamber. Any extruded intraocular tissue (such as the iris) must be removed. Intraocular foreign bodies (Figs. 18.8a and b) should be removed when the wound is repaired (i.e., by vitrectomy and extraction of the foreign body).

Late sequelae:

- ❖ **Improper reconstruction of the anterior chamber** may lead to adhesions between the iris and the angle of the anterior chamber, resulting in secondary angle closure glaucoma.
- ❖ A **retinal injury** (for example at the site of the impact of the foreign body) can lead to retinal detachment.
- ❖ Failure to remove **iron foreign bodies** can lead to ocular siderosis, which causes irreparable damage to the receptors and may manifest itself years later.
- ❖ **Copper foreign bodies** cause severe inflammatory reactions in the eye (ocular chalcosis) within a few hours. Symptoms range from uveitis and hypopyon to phthisis bulbi (shrinkage and hypotonia of the eyeball).
- ❖ **Organic foreign bodies** (such as wood) in the eye lead to fulminant endophthalmitis.

18.3.9 Impalement Injuries of the Orbit

Etiology: Impalement injuries occur most frequently in situations such as these:



Intraocular foreign body sustained while working with a hammer and chisel.

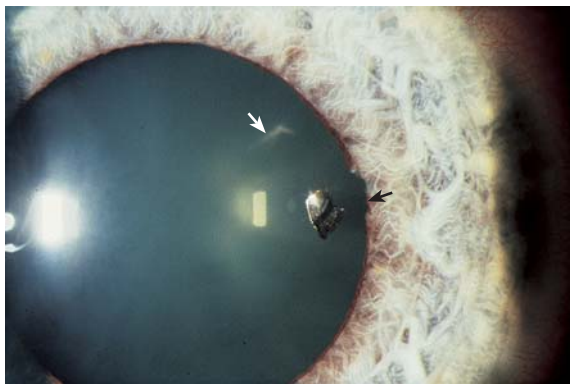
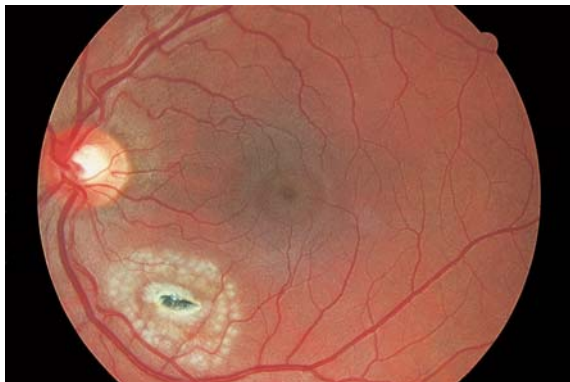
Fig. 18.8 a The iron splinter is lodged in the lens; the cornea has closed spontaneously immediately after the injury (white arrow). A sphincter injury is also present (black arrow).



b The iron splinter entered through the sclera and is now lodged in the retina on the posterior wall of the globe, which it has “coagulated” (white discoloration of the surrounding retinal tissue). Focal burns are placed around the foreign body with

an argon laser to fix the retina before a vitrectomy is performed to remove the foreign body.

- ❖ Children may fall on pencils held in their hands (Fig. 18.9).
- ❖ Injuries may result from the actions of other persons (such as arrows or darts).
- ❖ A knife may slip while a butcher is removing a bone from a cut of meat. Often the impaling “stake” will glance off the round hard outer layer of the globe (*cornea and sclera*) and lodge in the soft tissue of the orbit.

Symptoms and diagnostic considerations: The stake can cause displacement of the globe. Often there will be minimal bleeding in the surrounding



Impalement injury of the right orbit.

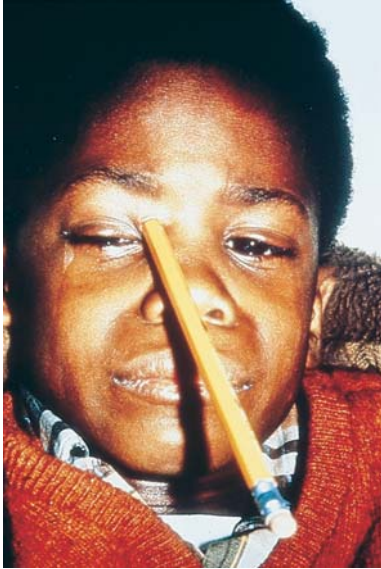

Fig. 18.9 Orbital injury without injury to the globe following a fall on a pencil held in the patient's hand. (Photograph courtesy of Prof. W. D. Green, M.D., Baltimore, Maryland.)

tissue. Diagnostic studies used to ascertain possible damage to intraocular structures include ophthalmoscopy, radiographic studies, and ultrasound.

Treatment: First aid treatment should leave the stake *in situ*. Removing the stake could cause severe bleeding and orbital hematoma. If necessary, the stake should be stabilized before the patient is transported to the eye clinic. Once the patient is in the clinic, the foreign body is removed from the orbit and the integrity of the globe is verified, depending on specific findings. Any bleeding is controlled. Prophylactic antibiotic treatment is indicated routinely to minimize the risk of orbital cellulitis.

18.4 Chemical Injuries

Etiology: Chemical injuries can be caused by a variety of substances such as acids, alkalis, detergents, solvents, adhesives, and irritants like tear gas. Severity may range from slight irritation of the eye to total blindness.



Chemical injuries are among the most dangerous ocular injuries. First aid at the site of the accident is crucial to minimize the risk of severe sequelae such as blindness.



As a general rule, acid burns are less dangerous than alkali burns. This is because most acids do not act deeply. **Acids** differ from alkalis in that they cause immediate *coagulation necrosis* in the superficial tissue. This has the effect of preventing the acid from penetrating deeper so that the burn is effectively a self-limiting process. However, some acids penetrate deeply like alkalis and cause similarly severe injuries. Concentrated sulfuric acid (such as from an exploding car battery) draws water out of tissue and simultaneously develops intense heat that affects every layer of the eye. Hydrofluoric acid and nitric acid have a similar penetrating effect.

Alkalis differ from most acids in that they can penetrate by hydrolyzing structural proteins and dissolving cells. This is referred to as *liquefactive necrosis*. They then cause severe intraocular damage by alkalizing the aqueous humor.

Symptoms: Epiphora, blepharospasm, and severe pain are the primary symptoms. Acid burns usually cause immediate loss of visual acuity due to the superficial necrosis. In alkali injuries, loss of visual acuity *often* manifests itself only several days later.

Clinical picture and diagnostic considerations: Proper diagnosis of the cause and severity of the burn is crucial to treatment and prognosis.



Alkali burns may appear less severe initially than acid burns but they lead to blindness.

Morphologic findings and the resulting prognosis can vary greatly depending on the severity and duration of exposure to the caustic agent. This information is summarized in Table 18.2.

Treatment: First aid rendered at the scene of the accident often decides the fate of the eye. The first few seconds and minutes and resolute action by persons at the scene are crucial. Immediate copious irrigation of the eye may be performed with any watery solution of neutral pH, such as tap water, mineral water, soft drinks, coffee, tea, or similar liquids. Milk should be avoided as it increases penetration of the burn by opening the epithelial barrier. A second person must rigorously restrain the severe blepharospasm to allow effective irrigation. A topical anesthetic to relieve the blepharospasm will rarely be available at the scene of the accident. Coarse particles (such as lime particles in a lime injury) should be flushed and removed from the eye. Only after these actions have been taken should the patient be brought to an ophthalmologist or eye clinic.

Chronology of treatment of chemical injuries:

- ❖ **First aid at the scene of the accident** (coworkers or family members):
 - Restrain blepharospasm by rigorously holding the eyelids open.



Table 18.2 Findings in chemical injuries of various degrees of severity

Severity of the injury	Damage to the corneal epithelium	Damage to the conjunctiva	Damage to the corneal stroma	Intraocular involvement	Prognosis
Slight	<ul style="list-style-type: none"> ❖ Superficial punctate keratitis. ❖ No corneal erosion. 	<ul style="list-style-type: none"> ❖ Conjunctival epithelium largely intact. ❖ Slight chemosis (edematous conjunctival swelling) 	Clear.	None.	Good: Healing without loss of function.
Moderate to severe	Moderate to total corneal erosion.	<ul style="list-style-type: none"> ❖ Moderate chemosis ❖ Segmental ischemia of the limbal vessels. 	Slightly opacified.	Slight irritation of the anterior chamber (slight amount of cellular and protein exudate in the anterior chamber).	Defect healing with functional impairment and possibly symblepharon.
Severe	Total corneal erosion including erosion of the conjunctival epithelium at the limbus.	<ul style="list-style-type: none"> ❖ Severe chemosis. ❖ Total ischemia of the limbal vessels. 	All layers are opacified ("cooked fish eye"; see Fig. 18.11).	<ul style="list-style-type: none"> ❖ Severe irritation of the anterior chamber. ❖ Damage to the iris, lens, ciliary body, and angle of the anterior chamber). 	<ul style="list-style-type: none"> ❖ Poor. ❖ Defect healing with functional impairment that may include loss of the eye. ❖ Symblepharon.



- Irrigate the eye within seconds of the injury using tap water, mineral water, soft drinks, coffee, tea, or similar liquids. Carefully remove coarse particles from the conjunctival sac.
- Notify the rescue squad at the same time.
- Transport the patient to the nearest ophthalmologist or eye clinic.
- ❖ **Treatment by the ophthalmologist or at the eye clinic:**
 - Administer topical anesthesia to relieve pain and neutralize blepharospasm.
 - With the upper and lower eyelids fully everted, carefully remove small particles such as residual lime from the superior and inferior conjunctival fornices under a microscope using a moist cotton swab.
 - Flush the eye with a buffer solution. Long-term irrigation using an irrigating contact lens may be indicated (the lens is connected to a cannula to irrigate the eye with a constant stream of liquid).
 - Initiate systemic pain therapy if indicated.
- ❖ **Additional treatment on the ward in an eye clinic:**

The following therapeutic measures for severe chemical injuries are usually performed on the ward:

 - Continue irrigation.
 - Initiate topical cortisone therapy (dexamethasone 0.1% eyedrops and prednisolone 1% eyedrops).
 - Administer subconjunctival steroids.
 - Immobilize the pupil with atropine 1% eyedrops or scopolamine 0.25% eyedrops twice daily.
 - Administer anti-inflammatory agents (two oral doses of 100 mg indomethacin or diclofenac) or 50–200 mg systemic prednisolone.
 - Administer oral and topical vitamin C to neutralize cytotoxic radicals.
 - Administer 500 mg of oral acetazolamide (Diamox) to reduce intraocular pressure as prophylaxis against secondary glaucoma.
 - Administer hyaluronic acid for corneal care to promote re-epithelialization and stabilize the physiologic barrier.
 - Administer topical antibiotic eyedrops.
 - Debride necrotic conjunctival and corneal tissue and make radial incisions in the conjunctiva (Passow's method) to drain the subconjunctival edema.
- ❖ **Additional surgical treatment in the presence of impaired wound healing following extremely severe chemical injuries:**
 - A *conjunctival and limbal transplantation* (stem cell transfer) can replace lost stem cells that are important for corneal healing. This will allow re-epithelialization.
 - Where the cornea does not heal, cyanoacrylate glue can be used to attach a *hard contact lens* (artificial epithelium) to promote healing.



- A Tenon's capsuloplasty (mobilization and advancement of a flap of subconjunctival tissue of Tenon's capsule to cover defects) can help to eliminate conjunctival and scleral defects.
- ❖ **Late surgical treatment after the eye has stabilized:**
 - Lysis of symblepharon (symblepharon refers to adhesions between the palpebral and bulbar conjunctiva; see also prognosis and complications) to improve the motility of the globe and eyelids.
 - Plastic surgery of the eyelids to the release the globe. This should be only performed 12 to 18 months after the injury).
 - Where there is total loss of the goblet cells, transplantation of nasal mucosa usually relieves pain (the lack of mucus is substituted by goblet cells from the nasal mucosa).
 - Penetrating keratoplasty (see Chapter 5) may be performed to restore vision. Because the traumatized cornea is highly vascularized (Fig. 18.10), these procedures are plagued by a high incidence of graft rejection. A clear cornea can rarely be achieved in a severely burned eye even with a HLA-typed corneal graft and immunosuppressive therapy.

Prognosis and possible complications: The degree of ischemia of the conjunctiva and the limbal vessels is an indicator of the severity of the injury and the prognosis for healing (see Table 18.2). The *greater the ischemia of the conjunctiva and limbal vessels, the more severe the burn will be*. The most severe form of chemical injury presents as a “**cooked fish eye**” (Fig. 18.11) for which the prognosis is very poor, i.e., blindness is possible.

Moderate to severe chemical injuries involving the bulbar and palpebral conjunctiva can result in **symblepharon** (adhesions between the palpe-

Lime injury.

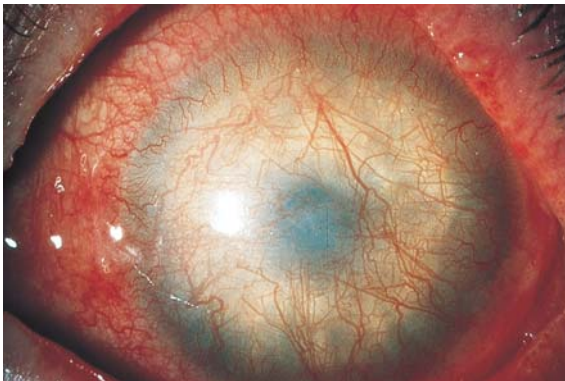


Fig. 18.10 Superficial and deep corneal vascularization is present, and the eye is dry due to loss of most of the goblet cells.



“Cooked fish eye” following alkali injury.

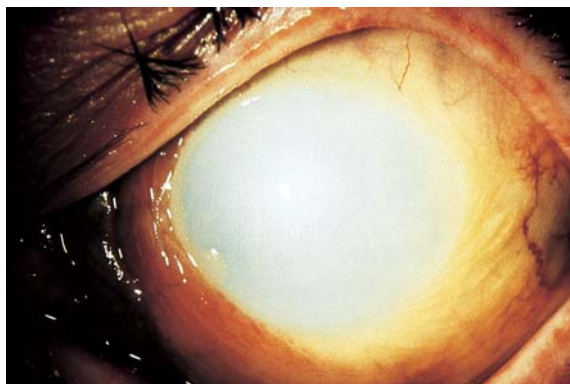


Fig. 18.11 The cornea is white as chalk and opaque. The vascular supply to the limbus (capillaries at its edge) has been obliterated.

Symblepharon.

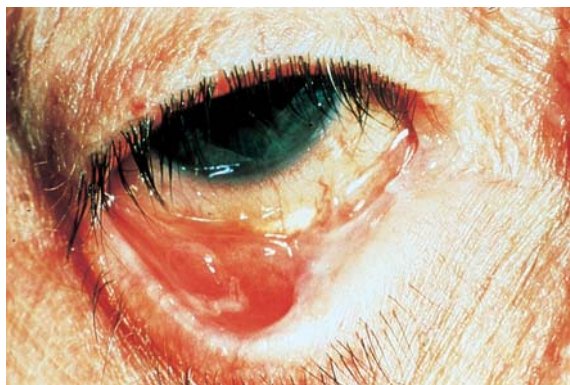

Fig. 18.12 Moderate and severe chemical injuries may produce adhesions between the palpebral and bulbar conjunctiva.

bral and bulbar conjunctiva; Fig. 18.12). Inflammatory reactions in the anterior chamber secondary to chemical injuries can lead to **secondary glaucoma**.



18.5 Injuries Due to Physical Agents

18.5.1 Ultraviolet Keratoconjunctivitis

Etiology: Injury from ultraviolet radiation can occur from welding without proper eye protection, exposure to high-altitude sunlight with the eyes open without proper eye protection, or due to sunlight reflected off snow when skiing at high altitudes on a sunny day. Intense ultraviolet light can lead to ultraviolet keratoconjunctivitis within a short time (for example just a few minutes of welding without proper eye protection). Ultraviolet radiation penetrates only slightly and therefore causes only superficial necrosis in the corneal epithelium. The exposed areas of the cornea and conjunctiva in the palpebral fissure become edematous, disintegrate, and are finally cast off.

! Ultraviolet keratoconjunctivitis is one of the most common ocular injuries.

Symptoms and diagnostic considerations: Symptoms typically manifest themselves after a latency period of six to eight hours. This causes patients to seek the aid of an ophthalmologist or eye clinic in the middle of the night, complaining of “acute blindness” accompanied by pain, photophobia, epiphora, and an intolerable foreign-body sensation. Often severe blepharospasm will be present. Slit-lamp examination will require administration of a topical anesthetic. This examination will reveal epithelial edema and superficial punctate keratitis or erosion in the palpebral fissure under fluorescein dye (see Fig. 18.5).

! The topical anesthetic will completely relieve symptoms within a few seconds and allow the patient to see clearly and open his or her eyes without pain. Under no circumstances may the patient be allowed access to this anesthetic without medical supervision. Uncontrolled habitual use suppresses the pain reflex (eye closing reflex), which could result in incalculable corneal damage.

Treatment: The “blinded” patient should be instructed that the symptoms will resolve completely under treatment with antibiotic ointment within 24 to 48 hours. Ointment is best applied to both eyes every two or three hours with the patient at rest in a darkened room. The patient should be informed that the eye ointment will not immediately relieve pain and that eye movements should be avoided.

18.5.2 Burns

Etiology: Flaring flames such as from a cigarette lighter, hot vapors, boiling water, and splatters of hot grease or hot metal cause thermal coagulation of the corneal and conjunctival surface. Because of the eye closing reflex, the eyelids often will be affected as well.



Injuries due to explosion or burns from a starter's gun also include particles of burned powder (powder burns). Injuries from a gas pistol will also involve a chemical injury.

Symptoms and diagnostic considerations: Symptoms are similar to those of chemical injuries (epiphora, blepharospasm, and pain).

A topical anesthetic is administered, and the eye is examined as in a chemical injury. *Immediate opacification of the cornea* will be readily apparent. This is due to scaling of the epithelium and tissue necrosis, whose depth will vary with the severity of the burn. In burns from metal splinters, one will often find cooled metal particles embedded in the cornea.

Treatment: Initial treatment consists of applying cooling antiseptic bandages to relieve pain, after which necrotic areas of the skin, conjunctiva, and cornea are removed under local anesthesia. Foreign particles such as **embedded ash and smoke particles in the eyelids and face** are removed in cooperation with a dermatologist by brushing them out with a sterile toothbrush under general anesthesia. This is done to prevent them from growing into the skin like a tattoo. **Superficial particles in the cornea and conjunctiva** are removed under local anesthesia together with the necrotic tissue. The affected areas are then treated with an antibiotic ointment.

Prognosis: The clinical course of a burn is usually less severe than that of a chemical injury. This is because burns, like acid injuries, cause superficial coagulation. Usually they heal well when treated with antibiotic ointment.

18.5.3 Radiation Injuries (Ionizing Radiation)

Etiology: Ionizing radiation (neutron, or gamma/x-ray radiation) have high energy that can cause ionization and formation of radicals in cellular tissue. Penetration depth in the eye varies with the type of radiation, i.e., the wavelength, resulting in characteristic types of tissue damage (Fig. 18.13). This tissue damage always manifests itself after a latency period, often only after a period of years (see also Symptoms and clinical picture). Common sites include the lens (radiation cataract) and retina (radiation retinopathy). This tissue damage is usually the result of tumor irradiation in the eye or nasopharynx. Radiation disorders have been observed in patients from Hiroshima and Nagasaki and, more recently, in Chernobyl.

Symptoms and clinical picture: Loss of the eyelashes and eyelid pigmentation accompanied by blepharitis are typical symptoms. A dry eye is a sign of damage to the conjunctival epithelium (loss of the goblet cells). Loss of visual acuity due to a radiation cataract is usually observed within one or two years of irradiation. Radiation retinopathy in the form of ischemic retinopathy with bleeding, cotton-wool spots, vascular occlusion, and retinal neovascularization usually occurs within months of irradiation.



Possible radiation damage to the eye.

Ultraviolet
keratoconjunctivitis

Radiation
cataract

Radiation
retinopathy

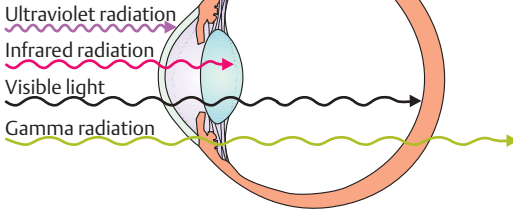


Fig. 18.13 The penetration depth of radiation in the eye varies according to wavelength. Therefore, each radiation injury causes characteristic tissue damage.

Treatment and prophylaxis: Care should be taken to cover the eyes prior to planned radiation therapy in the head and neck. Radiation cataract may be treated surgically. Radiation retinopathy may be treated with panretinal photocoagulation with an argon laser.

18.6 Indirect Ocular Trauma: Purtscher's Retinopathy

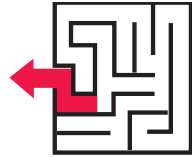
Etiology: Arterial and venous circulatory disruption in the retina characterized by a sudden increase in intravascular pressure may occur following severe chest injuries (compression trauma such as in a seat-belt injury) or fractures of long bones (presumably due to fat embolisms or vascular spasms).

Symptoms and diagnostic considerations: Acute retinal ischemia with impaired vision and loss of visual acuity will occur either immediately or within three to four days of the injury. Examination of the fundus will reveal cotton-wool spots and intraretinal bleeding indicative of focal retinal ischemia. Lines of bleeding will also be observed.

Treatment: Fundus symptoms will usually disappear spontaneously within four to six weeks. Reduced visual acuity and visual field defects may occasionally persist. Occasionally treatment with high doses of systemic steroids and prostaglandin inhibitors is attempted.

19 Cardinal Symptoms

Gerhard K. Lang



This list of cardinal symptoms is included to provide the medical student, intern, or ophthalmology resident with a concise overview of the range of possible underlying clinical syndromes. This compilation of cardinal symptoms cannot and does not represent a complete and comprehensive listing. Nonetheless, it will also be helpful in recalling the most important clinical pictures in ophthalmology and providing a review of the material.



Cardinal symptoms	Possible associated symptoms and findings	Tentative diagnosis (probable underlying clinical picture)	Further diagnostic work-up
Burning sensation Common causes:	<ul style="list-style-type: none">❖ Reddening of the eyelids.❖ Adhesion of the eyelashes.❖ Scales on the eyelids and bases of the eyelashes.❖ Itchy eyelid margins.❖ Common in fair-haired patients.	Blepharitis.	Exclude refractive anomaly as possible cause.
	<ul style="list-style-type: none">❖ Sensation of pressure, dryness, and sand in the eyes.❖ Occasionally excessively tearing in response to dry eyes.❖ Dryness of other mucous membranes.	Dry eyes (keratoconjunctivitis sicca).	Evaluate tear secretion with Schirmer tear testing and tear break-up time (TBUT).
Rare causes:	<ul style="list-style-type: none">❖ Reddened conjunctiva.❖ Purulent, mucoid, or watery discharge.❖ Sticky eyelids in the morning.	Conjunctivitis.	Obtain smear for microbiological examination.
	<ul style="list-style-type: none">❖ Usually segmental, livid reddening of the conjunctiva.❖ Nodular mobile swelling that is tender to palpation.	Episcleritis.	Unequivocal diagnosis.
	<ul style="list-style-type: none">❖ Circumscribed reddening at the pinguecula.❖ Thickened conjunctival vessels.	Irritated pinguecula.	Unequivocal diagnosis.



	<p>Circumscribed reddening at the pterygium.</p> <p>Reddening in the upper circumference near the limbus.</p>	<p>Irritated pterygium.</p> <p>Keratitis of the upper limbus.</p>	<p>Unequivocal diagnosis.</p> <p>Unequivocal diagnosis.</p>
<p>Tearing (epiphora) In children:</p>	<ul style="list-style-type: none"> ❖ Buphthalmos. ❖ Increased glare and squinting. ❖ Unilateral or bilateral. ❖ Corneal opacification. <ul style="list-style-type: none"> ❖ Red eye. ❖ Severe foreign-body sensation. ❖ Pain causing blepharospasm. ❖ Photophobia. ❖ Eyelid swelling. ❖ Decreased visual acuity. <ul style="list-style-type: none"> ❖ No pain. ❖ Nearly constant purulent watery discharge. ❖ Sticky eyelids in the morning. ❖ No itching or reddening of the eye and no visible eyelid deformity. 	<p>Congenital glaucoma.</p> <ul style="list-style-type: none"> ❖ Subtarsal or corneal foreign body. ❖ Corneal erosion. <p>Dacryostenosis (valve of Hasner).</p>	<ul style="list-style-type: none"> ❖ Risk of blindness. ❖ Measure intraocular pressure immediately. <ul style="list-style-type: none"> ❖ Full eversion of the eyelids to localize subtarsal foreign body. ❖ Apply fluorescein dye to evaluate cornea where corneal erosion is suspected. <p>Irrigate lacrimal system to locate the stenosis.</p>
<p>In adults (painless or nearly painless):</p>	<ul style="list-style-type: none"> ❖ Reddening of the conjunctiva. ❖ Only minimal symptoms. ❖ Ectropion develops from constantly wiping away tears. ❖ Epidermization of the exposed conjunctiva. 	<p>Ectropion.</p>	<p>Unequivocal diagnosis.</p>



Cardinal symptoms	Possible associated symptoms and findings	Tentative diagnosis (probable underlying clinical picture)	Further diagnostic work-up
Tearing In adults (painless or nearly painless):	<ul style="list-style-type: none">❖ Sandy, dry feeling.❖ Eye often free of irritation.❖ Oral, nasal, and genital mucous membranes often are also dry.	<ul style="list-style-type: none">❖ Dry eyes.❖ Dry eyes in keratoconjunctivitis sicca.	Evaluate tear secretion with Schirmer tear testing and tear break-up time (TBUT).
	<ul style="list-style-type: none">❖ Slight pain.❖ Purulent discharge of thickened tear fluid and pus is common (expressed from the punctum by pressing on the lacrimal sac).❖ Recurrent dacryocystitis.	Obstructed drainage through the lower lacrimal system, possibly with inflammation.	Irrigate the lower lacrimal system to localize the stenosis.
Painful:	<ul style="list-style-type: none">❖ Clear tear fluid.❖ Punctum is covered by connective tissue or projects from the eye.	Obstruction or eversion of the punctum lacrimale.	Unequivocal diagnosis.
	<ul style="list-style-type: none">❖ Severe foreign-body sensation.❖ Eyelid swelling.❖ Blepharospasm and photophobia.❖ Reddened eye.❖ Decreased visual acuity.	<ul style="list-style-type: none">❖ Corneal erosion.❖ Subtarsal corneal foreign body.	<ul style="list-style-type: none">❖ Evert eyelid to localize subtarsal corneal foreign body.❖ Apply fluorescein dye to evaluate cornea where corneal erosion is suspected.
	<ul style="list-style-type: none">❖ Foreign-body sensation (eyelashes scratch cornea).❖ Inward deformity of the eyelashes, eyelid turned inward.	Trichiasis, entropion.	Unequivocal diagnosis.



Increased glare	<ul style="list-style-type: none"> ❖ Gray to white pupillary reflex. ❖ Gradual progressive loss of visual acuity. 	Cataract.	Slit-lamp examination. Diagnosis is unequivocal where the opacity is visible under retroillumination.
	<ul style="list-style-type: none"> ❖ Wide pupil (mydriasis). ❖ Little or no pupillary response to light. ❖ Pupil width is different from fellow eye. 	Traumatic or drug-induced paralysis of the sphincter pupillae.	Slit-lamp examination. Iris and pupillary response may be evaluated under retroillumination.
	<p>In children:</p> <ul style="list-style-type: none"> ❖ Enlargement of the cornea and unilateral or bilateral opacification. ❖ Increased glare with squinting. 	Buphthalmos.	<ul style="list-style-type: none"> ❗ Risk of blindness. ❖ Measure intraocular pressure immediately.
	<ul style="list-style-type: none"> ❖ Pigmentation deficiency in iris. ❖ Skin and hair pigmentation deficiency. 	Albinism.	Unequivocal diagnosis.
	<ul style="list-style-type: none"> ❖ History of trauma. ❖ Pupil is not round. ❖ Complete or partial aniridia. 	Iris defects (avulsion of the root of the iris or aniridia).	Unequivocal diagnosis.
Diplopia Binocular	<ul style="list-style-type: none"> ❖ No eye pain. ❖ Neurologic symptoms depending on cause. ❖ Possible history of trauma. 	Cranial nerve palsy (in central ischemia or apoplexy, intracranial tumors, or cerebral trauma).	Neurologic and neuroradiologic diagnostic studies are indicated.



Cardinal symptoms	Possible associated symptoms and findings	Tentative diagnosis (probable underlying clinical picture)	Further diagnostic work-up
Diplopia Binocular	<ul style="list-style-type: none"> ❖ History of trauma (always present with ocular contusion; when the eyelid is swollen shut, diplopia will not be apparent to the patient). ❖ Limited ocular motility in elevation and depression. ❖ Exophthalmos (posteriorly displaced eye). ❖ Pain during eye motion. ❖ Reddening and swelling of the eyelid and conjunctiva. ❖ Severe swelling of the eyelid and conjunctiva. ❖ Severe malaise. ❖ Affected eye is often immobile ("cemented" globe). ❖ Exophthalmos (in children, this is a sign of orbital cellulitis). 	Fracture of the floor of the orbit.	<ul style="list-style-type: none"> ❖ Obtain radiographs. ❖ In difficult cases, CT is indicated for precise localization of the fracture.
	Pain during eye motion. Reddening and swelling of the eyelid and conjunctiva.	Ocular myositis.	Ultrasound scan of the muscles.
	Severe swelling of the eyelid and conjunctiva. Severe malaise. Affected eye is often immobile ("cemented" globe). Exophthalmos (in children, this is a sign of orbital cellulitis).	Orbital cellulitis.	<ul style="list-style-type: none"> ❗ Risk of blindness (optic nerve atrophy). ❗ Cavernous sinus thrombosis is a life-threatening sequela. <p>Consult ENT specialist: Orbital cellulitis originates in the paranasal sinuses in 60% of all cases, and in 84% of all cases in children.</p>
	Associated Hyperthyreosis (in 60% of all cases) and keratoconjunctivitis sicca.	Graves' disease.	<ul style="list-style-type: none"> ❖ Ultrasound and/or CT is indicated to determine whether muscles are thickened.





<ul style="list-style-type: none"> ❖ Unilateral or bilateral exophthalmos may be present. ❖ Characteristic eyelid signs (see Table 15.3). 	<ul style="list-style-type: none"> ❖ Thyroid diagnostic studies by endocrinologist are indicated.
<ul style="list-style-type: none"> ❖ Patient suddenly experiences diplopia vision (often at the age of two to six). ❖ Patient closes one eye to suppress diplopia. 	<p>Late strabismus with normal sensory development.</p> <p>Unequivocal diagnosis.</p>
<ul style="list-style-type: none"> ❖ Scarring limits ocular motility. ❖ Diplopia in temporal gaze. ❖ Pterygium clearly visible with the unaided eye. 	<p>Pterygium.</p> <p>Unequivocal diagnosis.</p>
<p>Monocular</p>	<ul style="list-style-type: none"> ❖ Gray to white pupillary reflex. ❖ Gradual loss of visual acuity. ❖ Increased glare. <p>Slit-lamp examination. Diagnosis is unequivocal where the opacity is visible under retroillumination.</p>
<ul style="list-style-type: none"> ❖ Alternating diplopia (dislocated lens changes its position in the eye and may fall back into place in the plane of the pupil when the patient bends forward). 	<p>Dislocation or subluxation of the lens.</p> <p>Unequivocal diagnosis. Equator of the lens is visible in the plane of the pupil under retroillumination.</p>
<ul style="list-style-type: none"> ❖ History of trauma (avulsion of the root of the iris). ❖ Congenital or traumatic aniridia. 	<p>“Double” pupil due to an iris defect (avulsion of the root of the iris or aniridia).</p> <p>Unequivocal diagnosis.</p>
<p>Conical or hemispherical protrusion deformation of the cornea.</p>	<p>Keratoconus or keratoglobus. Diplopia results from multiple focal points of the deformed cornea.</p> <p>Unequivocal diagnosis. Condition may be visible with the unaided eye or verified by standard keratotomy or videokeratotomy.</p>



Cardinal symptoms	Possible associated symptoms and findings	Tentative diagnosis (probable underlying clinical picture)	Further diagnostic work-up
Enophthalmos (eye recedes into orbit)	<ul style="list-style-type: none"> ❖ History of trauma (signs of ocular contusion). ❖ Diplopia. ❖ Eyelid swelling. ❖ Limited ocular motility in elevation and depression. 	Fracture of the floor of the orbit.	<ul style="list-style-type: none"> ❖ Obtain radiographs. ❖ In difficult cases, CT is indicated for precise localization of the fracture.
Exophthalmos (projecting eye)	<ul style="list-style-type: none"> ❖ Triad of ptosis, miosis, exophthalmos (unilateral findings). ❖ Blind eye. ❖ Phthisis (shrinkage of the eyeball). ❖ Pseudoexophthalmos (severe trauma, surgery, or retinal detachment) and chronic inflammation (uveitis or retinitis). ❖ Loss of orbital fatty tissue in advanced age (eyes recede into the orbit). ❖ Always bilateral 	<p>Horner's syndrome.</p> <p>Ocular atrophy with shrinkage of the globe.</p> <p>Senile sunken eye.</p>	<p>Neurologic examination.</p> <p>Unequivocal diagnosis.</p> <p>Unequivocal diagnosis.</p> <ul style="list-style-type: none"> ❖ Ultrasound and/or CT is indicated to determine whether muscles are thickened. ❖ Thyroid diagnostic studies by endocrinologist are indicated.



<ul style="list-style-type: none"> ❖ Metamorphopsia. ❖ Retinal impression folds are visible under ophthalmoscopy. 	<p>Retrobulbar tumor (exophthalmos due to posterior pressure on the globe).</p>	<p>CT scan.</p>
<ul style="list-style-type: none"> ❖ History of trauma. ❖ Eyelid hematoma (black eye). ❖ Eyelid swelling. 	<p>Orbital bleeding.</p>	<p>Radiographs to exclude injury of the bony structures of the orbit.</p>
<ul style="list-style-type: none"> ❖ Pseudoexophthalmos due to long globe. ❖ Occasionally unilateral. ❖ Difference in refraction (anisometropia). ❖ Poor distance vision; good near vision. 	<p>Severe myopia.</p>	<p>Refraction testing.</p>
<ul style="list-style-type: none"> ❖ Pain during eye motion. ❖ Diplopia. ❖ Reddening and swelling of the eyelid and conjunctiva. 	<p>Ocular myositis.</p>	<p>Ultrasound scan of the muscles.</p>
<ul style="list-style-type: none"> ❖ Patients are often children. ❖ Severe swelling of the eyelid and conjunctiva. ❖ Severe malaise. ❖ Affected eye is often immobile ("cemented" globe). 	<p>Orbital cellulitis.</p>	<p>  Risk of blindness (optic nerve atrophy).  Cavernous sinus thrombosis is a life-threatening sequela. Consult ENT specialist: Orbital cellulitis originates in the paranasal sinuses in 60% of all cases, and in 84% of all cases in children. </p>
<p>Other developmental anomalies may accompany exophthalmos, which in these cases is usually bilateral.</p>	<p>Craniosynostosis.</p>	<p>Unequivocal diagnosis.</p>



Cardinal symptoms	Possible associated symptoms and findings	Tentative diagnosis (probable underlying clinical picture)	Further diagnostic work-up
Hypopyon	<ul style="list-style-type: none">❖ Deep eye pain that hardly responds to analgesics at all.❖ Reddening and swelling of the eyelids and conjunctiva.❖ Acutely decreased visual acuity.❖ Prior intraocular surgery, penetrating injury, or corneal ulceration.	Acute endophthalmitis.	<ul style="list-style-type: none">❗ Risk of blindness within hours.❖ Microbiological diagnostic studies.
	<ul style="list-style-type: none">❖ Reddening of the conjunctiva.❖ Corneal ulcer.❖ Eyelid swelling.❖ Pain.	Serpiginous corneal ulcer.	<ul style="list-style-type: none">❗ Rapid progression of the ulcer can threaten the eye.❖ Microbiological diagnostic studies.
Headache	<ul style="list-style-type: none">❖ No ocular pain.❖ Iritis or iridocyclitis.	Sterile hypopyon.	<ul style="list-style-type: none">❖ Diagnostic studies for uveitis.❖ Systemic, immunologic, and rheumatologic examinations are required.
	<ul style="list-style-type: none">❖ Unilaterally red, hard eye.❖ Pupil fixed and dilated.❖ Corneal opacification.❖ Severe pain.❖ Frequent vomiting.❖ Sudden unilateral loss of visual acuity.❖ Patients are usually over 60.❖ Headache pain in temples.	Glaucoma attack.	<ul style="list-style-type: none">❗ Risk of blindness.❖ Measure intraocular pressure immediately.
		<ul style="list-style-type: none">❖ AION: anterior ischemic optic neuropathy due to arthritis.❖ Giant cell arthritis in temporal arteritis.	<ul style="list-style-type: none">❗ Risk of blindness.❖ Circular or segmental swelling of the optic disk will be visible upon ophthalmoscopy.



	<ul style="list-style-type: none"> ❖ Temporal artery tender to palpation. ❖ Pain when chewing, weight loss. ❖ Poor overall health. ❖ Myalgia. ❖ Stiff neck. 	<ul style="list-style-type: none"> ❖ Arterial biopsy and histologic examination are indicated. ❖ Determine erythrocyte sedimentation rate and level of C-reactive protein (precipitous drops occur in temporal arteritis).
	<ul style="list-style-type: none"> ❖ Poor vision. ❖ Eyeglasses or change of eyeglass prescription needed. ❖ Rapid fatigue (for example when reading). ❖ Burning sensation. 	<p>Asthenopic symptoms.</p> <p>Test visual acuity.</p>
<p>Flashes of light</p>	<ul style="list-style-type: none"> ❖ Often in older patients. ❖ Flashes of light and shadows seen when moving the eyes, even in the dark. ❖ Floaters. 	<ul style="list-style-type: none"> ❖ Essentially harmless age-related disorder. ❖ Examine fundus to exclude retinal defect.
	<p>Retinal detachment.</p>	<ul style="list-style-type: none"> ❖ Risk of blindness. ❖ Ophthalmoscopy.
	<p>Retinal tear.</p>	<ul style="list-style-type: none"> ❖ Risk of retinal detachment. ❖ Ophthalmoscopy.
<p>Often encountered in patients with consumptive systemic disorders such as AIDS.</p>	<p>Retinitis.</p>	<p>Consult internist for diagnosis of cause.</p>



Cardinal symptoms	Possible associated symptoms and findings	Tentative diagnosis (probable underlying clinical picture)	Further diagnostic work-up
Eyelid swelling Inflammatory:	<ul style="list-style-type: none">❖ Clear vesicles on the eyelids.❖ Eyelid swelling.❖ Inflammatory ptosis.	Herpes simplex virus infection.	Unequivocal diagnosis.
	<ul style="list-style-type: none">❖ Painful pressure point on the eyelid.❖ Circumscribed swelling and reddening of the eyelid.❖ Often severe pulsating pain.❖ Spot of yellow pus.❖ Pseudoptosis.	Hordeolum.	Unequivocal diagnosis.
	<ul style="list-style-type: none">❖ Sting is often visible.❖ Clear swelling.❖ Unilateral.❖ Itching.	Insect sting.	Unequivocal diagnosis.
	<ul style="list-style-type: none">❖ Red eye.❖ Often few symptoms.❖ Sticky eyelids in the morning.❖ Purulent or watery discharge.	Conjunctivitis.	Microbiological diagnostic studies.
	<ul style="list-style-type: none">❖ Large, hard swelling and redden- ing with edema are often pres- ent.❖ Pain.❖ Ptosis.	Eyelid abscess.	Unequivocal diagnosis.



	<ul style="list-style-type: none"> ❖ Severe pain. ❖ Bleeding vesicles. ❖ Pattern of lesions follows trigeminal nerve. 	Herpes zoster ophthalmicus.	Refer patient to dermatologist.
Noninflammatory	<ul style="list-style-type: none"> ❖ Painless, circumscribed swelling of the eyelid. ❖ No reddening. ❖ Hard palpable nodules on the eyelid. ❖ Pseudoptosis. 	Chalazion.	Unequivocal diagnosis.
	<ul style="list-style-type: none"> ❖ Occurs in older patients (elderly skin). ❖ Limp, drooping eyelid. ❖ Drooping eyebrows. 	<ul style="list-style-type: none"> ❖ Cutis laxa senilis. ❖ Blepharochalasis. 	Unequivocal diagnosis.
	<ul style="list-style-type: none"> ❖ S-shaped upper eyelid. ❖ No reddening. ❖ Palpable mass. 	<ul style="list-style-type: none"> ❖ Eyelid tumor. ❖ Lacrimal gland tumor. 	Biopsy.
	No other ocular symptoms.	Systemic cause (heart, kidney, or thyroid disorder).	Refer patient to internist.
	Yellowish mobile prolapsed fat under the eyelids.	Orbital fat hernia.	Unequivocal diagnosis.
	<ul style="list-style-type: none"> ❖ Enophthalmos. ❖ History of trauma (ocular contusion). ❖ Diplopia may be present. 	Fracture of the floor of the orbit.	<ul style="list-style-type: none"> ❖ Obtain radiographs. ❖ In difficult cases, CT is indicated for precise localization of the fracture.



Cardinal symptoms	Possible associated symptoms and findings	Tentative diagnosis (probable underlying clinical picture)	Further diagnostic work-up
Pseudoptosis	<ul style="list-style-type: none">❖ In older patients.❖ Limp eyelid skin.❖ Drooping eyelids.	<ul style="list-style-type: none">❖ Cutis laxa senilis.❖ Blepharochalasis.	Unequivocal diagnosis.
	<ul style="list-style-type: none">❖ History of trauma (signs of ocular contusion).❖ Diplopia may be present.❖ Eyelid swelling.❖ Enophthalmos.	Fracture of the floor of the orbit.	<ul style="list-style-type: none">❖ Obtain radiographs.❖ In difficult cases, CT is indicated for precise localization of the fracture.
Ptosis Common:	<ul style="list-style-type: none">❖ Pseudoenophthalmos.❖ Often secondary to severe trauma, surgery, or chronic inflammation (uveitis or retinitis).❖ Blind eye.	Phthisis (shrinkage of the eyeball).	Unequivocal diagnosis.
	Palpable, immobile swelling.	Eyelid tumors.	Biopsy.
Ptosis Rare:	History of trauma or older patient.	Tear in the levator palpebrae.	Unequivocal diagnosis.
	Secondary to intraocular surgery.	Elongation of the levator palpebrae.	Unequivocal diagnosis.
	Usually bilateral; present at birth.	Congenital ptosis.	Unequivocal diagnosis.
	Paralysis of one of all extraocular muscles.	Chronic progressive external ophthalmoplegia.	Refer patient to neurologist.



	<ul style="list-style-type: none"> ❖ Eyelid swelling. ❖ Pain. ❖ Foreign-body sensation. ❖ Blepharospasm. 	<ul style="list-style-type: none"> ❖ Corneal erosion. ❖ Corneal foreign body. ❖ Subtarsal corneal foreign body. 	<ul style="list-style-type: none"> ❖ Examine cornea. ❖ Fully evert the eyelids where subtarsal foreign body is suspected. ❖ Apply fluorescein dye to evaluate cornea where corneal erosion is suspected.
	Secondary to application of anti-glaucoma medications containing guanethidine.	For drug side effects.	Unequivocal diagnosis.
	Triad of ptosis, miosis, and enophthalmos.	Horner's syndrome.	Refer patient to neurologist.
	Severity of ptosis can vary from day to day.	Myasthenia gravis.	Refer patient to neurologist.
	Accompanied by dilated pupil and diplopia.	Oculomotor nerve palsy.	Refer patient to neurologist.
Pupillary dysfunction Miosis:	Secondary to application of pilocarpine.	Drug-induced miosis.	Unequivocal diagnosis.
	Secondary to use of morphine.	Toxic miosis.	Unequivocal diagnosis.
	Accompanied by ptosis and enophthalmos.	Horner's syndrome.	Refer patient to neurologist.
	<ul style="list-style-type: none"> ❖ Accompanied by iritis or iridocyclitis. ❖ Red eye. ❖ Pain. 	Reactive miosis.	Unequivocal diagnosis.





Cardinal symptoms	Possible associated symptoms and findings	Tentative diagnosis (probable underlying clinical picture)	Further diagnostic work-up
Pupillary dysfunction Mydriasis:	Secondary to administration of atropine or mydriatics.	Drug-induced mydriasis.	Unequivocal diagnosis.
	<ul style="list-style-type: none"> ❖ Ischemic. ❖ Tumor. ❖ History of trauma. 	Lesion of the optic nerve or optic tract.	Refer patient to neurologist.
Rings around light sources	Pupil does not respond to light.	Following sudden blindness.	Unequivocal diagnosis.
	<ul style="list-style-type: none"> ❖ Gradual progressive loss of visual acuity. ❖ Increased glare. ❖ Grayish white pupillary reflex. 	Cataract.	Slit-lamp examination. Diagnosis is unequivocal where the opacity is visible under retroillumination.
	Corneal edema.	Increased intraocular pressure.	Measure intraocular pressure.
Red eye	<ul style="list-style-type: none"> ❖ Conjunctival injection. ❖ Full visual acuity. ❖ Purulent or watery discharge. ❖ Swelling of the eyelid and conjunctiva. ❖ Sticky eyelids in the morning. 	Conjunctivitis.	Obtain smear for microbiological examination.
	<ul style="list-style-type: none"> ❖ Combined injection. ❖ Reduced visual acuity. ❖ Intraocular structures obscured. ❖ Pain. 	Scleritis and/or episcleritis.	Unequivocal diagnosis.



<p>Black spots before the eyes (floaters)</p>	<ul style="list-style-type: none"> ❖ Eye hard to palpation. ❖ Pupil fixed and dilated. ❖ Head and eye pain. ❖ Loss of visual acuity. ❖ Nausea, possibly with vomiting. 	<p>Glaucoma attack.</p>	<p>! Risk of blindness.</p> <ul style="list-style-type: none"> ❖ Measure intraocular pressure immediately.
	<ul style="list-style-type: none"> ❖ Spontaneous (normal history). ❖ Secondary to exercise (such as lifting heavy objects, pressing, defecation of hard stool) and coughing or sneezing. ❖ Secondary to trauma or surgery. ❖ Due to arteriosclerosis (may be recurrent in older patients). ❖ With impaired coagulation (hemophilia or medication such as coumarin derivatives). 	<p>Subconjunctival hemorrhage.</p>	<p>Diagnosis is unequivocal where confirmed by patient's history.</p>
<p>Black spots before the eyes (floaters)</p>	<ul style="list-style-type: none"> ❖ Usually no other ocular symptoms. ❖ Decreased visual acuity only in severe cases. 	<p>Vitreous opacification.</p>	<p>Unequivocal diagnosis.</p>
	<ul style="list-style-type: none"> ❖ Patients are often older. ❖ Patient perceives veils and curtains in the eye, even in the dark. ❖ Floaters move with the eye. ❖ Flashes of light. 	<p>Posterior vitreous detachment.</p>	<ul style="list-style-type: none"> ❖ Isolated findings are harmless. ❖ Examine fundus to exclude retinal defects.
	<p>Inflammatory debris in the vitreous body.</p>	<p>Posterior uveitis.</p>	<p>Examine fundus.</p>



Cardinal symptoms	Possible associated symptoms and findings	Tentative diagnosis (probable underlying clinical picture)	Further diagnostic work-up
Decreased visual acuity  Fundus examination is indicated where visual acuity is decreased.	<ul style="list-style-type: none">❖ Lasts a few seconds.❖ Darkening that may include amaurosis.	Amaurosis fugax (such as in ipsilateral stenosis in the internal carotid artery).	No abnormal ocular findings.
Transient (visual acuity improves with 24 hours, usually within one hour)	<ul style="list-style-type: none">❖ Poor general health.❖ Visual acuity improves with improvement in general health.❖ Visual field defects.❖ Scintillating scotoma for 10–20 minutes.❖ Vertigo and vomiting.	Circulatory failure. Ocular migraine.	No abnormal ocular findings. Unequivocal diagnosis.
Transient	<ul style="list-style-type: none">❖ Blurred vision.❖ General feeling of fatigue.	Hypoglycemia.	 Risk of blindness. <ul style="list-style-type: none">❖ Administer glucose. Diagnosis is unequivocal where visual acuity returns to normal as the level of blood glucose increases.
Persisting longer than 24 hours, sudden onset, painless.	<ul style="list-style-type: none">❖ Unilateral loss of visual acuity.❖ Headache is possible.	<ul style="list-style-type: none">❖ AION: anterior ischemic optic neuropathy.	<ul style="list-style-type: none">❖ Determine erythrocyte sedimentation rate and level of C-reactive protein (precipitous drops occur in temporal arteritis).



<ul style="list-style-type: none"> ❖ Mobile shadows before the eyes. ❖ Allow to clear by immobilizing the eyes so that blood will settle. 	Vitreous hemorrhage.	Examine fundus. Diagnosis is unequivocal where fundus is obscured.
<ul style="list-style-type: none"> ❖ Severe loss of visual acuity. ❖ Flashes of light. 	Retinal detachment.	<ul style="list-style-type: none"> ❖ Risk of blindness. ❖ Ophthalmoscopy (clearly visible retinal detachment).
<ul style="list-style-type: none"> ❖ Pain from posterior swelling and with eye motion. ❖ Increasing loss of visual acuity following exercise. ❖ Central scotoma. ❖ Normal findings upon ophthalmoscopy (patient sees nothing; examiner sees nothing). 	Retrolbulbar optic neuritis.	Neurologic examination.
<p>Intraretinal linear hemorrhages:</p> <ul style="list-style-type: none"> ❖ In one quadrant ❖ In two quadrants ❖ In four quadrants 	<ul style="list-style-type: none"> ❖ Branch retinal vein occlusion. ❖ Hemispherical occlusion. ❖ Central retinal vein occlusion. 	<ul style="list-style-type: none"> ❖ Ophthalmoscopy (linear hemorrhages). ❖ Fluorescein angiography to differentiate ischemic from non-ischemic type.
<ul style="list-style-type: none"> ❖ Segmental or total visual field defects. ❖ Sudden unilateral blindness. 	Central retinal artery occlusion.	Ophthalmoscopy: whitish retinal edema, visible "cherry red spot" (macula).



Cardinal symptoms	Possible associated symptoms and findings	Tentative diagnosis (probable underlying clinical picture)	Further diagnostic work-up
Decreased visual acuity Persisting longer than 24 hours, sudden onset, painless.	<ul style="list-style-type: none"> ❖ Patient is usually over 60. ❖ Unilateral decrease in visual acuity. ❖ Headaches. ❖ Temporal artery is tender to palpation. ❖ Cervical myalgia. ❖ Pain when chewing. ❖ Weight loss. 	<ul style="list-style-type: none"> ❖ AION: anterior ischemic optic neuropathy due to arthritis in giant cell arthritis or temporal arteritis. 	<p>! Risk of blindness.</p> <ul style="list-style-type: none"> ❖ Arterial biopsy and histologic examination are indicated. ❖ Circular or segmental swelling of the optic disk will be visible upon ophthalmoscopy. ❖ Determine erythrocyte sedimentation rate and level of C-reactive protein (heightened levels in temporal arteritis). ❖ Unequivocal diagnosis.
Slowly increasing over a period of weeks, months, or years; painless:	<ul style="list-style-type: none"> ❖ Gray to white pupillary reflex. ❖ Loss of contrast. ❖ Increased glare. ❖ Corneal opacification. ❖ Corneal scarring. 	<p>Cataract.</p> <p>Chronic corneal degeneration, keratopathy.</p>	<p>Slit-lamp examination. Diagnosis is unequivocal where the opacity is visible under retroillumination.</p> <ul style="list-style-type: none"> ❖ Unequivocal diagnosis. ❖ Slit-lamp examination will reveal corneal degeneration and scarring.
Slow, painless:	<ul style="list-style-type: none"> ❖ Central visual field defect. ❖ Patient is usually over 65. ❖ Blurred vision, micropsia, and macropsia may be present. ❖ Increased intraocular pressure. ❖ Visual field defects 	<p>Age-related macular degeneration.</p> <p>Primary chronic open angle glaucoma.</p>	<p>Fluorescein angiography.</p> <p>! Risk of blindness.</p> <ul style="list-style-type: none"> ❖ Measure intraocular pressure.



	<p>Decreased visual acuity is typically more severe in the morning than in the evening.</p> <p>Specifically decreased visual acuity in near or distance vision.</p>	<p>Fuchs' endothelial dystrophy.</p> <ul style="list-style-type: none"> ❖ Myopia. ❖ Hyperopia. 	<ul style="list-style-type: none"> ❖ Slit-lamp examination. <p>Test visual acuity.</p>
<p>Painful, acute:</p>	<p>Whitish corneal opacification.</p> <ul style="list-style-type: none"> ❖ Red eye, hard to palpation. ❖ Pupil fixed and dilated. ❖ Nausea, possible with vomiting. ❖ Central scotoma. ❖ Increasing loss of visual acuity following exercise; pain from posterior swelling and with eye motion. ❖ Normal findings upon ophthalmoscopy (patient sees nothing; examiner sees nothing). 	<p>Acute keratoconus.</p> <p>Glaucoma attack.</p> <p>Retrobulbar optic neuritis.</p>	<p>Typical conical projection of the cornea is visible under slit-lamp examination.</p> <ul style="list-style-type: none"> ❗ Risk of blindness. ❖ Measure intraocular pressure immediately. <p>Neurologic examination.</p>
	<ul style="list-style-type: none"> ❖ Combined injection. ❖ Eye pain. ❖ Fibrin and cells in the anterior chamber. ❖ Vitreous infiltration. ❖ Anterior and posterior synechiae. 	<p>Uveitis.</p>	<p>Slit-lamp examination.</p>



Cardinal symptoms	Possible associated symptoms and findings	Tentative diagnosis (probable underlying clinical picture)	Further diagnostic work-up
<p>White pupillary reflex (leukocoria) in children</p> <p>Often first noticed in photos</p> <p> Retinoblastoma (whitish vitreous, retinal, or subretinal tumor) should be excluded in leukocoria.</p>	<p>Unilateral or bilateral.</p> <ul style="list-style-type: none"> ❖ Up to 90% of patients are male among children and teenagers. ❖ Unilateral leukocoria (occasionally combined with strabismus). ❖ Exudative retinal detachment visible upon ophthalmoscopy. 	<p>Cataract.</p> <p>Coats' disease.</p>	<p>Slit-lamp examination. Diagnosis is unequivocal where lens opacity is visible under retroillumination.</p> <p>Unequivocal diagnosis.</p>
<p>Retinal detachment visible upon ophthalmoscopy.</p> <ul style="list-style-type: none"> ❖ Usually unilateral. ❖ Congenital (leukocoria manifests itself at birth). ❖ Microphthalmos is usually present. 	<p>Retinal detachment visible upon ophthalmoscopy.</p> <ul style="list-style-type: none"> ❖ Usually unilateral. ❖ Congenital (leukocoria manifests itself at birth). ❖ Microphthalmos is usually present. 	<p>Retinal detachment, for example in retinopathy of prematurity.</p> <p>PHPV (persistent hyperplastic primary vitreous).</p>	<p>Unequivocal diagnosis.</p> <p>Ultrasound scan.</p>
<ul style="list-style-type: none"> ❖ Usually unilateral (two-thirds of all cases). ❖ May be accompanied by red eye. ❖ Child is usually below the age of three. ❖ Globe is normal size. 	<p>Retinoblastoma (whitish vitreous, retinal, or subretinal tumor).</p>	<p>Retinoblastoma also in fellow eye to exclude a bilateral retinoblastoma.</p> <ul style="list-style-type: none"> ❖ CT scan. 	<p>❖ Ophthalmoscopy also in fellow eye to exclude a bilateral retinoblastoma.</p> <ul style="list-style-type: none"> ❖ CT scan.



Blurred or distorted vision	Especially when fixating close or remote objects.	Refraction anomaly (myopia or hyperopia).	Refraction testing.
	❖ Older patients (65 and older). ❖ Gradual progressive loss of visual acuity.	Age-related macular degeneration.	Ophthalmoscopy.
	❖ Patient under emotional or physical stress. ❖ Men in their thirties and forties are most commonly affected. ❖ Objects appear enlarged or reduced in size. ❖ Central relative visual field defects (patients see a dark spot).	Central serous chorioretinopathy.	Ophthalmoscopy.
	Headaches, possibly with nausea. Scintillating scotoma.	Ocular migraine.	Unequivocal diagnosis.
	❖ Permanent or worsening. ❖ Possibly with diplopia. ❖ Increased glare. ❖ Gray to white pupillary reflex.	Cataract.	Slit-lamp examination will reveal obvious lens opacity where a cataract is present.
	Narrowed or dilated pupil.	Following administration of eye-drops (miotics or mydriatics).	Unequivocal diagnosis.
	❖ Fundus reflex absent or weak. ❖ Patient sees shadows (a “wall” from below or a “curtain” from above).	Retinal detachment.	❖ Neurologic examination. ❖ CT scan.



Cardinal symptoms	Possible associated symptoms and findings	Tentative diagnosis (probable underlying clinical picture)	Further diagnostic work-up
Blurred or distorted vision	<ul style="list-style-type: none">❖ Headache.❖ Visual field defect.❖ Diplopia.❖ Ophthalmoplegia.❖ Prominent, edematous optic disk.	Cerebral cause (tumor or increased intracranial pressure).	

Appendix 1 Topical ophthalmic preparations

Pharmaceutical	Indications	Ocular effects and side effects	Systemic side effects
Acyclovir	<ul style="list-style-type: none"> ❖ Herpes simplex keratitis. ❖ Herpes zoster ophthalmicus. 	Local irritation, keratitis, allergic reaction in eyelids and conjunctiva.	No known systemic effects from topical use.
Atropine	<ul style="list-style-type: none"> ❖ Cycloplegia. ❖ Uveitis. 	Mydriasis, angle closure glaucoma, cycloplegia, decreased visual acuity, increased intraocular pressure.	Confusion, tachycardia, dry mouth.
Beta blockers (timolol)	Glaucoma therapy.	Decreased intraocular pressure, decreased visual acuity, dry eye.	Bronchoconstriction, bradycardia.
Carbachol	Glaucoma therapy.	Decreased intraocular pressure, miosis, accommodation spasm, decreased visual acuity.	Fever, syncope, nausea.
Clonidine	Glaucoma therapy.	Decreased intraocular pressure, decreased blood supply to the head of the optic nerve.	Decreased blood pressure.
Cyclopentolate	<ul style="list-style-type: none"> ❖ Mydriatic. ❖ Cycloplegic. 	Mydriasis, angle closure glaucoma, decreased visual acuity, increased intraocular pressure.	Central nervous system dysfunction, tachycardia, dry mouth, nausea.
Chloramphenicol	Severe ocular bacterial infections.	Local irritation, keratitis, allergic reaction in eyelids and conjunctiva, keratitis.	Aplastic anemia (rare).

Continued →

Appendix 1 (Continued)

Pharmaceutical	Indications	Ocular effects and side effects	Systemic side effects
Dorzolamide (local carbonic anhydrase inhibitor)	<ul style="list-style-type: none"> ❖ Glaucoma therapy. ❖ Prophylaxis against increased intraocular pressure following laser surgery. 	Local allergic reaction in eyelids and conjunctiva.	Malaise, depression, metallic taste.
Dipivefrin	<ul style="list-style-type: none"> ❖ Glaucoma therapy. 	Decreased intraocular pressure, local irritation and allergic reaction in eyelids and conjunctiva, mydriasis, angle closure glaucoma.	Tachycardia, cardiac arrhythmia, increased blood pressure, headaches.
Epinephrine	Glaucoma therapy.	Decreased intraocular pressure, cystoid macular edema.	Headaches, perspiration, syncope.
Echothiophate	Glaucoma therapy.	Decreased intraocular pressure, miosis, decreased visual acuity, accommodation spasm.	Nausea, dyspnea, bradycardia.
Gentamicin	Ocular bacterial infections, especially <i>Pseudomonas aeruginosa</i> , <i>Escherichia coli</i> , <i>Proteus</i> species, <i>Klebsiella pneumoniae</i> .	Local irritation and allergic reaction in eyelids and conjunctiva, keratitis; intravitreal administration may cause retinal damage and atrophy of the optic nerve.	No known systemic effects from topical use.
Glucocorticoids	Anti-inflammatory therapy.	Increased intraocular pressure, posterior subcapsular cataract.	Decreased plasma cortisol levels.

Guanethidine	Glaucoma therapy.	Decreased intraocular pressure, local irritation, miosis, ptosis, decreased visual acuity.	No known systemic effects from topical use.
Idoxuridine, trifluridine, vidarabine	Herpes simplex keratitis	Local irritation, corneal damage, ptosis, and obstruction of the punctum lacrimale.	No known systemic effects from topical use.
Naphazoline	Symptomatic treatment of allergic or inflammatory reactions.	Conjunctival vasoconstriction, local irritation, mydriasis, angle closure glaucoma, keratitis.	Rare: headaches, increased blood pressure, nausea, cardiac arrhythmia.
Neostigmine	Glaucoma therapy.	Decreased intraocular pressure, local irritation, miosis, accommodation spasm, decreased visual acuity.	No known systemic effects from topical use.
Penicillin	Ocular bacterial infections.	Local irritations, allergic reactions in eyelids and conjunctiva.	No known systemic effects from topical use.
Phenylephrine	<ul style="list-style-type: none"> ❖ Mydriatic. ❖ Vasoconstrictor. 	Mydriasis, angle closure glaucoma, vasoconstriction.	Increased blood pressure, myocardial infarction, tachycardia.
Pilocarpine	Glaucoma therapy.	Decreased intraocular pressure, miosis, accommodation spasm, decreased visual acuity, retinal tears (rare).	Headaches, nausea, bradycardia, decreased blood pressure, bronchospasm.
Rifampicin	Ocular infections with <i>Chlamydia</i> .	Conjunctival hyperemia, pain, tearing.	No known systemic effects from topical use.

Continued →

Appendix 1 (Continued)

Pharmaceutical	Indications	Ocular effects and side effects	Systemic side effects
Scopolamine	<ul style="list-style-type: none"> ❖ Therapeutic mydriasis. ❖ Uveitis. 	Decreased visual acuity, mydriasis, angle closure glaucoma, cycloplegia, increased intraocular pressure.	Confusion, hallucinations.
Sulfonamide	Ocular bacterial infections.	Local irritation, allergic reaction, keratitis.	No known systemic effects from topical use.
Tetracycline	Ocular bacterial infections (including <i>Mycoplasma</i> strains).	Unspecific conjunctivitis, allergic reactions.	No known systemic effects from topical use.

Appendix 2 Non-ophthalmic preparations with ocular side effects

Systemic cardiovascular preparations	Indications	Ocular effects and side effects	Systemic side effects
Atropine	<ul style="list-style-type: none"> ❖ Bradycardic arrhythmia. ❖ Gastrointestinal spasms. 	Decreased visual acuity, mydriasis, angle closure glaucoma, visual hallucinations.	Tachycardia, agitation, confusion.
Amiodarone	<ul style="list-style-type: none"> ❖ Ventricular arrhythmias that do not respond to treatment. 	Yellowish brown deposits in the cornea, conjunctiva, and lens.	Thyroid dysfunction, pulmonary fibrosis, photosensitivity.
Beta blockers	<ul style="list-style-type: none"> ❖ Arterial hypertension. ❖ Coronary heart disease. ❖ Cardiac insufficiency (in low doses). 	Decreased visual acuity, visual hallucinations, decreased intraocular pressure, dry eye.	Decreased blood pressure, bradycardia, dyspnea, stupor.
Clonidine	Arterial hypertension.	Decreased intraocular pressure, decreased visual acuity, allergic reaction in eyelids and conjunctiva.	Sedation, bradycardia, dry mouth, depressive moods.
Digitalis glycosides (digoxin, digitoxin, acetyldigoxin)	<ul style="list-style-type: none"> ❖ Cardiac insufficiency. ❖ Cardiac arrhythmia. 	Color vision defects (xanthopsia).	Nausea, bradycardia.
Guanethidine	Arterial hypertension.	Decreased visual acuity, irritation, miosis, ptosis, diplopia, decreased intraocular pressure.	Orthostatic circulatory symptoms, diarrhea.

Continued →

Appendix 2 (Continued)

Systemic CNS preparations	Indications	Ocular effects and side effects	Systemic side effects
Amphetamines	<ul style="list-style-type: none"> ❖ Narcolepsy. ❖ Appetite suppression. ❖ Hyperkinetic child syndrome (pediatrics). 	Decreased visual acuity, mydriasis, angle closure glaucoma, enlarged palpebral fissures, visual hallucinations.	Agitated and restless states, tachycardia, insomnia.
Barbiturates	<ul style="list-style-type: none"> ❖ Epilepsy. ❖ Anesthesia. ❖ Tranquilizers and sedatives. 	Ocular motility disturbances (depressed convergence response, ophthalmoplegia, nystagmus), ptosis, and blepharoclonus from chronic use.	Decreased blood pressure, suppression of REM sleep phases, respiratory depression, hyperalgesia.
Benzodiazepines (alprazolam, diazepam, clonazepam, midazolam)	<ul style="list-style-type: none"> ❖ Anxiety and agitated states. ❖ Epilepsy. ❖ Insomnia. 	Suppression of corneal reflex, depressed accommodation and depth perception, ocular motility disturbances, allergic conjunctivitis.	Respiratory depression, fatigue, development of tolerance.
Chloral hydrate	Sedative.	Miosis, ptosis, depressed convergence response.	Irritation of mucous membranes, liver toxicity.
Chlorpromazine, thioridazine, perphenazine (group of phenothiazine neuroleptics)	<ul style="list-style-type: none"> ❖ Schizophrenia. ❖ Psychomotor agitation. ❖ Manias. ❖ Chronic pain syndromes. 	Decreased visual acuity, pigment deposits on the surface of the lens and cornea, changes in the retinal pigment epithelium (especially with thioridazine).	Parkinson's disease, early dyskinesia and tardive dyskinesia, liver damage.

Carbamazepine	<ul style="list-style-type: none"> ❖ Epilepsy. ❖ Neuralgia (trigeminal neuralgia). 	Diplopia, blurred vision, sensation of heaviness in the eyelids.	Fatigue, ataxia, blood count changes.
L-dopa	Parkinson's disease.	Mydriasis (angle closure glaucoma), eyelid retraction, ptosis.	Orthostatic circulatory symptoms, nausea, dyskinesia, psychosis.
Haloperidol (group of butyrophenone neuroleptics)	<ul style="list-style-type: none"> ❖ Schizophrenia. ❖ Psychomotor agitation. ❖ Manias. ❖ Chronic pain syndromes. 	Mydriasis, decreased visual acuity.	Parkinson's disease, early dyskinesia and tardive dyskinesia, liver damage.
Lithium	<ul style="list-style-type: none"> ❖ Manic phases. ❖ Prophylaxis against endogenous depression. 	Decreased visual acuity, nystagmus, exophthalmos (due to thyroid dysfunction).	Goiter, ataxia, diarrhea, tremor.
Morphine	Severe pain.	Miosis, decreased visual acuity, decreased accommodation and convergence reaction. During withdrawal: mydriasis, tearing, and diplopia.	Respiratory depression, bronchoconstriction, constipation, euphoria (addictive).
Phenytoin	Epilepsy.	Nystagmus, decreased visual acuity, mydriasis.	Hypertrichosis, gingival hyperplasia, cerebral ataxia, osteopathy.
Tricyclic antidepressants (amitriptyline, desipramine, imipramine)	Depression.	Mydriasis, angle closure glaucoma, cycloplegia, dry eyes, diplopia.	Tachycardia, constipation, micturition difficulties.

Continued →

Appendix 2 (Continued)

Systemic medications for treating infection	Indications	Ocular effects and side effects	Systemic side effects
Chloramphenicol	Severe bacterial infections such as abdominal typhus, <i>Haemophilus influenzae</i> meningitis.	Decreased visual acuity, visual field changes (scotomas or limitation), optic neuritis or retrobulbar optic neuritis, local allergic reactions.	Aplastic anemia, gastrointestinal dysfunction, fever, gray syndrome.
Chloroquine and hydroxychloroquine	<ul style="list-style-type: none"> ❖ Malaria. ❖ Amebiasis. 	Deposits on the cornea, changes in the retinal pigment epithelium (bull's eye maculopathy), visual field changes.	Nausea, headache, bleaching of the hair, blood count changes.
Quinine	Malaria infection.	Decreased visual acuity including toxic amblyopia, mydriasis, retinal damage (edema or vascular constriction), optic disk edema, scotomas.	Hemolytic anemia, allergic reactions, hearing loss.
Ethambutol	Tuberculosis.	Optic neuritis, visual field changes, color vision defects.	Hyperuricemia, nausea.
Isoniazid	Tuberculosis.	Optic neuritis, atrophy of the optic nerve, visual field changes, optic disk edema, color vision defects.	Polyneuropathy (vitamin B6 metabolic dysfunction), allergic reactions, liver damage.
Penicillin	Bacterial infections.	Mydriasis, depressed accommodation, diplopia, optic disk edema with cerebral pseudotumor (secondary).	Nausea, allergic reactions.

Rifampicin	Tuberculosis.	Conjunctival hyperemia, blepharocconjunctivitis, color change (orange) of fluid is possible.	Liver dysfunction, nausea, allergic reactions, hepatic enzyme induction.
Streptomycin	Tuberculosis.	Nystagmus, decreased visual acuity, toxic amblyopia, color vision defect, atrophy of the optic nerve.	Ototoxicity, nephrotoxicity, allergy.
Sulfonamides	Bacterial infections.	Myopia, unspecific irritation.	Allergic reactions, nausea, photosensitivity.
Tetracycline	Bacterial infections.	Myopia, optic disk edema with cerebral pseudotumor, decreased visual acuity, diplopia.	Nausea, allergic reactions, liver damage.
Systemic medications for treating rheumatic disorders	Indications	Ocular effects and side effects	Systemic side effects
Chloroquine and hydroxychloroquine	Base medication in rheumatoid arthritis.	Deposits on the cornea, changes in the retinal pigment epithelium (bull's eye maculopathy), visual field changes.	Nausea, headache, bleaching of the hair, blood count changes.
Gold salts	Base medication in rheumatoid arthritis.	Deposits on the eyelids, conjunctiva, cornea (chrysiasis), and lens (rare). Ptosis, nystagmus, and diplopia are rare.	Blood count changes, nephrotoxicity, mucous membrane damage.

Continued →

Appendix 2 (Continued)

Systemic medications for treating rheumatic disorders	Indications	Ocular effects and side effects	Systemic side effects
Ibuprofen	<ul style="list-style-type: none"> ❖ Rheumatoid arthritis. ❖ Inflammation in degenerative joint disease. 	Blurred vision, diplopia, color vision defects, dry eyes, optic neuritis (rare).	Damage to gastrointestinal mucous membranes.
Indomethacin	<ul style="list-style-type: none"> ❖ Rheumatoid arthritis. ❖ Inflammation in degenerative joint disease. 	Decreased visual acuity, diplopia, color vision defects, corneal deposits.	Damage to gastrointestinal mucous membranes, headaches.
Acetylsalicylic acid and salicylic acid	<ul style="list-style-type: none"> ❖ Fever, pain. ❖ Rheumatoid arthritis. ❖ Thrombocyte aggregation inhibitor. 	Allergies, conjunctivitis, decreased visual acuity, transient blindness.	Microscopic gastrointestinal bleeding, allergies, bronchospasm, ototoxic side effects.
Hormone preparations	Indications	Ocular effects and side effects	Systemic side effects
Glucocorticoids	<ul style="list-style-type: none"> ❖ Anaphylactic shock, immunosuppressive therapy (such as in ulcerous colitis or immunohemolytic anemia). ❖ Bronchial asthma. ❖ Acute rheumatic fever. 	Decreased visual acuity, increased intraocular pressure, posterior subcapsular cataract.	Increased blood glucose levels, Cushing's syndrome, osteoporosis, increased risk of thrombosis, increased susceptibility to infection.

Oral contraceptives	<ul style="list-style-type: none"> ❖ Contraception. ❖ Regulation of menstrual cycle. 	Decreased visual acuity, retinal vascular changes (occlusion, bleeding, spasm), retinal edema, visual field changes, optic neuritis.	Varicosis, migraine, edemas.
Other important medications with ocular side effects			
Coumarin derivatives (phenprocoumon, warfarin)	Thinning of blood as prophylaxis against and treatment of venous thrombosis.	Subconjunctival or retinal bleeding, hyphema.	Loss of hair, nausea, cerebral bleeding, spontaneous hematomas.
Vitamin A	<ul style="list-style-type: none"> ❖ Vitamin A deficiency. ❖ Acne vulgaris. 	Loss of eyelashes, increased intracranial pressure (cerebral pseudotumor), diplopia, strabismus.	Severe headaches, loss of hair, nausea, pruritus, rhagades, bone and joint pain.
Vitamin D	<ul style="list-style-type: none"> ❖ Vitamin D deficiency. ❖ Hypoparathyroidism. 	Strabismus, calcium deposits in the conjunctiva and cornea (calcific band keratopathy), atrophy of the optic nerve due to calcium occlusion of the optic canal.	Calcification of parenchymal organs such as the kidneys.
Nicotinic acid	Fat metabolism disorders.	Cystoid maculopathy, decreased visual acuity, local allergic reactions.	Flush symptoms, restlessness, nausea, vomiting, diarrhea.

Appendix 3 Ocular symptoms of poisoning

Toxic substance	Ocular effects and side effects	Systemic side effects
Atropine	Mydriasis, decreased visual acuity, angle closure glaucoma, cycloplegia, increased intraocular pressure.	Dry mouth, dry skin, confusion, tachycardia, hyperthermia.
Lead	Increased intraocular pressure.	Fatigue, headache and pain in the extremities, pallor, colic, paralysis, lead halo on the gums.
Quinine	Decreased visual acuity, retinal vascular spasms, atrophy of the optic nerve including blindness.	Allergic reactions, hemolytic anemia, vertigo, tinnitus, cyanosis, cardiac death.
Digitalis	Scintillation, patient sees clouds, color vision defects.	Cardiac arrhythmia, (AV conduction blocks, bigeminy), nausea, vomiting, headaches, confusion.
Ethanol	Transient amblyopia, decreased intraocular pressure, nystagmus, diplopia, conjunctival hyperemia.	Disturbed gait, disorientation including impaired consciousness, cramps, tachycardia.
Methyl alcohol	Atrophy of the optic nerve including blindness.	Nausea, colic, acidosis, oliguria.

Index

- A**
- A pattern deviation 469, 471
 A-mode scan 409
 abducent nerve
 lesions 482
 palsy 486, 490–491
 retraction syndrome 490–491
 aberrations 456–458
 astigmatic aberration 457, 458
 chromatic aberration 456
 curvature of field 456, 458
 spherical aberration 456–457
 abscess
 eyelid 36–37, 64, 538
 lacrimal sac 57, 58
 vitreous body 291
 absolute glaucoma 236
 absorption lenses 450
Acanthamoeba keratitis 136–137, 455
 accommodation 425–428
 impairments 445–447
 palsy 446–447
 spasm 445–446
 range of 427–428
 accommodative convergence/accommodation 470–471
 accommodative esotropia 470
 accommodometer 445
 aceclidine
 effects on pupil 224
 glaucoma treatment 256
 acetazolamide, glaucoma treatment 260
 acetylcholine, effects on pupil 224
 acetyldigoxin 555
 acetylsalicylic acid 560
 aciclovir 551
 acid burns 518
 acidic mucopolysaccharide deposits 148, 150
 acquired
 nuclear cataract 173, 174, 176
 ptosis 22–24
 strabismus 469
 acquired immune deficiency syndrome (AIDS) 113
 related retinal disorders 349–350
 acute
 conjunctivitis 74, 98, 100
 dacryoadenitis 64
 dacryocystitis 57–58
 glaucoma 265–270
 iritidocyclitis 208–212
 iritis 208–212
 retinal necrosis syndrome 133
 adaptation 303, 428
 sensory adaptation 466
 adenocarcinoma
 eyelids 47
 lacrimal gland 66
 adenoma
 lacrimal gland 66
 pituitary gland 396, 397
 Adie's tonic pupil syndrome 228
 adrenochrome deposits 111, 114
 against-the-rule astigmatism 441
 age-related macular degeneration 337–338, 546, 549
 aging
 accommodation changes 428
 conjunctiva 69–74
 fundus 310
 lens 168
 optic disk 310
 retinal degenerative disorders *see* retina
 vitreous body 282–284
 AIDS *see* acquired immune deficiency syndrome
 albinism 201, 206–207, 531
 iris print lenses and 454
 alexia 401
 alkali burns 518
 alkaptonuria *see* ochronosis
 allergic conjunctivitis 76–78, 82, 98–99, 101–102
 allograft rejection 152–153, 154
 Alport's syndrome 169
 alprazolam 556
 alternating
 esotropia 468
 strabismus 73
 amaurosis fugax 544
 amaurotic cat's eye 354
 amblyopia
 anisometropic 444
 congenital cataract and 193, 195
 congenital ptosis and 23, 24
 forms of 467
 strabismus and 469

- amblyopia
 strabismus and
 amblyopia secondary to suppression 466–467
 infantile strabismic amblyopia 472–473, 477–479
- ametropia 424, 451
- amiodarone 555
- amitriptyline 557
- amphetamines 556
- amyloid deposits 148
 vitreous body 287
- anesthesia, in cataract surgery 187
- aneurysm, internal carotid artery 398, 399
- angiography 201, 202, 409
 fundus 307–308
- angiomatosis retinae 356
- angle closure glaucoma *see* glaucoma
- angle of deviation
 incomitant 481, 488–490
 measurement of 474–476, 492–493
 primary 490
 secondary 490
- angular artery 404
- angular vein 405
- aniridia 202–203, 531, 533
 iris print lenses and 454
 traumatic 510
- aniseikonia 187, 444, 465–466
- anisocoria 226
 simple 229
 with constricted pupil in the affected eye 229–230
 with dilated pupil in the affected eye 228–229
 complete oculomotor palsy 228
 iris defects 229
 tonic pupil 228
- anisometropia 444–445, 451, 465
 contact lens correction 444, 445
- ankyloblepharon 22
- anterior chamber
 chronic inflammation 146
- depth of 11–12, 238
- examination of 11–12
- gonioscopy 238–240, 275
- oblique illumination 238
- slit-lamp examination 238
- anterior ischemic optic neuropathy (AION) 374–379, 536, 544, 546
- arteriosclerotic 374–378
- arteritic 378–379
- aperture 428
- aphakia 438, 440
 postoperative 187, 438
 unilateral 445
- applanation tonometry 240, 242, 275, 435
- apraclonidine, glaucoma treatment 258
- aqueous humor 167
 circulation 233–235
- arc of Wilbrand 389, 398
- arcus senilis 145
- Arden ratio 313
- argon laser trabeculoplasty 261–262
- Argyll-Robertson pupil 230–231
- argyrosis 114, 146
- Arlt's triangle 208
- arterial pulse 13
- arteriosclerotic changes 323–325
 anterior ischemic optic neuropathy (AION) 374–378, 536, 544, 546
- arteriovenous fistula 409
- arteritic anterior ischemic optic neuropathy (AION) 378–379
- artery
 angular 404
 ciliary 157, 199, 361
 hyaloid, persistent 285, 366
 internal carotid 396, 404
 aneurysm 398, 399
 stenosis 404
 ophthalmic 199, 404
 retinal 302
- central 302, 361
 occlusion 320–323, 545
- supraorbital 404
- supratrochlear 404
- aspergillomycosis 417
- asteroid hyalosis 287
- asthenopic symptoms 438, 537
- astigmatic aberration 457, 458
- astigmatism 5, 121, 433, 440–444, 457
 against-the-rule 441
 correction 442–444
 contact lenses 453
 photorefractive keratectomy 156
 external 441, 444
 internal 441, 444
 irregular 441–442, 444
 oblique 441
 regular 441, 442
 total 440
 with-the-rule 441
- astrocytoma
 optic nerve 385–386
 retina 355–356
- atrophy 534
 infantile recessive optic atrophy 383
 Leber's 382–383
 optic nerve 380–383, 399, 407
 waxy pallor optic atrophy 383
- atropine 551, 555, 562
 effects on pupil 225
- automated refractometry 431
- avulsion
 globe 512
 optic nerve 512
- axial
 hyperopia 438
 myopia 434

B

- B-mode scan 408
- bacterial
 conjunctivitis 60, 76–78, 81–87

- keratitis 130–132
 - Bagolini test 476–477
 - barbiturates 556
 - Barkan's membrane 273
 - barrel distortion 457
 - basal cell carcinoma 45–47
 - Behr's disease 383
 - Bell's phenomenon 17
 - benzodiazepines 556
 - Bergmeister's papilla 366
 - Berlin's edema 511
 - Best's vitelliform dystrophy 313, 341–342
 - beta blockers 551, 555
 - glaucoma treatment 259
 - betaxolol, glaucoma treatment 259
 - bicanicular ring intubation 502–503
 - Bielschowsky head tilt test 488, 489, 492
 - bifocal lenses
 - contact lenses 454
 - eyeglasses 447
 - accommodative esotropia correction 470
 - bilateral afferent pupillary defect 227
 - binocular
 - alignment 6
 - loupes 456
 - testing 451
 - vision 461–465, 466, 469
 - fusion 464
 - simultaneous vision 461–464
 - stereoscopic vision 465
 - testing of 476–477
 - birthmarks, conjunctival 108
 - Bitot's spots 73
 - black cataract 173
 - bleeding see hemorrhage
 - blepharitis 528
 - in herpes zoster ophthalmicus 35
 - seborrhoeic 33–34
 - blepharochalasis 19, 539, 540
 - blepharophimosis 21, 23
 - blepharospasm 10, 30
 - entropion and 26, 27
 - with conjunctivitis 74
 - blind spot 360
 - blinders phenomenon 399
 - blinking 17
 - blow-out fracture 507–513, 532, 534, 539, 540
 - blurred vision 549–550
 - bony socket 403
 - blow-out fracture 507–513, 532, 534, 539, 540
 - botulism, accommodation palsy in 446
 - Bourneville's disease 355, 386
 - Bowman's layer of the cornea 70, 117
 - calcific deposits 146–147
 - brachytherapy 217
 - branch retinal vein occlusion 319, 545
 - bridge coloboma 203
 - brimonidine, glaucoma treatment 258
 - Brodmann's area 17: 389
 - Bruch's membrane 201, 339
 - Brückner's test 168–169
 - brunescient nuclear cataract 173
 - Budge's center 220
 - bulbar conjunctiva 67, 68
 - bullous keratopathy 143–144, 148
 - buphthalmos 124, 127, 273, 285, 531
 - Burkitt's lymphoma 421
 - burns 523–524
 - chemical burns 518
- C**
- calcareous infiltration 72
 - calcific band keratopathy 146–147, 212
 - canal of Schlemm 157, 234
 - canalicular stenosis 53
 - canaliculitis 61
 - conjunctivitis in 82
 - Candida albicans* keratitis 134–135
 - capsulorrhexis 189
 - carbachol 551
 - effects on pupil 224
 - glaucoma treatment 256
 - carbamazepine 557
 - carbonic anhydrase inhibitors 552
 - glaucoma treatment 255, 260, 268
 - carcinoma
 - basal cell 45–47
 - conjunctival 107
 - lacrimal gland 66
 - lacrimal sac 61
 - squamous cell 47, 107
 - carteolol, glaucoma treatment 259
 - caruncle, lacrimal 67
 - cataract 12, 150, 167, 171–195, 434
 - classification 171–172, 173
 - complicated cataracts 180, 181
 - congenital 182–185, 192–195
 - anterior pyramidal cataract 183
 - cerulean cataract 183
 - coronary cataract 183
 - from transplacental infection 185
 - lamellar/zonular cataract 183, 184
 - nuclear cataract 183, 184
 - polar cataract 183
 - definition 170
 - examination of 168–169
 - in systemic disease 179–180
 - cataract with myotonic dystrophy 179–180
 - dermatogenic cataract 180, 181
 - diabetic cataract 179
 - dialysis cataract 179
 - galactosemic cataract 179, 185
 - snowflake cataract 179
 - tenary cataract 180
 - medical treatment 185
 - membranous cataract 285
 - secondary cataract 192, 193, 194, 212–213

- cataract
 secondary cataract
 after intraocular surgery 180
 senile 173–179
 cortical cataract 173–176
 cuneiform cataract 176
 hypermature cataract 174, 177–179
 mature cataract 174, 177, 186
 Morgagni's cataract 178
 nuclear cataract 173, 174, 176
 posterior subcapsular cataract 174, 176–177
 surgical treatment 185–195
 anesthesia 187
 duration of hospitalization 186
 in children 192–195
 indications 185–186
 options for achieving refractive correction 187–188
 prognosis 186, 193
 surgical techniques 189–192
 vitreous body and 294
 symptoms 170–171, 531, 533, 542, 546, 548, 549
 in children 192
 toxic cataract 182
 traumatic 180–182, 514
 contusion cataract 180, 182
 electrical injury 182
 infrared radiation cataract 182
 visual acuity testing 431
 cataract eyeglasses 187, 188
 in children 194
 cavernous sinus
 fistula 418
 thrombosis 58, 415–416
 cellulitis, orbital 404, 414–415, 416, 532, 535
 differential diagnosis 58, 64, 415
 treatment 415
 cemented globe 414, 415
- central
 fixation 476
 Horner's syndrome 230
 retinal artery 302, 361
 occlusion 321, 545
 retinal vein 361
 occlusion 319, 545
 scotoma 466
 serous chorioretinopathy 335–336, 549
 cerulean cataract 183
 chalazion 38, 39–40, 47, 539
 check ligaments 460
 chemical injuries 517–522
 treatment 518–521
 chemosis
 in conjunctivitis 76, 78, 79
 in orbital cellulitis 414
 in orbital pseudotumor 416
 chiasm syndrome 399
 children
 cataracts 192–195
 conjunctivitis 93
 contact lens use 194, 195
 glaucoma 236, 273–277, 529
 infantile recessive optic atrophy 383
 leukocoria 548
 optic nerve glioma 422
 orbital cellulitis 414–415
 retinoblastoma 353–355
 rhabdomyosarcoma 421
 strabismus 459, 465–471, 477–479
 infantile strabismic amblyopia 472–473, 477–479
see also neonate
 chlamydial conjunctivitis
see conjunctivitis
 chloral hydrate 556
 chloramphenicol 551, 558
 chloroquine 558, 559
 toxicity 345, 346
 chlorpromazine 556
 cholinergic agents, glaucoma treatment 256
 cholinesterase inhibitors, glaucoma treatment 257
- choristoma 420
 choroid 201
 blunt trauma and 512
 rupture 511
 examination of 202
 tumors 202
 benign 217
 melanoma 216, 217
 vessels 308
see also uveal tract
 choroiditis 208, 209, 213–214
 chromatic aberration 456
 chronic
 anterior chamber inflammation 146
 dacryoadenitis 65
 dacryocystitis 60
 iridocyclitis 212–213
 iritis 212–213
 progressive external ophthalmoplegia (CPEO) 486
 chrysiasis 146
 cicatricial
 ectropion 28, 29, 501
 entropion 27
 ciliary
 arteries 157, 199, 361
 body (muscle) 201, 438
 accommodation mechanism 426–427
 accommodation spasm 445–446
 examination of 202
 melanoma 217
see also uveal tract
 injection 75, 78, 157
 nerves 157, 199
 processes 201
 cilioretinal vessels 361
 circle of least confusion 440
 clonazepam 556
 clonidine 551, 555
 glaucoma treatment 258
 Cloquet's canal 279
 closed-circuit TV magnifier 456
 coated lenses 450
 Coats' disease 325–326, 548
 cobblestone degenerations 334
 cocaine, effects on pupil 226

- coloboma 20–21, 203–205
 bridge coloboma 203
 optic disk 384–385
 rudimentary 364, 384
 surgical 203
 traumatic 203
- color agnosia 401
- color vision evaluation 311–312, 362
- computed tomography (CT), orbital cavity 409
- computerized corneal topography 121, 122–123, 442
- computerized static perimetry 247
- concave lenses 5, 435
see also eyeglass lenses
- concomitant strabismus 459, 465–479
 acquired 469
 causes of 465–466
 diagnosis 471–477
 alternating strabismus 473
 angle of deviation measurement 474–476
 differential diagnosis 493
 infantile strabismic amblyopia 472–473
 ocular alignment evaluation 471–472
 type of fixation 476
 unilateral strabismus 473
 forms of 467
 microstrabismus 469
 therapy 477–479
 eyeglass prescription 477
 strabismic amblyopia 477–479
 surgery 479
 vertical deviations 471
see also esotropia;
 exotropia; strabismus
- cone-rod dystrophy 343, 344
- cones 303
 spacing 423
- confocal corneal microscopy 125, 136
- confrontation field testing 14
- congenital
 cataract *see* cataract
 ectropion 28, 29
 entropion 24, 26, 27
 esotropia 468–469
 melanosis 108, 110, 112–113
 nystagmus 495
 ocular motility disturbances 482
 ptosis 22–24, 540
 toxoplasmosis 348–349
see also children; neonate
- conjunctiva 67–115
 bulbar conjunctiva 67, 68
 degeneration and aging changes 69–74
 calcareous infiltration 72
 conjunctival xerosis 72–74, 148
 pinguecula 69, 70
 pseudopterygium 71
 pterygium 69–71
 subconjunctival hemorrhage 72
 deposits 114–115
 examination of 7–10, 68–69, 80–82
 foreign bodies 503–505
 fornix 67
 function 67
 laceration 499–503
 palpebral conjunctiva 17, 20, 67
 structure of 67, 68
 trauma *see* ocular trauma
 tumors 104–114
 carcinoma 107
 congenital ocular melanosis 110, 112–113
 cysts 105, 106
 epibulbar dermoid 104, 105
 hemangioma 104, 106
 Kaposi's sarcoma 113–114
 lymphoma 113
 melanosis 108–112
- nervus 108, 109
 papilloma 106–107
see also conjunctivitis;
 goblet cells
- conjunctival
 fluorescein dye test 53, 63, 69
 injection 75–78, 157
 smear 80
- conjunctivitis 74–104, 160, 528, 538, 542
 acute 74, 98, 100
 allergic 76–78, 82, 98–99, 101–102
 bacterial 60, 76–78, 81–87
 chlamydial 76–78, 80–81, 83, 88, 92–93
 neonatal 95, 98
 contact lens complications 455
 examination methods 80–82
 conjunctival smear 80
 epithelial smear 80–82
 eyelid eversion 80
 irrigation 82
 giant papillary conjunctivitis 98, 102
 contact lens complications 455
 granulomatous 104
 hordeolum and 38
 inclusion conjunctivitis 60, 88, 92–93
 mycotic 82, 91, 98
 neonatal 95–98
 differential diagnosis 96–97
 nodose 91
 parasitic 90–91, 98
 seborrhic blepharitis and 33
 symptoms and findings 74–79
 toxic 76–78, 97
 vernal 98, 101
 viral 76–79, 81, 89, 93–95
see also keratoconjunctivitis
- consecutive exotropia 471
- consensual light reflex 220

- consensual light reflex
 testing of 221 – 223
 contact eczema, eyelids
 30 – 31
 contact lenses 451 – 455
 advantages of 451
 anisometropia correction
 444, 445
 characteristics of 451 –
 452
 complications 454 – 455
 disadvantages of 454
 following cataract surgery
 187, 188
 in infants 194, 195
 myopia correction 436
 problems with 141 – 142
 rigid contact lenses 452 –
 453
 soft contact lenses 453
 special lenses 453 – 454
 bifocal contact lenses
 454
 corneal shields 453
 iris print lenses 454
 therapeutic contact
 lenses 453
 spherical lenses 453
 toric lenses 453
 contusion 506 – 507
 cataract 180, 182
 rosette 511
 convergent strabismus *see*
 esotropia
 convex lenses 5, 439, 440
 see also eyeglass lenses
 cooked fish eye 521, 522
 copper foreign bodies 515
 cornea 117 – 156
 anatomy 117 – 118
 Bowman's layer 70, 117
 calcific deposits 146 –
 147
 bullous keratopathy 143 –
 144
 contact lens problems
 141 – 142, 454 – 455
 corneal vascularization
 455
 mechanical influences
 454
 metabolic influences
 454
 degeneration 146 – 148,
 546
 calcific band kera-
 topathy 146 – 147
 peripheral furrow ker-
 atitis 147 – 148
 deposits 145 – 146
 arcus senilis 145
 argyrosis 146
 chrysiasis 146
 corneal verticillata 145 –
 146
 iron lines 146
 Kayser-Fleischer ring
 146
 Descemet's membrane
 118, 128
 tears of 126, 275
 developmental anomalies
 125 – 127
 keratoconus 125 – 126
 keratoglobus 127
 size anomalies 127
 dystrophies 148 – 150
 edema 208, 210
 embryology 117
 endothelium 118
 epithelium 117
 density of 121 – 124
 erosion 141, 453, 505 –
 506, 529, 530, 540
 recurring 505
 examination of 10 – 11,
 120 – 125
 confocal corneal
 microscopy 125
 density of epithelium
 121 – 124
 diameter 124
 dye examination 120 –
 121
 in children 275
 pachymetry 125
 sensitivity 121
 slit lamp 120
 topography 121
 foreign bodies 503 – 505,
 529, 530, 540
 importance for eye 117
 mechanical indentation of
 268
 nerve supply 119
 protective mechanisms
 127 – 128
 pterygium 70
 regeneration 117
 sensitivity 10 – 11, 121, 134
 loss of 141
 stroma 117
 tear film significance 119
 transparency 119, 143
 opacification 275
 trauma *see* ocular trauma
 see also keratitis
 cornea plana 127
 corneal shields 453
 corneal surgery 150 – 156
 excimer laser *in situ*
 keratomileusis
 (LASIK) 156
 holmium laser correction
 of hyperopia 156
 lamellar keratoplasty 153 –
 154
 penetrating keratoplasty
 (corneal
 transplant) 117 – 118,
 143, 149, 152 – 153
 photorefractive kera-
 tectomy 155
 astigmatism correction
 156
 phototherapeutic kera-
 tectomy 154
 radial keratotomy 155 –
 156
 coronary cataract 183
 cortical
 blindness 401
 cataract 173 – 176
 cortisone
 cataract 183
 glaucoma 271
 couching 189
 coumarin derivatives 561
 cover test 6
 crab lice 37
 cranial nerve palsies 490,
 531
 combined palsies 491 –
 492
 see also specific nerves
 craniofacial dysplasia 409 –
 410

- craniofacial dysostosis 410
 oxycephaly 409
 craniopharyngioma 396–397
 craniostenosis 409
 craniosynostosis 535
 Credé's prophylaxis 60, 95, 97, 98
 crepitus 507
 cuneiform cataract 176
 curvature of field 456, 458
 cutaneous horn 42, 43
 cutis laxa senilis 19, 539, 540
 cyclitis 208
 Fuchs' heterochromic cyclitis 206
 see also iridocyclitis
 cycloablation 264
 cyclocryotherapy 216, 264
 cycloodialysis 262–264
 blunt trauma and 510
 cycloclathery 264
 cyclopentolate 551
 effects on pupil 225
 cycloplegics 426–427
 cylindrical lenses 5, 442, 443
 cysts
 conjunctival 105, 106
 dermoid 420
 ductal 40
 epidermoid 420
 pseudocysts 108
 round 40, 41
 see also dacryocystitis
 cytomegalovirus retinitis 350, 351
- D**
- dacryoadenitis 50, 64–65
 acute 64
 chronic 65
 dacryocystitis 57–60
 acute 57–58
 chronic 60
 conjunctivitis in 82
 neonatal 60, 97
 trauma and 499
 dacryocystography 53
 dacryocystorhinostomy 58–59, 60
 dacryostenosis 529
 Dalrymple's sign 412
 dark adaptation 303, 304
 degenerative
 myopia 339–340
 retinal disorders *see* retina
 retinoschisis 330, 333–334
 see also aging
 dendritic keratitis 132–133
 deposits
 acidic mucopolysaccharide 148, 150
 adrenochrome 111, 114
 amyloid 148
 vitreous body 287
 conjunctiva 114–115
 cornea 145–146
 Bowman's layer 146–147
 hyaline 148–149
 iron 111, 114
 depth perception 465
 dermatochalasis 19
 dermatogenic cataract 180, 181
 dermoid cyst 420
 descemetocoele 128, 129
 Descemet's membrane 118, 128
 Kayser-Fleischer ring 146
 tears of 126, 275
 desipramine 557
 Desmarres eyelid retractor 2, 3, 9
 diabetic
 cataract 179
 papillopathy 374
 retinopathy 272, 314–318, 323
 nonproliferative 315
 proliferative 215, 216, 315–316, 317
 dialysis cataract 179
 diaphragma sellae 396
 diazepam 556
 dichlorphenamide, glaucoma treatment 260
 digital subtraction dacryocystography 53
 digitalis 555, 562
 digitoxin 555
 digoxin 555
 dilator pupillae muscle 200, 220
 diphtheric conjunctivitis 85
 dipivefrin 552
 glaucoma treatment 257
 diplopia (double vision)
 464, 465, 486–488, 531–533
 binocular 531–533
 cataract and 434
 compensatory head posture 487–489
 crossed double images 488
 in orbital pseudotumor 416
 management 493
 monocular 533
 physiologic 464
 strabismus and 466
 uncrossed double images 488, 490
 vertical 491
 with blow-out fracture 507
 discharge, in conjunctivitis 76, 78
 diskiform keratitis 133
 dislocation of the lens 195–197, 533
 dispersion 456
 distorted vision 549–550
 distortion 457
 divergent strabismus *see* exotropia
 L-dopa 557
 Doppler scans 409
 dorzolamide 552
 glaucoma treatment 260
 double vision *see* diplopia
 Draeger's applanation tonometry 240
 Dräger esthesiometer 121
 drusen 310, 337, 366
 optic disk 366–367, 372
 dry eyes *see* keratoconjunctivitis sicca
 ductal cysts 40
 dysostosis multiplex 411
 dystrophy

dystrophy

- Best's vitelliform 313, 341–342
- cataract with myotonic dystrophy 179–180
- corneal 148–150
- Fuchs' endothelial 148, 149–150, 547
- macular 148, 150, 340–342
- retinal 340–345
- vitreoretinal 293

E

eccentric fixation 476

echothiophate 552

ectasia 158

ectopia lentis 196

ectropion 28–29, 529

- cicatricial 28, 29, 501

- congenital 28, 29

- paralytic 28, 29

- senile 28, 29

- with ductal cysts 40, 41

eczema, eyelids 30–31

edema

- Berlin's 511

- cornea 208, 210

- differential diagnosis

- 32–33

- eyelids 31–33

- macular 317, 319

- optic disk 367–368

- infiltrative 379

- papilledema 368–370,

- 371, 372

- pseudopapilledema

- 364–365, 372

Edinger-Westphal nuclei

- 220, 229

edrophonium chloride test

- 485

electrical injury, cataract

- and 182

electro-oculogram (EOG)

- 312–313, 314

electroretinogram (ERG)

- 312, 313

elephantiasis of the eyelids

- 45

emboli, retinal artery occlusion

- and 320–321

embryology

- cornea 117

- lens 165–167, 279

- retina 299

- vitreous body 279, 280

emergency keratoplasty

- 136, 152

emmetropia 423, 424, 425,

- 428

- refraction in 429

endophthalmitis 290–292,

- 536

endoscopy, lacrimal 53

endothelial dystrophy 148

endotheliitis 133

enophthalmos 405, 534

- causes of 406

- blow-out fracture 507

- Horner's syndrome 230

- senile 27

entopic phenomenon 307

entropion 24–27, 530

- cicatricial 27

- congenital 24, 26, 27

- spastic 26–27

eosinophilic granuloma 421

epibulbar dermoid 104, 105

epicanthal folds 21, 23

epidermoid cyst 420

epikeratophakia 151, 156

epinephrine 552

- effects on pupil 226

epipapillary membrane 366

epiphora 7, 30, 64, 529–530

- in conjunctivitis 74, 76,

- 78, 98

episcleritis 158, 159–160,

- 528, 542

epithelial corneal dystrophy

- 148

epithelial smear 80–82

erythema multiforme 99,

- 102

esotropia 438, 459, 467–

- 471

- accommodative 470

- acquired strabismus 469

- alternating 468

- congenital/infantile 468

- hyperopia and 465

- microstrabismus 469

- surgical correction 479

ethambutol 558

ethanol 562

ethmoidal air cells 403

eversion of eyelids 80

- lower eyelid 7–8, 67

- upper eyelid 8–9, 20, 67

examination 1–16

- anterior chamber 11–12

- binocular alignment 6

- choroid 202

- ciliary body 202

- confrontation field testing

- 14

- conjunctiva 7–10, 68–69,

- 80–82

- lower eyelid eversion

- 7–9, 20, 69, 80

- cornea 10–11, 120–125

- equipment 1–3

- eyelids 7, 19–20

- glaucoma *see* glaucoma

- history 3–4, 497

- intraocular pressure

- measurement *see*

- intraocular pressure

- iris 201–202

- lacrimal system 52–57

- nasolacrimal duct 7

- lens 12, 168–169

- ocular motility 5

- ophthalmoscopy 13

- optic nerve 223, 244–

- 246, 252, 362–363

- orbital cavity 405–409

- pupil 221–224

- refraction testing 429–

- 431

- retina 304–313

- fundus 304–308, 407

- sclera 157

- strabismus 471–477

- trauma 497–498

- visual acuity 4–5

- visual field testing *see*

- visual field

- visual pathway 391–394

- vitreous body 281

excimer laser *in situ* kerat-

- omileusis

- (LASIK) 151, 156

exophthalmometry 407–

- 408

exophthalmos 405, 534–

- 535

- causes of 406
- in craniostenosis 409
- in Graves' disease 411 – 412
- in orbital cellulitis 414
- in orbital pseudotumor 416
- intermittent 419
- pulsating 418 – 419
- with scleritis 162
- see also orbital cavity
- exotropia 409, 459, 471
- consecutive 471
- intermittent 471, 472
- secondary 471
- surgical correction 479
- exposure keratitis 140
- in Graves' disease 413
- external
 - astigmatism 441, 444
 - oculomotor nerve palsy 491
- extracapsular cataract
 - extraction 189 – 192
- extraocular muscles 459 – 460, 462 – 463
 - direction of pull 461
 - nerve supply 461
 - paralysis 486, 491
- exudative retinal detachment 328, 329, 330
- eye bandage 16
 - watch glass bandage 29
- eye charts 1 – 2
- eye closing reflex 14, 119
- eye ointment 15
- eye patching 478
- eyebrows 19
- eyedrops 15, 16
- eyeglass lenses
 - aberrations 456 – 458
 - astigmatic aberration 457, 458
 - chromatic aberration 456
 - curvature of field 457, 458
 - spherical aberration 456 – 457
 - absorption lenses 450
 - coated lenses 450
 - cylindrical lenses 5, 442, 443
 - minus (concave) lenses 5, 435 – 436
 - monofocal lenses 447
 - multifocal lenses 447 – 449
 - bifocals 447
 - progressive addition lenses 449
 - trifocals 449
 - occlusion 478
 - photochromic lenses 450
 - plastic lenses 450
 - plus (convex) lenses 5, 439, 440
 - prescription 448, 451
 - spherical lenses 447
 - strabismus treatment 477, 480
 - subjective refraction testing 450 – 451
 - toric lenses 447
- eyelashes 19
- trichiasis 30
- eyelids 17 – 47
 - deformities 2230
 - blepharospasm 30
 - ectropion 28 – 29
 - entropion 24 – 27
 - ptosis 22 – 24
 - trichiasis 30
 - developmental anomalies 20 – 22
 - ankyloblepharon 22
 - blepharophimosis 21
 - coloboma 20 – 21
 - epicanthal folds 21
 - examination of 7, 19 – 20
 - eversion 7 – 9, 20, 67, 80
 - glandular disorders 38 – 39
 - chalazion 39
 - hordeolum 38 – 39
 - injuries to 498 – 499, 500 – 503
 - protective function 17
 - signs, in Graves' disease 411 – 412
 - skin/margin disorders 30 – 37
 - abscess 36 – 37, 64, 538
 - contact eczema 30 – 31
 - edema 31 – 33
 - herpes simplex 34
- herpes zoster ophthalmicus 35 – 36
- louse infestation 37
- seborrheic blepharitis 33 – 34
- tick infestation 37
- structure of 17 – 19
- surgical retraction of
 - upper eyelid 24, 25
- swelling 538 – 539
- tumors 40 – 47, 539, 540
 - adenocarcinoma 47
 - basal cell carcinoma 45 – 47
 - cutaneous horn 42, 43
 - ductal cysts 40
 - hemangioma 43 – 44
 - keratoacanthoma 42 – 43
 - molluscum contagiosum 42
 - neurofibromatosis (Recklinghausen's disease) 44 – 45
 - squamous cell carcinoma 47
 - xanthelasma 40 – 42

F

- Fabry's disease 146
- facial nerve palsy 140
- family history 3
- far point 427 – 428
- Farnsworth-Munsell tests 311, 312
- farsightedness see hyperopia
- Fasanella-Servat procedure 25
- Ferry's line 146
- filamentary keratitis 63
- filtration surgery 262, 263
- fistula
 - arteriovenous 409
 - cavernous sinus 418
 - lacrimal sac 57
- fixation type 476
- flashes of light 537
- Fleischer ring 146
- flicker ERG 312
- floaters 282, 330, 543

- fluorescein angiography 307–308, 309
 fluorescein dye test 53
 conjunctival examination 63, 69
 corneal examination 120
 focal ERG 312
 follicles, in conjunctivitis 76, 78, 79
 foreign body 503–505, 516, 529
 conjunctivitis and 98
 copper foreign bodies 515
 iron foreign bodies 515
 metallic foreign bodies in the conjunctiva 111, 115
 organic foreign bodies 515
 removal 2, 3, 505
 subtarsal 505, 529, 530, 540
 fortification spectra 402
 Foster Kennedy syndrome 368
 fovea centralis 300–302, 321
 foveal reflex 308
 Franceschetti's syndrome 20, 28, 410
 Fuchs'
 black spot 339
 endothelial dystrophy 148, 149–150, 547
 heterochromic cyclitis 206
 fundus 308–309
 abnormal changes 310
 arteriosclerosis 323–325
 age-related changes 310
 examination of 304–308, 407
 contact lens examination 306–307
 fluorescence angiography 307–308, 309
 ophthalmoscopy 304–306
 photography 307
 ultrasonography 307, 308
 fundus flavimaculatus 340
 funnel of Martegiani 280, 283
 fusion 464
- G**
- galactosemic cataract 179, 185
 gaze centers 463
 lesions 482, 486
 gaze palsy 481, 486
 horizontal 483
 nystagmus 495
 vertical 484, 486
 gentamicin 552
 geometric horopter 464
 giant cell arteritis 378, 536, 546
 giant papillary conjunctivitis 98, 102
 contact lens complications 455
 glands of Krause 50, 51
 glands of Moll 17
 hordeolum 38
 round cysts 40, 41
 glands of Wolfring 50, 51
 glands of Zeis 17
 adenocarcinoma 47
 hordeolum 38
 glare 531
 sensitivity to 303–304
 absorption lenses and 450
 glassblower's cataract 182
 glasses *see* eyeglass lenses
 glaucoma 15, 233–277, 536, 543, 547
 absolute glaucoma 236
 acute glaucoma 265–270
 angle closure glaucoma 234–235, 236, 265–270
 mature cataract and 177
 primary 265–270
 rubeosis iridis and 215–216, 271–272
 secondary 212–213, 215–216, 271–272
 trauma and 272
 bullous keratopathy and 143
 cataract and 177, 178
 childhood 236, 273–277, 529
 classification 235–237
 cortisone glaucoma 271
 definition 233
 differential diagnosis 210–211, 215, 267, 275–276
 epidemiology 233, 251–252, 265
 examination methods 238–250
 gonioscopy 238–240, 252, 275
 intraocular pressure measurement 15, 240–244, 252, 275
 oblique illumination of the anterior chamber 238
 optic disk ophthalmoscopy 244–246, 252, 275
 retinal nerve fiber layer examination 250–251
 slit-lamp examination 238
 visual field testing 246–250
 inflammatory glaucoma 271
 juvenile glaucoma 236, 273–277
 low-tension glaucoma 253, 254
 myopia and 435
 neovascular glaucoma 271, 272
 open angle glaucoma 235, 236, 251–264
 iritis and 211, 212
 primary 251–264, 546
 secondary 211, 212, 271
 phacolytic glaucoma 178, 179, 271
 pigmentary glaucoma 271
 pseudoexfoliative glaucoma 271
 pupillary dilation and 11

- secondary glaucomas 133,
211–216, 233, 270–
273
following chemical
injury 522
treatment 253–264, 267–
270, 273, 276
indications for 253–
254
mechanical indentation
of the cornea 268
medical therapy 254–
255, 256–261, 267–
268
surgical treatment 256–
264, 268–270
- Glifford's sign 412
- glioma 387
optic nerve 422
- glucocorticoids 552, 560
- glycerine, glaucoma treat-
ment 261
- glycolipid lipidosis 146
- goblet cells 51
degeneration in conjunc-
tival xerosis 73
density of 53
- gold salts 559
- Goldenhar's syndrome 20,
104
- Goldmann hemispheric
perimeter 391, 392–
393
- Goldmann's applanation
tonometry 240, 242
- gonioscopy 202, 238–240,
252
in children 275
- goniometry 276
- gonococcal conjunctivitis
85
neonatal 95, 96–98
- granular dystrophy 148, 149
- granulomas 80, 104
eosinophilic 421
- Graves' disease 411–413,
484, 532–533, 534
- guanethidine 553, 555
glaucoma treatment 259
- H**
- Haab's striae 275
- Haemophilus aegyptius* con-
junctivitis 87
- Haemophilus influenzae* con-
junctivitis 86
- haloperidol 557
- Hand-Schüller-Christian
disease 421
- Harms tangent table 492–
493
- hay fever 98, 101
- headache 536–537
- Helmholtz ophthalmometer
442
- hemangioma
choroid 202
conjunctival 104, 106
eyelid 43–44
optic nerve 386
orbital cavity 420
retina 356–357
- hematoma
orbital 419
retrobulbar 512
- hemorrhage 535
subconjunctival 72, 499,
543
vitreous 287–290, 294,
497, 513, 545
- herpes simplex 34, 538
conjunctivitis 89, 98
keratitis 132–134
retinal infection 350, 351
- herpes zoster ophthalmicus
35–36, 539
conjunctivitis 89
keratitis 134
retinal infection 350, 351
- Hertel mirror exoph-
thalmometer 407–
408
- heterochromia 206
- heterophoria 455, 466, 480
- high blood pressure see
hypertension
- Hirschberg's method 471–
472
- histiocytosis X 421
- history 3–4, 497
- holmium laser correction of
hyperopia 151, 156
- homatropine, effects on
pupil 225
- homocystinuria, lens dis-
placement and 195,
196
- hordeolum 38–39, 538
differential diagnosis 58,
64
- horizontal gaze palsy 483
- Horner's syndrome 23, 24,
229–230, 534, 541
central 230
peripheral 230
- Horton's arteritis 320–321
- Hruby-Irvine-Gass syn-
drome 294
- Hudson-Stähli line 146
- human papillomavirus 106
- Humphrey field analyzer
391, 394–395
- Hurler's syndrome 411
- Hutchinson's sign 134
- hyaline
degeneration 69
deposits 148, 149
- hyaloid
artery, persistent 285, 366
canal 279, 284
fossa 165
membrane 280
- hydrophthalmia 273
- hydrophthalmos 273, 285
- hydroxychloroquine 558,
559
- hyperemia 75, 76
- hyperlysinemia 195
- hypermaturation cataract 177–
179
- hypermetropia see hyper-
opia
- hyperopia 5, 433, 436–440,
547, 549
axial 438
correction 439–440
converging lenses 439–
440
epikeratophakia 156
holmium laser 156
photorefractive kera-
tectomy 155
latent 438–439, 445
newborn 437
refractive 438

- hyperopia
strabismus and 465
- hyperostoses 420
- hypertension 323
ocular 253
- hypertensive retinopathy 323–325
- hypertropia 471
- hyphema 11, 208, 210, 513
- hypoglycemia 544
- hypoplasia, orbital 410
- hypopyon 11, 128, 129, 536
in uveal tract inflammation 208, 210
sterile 536
with bacterial keratitis 131
with mycotic keratitis 135
- hypotension papilledema 369
- hypothalamus 396
- hypotropia 471
- I**
- ibuprofen 560
- idoxuridine 553
- illacrimation 64
with conjunctivitis 74, 76, 78
- imipramine 557
- impalement injuries of the orbit 515–517
- impression cytology 53, 63
- inclusion conjunctivitis 60, 80, 92–93
- incomitant
angle of deviation 481, 488–490
strabismus 459
- indentation tonometry 240, 241
- indomethacin 560
- infantile
esotropia 468–469
recessive optic atrophy 383
strabismic amblyopia 472–473
treatment and avoidance 477–479
- infants *see* children;
neonate
- inferior concha 51
- inflammation
anterior chamber 146
lacrimal sac *see* dacryocystitis
orbital *see* orbital cavity
phacogenic 208
sclera 158–159
uveal tract 208–215
- inflammatory glaucoma 271
- infranuclear ocular motility disturbance 482, 483
- infrared radiation cataract 182
- injuries *see* ocular trauma
- intermittent
exophthalmos 419
exotropia 471, 472
- internal
astigmatism 441, 444
oculomotor nerve palsy 491
- internal carotid artery 396, 404
aneurysm 398, 399
stenosis 404
- internuclear ocular motility disturbance (INO) 482, 484, 485
- intracapsular cataract extraction 189
- intraocular lens (IOL) 187, 188
anisometropia correction 444, 445
- implantation 191
for congenital cataract 194
myopia correction 436
- intraocular pressure 233, 542
measurement of 15, 240–244, 252, 451
applanation tonometry 240, 242, 275, 435
in children 275
palpation 15, 240
pneumatic non-contact tonometry 240–241
Schiotz indentation tonometry 240, 241
tonometric self examination 243–244
twenty-four hour pressure curve 243, 252
see also glaucoma
- ionizing radiation injuries 524–525
- iridectomy, peripheral 268
- iridocyclitis 208, 209
acute 208–212
chronic 212–213
complicated cataract in 180, 181
recurrent 206
- iridodialysis, blunt trauma and 510
- iridodonesis 169, 196
- iridotomy 268
- iris 199–201, 428
aniridia 202–203
collarette 200
color 201
pigmentation anomalies 206
defects 229, 531, 533
examination methods 201–202
melanoma 216
neovascularization 215–216
prolapse 129
see also uveal tract
- iris print lenses 454
- iritis 208
acute 208–212
chronic 212–213
- iron deposits
conjunctiva 111, 114
cornea 146
- iron foreign bodies 515
- irregular astigmatism 441–442, 444
- irrigation 53, 54, 55
following chemical injury 518–520
in conjunctivitis 82
- Ishihara plates 311
- isocoria 220, 226
with constricted pupils 230–231
with dilated pupils 231–232
with normal pupil size 227
- isoniazid 558

J

- jaundice 115, 158
- Javal ophthalmometer 442
- juvenile
 - glaucoma 236, 273–277
 - retinoschisis 293

K

- Kaposi's sarcoma 113–114
- Kayser-Fleischer ring 146
- keratectomy
 - photorefractive 151, 155
 - astigmatism correction 156
 - phototherapeutic 151, 154
- keratitis 127–141, 529
 - Acanthamoeba* 136–137, 455
 - bacterial 130–132
 - contact lens complications 454–455
 - dendritic 132–133
 - diagnosis 130
 - diskiform 133
 - exposure 140
 - in Graves' disease 413
 - mycotic 134–136
 - neuroparalytic 141
 - pathogenesis 128–130
 - peripheral furrow 147–148
 - predisposing factors 128
 - stromal 133
 - superficial punctate 138–139
 - viral 132–134
 - herpes simplex 132–134
 - herpes zoster 134
 - keratoacanthoma 42, 43
 - keratoconjunctivitis 74, 89, 93–95
 - contact lens incompatibility and 142
 - phlyctenular 98, 102
 - sicca 62–63, 138, 528, 530
 - rose bengal test 52, 63
 - ultraviolet radiation-induced 523

- keratoconus 125–126, 533, 547
- keratoglobus 127, 533
- keratomalacia 148
- keratopathy 546
 - bullous 143–144, 148
 - calcific band 146–147, 212
- keratoplasty 136
 - allograft rejection 152–153, 154
 - emergency 136, 152
 - epikeratophakic 151, 156
 - lamellar 151, 153–154
 - penetrating (corneal transplant) 117–118, 143, 149, 151–153, 521
 - tectonic 152
- keratoscope 121, 442
- keratotomy, radial 151, 155–156
- Kestenbaum's operation 494
- kinetic perimetry 391, 392–393
- Kocher's sign 412

L

- lacrimal
 - canaliculi 51
 - caruncle 67
 - endoscopy 53
 - nerve 50
- lacrimal gland 50, 51
 - accessory lacrimal glands 50, 51
 - disorders 64–66
 - dacryoadenitis 64–65
 - tumors 66
 - injuries to 499
 - nerve supply 50
 - structure of 50
- lacrimal sac 51
 - abscess 57
 - fistula 57
 - inflammation of *see* dacryocystitis
 - injuries to 499
 - stenosis 57
 - tumors 61
- lacrimal system 49–66
 - disorders of lower lacrimal system 57–61, 530
 - canaliculitis 61
 - dacryocystitis 57–60
 - dysfunction 62–64, 138
 - illacrimation 64
 - karatoconjunctivitis sicca 62–63
 - examination methods 52–57
 - tear drainage evaluation 53–57
 - tear formation evaluation 52–53
 - injuries to 499, 500–503
 - tear drainage 51
 - tear film 50–51
 - see also* lacrimal gland; nasolacrimal duct
- lacrimation *see* illacrimation
- lagophthalmos 140
- lamellar
 - cataract 183, 184
 - keratoplasty 151, 153–154
 - allograft rejection 154
- lamina cribrosa 157, 361
- Langerhans' cell proliferation 421
- Lang's test 477
- laser interference visual acuity testing 431
- laser therapy
 - diabetic retinopathy 317, 318
 - excimer laser *in situ* keratomileusis (LASIK) 151, 156
 - glaucoma
 - argon laser trabeculoplasty 261–262
 - laser cycloablation 264
 - Nd:YAG laser iridotomy 268, 269
 - holmium laser correction of hyperopia 156
 - latanoprost, glaucoma treatment 260
- latent
 - hyperopia 438–439, 445
 - nystagmus 468

- latent strabismus *see* heterophoria
- lateral geniculate body 359, 389
- lesions 400
- lattice degeneration 334–335
- dystrophy 148
- lead 562
- Leber's atrophy 382–383
- lens 165–197
- accommodation mechanism 426
- aging 168
- developmental anomalies 169
- dislocation 195–197, 533
- embryology 165–167, 279
- examination of 12, 168–169
- retroillumination (Brückner's test) 168–169
- function 165
- metabolism 167–168
- position in eye 165, 166
- shape 165, 166
- subluxation 195, 197, 510, 533
- surgical removal of 436
- water content 168
- see also* cataract; contact lenses; eyeglass lenses; intraocular lens (IOL)
- lenticonus 169, 170
- lentiglobus 169
- Letterer-Siwe disease 421
- leukemic infiltrations 421
- leukocoria 169, 185
- differential diagnosis 286
- in children 548
- in Coats' disease 325, 548
- in retinoblastoma 354, 548
- with persistent hyperplastic primary vitreous 285, 286
- levator palpebrae muscle 23
- elongation of 540
- tears in 540
- levobunolol, glaucoma treatment 259
- lid lag 23
- ligament of Lockwood 460
- of Wieger 280
- light adaptation 303
- reflex 219–220
- consensual 220
- testing of 221–223
- lime injury 518, 521
- lipodermoid, differential diagnosis 65
- lipomatous pseudophakia 285
- liquefactive necrosis 518
- lithium 557
- loa loa 90
- loupes 456
- louse infestation, eyelids 37
- low-tension glaucoma 253, 254
- lower eyelid *see* eyelids
- luxation of the lens 195
- Lyell's syndrome 99, 103
- Lyme disease 351–352
- lymph nodes, swollen, in conjunctivitis 76, 79
- lymphoma 421
- conjunctival 113
- M**
- macropsia 335, 337
- macula lutea 300–302, 389
- macular degeneration, age-related 337–338, 546, 549
- dystrophies 148, 150, 340–342
- Best's vitelliform dystrophy 313, 341–342
- Stargardt's disease 311, 340–341
- edema 317, 319
- Maddox's cross 475
- magnetic resonance imaging, orbital cavity 409
- magnifying vision aids 455–456
- mandibulofacial dysostosis 20, 410
- dysplasia 410
- mannitol, glaucoma treatment 261
- marble-bone disease of Albers-Schönberg 411
- Marcus Gunn pupil 227
- Marfan's syndrome, lens displacement and 195, 196, 197
- mature cataract 174, 177, 186
- maxillary sinus 403
- mechanical injuries *see* ocular trauma
- medical history 3
- megalocornea 118, 124, 127
- meibomian glands 18, 50
- adenocarcinoma 47
- hordeolum 38
- melanin 201
- deficiency 206
- melanocytoma 385
- melanoma 110, 112–113
- choroid 216, 217
- ciliary body 217
- iris 216
- melanosin congenital 108, 110, 112–113
- conjunctival 108–112
- oculodermal 112
- of the iris 206
- membranes, in conjunctivitis 76, 78, 81
- membranous cataract 285
- meningioma 387, 398, 407, 420–421
- meningoencephalocele 410
- metallic foreign bodies in the conjunctiva 111, 115
- metamorphopsia 335, 337
- metastases orbital cavity 421
- uveal 217
- methyl alcohol 562
- metipranolol, glaucoma treatment 259
- microcornea 118, 124, 127
- microphakia 169
- microphthalmos 124, 285, 438
- micropsia 335, 337
- microstrabismus 469

- midazolam 556
migraine, ocular 402, 544, 549
Mikulicz's syndrome 65
minimum
 threshold resolution 423, 424
 visual angle 423
minus lenses 5, 435–436
 see also contact lenses;
 eyeglass lenses
miosis 220, 427, 541
 Horner's syndrome 230
Mittendorf's dot 183, 284
molluscum contagiosum 42
monocular
 loupes 456
 testing 450–451
monofocal lenses 447
Moraxella
 conjunctivitis 87
 keratitis 130
Morgagni's cataract 178
morning glory disk 385
morphine 557
mucocele 417
mucormycosis 417
multifocal lenses *see* eye-
 glass lenses
Munson's sign 126
muscle
 ciliary *see* ciliary body
 (muscle)
 dilator pupillae 200, 220
 extraocular muscles 459–
 463
 paralysis 486, 491
 levator palpebrae 23
 elongation of 540
 tears in 540
 oblique 459–463
 primary oblique muscle
 dysfunction 471, 479
 orbicularis oculi 17, 51
 rectus 459–462
 sphincter 200, 220
 blunt trauma and 511
 tarsal 17
myasthenia gravis 23–24,
 484–485, 541
mycoses 417
mycotic
 conjunctivitis 82, 91, 98
 endophthalmitis 291, 292
 keratitis 134–136
 mydriasis 220, 427, 542
 myelinated nerve fibers
 365–366
myogenic
 ophthalmoplegia 484–
 486
 ptosis 23–24
myopia 5, 432–436, 535,
 547, 549
 axial 434
 correction 435–436
 contact lenses 436
 diverging lenses 435–
 436
 epikeratophakia 156
 excimer laser *in situ*
 keratomileusis
 (LASIK) 156
 photorefractive kera-
 tectomy 155
 radial keratotomy 155–
 156
 degenerative 339–340
 pathologic 434
 refraction in 432
 refractive 434
 simple 434
 staphyloma 158, 159
myopia syndrome 434–435
myopic
 crescent 364
 sclerosis 434
myositis 416–417, 486, 532,
 535
myotonic dystrophy, cata-
 ract with 179–180
- N**
Nagel anomaloscope 311
naphazoline 553
nasolacrimal duct 51
 examination of 7
Nd:YAG laser iridotomy 268,
 269
near point 427
 testing 451
near reflex 220
 evaluation of 223–224
nearsightedness *see* myopia
necrosis
 acute retinal necrosis syn-
 drome 133
 liquefactive 518
neonate
 conjunctivitis 95–98
 differential diagnosis
 96–97
 dacryocystitis 60, 97
 newborn hyperopia 437
 see also children
neostigmine 553
 glaucoma treatment 257
neovascular glaucoma 271,
 272
neovascularization in the
 iris *see* rubeosis iridis
nerve
 abducent, lesions 482
 palsy 486, 490–491
 ciliary 157, 199
 cranial, palsies 490, 531
 facial, palsy 140
 lacrimal 50
 oculomotor *see* oculomo-
 tor nerve
 optic *see* optic nerve
 trigeminal 134, 141
 trochlear, lesions 482
 palsy 486, 487–488,
 489, 491
nervus intermedius 50
neurinoma 420
neuritis *see* optic neuritis
neurofibroma 45, 420
neurofibromatosis 44–45,
 386, 420, 421, 422
neuroparalytic keratitis 141
neuroretinal rim 361
nevus
 choroidal 217
 conjunctival 108, 109
 flammeus 44
 Ota's 112
newborn hyperopia 437
 see also neonate
nicotinic acid 561
nodose conjunctivitis 91
nuclear cataract
 acquired 173, 174, 176
 congenital 183, 184
nuclear ocular motility dis-
 turbance 482, 483

- nystagmus 494–495
 congenital 495
 fixation 495
 forms of 495
 gaze palsy 495
 latent 468, 495
 ocular 495
 optokinetic 494
- O**
- oblique
 astigmatism 441
 entry of optic nerve 363–364
- oblique muscles 459–460, 462–463
 direction of pull 461
 nerve supply 461
 primary oblique muscle dysfunction 471
 surgical correction 479
- occlusion therapy 477–479
- ochronosis 112, 114, 158
- ocular
 albinism 206, 207
 alignment evaluation 471–472
 hypertelorism 409
 hypertension 253
 migraine 402, 544, 549
 motility *see* ocular motility
 myositis 416–417, 486, 532, 535
 nystagmus 495
 pemphigoid 99, 103
 torticollis 488
 trauma *see* ocular trauma
- ocular motility 5, 407, 459–461
 acquired disturbances 482
 congenital disturbances 482
 in cavernous sinus thrombosis 415–416
 in orbital cellulitis 414, 415
 in orbital pseudotumor 416
- mechanical disturbances 486
- myogenic disturbances 484–486
- neurogenic disturbances 482–484
 infranuclear disturbance 482, 483
 internuclear disturbance 482, 484, 485
 nuclear disturbance 482, 483
 supranuclear disturbance 482, 483–484
see also nystagmus; strabismus
- ocular trauma 497–525
 chemical injuries 517–522
 treatment 518–521
 classification of injuries 498
 colobomas and 203, 205
 examination methods 497–498
 indirect trauma 525
 injuries due to physical agents 523–525
 burns 523–524
 radiation injuries 524–525
 ultraviolet keratoconjunctivitis 523
- lens displacement and 195, 196
- mechanical injuries 498–517
 blow-out fracture 507–513, 532, 534, 539, 540
 blunt trauma (ocular contusion) 506–507, 508–513
 conjunctival laceration 499–503
 eyelid injury 498–499, 500–503
 foreign bodies 503–505
 impalement injuries of the orbit 515–517
 open-globe injuries 514–515
- to lacrimal system 499, 500–503
 sclera 158
 secondary angle closure glaucoma and 272
 traumatic cataract *see* cataract
- ocular-mucocutaneous syndromes 99, 102
- oculoauriculovertebral dysplasia 20, 410
- oculocutaneous albinism 206
- oculodermal melanosis 112
- oculomandibular dysostosis 410
- oculomotor nerve 461
 aplasia 23
 lesions 482
 palsy 23, 228, 491, 541
 complete 228, 491
 external 491
 internal 491
- Onchocerca volvulus* 352
- onchocerciasis 90, 352
- open angle glaucoma *see* glaucoma
- open-globe injuries 514–515
- ophthalmia
 neonatorum (neonatal conjunctivitis) 95–98
 sympathetic 214–215, 446
- ophthalmic
 artery 199, 404
 veins 199, 405
- ophthalmic examination *see* examination
- ophthalmometer 442, 443
- ophthalmoplegia 481–494, 540
 chronic progressive external
 ophthalmoplegia (CPEO) 486
 diagnosis 492
 double vision 486–487
 myogenic 484–486
 neurogenic 482–484
 total 415
see also ocular motility

- ophthalmoplegic migraine 402
- ophthalmoscope 1
- ophthalmoscopy 13
- choroid 202
- fundus 304–306
- optic disk 244–246, 252
- in children 275
- trauma 497
- vitreous body 281
- optic chiasm 359, 389
- lesions 396–400
- optic cup 244–245, 275, 308, 361
- myopia and 435
- optic disk 13, 308, 360
- age-related changes 310
- blood supply 361
- coloboma 385
- disorders that obscure the margin 363–379
- anterior ischemic optic neuropathy (AION) 374–379, 536, 544, 546
- Bergmeister's papilla 366
- drusen 366–367, 372
- infiltrative edema 379
- myelinated nerve fibers 365–366
- oblique entry of the optic nerve 363–364
- optic neuritis 370–374
- papilledema 368–370, 371, 372
- pseudopapilledema 364–365, 372
- tilted disk 364
- in hyperopia 438
- ophthalmoscopy 244–246, 252
- in children 275
- shunt vessels 407
- tomography 246
- see also* optic nerve
- optic nerve 359–387, 389, 396
- atrophy 380–383, 399, 407
- primary 380–381, 382
- secondary 381–382
- avulsion 512
- blood supply 361, 362
- examination methods 244–246, 252, 362–363
- swinging flashlight test 223
- glaucoma and 244–246, 247
- injury to 512
- intracranial portion 361
- intraocular portion 360–361
- intraorbital portion 361
- myelinated nerve fibers 365–366
- oblique entry of 363–364
- pits 383–384
- tumors 385–387
- astrocytoma 385–386
- glioma 422
- hemangioma 386
- intraocular 385–386
- melanocytoma 385
- retrobulbar 387
- see also* optic disk
- optic neuritis 370–374, 415
- papillitis 370, 372–374, 375
- retrobulbar 363, 370, 372–373, 545, 547
- optic neuropathy *see* anterior ischemic optic neuropathy (AION)
- optic radiations 389
- lesions 400
- optic tract 359, 389
- lesions 400, 542
- optokinetic nystagmus 494
- oral contraceptives 561
- orbicularis oculi muscle 17, 51
- orbital
- apex syndrome 415
- cavity *see* orbital cavity
- cellulitis 404, 414–415, 416, 532, 535
- differential diagnosis 58, 64, 415
- treatment 415
- hematoma 419
- hypoplasia 410
- periostitis 417
- pseudotumor 416
- orbital cavity 403–422
- blood supply 404–405
- developmental anomalies 409–411
- craniofacial dysplasia 409–410
- mandibulofacial dysplasia 410
- meningoencephalocele 410
- osteopathies 411
- examination methods 405–409
- fat hernia 539
- Graves' disease and 411–413
- impalement injuries 515–517
- importance for eye 403
- inflammation 413–417
- cavernous sinus thrombosis 415–416
- mucocele 417
- mycoses 417
- myositis 416–417
- orbital periostitis 417
- orbital pseudotumor 416
- see also* orbital cellulitis
- surgery 422
- tumors 420–422
- dermoid cyst 420
- epidermoid cyst 420
- glioma 422
- hemangioma 420
- histiocytosis X 421
- leukemic infiltrations 421
- lymphoma 421
- meningioma 420–421
- metastases 421
- neurinoma 420
- neurofibroma 420
- rhabdomyosarcoma 421
- vascular disorders 418–419
- hematoma 419
- intermittent exophthalmos 419
- pulsating exophthalmos 418–419
- organic foreign bodies 515
- orthoptic exercises 480

- osmotic agents, glaucoma treatment 255, 261, 267
- osteopathies 411
- Ota's nevus 112
- oxycephaly 409
- P**
- pachymetry, corneal 125
- Paget's disease 411
- palpation, intraocular pressure measurement 15, 240
- palpebral
- conjunctiva 17, 20
 - fissure
 - shortening of 21, 22
 - width of 19, 507
- palsy 490, 531
- abducent nerve 486, 490–491
 - retraction syndrome 490–491
 - accommodation impairments 446–447
 - combined palsies 491–492
 - facial nerve 140
 - oculomotor nerve 23, 228, 491, 541
 - complete 228, 491
 - trigeminal nerve, ophthalmic division 141
 - trochlear nerve 486, 487–488, 489, 491
 - see also gaze palsy*
- panel D 15 test 362
- pannus formation, in conjunctivitis 76, 79
- panorama vision 471
- Panum's area 465
- panuveitis 208
- papillae
- Bergmeister's 366
 - contact lens incompatibility and 142
 - in conjunctivitis 76, 78, 80
- papilledema 368–370, 371, 372
- Foster Kennedy syndrome 368
 - hypotension papilledema 369
 - in craniostenosis 409
 - papillitis 370, 372–374, 375
 - papillomas
 - conjunctival 106–107
 - lacrimal sac 61
 - paralytic
 - ectropion 28, 29
 - keratitis 141
 - ptosis 23
 - strabismus 459, 481–494
 - parasitic
 - conjunctivitis 90–91, 98
 - retinal disorders 352–353
 - see also specific parasites*
 - parastriate area 389
 - parasympatholytic agents 426–427
 - parasympathomimetic agents 427
 - effects on pupil 224–225
 - glaucoma treatment 255, 256–257
 - paresis 481, 486
 - Parinaud's syndrome 80, 104, 231, 484, 486
 - pars plana 201
 - examination 202
 - vitrectomy (PPV) 294, 295
 - pars plicata 201
 - pathologic myopia 434
 - pattern deviations 469, 471
 - pattern ERG 312
 - penetrating keratoplasty
 - 117–118, 143, 149, 151, 152–153
 - allograft rejection 152–153, 154
 - penicillin 553, 558
 - perforated corneal ulcer 128
 - pericorneal injection 75
 - perimetry *see* visual field testing
 - periostitis, orbital 417
 - differential diagnosis 65
 - peripheral
 - furrow keratitis 147–148
 - Horner's syndrome 230
 - iridectomy 268
 - retinal degenerations 334–335
 - peristriate area 389
 - Perlia's nucleus 220
 - perphenazine 556
 - persistent
 - fetal vasculature 284–287
 - hyaloid artery 285, 366
 - hyperplastic primary vitreous (PHPV) 285–287, 548
 - phacodonesis 169, 196
 - phacoemulsification 190, 191
 - phacogenic inflammation 208
 - phacolytic glaucoma 178, 179, 271
 - phacomatosis 44
 - phenprocoumon 561
 - phenylephrine 553
 - effects on pupil 226
 - phenytoin 557
 - phlyctenular keratoconjunctivitis 98, 102
 - Phoropter 5, 450
 - photochromic lenses 450
 - photophobia 74
 - in albinism 206
 - photopsia 330
 - photorefractive keratectomy 151, 155
 - astigmatism correction 156
 - photosensitivity 30
 - phototherapeutic keratectomy 151, 154
 - phthisis 540
 - physiologic diplopia 464
 - physostigmine, effects on pupil 224
 - pigmentary glaucoma 271
 - pilocarpine 553
 - effects on pupil 224
 - glaucoma treatment 256, 268
 - pincushion distortion 457
 - pinguecula 69, 70, 528
 - pituitary gland 396
 - adenomas 396, 397
 - Placido's disk 121, 442
 - plastic lenses 450
 - plica semilunaris 67
 - plus lenses 5, 439, 440
 - see also* contact lenses; eyeglass lenses

- pneumatic non-contact tonometry 240–241
- pneumococcal conjunctivitis 84
- Pneumocystis carinii* infection 350
- polar cataracts 183
- polymethyl methacrylate (PMMA) 452
- post-diphtheria accommodation palsy 446
- posterior subcapsular cataract 174, 176–177
- postoperative aphakia 187, 438
- powder burns 524
- preferential looking test 472–473
- presbyopia 428
 - bifocal contact lenses and 454
 - progressive addition lenses and 449
- preseptal cellulitis 415
- primary
 - angle closure glaucoma 265–270
 - angle of deviation 490
 - choroidal process 214
 - oblique muscle dysfunction 471
 - surgical correction 479
 - open angle glaucoma 251–264, 546
 - optic nerve atrophy 380–381, 382
 - visual area 389
 - vitreous 279
- prism loupes 456
- prisms 455
 - prism bars 475
 - prism diopters 476
 - strabismus correction 474, 480, 493
- progressive addition lenses 449
- proliferative
 - diabetic retinopathy *see* diabetic retinopathy
 - vitreoretinopathy (PVR) 293
- proptosis, with scleritis 162
- prostaglandin, effects on pupil 224
- pseudocysts 108
- pseudoenophthalmos 405
- pseudoexfoliation
 - glaucoma and 271
 - lens displacement and 195, 196
- pseudoexophthalmos 405
- pseudoisochromatic plates 311
- pseudomembranes, in conjunctivitis 76, 78
- Pseudomonas*
 - conjunctivitis 86
 - keratitis 130
- pseudopapilledema 364–365, 372
- pseudophakia 187
 - lipomatous 285
- pseudopterygium 71
- pseudoptosis 74, 540
- pseudoretinitis pigmentosa 344–345
- pseudostrabismus 481
- pseudotumor, orbital 416
- pterygium 69–71, 529, 533
- ptosis 22–24, 540–541
 - acquired 22–24
 - congenital 22–24, 540
 - myogenic 23–24
 - paralytic 23
 - sympathetic 23, 24
- pulsating exophthalmos 418–419
- pump-leak system 167
- puncta lacrimales 51, 530
- punctal plugs 63
- pupil 219–232
 - distance between pupils 451
 - examination methods 221–224
 - swinging flashlight test 223
 - testing the light reflex 221–223
 - testing the near reflex 223–224
 - light reflex 219–220
 - motor dysfunction 226–232, 541–542
- see also* anisocoria; isocoria
- pharmacologic agent
 - effects 224–226, 231
 - size 220
- pupillary block 212–213, 234, 265, 266, 269
 - see also* glaucoma
- Purtscher's retinopathy 525
- pyramidal cataract 183
- Q**
- quinine 558, 562
- R**
- radial keratotomy 151, 155–156
- radiation injuries 524–525
 - infrared radiation cataract 182
 - ultraviolet keratoconjunctivitis 523
- radiography
 - lacrimal system 53, 57
 - orbital cavity 409
- Recklinghausen's disease 44–45, 386, 420, 421, 422
- reclination 189
- rectus muscles 459–460, 462
 - direction of pull 461
 - nerve supply 461
- red eye 542–543
- reflex
 - eye closing 14, 119
 - foveal 308
 - light 219–220
 - testing of 221–223
 - near 220
 - evaluation of 223–224
 - wall 308, 310
- refraction 423, 426
 - anomalies 432–445
 - see also* anisometropia; astigmatism; hyperopia; myopia

- refraction
 correction of errors *see*
 contact lenses; eye-
 glass lenses; prisms
 testing 429–431
 subjective refraction
 testing for eyeglasses
 450–451
- refractive
 hyperopia 438
 myopia 434
 power 425, 426
 of eyeglass lenses 447
- refractometry 431
- regular astigmatism 441,
 442
- relative afferent pupillary
 defect 223, 227
- resolution 423, 424
see also visual acuity
- retina 299–357
 corresponding points on
 464
 degenerative disorders
 328–340
 age-related macular
 degeneration 337–
 338
 central serous chori-
 oretinopathy 335–
 336, 549
 degenerative myopia
 339–340
 degenerative retinos-
 chisis 333–334
 peripheral retinal
 degenerations 334–
 335
see also retinal detach-
 ment
 dystrophies 340–345
 retinitis pigmentosa
 343–345
see also macular dystro-
 phies
 embryology 299
 examination methods
 304–313
 color vision evaluation
 311–312
 electrophysiologic
 examination methods
 312–314
 fundus examination
 304–308
 swinging flashlight test
 223
 in hyperopia 438
 inflammatory disease
 346–353
 AIDS-related disorders
 349–350
 parasitic disorders 352–
 353
 posterior uveitis due to
 toxoplasmosis 348–
 349
 retinal vasculitis 346–
 348
 retinitis in Lyme disease
 351–352
 viral retinitis 351
 injury to 515
 layers of 299–300, 301
 pars caeca retinae 299
 pars optica retinae 299
 resolving power *see* visual
 acuity
 sensitivity
 to glare 303–304
 to light intensity 303,
 428
 thickness of 300
 tumors 353–357
 astrocytoma 355–356
 hemangiomas 356–357
 retinoblastoma 286,
 353–355
 vascular disorders 314–
 327
 arteriosclerotic changes
 323–325
 Coats' disease 325–
 326, 548
 diabetic retinopathy
 314–318
 hypertensive reti-
 nopathy 323–325
 retinal artery occlusion
 320–322
 retinal vein occlusion
 318–320
 vascular supply 302
see also fundus; reti-
 nopathy
- retinal
 arteries 302
 central 302, 361
 occlusion 320–323,
 545
 detachment *see* retinal
 detachment
 dysplasia 285
 nerve fiber layer exami-
 nation 250–251
 periphlebitis 215
 tears 537
 vitreous detachment
 and 282–283
 vascular proliferation
 293–294
 vasculitis 346–348
 veins 302
 central 302, 361
 occlusion 215, 272, 318–
 320, 545
 retinal detachment 328–
 333, 537, 545, 548,
 549
 choroidal melanoma and
 217
 exudative 328, 329, 330
 in Coats' disease 325–326
 myopia and 435
 optic nerve pits and 384
 persistent hyperplastic
 primary vitreous and
 285
 rhexmatogenous 293,
 328–329, 330, 331–
 332, 334
 tractional 328, 329, 330
 treatment 295–298
 tumor-related 328, 329,
 330
 vitreous detachment and
 282, 293, 328–329
 retinitis 537
 in Lyme disease 351–352
 pigmentosa 312, 343–345
 viral 351
 cytomegalovirus 350
 retinoblastoma 286, 353–
 355, 548
 retinochoroiditis 214, 292
 retinohypothalamic tract
 389–391

- retinopathy
 blunt trauma and 512
 diabetic 272, 314–318, 323
 nonproliferative 315
 proliferative 215, 216, 315–316, 317
 hypertensive 323–325
 of prematurity 326–327, 548
 Purtscher's retinopathy 525
 toxic 345–346
- retinoschisis
 degenerative 330, 333–334
 juvenile 293
- retinoscopy 430
- retraction syndrome 490–491
- retrobulbar
 hematoma 512
 optic nerve tumors 387
 optic neuritis 363, 370, 372–373, 545, 547
- retroillumination of the lens (Brückner's test) 168–169, 281
- rhabdomyosarcoma 421
- rhegmatogenous retinal detachment 293, 328–329, 330, 331–332, 334
- rifampicin 553, 559
- rigid contact lenses 452–563
see also contact lenses
- ring of Zinn 361
- rings around light sources 542
- river blindness 90
- rod-cone dystrophy 343, 344
- Rodenstock perimeter 391
- rods 303
- rose bengal test 52, 69
 corneal examination 120
 in keratoconjunctivitis sicca 52, 63
- Roth's spots 291–292
- rubella
 congenital cataract and 185
- retinal infection 351
- rubeosis iridis 215–216, 271–272, 317
- Rubinstein–Taybi syndrome 410
- rudimentary coloboma 364, 384
- S**
- salicylic acid 560
- sarcoma
 Kaposi's 113–114
 lacrimal sac 61
- Schiøtz indentation tonometry 240, 241
- Schirmer tear testing 52
 in keratoconjunctivitis sicca 62
- sclera 157–163
 color changes 157–158
 ectasia 158
 examination methods 157
 inflammations 158–159
 staphyloma 158, 159
 trauma 158
- scleritis 158–159, 161–163, 542
 anterior
 necrotizing 162, 163
 non-necrotizing 161, 163
 posterior 162, 163
 staphyloma and 158
- scleromalacia perforans 161, 162
- scopolamine 554
 effects on pupil 225
- scotoma
 central 466
 fixation point 466
 in central serous chorioretinopathy 335
 in glaucoma 246, 249, 250, 253
 in ocular migraine 402
 with optic neuritis 372–373
- sebaceous glands 17, 18, 50
- seborrheic blepharitis 33–34
- secondary
 angle of deviation 490
 cataract 192, 193, 212–213
 in children 194
 exotropia 471
 glaucoma 133, 211–216, 233, 270–273, 522
 optic nerve atrophy 381–382
 vitreous 279
- sella turcica 396, 399–400
- senile
 cataract *see* cataract
 ectropion 28, 29
 enophthalmos 27
 sunken eye 534
- sensory adaptation 466
- serpiginous corneal ulcer 129–130, 131, 134–135, 536
- shadow testing 430
- shortsightedness *see* myopia
- silver catarrh 60
- simple
 anisocoria 229
 myopia 434
- Simpson test 485
- simultaneous vision 461–464
- slit lamp
 anterior chamber examination 238
 corneal examination 120, 121, 125, 135
 iris examination 201–202
 lens examination 12, 168–169
- snail track degeneration 334
- Snell's law 425
- snowflake cataract 179
- soft contact lenses 453
see also contact lenses
- spastic entropion 26–27
- spectacles *see* eyeglass lenses
- specular microscopy 121–124
- spherical
 aberration 456–457
 lenses
 contact lenses 453
 eyeglasses 447

- spherophakia 344
 sphincter muscle 200, 220
 blunt trauma and 511
 spoke phenomenon 293
 squamous cell carcinoma 47
 staphylococcal
 conjunctivitis 84
 hordeolum 38
 keratitis 130
 staphyloma 158, 159
 Stargardt's disease 311, 340–341
 static perimetry 391, 394–395
 Stellwag's sign 412
 stenosis
 craniostenosis 409
 dacryostenosis 529
 internal carotid artery 404
 lacrimal system 53, 55, 56, 57
 stereoscopic vision 465
 steroid cataract 182, 183
 Stevens–Johnson syndrome 99, 102
 Stilling–Velhagen plates 311
 Stocker–Busacca line 146
 strabismus 459, 533
 latent *see* heterophoria
 paralytic 459, 481–494
 prisms and 455
 pseudotrismus 481
 see also concomitant strabismus; esotropia; exotropia; ocular motility
 streptococcal conjunctivitis 84
 streptomycin 559
 striate cortex 389
 stromal
 corneal dystrophy 148–150
 keratitis 133
 subcapsular cataract 174
 posterior 174, 176–177
 subconjunctival hemorrhage 72, 543
 trauma and 499
 subluxation of the lens 195, 197, 510, 533
 sulfite oxidase deficiency 195
 sulfonamide 554, 559
 superficial punctate keratitis 138–139
 suppression 466
 amblyopia secondary to 466–467
 supranuclear ocular motility disturbance 482, 483–484
 supraorbital artery 404
 supratrochlear artery 404
 sweat glands 17, 50
 swinging flashlight test 223
 symblepharon 521, 522
 sympathetic
 heterochromia 206
 ophthalmia 214–215, 446
 ptosis 23, 24
 sympatholytic agents, glaucoma treatment 255, 259
 sympathomimetic agents
 effects on pupil 225–226
 glaucoma treatment 255, 257–258
 synchysis 282
 scintillans 287
 synechiae 211–212
- T**
- Taenia solium* 353
 tarsal
 glands 18
 muscle 17
 plate 17
 tarsorrhaphy, lateral 140
 tear break-up time (TBUT) 52
 in keratoconjunctivitis sicca 62
 tear drainage 51
 evaluation of 53–57
 tear film 50–51
 evaluation of 52–53
 in keratoconjunctivitis sicca 62, 63
 significance for cornea 119
 tearing *see* epiphora
- tectonic keratoplasty 152
 telangiectasia 325, 326
 telescopes 456
 Teller acuity card 473
 temporal arteritis 320, 378–379, 536, 546
 tenonitis 416
 Tenon's capsule 160, 416, 460
 Tensilon test 485
 tertiary vitreous 279
 tetany cataract 180
 tetracycline 554, 559
 thioridazine 556
 thyroid dysfunction 411–413
 tick infestation, eyelids 37
 tilted-disk syndrome 364
 timolol 551
 glaucoma treatment 259
 Tolosa–Hunt syndrome 416
 tonic pupil 228, 446, 447
 tonometry 240–244
 applanation tonometry 240, 242, 275, 435
 pneumatic non-contact tonometry 240–241
 Schiotz indentation tonometry 240, 241
 tonometric self-examination 243–244
 toric lenses
 contact lenses 453
 eyeglasses 447
 total
 astigmatism 440
 ophthalmoplegia 415
 toxic
 cataract 182
 conjunctivitis 76–78, 97
 retinopathy 345–346
Toxocara canis 352, 353, 355
Toxocara cati 352, 353
 toxoplasmosis 348–349
 AIDS-related retinal infection 350
 trabecular network 157, 234–235, 273
 argon laser trabeculoplasty 261–262
 trabeculotomy 276, 277
 trachoma 88, 93

- tractional retinal detachment 328, 329, 330
 trauma *see* ocular trauma
 traumatic cataract *see* cataract
 Treacher Collins' syndrome 410
 trichiasis 27, 30, 530
 tricyclic antidepressants 557
 trifluridine 553
 trifocal lenses 449
 trigeminal nerve 134, 141
 palsy of ophthalmic division 141
 trigeminal neuralgia, blepharospasm and 30
 trilateral retinoblastoma 354
 trochlear nerve lesions 482
 palsy 486, 487–488, 489, 491
 tropia 6
 tropicamide, effects on pupil 225
 tuberous sclerosis 386
 tumor-related retinal detachment 328, 329, 330
 tumors
 choroid 202
 conjunctival *see* conjunctiva
 eyelids *see* eyelids
 lacrimal gland 66
 lacrimal sac 61
 optic nerve 385–387
 orbital cavity 420–422
 retina 353–357
 uveal tract 216–217
 visual pathway 396–398
 tunica vasculosa lentis 279, 280
 Tyndall effect 202, 208, 210
- U**
- Uthoff symptom 372
 ulcers, corneal perforated 128
- serpiginous 129–130, 131, 134–135, 536
see also keratitis
- ulcer
 rodens 46
 terebans 46
 ultrasonography
 A-mode scan 409
 B-mode scan 408
 fundus examination 307, 308
 orbital cavity examination 408–409
 vitreous body 281
 ultraviolet keratoconjunctivitis 523
 uncover test 480
 unilateral
 aphakia 445
 strabismus 473
 unilateral cover test 473–474
- upper eyelid *see* eyelids
 uveal tract 199–217
 developmental anomalies 202–205
 aniridia 202–203
 coloboma 203–205
 examination methods 201–202
 inflammation 208–215
 neurovascular supply 199, 200
 pigmentation anomalies 206–207
 tumors 216–217
 metastases 217
 see also choroid; ciliary body; iris
 uveitis 208–215, 547
 causes of 209
 posterior 543
 due to toxoplasmosis 348–349
 with scleritis 162
- V**
- V pattern deviation 469, 471
 varicella zoster virus *see* herpes zoster ophthalmicus
- vascular pigmented layer *see* uveal tract
 vasculitis, retinal 346–348
 vein
 angular 405
 ophthalmic 199, 405
 retinal 302
 central 302, 361
 occlusion 215, 272, 318–320, 545
 vortex 157, 199
 venous pulse 13
 vernal conjunctivitis 98, 101
 vertex distance 451
 vertical
 deviations 471
 dissociated 471
 diplopia 491
 gaze palsy 484, 486
 verticillata, corneal 145–146
 vidarabine 553
 videokeratoscopy 121, 122–123, 442
 viral
 conjunctivitis 76–79, 81, 89, 93–95
 keratitis 132–134
 retinitis 351
 visual
 agnosia 401
 areas 461
 primary visual area 389
 cortex 389
 lesions 400
 visual acuity
 corrected 423
 decreased 544–547
 testing 4–5
 in the presence of opacifications 431
 uncorrected 423
 visual evoked potential (VEP) 313, 363
 visual field 391
 testing 246–250, 253, 391–394
 confrontation field testing 14
 in retinal artery occlusion 321
 kinetic perimetry 391, 392–393

- visual field
testing
orbital cavity disorders 408
static perimetry 391, 394–395
- visual pathway 389–402
disorders 394–402
chiasmal lesions 396–400
prechiasmal lesions 394
retrochiasmal lesions 400–402
examination methods 391–394
see also optic nerve
- vitamin A 561
deficiency
conjunctival xerosis 72–74, 148
tear film and 62
- vitamin D 561
- vitrectomy 294–298, 331
- vitreoretinal dystrophies 293
- vitreous
amyloidosis 287
hemorrhage 287–290, 294, 497, 513, 545
- vitreous body 279–298
abnormal changes 284–293
abnormal opacities 287
endophthalmitis 290–292
persistent fetal vasculature 284–287
vitreoretinal dystrophies 293
- vitreous hemorrhage 287–290
vitritis 290–292
- abscess 291
- aging changes 282–284
synchysis 282
see also vitreous
detachment
- attachments of 280–281
- cataract surgery and 294
- composition 279
- embryology 279, 280
- examination methods 281
- importance for eye 279
- neurovascular supply 281
- retinal detachment and 293
- retinal vascular proliferation and 293–294
- retinal vasculitis and 346–347
- surgical treatment 294–298
- vitreous detachment 282–284, 537, 543
blunt trauma and 510
retinal detachment and 282, 293, 328–329
- vitritis 290–292
- Vogt-Koyanagi-Harada syndrome 330
- von Graefe's sign 412
- von Hippel disease 386
- von Hippel-Lindau disease 356, 386
- vortex veins 157, 199

W

- Waardenburg syndrome 23
- Wagner's disease 293
- wall reflex 308, 310
- warfarin 561
- watch glass bandage 29
- waxy pallor optic atrophy 383
- Weill-Marchesani syndrome 169
lens displacement and 195, 196
- Weiss' ring 283, 284
- Wessely keratometer 124
- Wilson's disease 146
- with-the-rule astigmatism 441

X

- xanthelasma 40–42
- xerosis, conjunctival 72–74, 148

Z

- zonular cataract 183
- zonule 201
- zonule fibers 165, 195, 279
accommodation mechanism 426